

## **DEXTROSE PROLOTHERAPY VERSUS BOTOX INJECTION FOR THE MANAGEMENT OF TMJ DISC DISPLACEMENT WITH REDUCTION**

Aalaa S. Emara \* and Noha M. El Adl\*\*

### **ABSTRACT**

**Background:** Temporomandibular disc displacement is a widely faced clinical condition and the management options are vast with varying difficulty and success rates. This study aims to evaluate the use of Botulinum Toxin injection and dextrose prolotherapy for such cases.

**Methods:** 20 joints were included in this study divided into 2 groups; Group 1 receiving 25% 3mL Dextrose injection (with local anesthetic and saline solution) into the retrodiscal region while group 2 received 35 U Botulinum Toxin – Type A injection in the lateral pterygoid muscle. Pain (according to the visual analogue scale), clicking and maximal interincisal opening were assessed preoperatively and at 4 months followup.

**Results:** The results showed no statistically significant differences between the 2 groups. The click disappeared in 7/10 joints in group 1 and 9/10 in group 2. The maximal interincisal opening was regained and slightly increased in all participants of the study. All patients reported better pain scores at the end of the followup period.

**Conclusions:** Within the limitations of this study, we conclude that both treatment options tested are considered acceptable in the management of TMJ anterior disc displacement with reduction. Moreover, the results do not allow recommending one over the other as no statistically significant differences were found.

**KEYWORDS:** Prolotherapy, Botox, TMJ, TMJ disc, internal derangement

### **INTRODUCTION**

The Temporomandibular joint (TMJ) is considered the most complex synovial articulation in the human body<sup>1</sup>. The articular disc is a flexible, biconcave structure formed of dense connective

tissue, positioned between the posterior slope of the articular tubercle and the antero-medial surface of the mandibular condyle. Three distinct regions are identifiable in the articular disc; posterior band (thickest portion), intermediate band (thinnest part) and the anterior band (intermediate thickness)<sup>2-4</sup>.

\* Lecturer of Oral Maxillofacial Surgery, Faculty of Dentistry, Cairo University, Egypt

\*\* Researcher of Surgery and Oral Medicine Department, National Research Centre; Cairo, Egypt

A normal disc position is when the posterior band of the disc is atop the cranial portion of the mandibular condyle at a 12 o'clock position on Magnetic resonance images (MRI)<sup>1</sup>. Nevertheless, many studies reveal that this position is not observed in around 30% of asymptomatic subjects<sup>5-7</sup>. This has made treatment of discal displacement mostly dependent on symptoms rather than anatomical disc position. The articular surface of the mandibular condyle is related to the intermediate band of the disc which receives high compressive forces and the position is maintained by intra-articular pressure<sup>6, 7</sup>

TMJ disc displacement is characterized by the abnormal position of the articular disc in relation to the mandibular condyle and the mandibular fossa<sup>2,6,8</sup> anterior and anterior-lateral displacements are the most commonly noted. In this case the bilaminar zone is pressed against the articular surfaces, and the retrodiscal tissues are positioned atop the condylar head. This leads to modifications in the mechanical properties of the tissues and jeopardizes vascular and neural supply and leads to pain, clicking and possibly episodes of jaw locking<sup>9, 10</sup>. Disc displacements may be classified as; disc displacement with reduction (DDWR) and disc displacement without reduction (DDWoR)<sup>11, 12</sup>. In DDWR an articular shift is observed during mandibular closing but repositioning occurs during opening. Some authors state that DDWR may be the earliest stages of DDWoR but it is considered stable as long as there are no complaints of locking<sup>12</sup>. TMJ clicking corresponds to 26.2% of clinical signs of TMD and is one of the most common complaints of patients<sup>13, 14, 15</sup> which when accompanied with pain and malfunction necessitate treatment<sup>15</sup>. Disc dislocation is thought to be caused by the excessive pull from the lateral pterygoid muscle which inserts at the anterior part of the disc<sup>16, 17</sup>.

DDWR is commonly treated with an intraoral occlusal appliance which achieves realignment

during the night but are reported by the patients to cause discomfort and compromise breathing<sup>12, 18, 19</sup>. Other management options for were researched to treat TMJ disc derangement. The use of Botulinum Toxin (BTX) injection into the lateral pterygoid muscle was based on the hypothesis that the lateral pterygoid muscle's pull causes the disc dislocation. Moderate doses of BTX injected into the lateral pterygoid with EMG guidance provided relief of symptoms such as clicking and joint pain. This result proved the lateral pterygoid's role in DDWR.<sup>16, 20, 21</sup>

Moreover, prolotherapy (proliferation injection therapy) was based on initiating a low-grade inflammatory process within the joint which attracts fibroblasts and so strengthens the attachments of tendons and ligaments and so improves disc position. It stabilizes the joint, improves the range of motion in a hypomobile joint, helps prevent dislocation in a hypermobile joint, and relieves pain<sup>22-24</sup>.

This study aims to compare the effects of BTX injection and dextrose prolotherapy in the management of symptomatic TMJ disc displacement with reduction.

## PATIENTS AND METHODS

Twenty patients were included in this study according to the sample size calculation selected from the Oral Surgery clinic at the Faculty of Dentistry, Cairo University and the dental clinics at the National Research Centre. All patients consented to the enrollment in this clinical trial and an ethical approval was acquired from the Ethical committee at Cairo University and complied with the Declaration of Helsinki.

The inclusion criteria were male patients diagnosed with TMJ anterior disc displacement with reduction (clinically had a painful click and reciprocal click) and radiographically by an MRI. Patients

with history of previous treatment for TMD, systemic joint issues (such as rheumatoid arthritis) or any conditions contraindicating MRI (pacemakers) were excluded.

The patients were randomly divided into two groups; Group 1 included 10 patients to receive prolotherapy while Group 2 included 10 patients to receive BTX injection in the lateral pterygoid muscle.

### Preoperative measurements of all patients included

Maximal interincisal opening in millimeters using a caliber from the between the anterior teeth at the maximal unassisted nonpainful opening of the patient.

Assessing the presence or absence of a click was done clinically by palpation at the preauricular region.

The Visual Analogue scale (VAS) was used to assess pain scores.

### Group 1 Prolotherapy injection:

The posterior joint space is located by cleansing the skin with alcohol immediately anterior to the tragus of the ear and palpating the lateral pole of the condyle as the patient opens and closes. The target is the depth of the depression that forms immediately anterior to the tragus of the ear as the condyle translates forwards and downwards. This is marked with a washable felt-tip pen. A disposable bite block is placed between the patient's anterior teeth to keep the patient from closing the condyle back into the fossa during injection. The injection needle penetrates the skin at the marked point and is directed medially and slightly anteriorly to avoid penetration into the ear. A negative confirmatory

aspiration was necessary to ensure safe injection. (Figure 1)

1 mL of the prepared solution were then injected. The intracapsular solution was prepared by drawing 0.75 mL of 25% dextrose, 0.75mL of saline and 1.5mL of plain anesthesia into a 3-mL syringe.

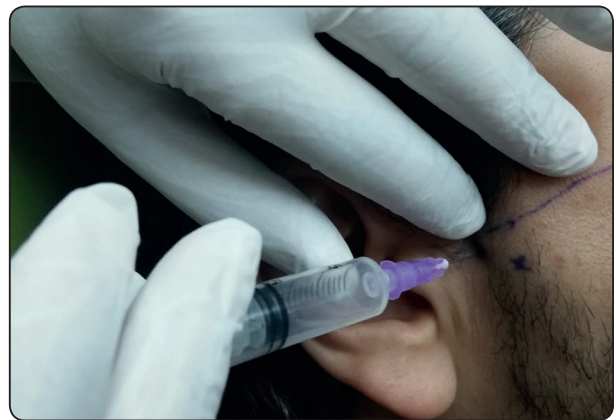

Fig. (1) Identification and insertion of prolotherapy injection while a bite block maintains the patient's mouth open to avoid closure and posterior space collapse on the needle.

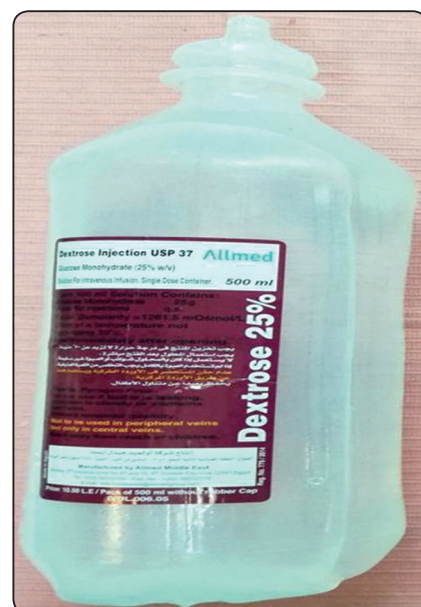

Fig. (2) : Dextrose solution used for prolotherapy.

\* Signal Amplifier for BTX-A, manufactured by Barrett Engineering Fortuna, CA 95540. US distributor Allergan, Inc Irvine, CA 92612 - USA

### Group 2 Botox injection

Group 2 patients received 35U of Botulinum Toxin Type A (Allergan) injected at the insertion of the lower head of the lateral Pterygoid muscle under audible electromyographic guidance\*.

The BTX vial was unpacked and 2 ml saline added slowly along the walls of the vial to obtain a 5 unit/0.1 ml solution. The solution was swirled to ensure complete mixing and 0.7 ml of the solution containing 35 U was drawn into an insulin syringe. The audible Electromyogram device (EMG) was used during injection to confirm the needle position into the target muscle. Two surface electrodes were placed, one on the patient's cheek and the other on the neck near the sternocleidomastoid muscle and the EMG needle attached to the insulin syringe (Figure 3) The lateral pterygoid muscle was approached intraorally from the opposite side and advanced lateral to the maxillary tuberosity with the needle directed towards the neck of the condyle where the lateral pterygoid inserts. Once at the needle reached the target position, the patient was asked to move his mandible laterally to activate the muscle; causing the EMG to produce a distinct loud sound. After negative aspiration, the solution

was injected slowly over a period of 5-10 seconds. (Figure 4 )

All patients were recalled weekly during the first month then monthly for three more months (total followup period of 4 months). The same pre-operative measurements were repeated at the end of the follow up period.

### Statistical analysis

The mean and standard deviation values were calculated for each group in each test. Data were explored for normality using Kolmogorov-Smirnov and Shapiro-Wilk tests, MIO data showed parametric (normal) distribution while Click and VAS data showed non-parametric (not-normal) distribution.

For parametric data; Independent sample t-test was used to compare between two groups in non-related samples. For non-parametric data; Mann Whitney test was used to compare between two groups in non-related samples. The significance level was set at  $P \leq 0.05$ . Statistical analysis was performed with IBM® SPSS® Statistics Version 20 for Windows.

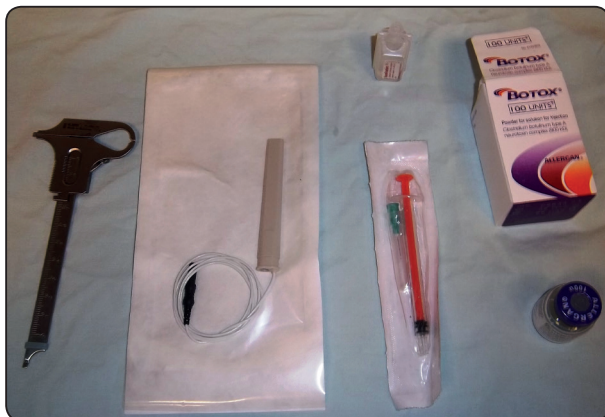

Fig. (3) : Armamentarium needed for BOTOX injection with EMG needle guidance

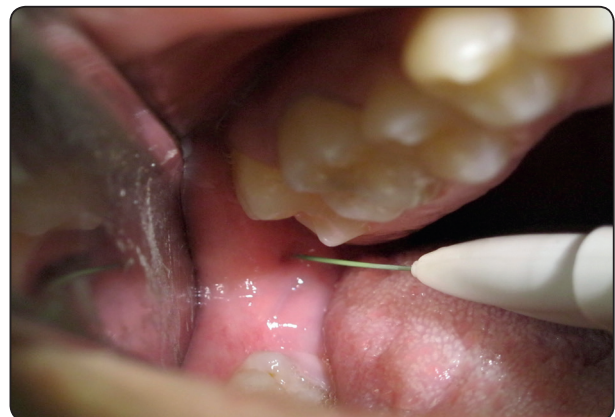

Fig. (4) : BTX injection at the insertion of the lower head of the lateral pterygoid

**RESULTS**

All 20 patients included in the study completed the trial and no dropouts were reported. None of the patients showed any adverse reactions or extreme side effects after the treatment protocol.

Clinical assessment of all the joints was completed in the 4- month followup time period and the same preoperative measurements were recorded at the end of the followup.

**Maximal interincisal opening**

Statistical analysis of the MIO (maximal interincisal opening) measurements showed no statistically significant difference between the 2 groups preoperatively and postoperatively (p=0.301 and p=0.256 respectively). On the other hand, the mean difference between MIO preoperatively and postoperatively was 1.5 mm in the BOTOX group while it was 2.6 mm in the Dextrose group; with the highest increase in maximal interincisal opening (7 mm increase) was seen in the Dextrose group and the lowest increase (0 mm) was seen in the BOTOX group (table 1) (figure 5). There was a slight increase of MIO by the end of the study period but that was statistically insignificant.

Patient	Preoperative	Postoperative					
		1 wk	2 wk	1 mo.	2mo.	3 mo.	4 mo.
1	42	18	25	33	36	36	39
2	42	18	25	33	36	36	39
3	43	25	26	29	34	37	42
4	43	25	26	29	34	37	42
5	37	21	23	27	30	34	37
6	37	21	23	27	30	34	37
7	41	23	25	30	36	39	42
8	41	23	25	30	36	39	42
9	37	21	25	29	32	38	38
10	37	21	25	29	32	38	38

DEXTROSE GROUP							
Patient	MIO preo	postop 1 wk	2wks	1 month	2 months	3 months	4 months
1	35	26	30	40	42	42	42
2	41	36	34	38	40	40	39
3	36	30	38	40	45	43	39
4	38	35	33	38	40	41	41
5	38	36	38	38	40	42	41
6	40	35	31	36	36	41	40
7	39	37	37	39	40	43	42
8	42	36	39	40	43	44	40
9	40	38	38	39	40	40	40
10	42	38	38	39	42	42	41

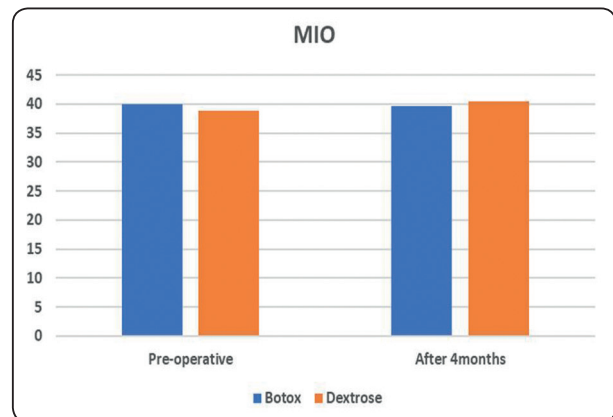


Fig. (5) Bar chart showing the mean maximal interincisal opening preoperatively and at the end of the followup period

**Presence of a click**

Regarding the presence of a click; all 10 joints in each group had a click preoperatively (incidence of 100%). Postoperatively the results were also statistically insignificant with a p value of 0.276; but it is to be noted that 3 joints had a click at the end of the 4-month follow-up period in Group 1 while only one joint regained a click in group 2 (figure 6).

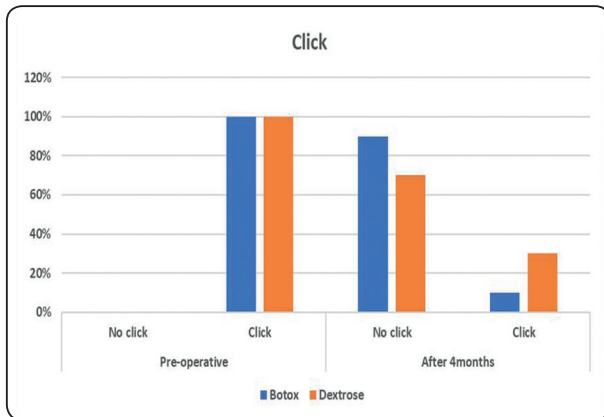


Fig. (6) Bar chart showing percentage of clicking joints in the 2 groups at the preoperative and postoperative assessment timepoints

### Pain scores

The recorded VAS scores preoperatively and postoperatively were analyzed. This showed no statistically significant difference between both groups as well (preoperatively  $p=0.969$  and postoperatively  $p=0.937$ ). the highest mean VAS score postoperatively was recorded in the BOTOX group (7) while the means in both groups was 3 for the BOTOX group and 2.9 in the Dextrose group.

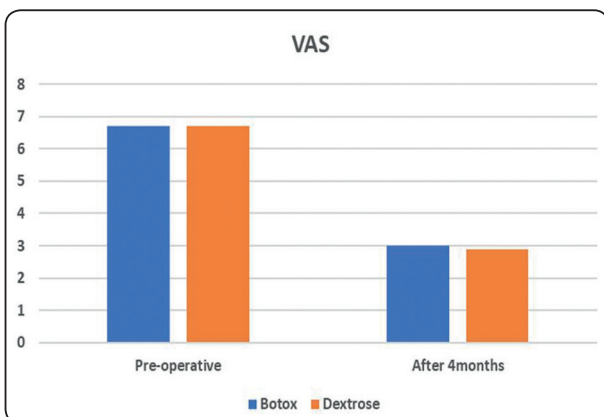


Fig. (6) Bar chart showing percentage of clicking joints in the 2 groups at the preoperative and postoperative assessment timepoints

### DISCUSSION

Temporomandibular disorders are commonly faced clinical complaints. Reports of clicking, joint pain, malfunction and episodes of jaw locking are the main symptoms reported by patients. With the rise in stress levels of middle-aged individuals nowadays, TMDs are becoming a regular finding. The cause of such disorders is still controversial with stress, muscle spasm and malocclusion being the most agreed on reasons. Non-invasive treatment protocols such as BTX and prolotherapy techniques have been researched to provide relief of TMD symptoms<sup>16, 20, 24, 25</sup>. The aim of this study was to assess the use of dextrose injection (prolotherapy management) versus BTX injection as treatment options for cases of DDWR.

Results of our study show no statistically significant differences between the results of the two groups: one receiving an intracapsular dextrose injection and the other receiving BTX injection in the lateral pterygoid muscle. Both groups showed clinical and pain score improvements indicating that both techniques could be considered successful.

The use of dextrose solution initiates an inflammatory reaction which in turn calls on connective tissue and fibroblast growth factors. As reported in literature the use of dextrose solutions of 5-25% has proven efficacy<sup>26</sup>, in this study a 25% dextrose solution with local anesthetic and saline solution were used to inject into the retrodiscal tissue to relieve the pain and improve function. Our results also support the effect of the prolotherapy injection in pain relief and improving function. That is seen in the disappearance of the click in 7 out of the 10 joints in the group. This may be attributed to the regeneration of the backward pull of the retrodiscal tissue on the disc improving its position and correcting the anterior displacement. Moreover, the improved pain scores are probably also due to the relief of the strain, inflammation and condylar trauma on the retrodiscal tissues which are highly

innervated and vascular. The slight improvement of the mean maximal interincisal opening also supports the regenerative effect of the dextrose injection by improving discal position and reducing pain. This leads to an increase in unassisted maximal incisal opening.

On the other hand, BTX injection in the lateral pterygoid was reported to improve pain and TMJ disc position in cases of DDWR<sup>16, 21, 27, 28</sup>. This was attributed to the transient chemodenervation and reduced function of the lateral pterygoid, without any adverse effects. In addition, the BTX-A blocking of gamma motor neurons to the muscle spindles in the LP may have temporarily changed the kinetic information and the feedback to the alpha motor neurons as well as modulated arthrokinetic reflexes. BTX has been reported to alleviate symptoms of DDWR and MRI analysis showed an improved discal position at 3 months postoperatively<sup>29, 30</sup>. This is in accordance with the results with our study which showed loss of clicking in all but one of the included joints by the 4<sup>th</sup> month postoperatively. This also supports the theory stating the role of the anterior pull of the lateral pterygoid muscle on the disc displacement. Maximal interincisal opening of Group 2 patients was regained at the end of the 4 month period in accordance with the literature stating that the effect of a single Botox injection lasts for 3-4 months<sup>16, 20</sup>. Long-term effects of the BTX injection needs longer followup periods as some research has pointed out anatomical variations after long-term followup<sup>31</sup>. This may be attributed to the denervation effect of the injection which causes a lack of function of some muscle fibres which may explain long term loss of some muscle fibres.

Moreover, combining the results of both groups (dextrose injection in the retrodiscal tissue), may indicate that the disc displacement is attributed to multiple factors including the lateral pterygoid's anterior pull and loss of elasticity of the retrodiscal tissue.

The results of this study support the use of both technique – retrodiscal dextrose injection and lateral pterygoid BTX injection- for the management of DDWR cases. Within the limitations of this study, the comparison of the techniques does not allow recommending one over the other since the differences are not significant. Clinically, both techniques are chair-side and minimally painful, but it should be mentioned that the cost of the BTX injection is more than three folds that of the dextrose injection. Further studies assessing the long term effects and with larger sample sizes are recommended.

## REFERENCES

1. Alomar X MJ, Cabratosa J, Clavero J, Lorente M, Serra I, Monill J, Salvador A. . Anatomy of the temporomandibular joint. *Semin Ultrasound CT MR* 2007; 28: 170-183. DOI: doi: 10.1053/j.sult.2007.02.002. PMID: 17571700.
2. Griffin CJ, Hawthorn R and Harris R. Anatomy and histology of the human temporomandibular joint. *Monogr Oral Sci* 1975; 4: 1-26. 1975/01/01. DOI: 10.1159/000397863.
3. Ottria L, Candotto V, Guzzo F, et al. Temporomandibular joint and related structures: anatomical and Histological aspects. *J Biol Regul Homeost Agents* 2018; 32: 203-207. 2018/02/21.
4. Greene CS. "The Ball on the Hill": A new perspective on TMJ functional anatomy. *Orthod Craniofac Res* 2018; 21: 170-174. 2018/10/16. DOI: 10.1111/ocr.12245.
5. Poluha RL CG, Costa YM, Grossmann E, Bonjardim LR, Conti PCR. Temporomandibular joint disc displacement with reduction: a review of mechanisms and clinical presentation. *J Appl Oral Sci* 2019; 21: e20180433. DOI: doi: 10.1590/1678-7757-2018-0433. .
6. Eberhard L, Giannakopoulos NN, Rohde S, et al. Temporomandibular joint (TMJ) disc position in patients with TMJ pain assessed by coronal MRI. *Dentomaxillofac Radiol* 2013; 42: 20120199. 2013/03/19. DOI: 10.1259/dmfr.20120199.
7. Gokalp H. Disc position in clinically asymptomatic, pre-treatment adolescents with Class I, II, or III malocclusion: A retrospective magnetic resonance imaging study. *J Orofac Orthop* 2016; 77: 194-202. 2016/05/06. DOI: 10.1007/s00056-016-0024-6.

8. Ahmad M and Schiffman EL. Temporomandibular Joint Disorders and Orofacial Pain. *Dent Clin North Am* 2016; 60: 105-124. 2015/11/29. DOI: 10.1016/j.cden.2015.08.004.
9. de Farias JF, Melo SL, Bento PM, et al. Correlation between temporomandibular joint morphology and disc displacement by MRI. *Dentomaxillofac Radiol* 2015; 44: 20150023. 2015/03/26. DOI: 10.1259/dmfr.20150023.
10. Serindere G and Aktuna Belgin C. MRI investigation of TMJ disc and articular eminence morphology in patients with disc displacement. *J Stomatol Oral Maxillofac Surg* 2021; 122: 3-6. 2020/10/16. DOI: 10.1016/j.joramas.2020.09.019.
11. Al-Baghdadi M, Durham J, Araujo-Soares V, et al. TMJ Disc Displacement without Reduction Management: A Systematic Review. *J Dent Res* 2014; 93: 37S-51S. 2014/03/25. DOI: 10.1177/0022034514528333.
12. Devi J, Verma M and Gupta R. Assessment of treatment response to splint therapy and evaluation of TMJ function using joint vibration analysis in patients exhibiting TMJ disc displacement with reduction: A clinical study. *Indian J Dent Res* 2017; 28: 33-43. 2017/04/11. DOI: 10.4103/ijdr.IJDR\_154\_16.
13. Poluha RL, De la Torre Canales G, Bonjardim LR, et al. Clinical variables associated with the presence of articular pain in patients with temporomandibular joint clicking. *Clin Oral Investig* 2020 2020/11/14. DOI: 10.1007/s00784-020-03685-8.
14. Olliver SJ, Broadbent JM, Thomson WM, et al. Occlusal Features and TMJ Clicking: A 30-Year Evaluation from a Cohort Study. *J Dent Res* 2020; 99: 1245-1251. 2020/07/15. DOI: 10.1177/0022034520936235.
15. Poluha RL, De la Torre Canales G, Bonjardim LR, et al. Somatosensory and psychosocial profile of patients with painful temporomandibular joint clicking. *J Oral Rehabil* 2020; 47: 1346-1357. 2020/08/20. DOI: 10.1111/joor.13081.
16. Emara AS, Faramawey MI, Hassaan MA, et al. Botulinum toxin injection for management of temporomandibular joint clicking. *Int J Oral Maxillofac Surg* 2013; 42: 759-764. 2013/03/30. DOI: 10.1016/j.ijom.2013.02.009.
17. Yilmaz D and Kamburoglu K. Comparison of the effectiveness of high resolution ultrasound with MRI in patients with temporomandibular joint disorders. *Dentomaxillofac Radiol* 2019; 48: 20180349. 2019/02/28. DOI: 10.1259/dmfr.20180349.
18. Wanman A and Marklund S. Treatment outcome of supervised exercise, home exercise and bite splint therapy, respectively, in patients with symptomatic disc displacement with reduction: A randomised clinical trial. *J Oral Rehabil* 2020; 47: 143-149. 2019/09/15. DOI: 10.1111/joor.12888.
19. Ma Z, Xie Q, Yang C, et al. Can anterior repositioning splint effectively treat temporomandibular joint disc displacement? *Sci Rep* 2019; 9: 534. 2019/01/27. DOI: 10.1038/s41598-018-36988-8.
20. Bakke M, Moller E, Werdelin LM, et al. Treatment of severe temporomandibular joint clicking with botulinum toxin in the lateral pterygoid muscle in two cases of anterior disc displacement. *Oral Surg Oral Med Oral Pathol Oral Radiol Endod* 2005; 100: 693-700. 2005/11/23. DOI: 10.1016/j.tripleo.2004.11.019.
21. Bakke M, Baram S, Dalager T, et al. Oromandibular dystonia, mental distress and oro-facial dysfunction-A follow-up 8-10 years after start of treatment with botulinum toxin. *J Oral Rehabil* 2019; 46: 441-449. 2019/01/22. DOI: 10.1111/joor.12768.
22. Priyadarshini S, Gnanam A, Sasikala B, et al. Evaluation of prolotherapy in comparison with occlusal splints in treating internal derangement of the temporomandibular joint - A randomized controlled trial. *J Craniomaxillofac Surg* 2021; 49: 24-28. 2020/12/07. DOI: 10.1016/j.jcms.2020.11.004.
23. Abrahamsson H, Eriksson L, Abrahamsson P, et al. Treatment of temporomandibular joint luxation: a systematic literature review. *Clin Oral Investig* 2020; 24: 61-70. 2019/11/16. DOI: 10.1007/s00784-019-03126-1.
24. Taskesen F and Cezairli B. Efficacy of prolotherapy and arthrocentesis in management of temporomandibular joint hypermobility. *Cranio* 2020; 16: 1-9. 2020/12/17. DOI: 10.1080/08869634.2020.1861887.
25. Nagori SA, Jose A, Gopalakrishnan V, et al. The efficacy of dextrose prolotherapy over placebo for temporomandibular joint hypermobility: A systematic review and meta-analysis. *J Oral Rehabil* 2018; 45: 998-1006. 2018/07/20. DOI: 10.1111/joor.12698.
26. Fouda AA. Change of site of intra-articular injection of hypertonic dextrose resulted in different effects of treatment. *Br J Oral Maxillofac Surg* 2018; 56: 715-718. 2018/08/16. DOI: 10.1016/j.bjoms.2018.07.022.
27. Altaweel AA, Elsayed SA, Baiomy A, et al. Extraoral Versus Intraoral Botulinum Toxin Type A Injection for Man-



- agement of Temporomandibular Joint Disc Displacement With Reduction. *J Craniofac Surg* 2019; 30: 2149-2153. 2019/06/25. DOI: 10.1097/SCS.0000000000005658.
28. Martin-Granizo R, Maniegas L, Colorado L, et al. Direct infiltration of botulinum toxin into the pterygoid lateral muscle for repositioning of the disc during arthroscopy of the temporomandibular joint. *Br J Oral Maxillofac Surg* 2018; 56: 769-771. 2018/08/14. DOI: 10.1016/j.bjoms.2018.07.014.
29. Awan KH. The therapeutic usage of botulinum toxin (Botox) in non-cosmetic head and neck conditions - An evidence based review. *Saudi Pharm J* 2017; 25: 18-24. 2017/02/23. DOI: 10.1016/j.jsps.2016.04.024.
30. Bilyk JR, Yen MT, Bradley EA, et al. Chemodenervation for the Treatment of Facial Dystonia: A Report by the American Academy of Ophthalmology. *Ophthalmology* 2018; 125: 1459-1467. 2018/04/15. DOI: 10.1016/j.ophtha.2018.03.013.
31. Lee HJ, Kim SJ, Lee KJ, et al. Repeated injections of botulinum toxin into the masseter muscle induce bony changes in human adults: A longitudinal study. *Korean J Orthod* 2017; 47: 222-228. 2017/07/04. DOI: 10.4041/kjod.2017.47.4.222.