



AUTOGENOUS SYMPHYSEAL VERSUS RETROMOLAR GRAFTS FOR 3D AUGMENTATION OF ANTERIOR MAXILLARY DEFICIENCIES

Nadia Galal*

ABSTRACT

Objective: To Compare and contrast different intraoral autogenous grafts for 3D reconstruction of atrophic anterior maxillae, to receive dental implants.

Patients & Methods: Twelve patients suffering from anterior maxillary bone resorption and in need for bone augmentation to be able to place dental implants were included in this study. Autogenous bone grafts were harvested from either the symphyseal region (Group A) or the retromolar region (Group B). Assessments were performed using CBCT both pre- and post-operatively; as well as, clinically on delayed implant placement.

Results: Both groups showed significant bone formation at 4 months postoperatively, and implants were placed with adequate initial stability. Group A, showed significantly higher insertion torque mainly occlusal and midway upon placement than Group B. All cases had uneventful fixed prosthetic loading of implants.

Conclusion: Both symphyseal and retromolar intraoral donor graft sites provide successful graft material for anterior maxillary 3D reconstruction, however, the symphyseal grafts despite providing better initial stability for implants, yet, were less perceivable by the patients regarding postoperative pain and oedema; and provided no significant difference regarding successful loading of dental implants with fixed prosthetics.

INTRODUCTION

The alveolar bone of the anterior maxilla is rapidly recontoured after the loss of the natural teeth, even in the presence of an intact alveolus after extraction. There is a 25% decrease in volume during the first year and a 40% to 60 % decrease in width within the first 3 years of extraction.⁽¹⁾ Autologous

grafts are considered the golden standard in terms of osteogenic potential, but they present some disadvantages, such as limited availability of material from the intraoral donor sites and morbidity at bone graft donor site.^(2, 3) The ideal characteristics of a bone graft substitute include the following: it should be cost effective; biocompatible with the host bone;

* Associate Professor, Oral and Maxillofacial Surgery Department, Faculty of Dentistry, Cairo University

minimize surgical time and bone exposure; osteogenic; osteoinductive; and osteoconductive, where the graft material can serve as a scaffold for bone apposition⁽⁴⁾ Classification of the atrophied alveolar ridge has been well documented throughout the literature, as that proposed by Cawood and Howell⁽⁵⁾ who proposed that the shape of basilar process of the mandible and maxilla remains relatively stable, whereas changes in shape of the alveolar process are significant in both the vertical and horizontal axes and follow the predictable pattern, and hence they proposed six different resorption stages. Of interest here, are Class IV: knife-edge ridge with sufficient height but insufficient width; and Class V: flat ridge with insufficient height and width.⁽⁵⁾

Intraoral harvested membranous graft (symphysis, mandibular ramus) show a lesser amount of resorption than endochondral bone graft (iliac crest)⁽⁶⁾, and having advantages of close proximity of donor and recipient sites, convenient surgical access, decrease donor site morbidity, and less expensive.⁽⁷⁾ Cortical autografts possess excellent structural integrity and are mechanical supportive, but have limited number of osteoprogenitor cells.⁽⁸⁾ Moreover, edentulous ridge augmentation using intraorally harvested bone blocks from the mandibular symphysis and the ramus buccal shelf are attractive techniques for several reasons. The advantages include: Horizontal alveolar bone volume increase documented up to 7.5mm, compared to only up to 4.5mm increase documented with particulate Guided bone regeneration (GBR) techniques.^(9, 10) Rapid integration allows early reentry for implant placement, often in 3-4 months compared to the 6-9 months required for particulate GBR techniques.^(11, 12) Reliable space maintenance during healing ensures the shape and stability of the bone block is retained without collapse.⁽¹¹⁾

Onlay grafts have proved useful for the treatment of combined vertical and lateral defects.^(13, 14)

Furthermore, Khoury, described bone blocks that are placed at a distance from the alveolar ridge for the three-dimensional reconstruction; as well as, the shell technique for three-dimensional hard tissue grafting. Thin cortical bone shell, harvested with a special cutting wheel from the retromolar region, were placed to reshape the alveolar crest and to protect the in-between bone graft.⁽¹⁵⁾ The advantage of the augmentation technique using cortical shell grafts at a distance from the ridge in comparison with mesh augmentation is the avoidance of a titanium mesh. In the case of dehiscence, an exposed titanium mesh involves a high risk of partial or complete loss of the graft as a result of bacterial contamination. Moreover, at reentry for implant placement a much larger part of the alveolar ridge has to be exposed to remove the titanium mesh. In comparison with titanium mesh augmentation, bone blocks offer the benefit of being osteoconductive.⁽¹⁶⁾ Augmentation with cortical shell at a distance from the alveolar ridge as compared to pure block grafting offers the advantage that the augmentation material does not consist of one single bone block, but also includes particulate material. Particulate grafting material revascularizes faster and better than cortical and/or cortico-cancellous block grafts.^(17, 18)

Cone beam computed tomography (CBCT) offers an effective, non-invasive and relatively low radiation technique for assessment of dimensional changes in the alveolar ridge.⁽¹⁹⁾ The anatomic radiographic fidelity of bone structures and accuracy of linear measurements are crucial for basic preoperative implant planning, and even more when applied in image-guided implant surgery. Studies show that 94% of the CBCT measurements have been accurate, within 1 mm. However, standardization is necessary for this technique to be truly reliable and this is obtained by superimposition or fusion where images should always be captured and reconstructed at identical positions.⁽²⁰⁾ Economopoulos TL et al.,

2012 in order to get identical CBCT sections for reliable quantitative measurements.⁽²¹⁾ The three basic types of superimposition algorithm are: (1) point landmark-based, (2) surface-based, and (3) voxel-based.⁽²²⁾ Anatomic landmarks are good choice to determine a fixed position on both real human body and images.⁽²³⁾

PATIENTS AND METHODS

Twelve patients with atrophied anterior maxillae in need for dental implantation were selected for this study. The patients were selected from the outpatient clinic of the Oral & Maxillofacial Surgery department, Faculty of Dentistry, Cairo University. Inclusion criteria included anterior maxillary alveolar ridge deficiency, minimum two teeth, with an initial ridge width of 5 mm or less. This was determined from the preoperative examination using a ridge mapping caliper and cone beam computed tomography (CBCT). On the CBCT scans, the initial ridge width was measured at three points; the crest, mid-way and 10 mm apical to the crest. (fig 1) After medical evaluation, dental examination, laboratory investigations, cast analysis and radiographic examination, patients were ready for surgery.

Full thickness mucoperiosteal flap at proposed

recipient site, bone scoring was performed in cortical bone to initiate bleeding. Autologous bone blocks were harvested from:

Group A: Symphyseal area according to desired dimensions

Group B: Retromolar region according to desired dimensions

The grafts were then fixed to recipient site using micro screws. The voids around bone blocks were filled using bone particulates; autogenous particulates harvested from chin around autogenous blocks, and Autogenous particulate collected from the retromolar region using DCM burs. The bone was then covered using collagen membrane, and mucoperiosteal flap was repositioned and sutured in place. (fig.2)

Clinical follow-up was performed on a weekly basis for the first postoperative month, and then on a monthly basis till the fifth postoperative month, at which the patients had dental implants placed. CBCT follow-up was performed immediate post-operatively and after 4 months prior to implant placement, for ideal assessment of the grafted sites and implant planning. Microscrews were removed during this second exposure prior to implant drilling.

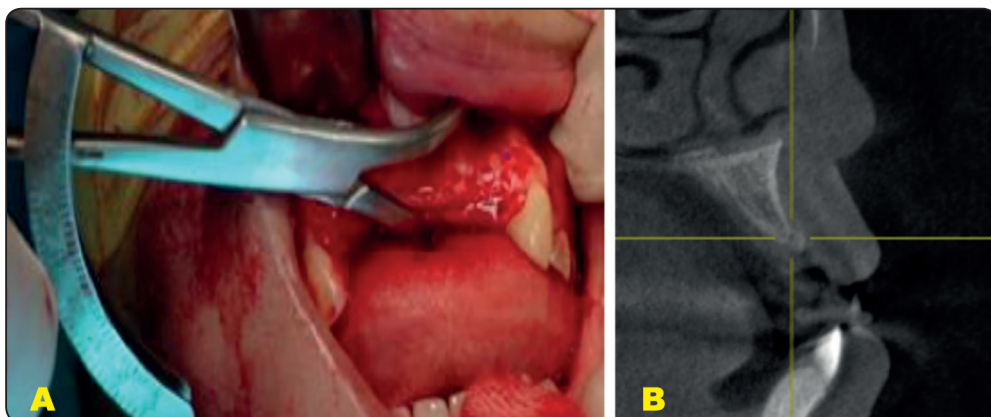


Fig. (1): Documenting the ridge width at 3 levels using (A) Caliper; and (B) CBCT cross sectional slices

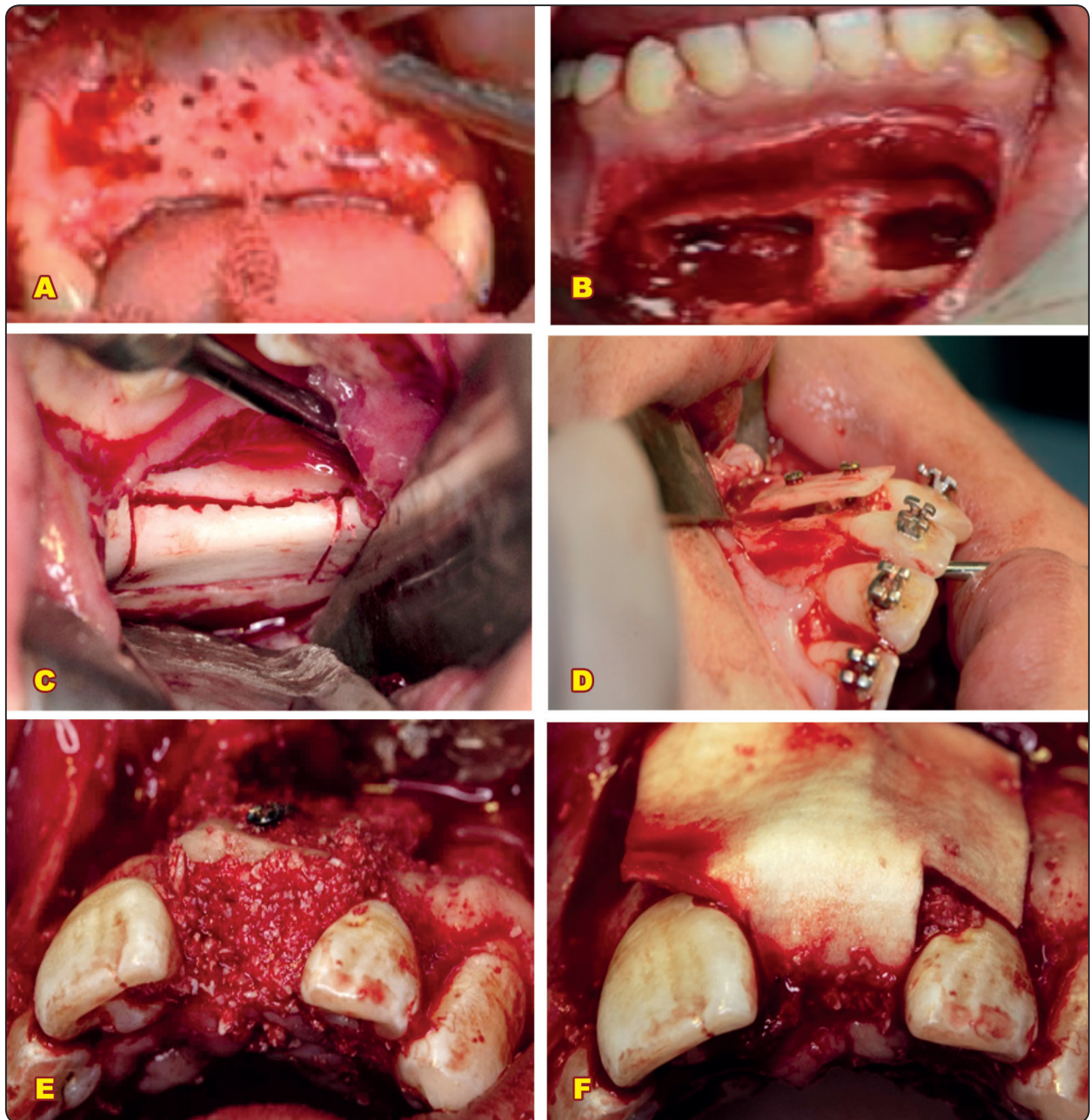


Fig. (2): (A) Decortication of the recipient site in anterior maxilla; (B) Symphyseal block graft harvesting; (C) Retro-Molar graft harvesting; (D) Fixation of the retro-molar graft at recipient site using microscrews; (E) Filling the gaps and voids using autogenous bone; and (F) Application of collagen membrane over the grafts.

RESULTS

Uneventful healing was noted during the postoperative clinical follow-up, except for one patient in Group B, where there was bone graft exposure at the 5th postoperative week. This patient was instructed strict oral hygiene measures and

mouth wash (0.125% Chlorohexidine HCL). The patient underwent routine disinfection of the exposed bone, and the exposed bone was trimmed off under copious saline irrigation, under local anesthesia. The site was left to heal by secondary intention.

The prescribed analgesics were enough to control postoperative pain as reported by the patients. No damage to the adjacent mandibular teeth was detected at the donor site. None of the patients experienced subjective neurosensory functional deficits in terms of hypoesthesia, numbness or tingling in the lower lip at the donor sites in both groups.

Linear bone measurements on cross-sectional CBCT cuts were carried out at pre-, immediate and 4 months postoperatively, to assess horizontal bone gain. There were statistically significant gain between the pre-operative and both post-operative measurements among each group; with no significant difference between both groups. This result was consistent along the crestal, midway and apical measures in both groups. However, the most gain in horizontal bone width was clearly documented at the crestal measurements in both groups, and the

least gain was at the apical measurements. Vertical bone gain followed a similar path in both groups, however, it was of a statistically significant less bone gain compared to the horizontal bone gain. Still there were mildly significant differences between the pre-operative and post-operative values, and non significant differences between the 2 post-operative values (immediate and 4 months) nor between the two groups. (Figure 3 A to C)

In the second stage surgery for implant placement the demarcation between the cortical bone graft and the particulate bone graft, in both groups. Implants were placed with a minimum torque of 30Ncm, and wound sutured back on top with 4-0 Vicryl sutures. (Figure 3-D)

Panoramic x-rays were taken following implant placement at the second stage surgery as well as following final prosthetics placement. (Figure 3E & F)

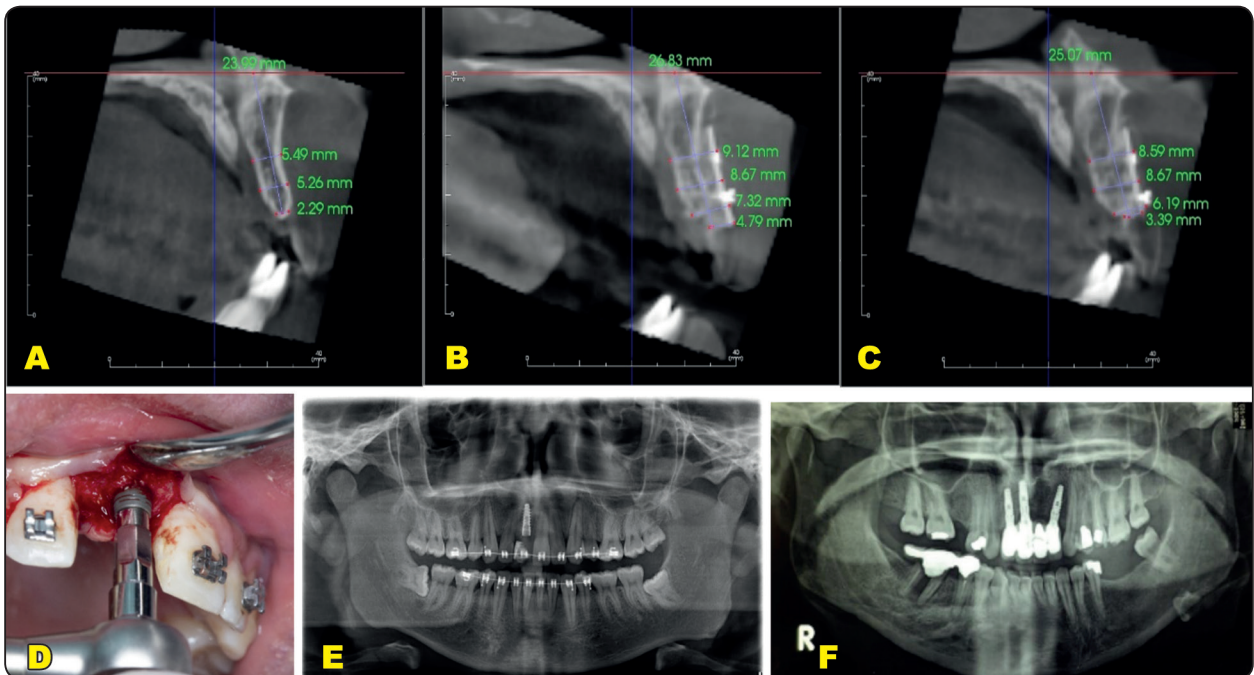


Fig. (3) : (A-C) CBCT cross-sectional slices (A) Pre-operative; (B) Immediate Post-operative; and (C) 4 months post-operative. (D) Clinical picture of Implant placement in grafted site; (E) Panoramic x-ray following implant placement; (F) Panoramic x-ray following final prosthetics.

DISCUSSION

Dental implants in the esthetic zone are a huge challenge especially when significant resorption exists. Resorption in this region is reported to constitute up to 25% in volume loss in the first year.^(1,24) Grafting being an integral part of the process to achieve a prosthetically acceptable placement of dental implants in the anterior maxilla⁽²⁵⁾; augmentation with block grafts (cortical shell) at a distance from the alveolar ridge has received wide interest. Autografts possess uniqueness in osteogenic, osteoconductive, and osteo-inductive properties while also being immunogenically stable.^(3,26–28) However, they also carry the disadvantages of necessitating a donor site along with associated complications, and need for general anesthesia and hospitalization, all of which come at a higher financial cost.^(29,30) Intraoral grafts overcame some of these problems due to the close proximity of donor to recipient sites, convenient surgical access, and reduced morbidity at a lower cost.^(6,7,29–33) In agreement with previous reports mandibular autografts possessed structural integrity and mechanical support.⁽⁸⁾ The reported micro-saw and surgical discs used in the current study, allowed for smooth clean cuts with minimal bone loss at the osteotomy sites. All osteotomies were carried out with the micro-saw and disc unlike, the reported use of the 1mm drill at the occlusal crestal osteotomy.⁽³⁴⁾

In the current study patients were selected with anterior maxillary residual horizontal alveolar width ≤ 5 mm with sufficient alveolar height according to Cawood and Howell classification, class IV. Our patients possessed a mean of 3mm (STD 0.47) of crestal bone width; which is close to those selected in von Arx and Bruser's study in 2006⁽²⁾ where the mean residual alveolar ridge was 3.06mm. In their study the mean width increased to a mean of 8.02mm (range 6–10mm), compared to the current study in which the crestal gain in bone width was 4.2mm – 7.15mm with (mean 6.09mm; STD 0.86) at 4 months post-operatively. All our cases accommodated a dental implant without further grafting; unlike their

study in which two sites required minor re-grafting upon implant placement. Gulinelli et al 2017⁽³⁵⁾ in a more recent and closely designed long term study reported mean alveolar ridge width crestally: 3.8 to 7 to 6.5mm (preoperative to 6 months to 5years postoperative); compared to our presently reported preoperative mean crestal bone width of 3 to 6.48 to 6.09mm (preoperative to immediate to 5months postoperative) with statistically significant bone gain upon implant placement. Despite the difference in follow-up periods between the two studies, yet, there was resorption in the grafts between immediate and 5months postoperative in the current study; and 6 months versus 5 years postoperative in their study. The current study addressed the recommendations made by Gulinelli et al, advising analysis immediately after bone reconstruction. Larger sample size studies and even longer implant survival rates should be conducted.

The second stage surgery for addressing the graft and placing the implant was reported to be with an average of 5 months^(36–38), 5.8months (minimum 4.5 months)⁽²⁾, 4-6 months⁽³⁸⁾, and 6 months^(35,39). However, here within we are reporting placement of dental implants at the grafted sites only 4months post-grafting, with no need for even minor re-grafting as reported by others.⁽²⁾ Similar to previous reports the re-entry involved removal of the graft fixation screws with no consequences, despite being removed only 4 months post-grafting.^(35–38)

The rationale of recipient site preparation remains to be providing adequate vascularity for the graft at the recipient bed and more homogenous osseointegration with the native bone through access for trabecular bone blood vessels to the graft and accelerates revascularization.⁽³⁷⁾ While some advocated decortication⁽³⁵⁾, others perforated the bone with 0.8 mm round bur to penetrate underlying marrow.^(2,37) In the current study, micro-screw drill was used to create such perforations in bone, as decortication in such cases that are already lacking bone volume, seemed inappropriate. Moreover, post-operative CBCT analysis revealed acceptable

homogeneity of bone at 4 months postoperatively, denoting that drilling of the recipient site was enough. In all presented cases, the labial cortical shells were fixed using 2 titanium micro-screws to prevent micro-rotation of the graft, which can result in compromised healing, similar to that reported by Singh et al⁽³⁷⁾, as well as others utilizing titanium screws.^(2,35,38,40) Removal of the screws after 4 months for implant placement was a smooth procedure with no complications to be reported.

Healing following the presented grafting technique, was reported to be both of minimal occurrence and consequences: in terms of superficial epithelial sloughing, re-epithelialization within two weeks⁽³⁶⁾, wound dehiscence^(38,40), membrane exposures, and hematoma⁽²⁾. In the current study only one case experienced graft exposure, that was treated with proper assignment of oral hygiene measures and was trimmed off under copious saline irrigations, then left to heal by secondary intention, similar to other reports without the need for re-suturing.^(38,40) While membrane exposures and wound dehiscence were attributed to tension at wound margins⁽²⁾, we tend to disagree and rather attribute it to the orbicularis oris activity and extent of postoperative edema; as all surgeries were done by the same surgeon, and scoring of the under surface of the flap was carried out for all patients in the same manner to ensure tension free suturing.

Both symphyseal and retro-molar intraoral donor graft sites are excellent sites for harvesting strong cortices with adequate thickness with minimal morbidity. In the current study the retro-molar grafts were more perceivable by the patients in terms of pain and swelling compared to symphyseal grafts. It is fair to agree with the fact that although the ramus area has some advantages over the mandibular symphysis as a donor site. These include minimal patient concern for altered facial contour, lower incidence of incision dehiscence, decreased complaints of postoperative sensory disturbance but surgical access in some patients is more difficult, and there are limitations to the size and shape of the

graft. The symphysis offers the potential for thicker grafts with an increased cancellous component.⁽¹²⁾

Autografts being the gold standard of grafting techniques, necessitate refinements of techniques such as the use of surgical discs and saws, for minimizing or even eradicating donor site morbidity and postoperative discomfort and pain for the patients. Further studies with wider samples and unified technique as well as, long term follow-up following implant loading are necessary to achieve more standardized and improved results.

REFERENCES

1. Pietrokovski J, Massler M. Alveolar ridge resorption following tooth extraction. *J Prosthet Dent.* 1967 Jan; 17(1):21–7.
2. von Arx T, Buser D. Horizontal ridge augmentation using autogenous block grafts and the guided bone regeneration technique with collagen membranes: a clinical study with 42 patients. *Clin Oral Implants Res.* 2006 Aug; 17(4): 359–66.
3. Finkemeier CG. Bone-grafting and bone-graft substitutes. *J Bone Joint Surg Am.* 2002 Mar;84-A(3):454–64.
4. Kao ST, Scott DD. A review of bone substitutes. *Oral Maxillofac Surg Clin North Am.* 2007 Nov;19(4): 513–21, vi.
5. Cawood JI, Howell RA. A classification of the edentulous jaws. *Int J Oral Maxillofac Surg.* 1988 Aug;17(4):232–6.
6. Albrektsson T. The healing of autologous bone grafts after varying degrees of surgical trauma. A microscopic and histochemical study in the rabbit. *J Bone Joint Surg Br.* 1980 Aug;62(3):403–10.
7. Burchardt H, Busbee GA 3rd, Enneking WF. Repair of experimental autologous grafts of cortical bone. *J Bone Joint Surg Am.* 1975 Sep;57(6):814–9.
8. Roberts TT, Rosenbaum AJ. Bone grafts, bone substitutes and orthobiologics: the bridge between basic science and clinical advancements in fracture healing. *Organogenesis.* 2012;8(4):114–24.
9. Buser D, Brägger U, Lang NP, Nyman S. Regeneration and enlargement of jaw bone using guided tissue regeneration. *Clin Oral Implants Res.* 1990 Dec;1(1):22–32.

10. Feuille F, Knapp CI, Brunsvold MA, Mellonig JT. Clinical and histologic evaluation of bone-replacement grafts in the treatment of localized alveolar ridge defects. Part 1: Mineralized freeze-dried bone allograft. *Int J Periodontics Restorative Dent.* 2003 Feb;23(1):29–35.
11. Pikos MA. Block autografts for localized ridge augmentation: Part II. The posterior mandible. *Implant Dent.* 2000;9(1):67–75.
12. Pikos MA. Mandibular block autografts for alveolar ridge augmentation. *Atlas Oral Maxillofac Surg Clin North Am.* 2005 Sep;13(2):91–107.
13. Moghadam HG. Vertical and horizontal bone augmentation with the intraoral autogenous J-graft. *Implant Dent.* 2009 Jun;18(3):230–8.
14. Louis PJ. Vertical ridge augmentation using titanium mesh. *Oral Maxillofac Surg Clin North Am.* 2010 Aug;22(3):353–68, v.
15. Khoury F, Hanser T. Three-Dimensional Vertical Alveolar Ridge Augmentation in the Posterior Maxilla: A 10-year Clinical Study. *Int J Oral Maxillofac Implants.* 2019;34(2):471–80.
16. Emerson RHJ. Basic science of onlay allografts: a review. *Instr Course Lect.* 2000;49:97–102.
17. Enneking WF, Eady JL, Burchardt H. Autogenous cortical bone grafts in the reconstruction of segmental skeletal defects. *J Bone Joint Surg Am.* 1980 Oct;62(7):1039–58.
18. Burchardt H. The biology of bone graft repair. *Clin Orthop Relat Res.* 1983 Apr;(174):28–42.
19. Arnheiter C, Scarfe WC, Farman AG. Trends in maxillofacial cone-beam computed tomography usage. *Oral Radiol [Internet].* 2006;22(2):80–5. Available from: <https://doi.org/10.1007/s11282-006-0055-6>
20. Nickenig H-J, Eitner S. Reliability of implant placement after virtual planning of implant positions using cone beam CT data and surgical (guide) templates. *J Craniomaxillofac Surg.* 2007;35(4–5):207–11.
21. Economopoulos TL, Asvestas PA, Matsopoulos GK, Molnar B, Windisch P. Volumetric difference evaluation of registered three-dimensional pre-operative and post-operative CT dental data. *Dentomaxillofac Radiol.* 2012 May;41(4):328–39.
22. Maes F, Collignon A, Vandermeulen D, Marchal G, Suetens P. Multimodality image registration by maximization of mutual information. *IEEE Trans Med Imaging.* 1997 Apr;16(2):187–98.
23. Lofthag-Hansen S, Grondahl K, Ekestubbe A. Cone-beam CT for preoperative implant planning in the posterior mandible: visibility of anatomic landmarks. *Clin Implant Dent Relat Res.* 2009 Sep;11(3):246–55.
24. Misch CE. *Contemporary Implant Dentistry.* 3rd ed. St. Louis: Mosby; 2007. 1120 p.
25. Kumar H, Verma M, Kaur Lamba A, Faraz F, Rahul ,, Chawla K. Restoration of Maxillary Anterior Defect using Autogenous Block Graft and Optimizing the Esthetics using Zirconia Restoration. *Int J Oral Implantol Clin Res.* 2011;2:165–70.
26. McAllister BS, Haghighat K. Bone augmentation techniques. *J Periodontol.* 2007 Mar;78(3):377–96.
27. Marx RE. Bone and Bone Graft Healing. *Oral Maxillofac Surg Clin North Am.* 2007 Nov;19(4):455–66.
28. Jensen SS, Terheyden H. Bone augmentation procedures in localized defects in the alveolar ridge: clinical results with different bone grafts and bone-substitute materials. *Int J Oral Maxillofac Implants.* 2009;24 Suppl:218–36.
29. Arrington ED, Smith WJ, Chambers HG, Bucknell AL, Davino NA. Complications of iliac crest bone graft harvesting. *Clin Orthop Relat Res.* 1996 Aug;(329):300–9.
30. Silber JS, Anderson DG, Daffner SD, Brislin BT, Leland JM, Hilibrand AS, et al. Donor site morbidity after anterior iliac crest bone harvest for single-level anterior cervical discectomy and fusion. *Spine (Phila Pa 1976).* 2003 Jan;28(2):134–9.
31. Kahnberg KE, Nystrom E, Bartholdsson L. Combined use of bone grafts and Branemark fixtures in the treatment of severely resorbed maxillae. *Int J Oral Maxillofac Implants.* 1989;4(4):297–304.
32. Misch CM. Comparison of intraoral donor sites for onlay grafting prior to implant placement. *Int J Oral Maxillofac Implants.* 1997;12(6):767–76.
33. Simion M, Jovanovic SA, Tinti C, Benfenati SP. Long-term evaluation of osseointegrated implants inserted at the time or after vertical ridge augmentation. A retrospective study on 123 implants with 1-5 year follow-up. *Clin Oral Implants Res.* 2001 Feb;12(1):35–45.
34. Khoury F, Hanser DMDT. Mandibular Bone Block Harvesting from the Retromolar Region : A 10-Year Prospective Clinical Study. 2015;30(3):6–9.

35. Gulinelli JL, Dutra RA, Mara HF, Simea SFP. Maxilla reconstruction with autogenous bone block grafts : computed tomography evaluation and implant survival in a 5-year retrospective study. 2017;1045–51.
36. Stimmelmayer M, Gu J. Use of a modified shell technique for three-dimensional bone grafting : description of a technique. 2012;93–7.
37. Singh A, Gupta A, Yadav A, Chaturvedi TP. Reconstruction of localized maxillary ridge defect with autogenous mandibular ramus block bone graft for dental implant placement. 2013;3(1):2013–6.
38. Yu H, Chen L, Zhu Y, Qiu L. Bilamina cortical tenting grafting technique for three-dimensional reconstruction of severely atrophic alveolar ridges in anterior maxillae: A 6-year prospective study. *J Cranio-Maxillofacial Surg.* 2016;44(7):868–75.
39. Deepika-Penmetsa S-L, Thomas R, Baron T-K, Shah R, Mehta D-S. Cortical lamina technique: A therapeutic approach for lateral ridge augmentation using guided bone regeneration. *J Clin Exp Dent.* 2017 Jan;9(1):e21–6.
40. Stimmelmayer M, Beuer F, Schlee M, Edelhoff D, Güth J. Vertical ridge augmentation using the modified shell technique – a case series. *Br J Oral Maxillofac Surg.* 2014;52(10):945–50.