

Online ISSN: 2682-2628
Print ISSN: 2682-261X

IJC CBR

INTERNATIONAL JOURNAL OF CANCER AND BIOMEDICAL RESEARCH

<https://jcbr.journals.ekb.eg>

Editor-in-chief

Prof. Mohamed Labib Salem, PhD

**Protective effects of coenzyme Q10 against
cisplatin-induced toxicity on testis in
experimental rats**

Huda Abd-Elhafiz¹, Noha Issa² and Eman Sweed



PUBLISHED BY

EACR EGYPTIAN ASSOCIATION
FOR CANCER RESEARCH

Since 2014

Protective effects of coenzyme Q10 against cisplatin-induced toxicity on testis in experimental rats

Huda Abd-Elhafiz¹, Noha Issa² and Eman Sweed¹

¹ Clinical Pharmacology Department, Faculty of Medicine, Menoufia University, Egypt

² Anatomy and Embryology Department, Faculty of Medicine, Menoufia University, Egypt

ABSTRACT

Background: Cisplatin is an anti-cancer drug that is associated with testicular toxicity because of its induction of excessive reactive oxygen species. Coenzyme Q10 (CoQ10) has been found to express antioxidant and anti-inflammatory effects. **Aim:** This study aims to investigate if CoQ10 can counter the testicular tissue toxicity caused by cisplatin. **Materials and Methods:** Animals were weighed and randomly divided into four groups (n = 10/each). In group I (control group), rats were received 1% of Tween-80 through intraperitoneal (i.p.) injection for 15 days. Group II (CoQ10 group) were i.p. treated for 15 days with CoQ10 in 1% tween-80 at a dosage of 10mg/kg/day for 15 days. Rats in group III (Cisplatin group) were i.p. treated with a single i.p. injection of cisplatin at a dosage of 7mg/kg on the 5th day of the experiment. Group IV (CoQ10/cisplatin) were i.p. treated with CoQ10 at a dosage of 10mg/kg/day for 15 days and cisplatin at a dosage of 7mg/kg on the 5th day of the experiment. Biochemical measurements as well as histological and immunohistochemical morphometric were done. **Results:** CoQ10 diminished cisplatin induced oxidative stress through reducing lipid peroxidation and nitric oxide levels and increasing the levels of antioxidant enzymes, including superoxide dismutase and glutathione dehydrogenase. Moreover, CoQ10 significantly decreased the inflammatory response to cisplatin administration by decreasing the proinflammatory mediator tumor necrosis factor- α and increasing the anti-inflammatory cytokine IL-10. Treatment with CoQ10 also induced significant improvement in histopathological changes in testes. **Conclusion:** CoQ10 could protect testes against cisplatin induced injury.

Keywords: Coenzyme Q10; Cisplatin; rat & testis

Editor-in-Chief: Prof. M.L. Salem, PhD - Article DOI: 10.21608/jcbr.2021.79891.1224

ARTICLE INFO

Article history

Received: August 6, 2021
Revised: September 28, 2021
Accepted: October 3, 2021

Correspondence to

Dr Eman Sweed, MD
Faculty of Medicine,
Menoufia University,
Shebin El-Kom,
Menoufia, Egypt
Tel.: 01066075637
Email:
eman.sweed@med.menofia.edu.eg

Copyright

© 2021 Huda Abd-Elhafiz, Noha Issa, Eman Sweed. This is an Open Access article distributed under the Creative Commons Attribution License, which permits unrestricted use, distribution, and reproduction in any medium, provided the original work is properly cited.

INTRODUCTION

Cisplatin is immensely used as a potent chemotherapeutic medication to treat numerous solid tumors, like ovarian, bladder, lymphoma, sarcoma and endometrial cancers, However, cisplatin has direct adverse effects on sperm production resulting in male infertility (Martenies & Perry, 2013). Infertility and its consequences are a major concern that distress the social life of partners (Ebisch et al., 2007).

Cisplatin causes DNA adduction (Colpi et al., 2004), which mediate its toxic side effects on the renal, nervous, inner ear, and testicular tissues, limiting its use (Fleischman et al., 1975). Its reproductive toxicity results in significant testicular injury due to the damage of zoogenic

cells during spermatogenesis which corresponds to sperm DNA detriment followed by testicular atrophy (Fung & Vaughn, 2011).

Although the exact cause of testicular toxicity has not been clearly identified, it may possibly be due to oxidative stress and overproduction of the reactive oxygen species (ROS), this oxidant/antioxidant imbalance is the cause of lipid and protein oxidation and DNA loss (Sherif et al., 2014). Catalase, superoxide dismutase (SOD), and reduced glutathione (GSH) are antioxidant enzyme defense systems that protect tissues from the damaging ROS that cause lipid peroxidation (Hassan & Alam, 2014). Moreover, ROS trigger the inflammation-inducing mediators as tumor necrosis factor- α (TNF- α), interleukin-1 β (IL-1 β), and reactive nitrogen

species (RNS), as nitric oxide (NO) which in turn, causes necrosis and apoptosis of the testicular cells (Hussein et al., 2015). As such, finding drugs or compound with potential anti-oxidant effects induced by cisplatin can overcome its limitation in clinical applications.

Coenzyme Q10 (CoQ10) is (2,3dimethoxy 5-methyl 6-decaprenyl1, 4benzoquinone, Co Q10) that acts on electron and proton transport in the respiratory cycle of mitochondria. This makes CoQ10 to express antioxidant effect by enhancing the transmission of protons and electrons to bind with the molecular O₂ whereas to form water, avoiding formation of ROS and lipoperoxides that mediate damage of different tissues (Jung et al., 2009).

Given these anti-oxidant effects of Co-Q10, the goal of this study was to test whether its supplementation could protect testes from cisplatin effect in experimental rats. The antioxidant, and anti-inflammatory activities of CoQ10 will be investigated in this study.

MATERIAL AND METHODS

Animals

A total of forty adult males Sprague–Dawley rats weighing 150–200 g were acclimatized for 5 days before initiating the experiments under ordinary laboratory condition of 12 h light/dark rotations at (25±2°C) and free access to food and water. All animals received proper care in accordance with the Public Health Service Policy that use of Laboratory Animals published by the National Institutes of Health. The study was approved by the Ethical Committee of the College of Medicine, Menoufia University, Egypt with Ethical approval number 191119ANAT15.

Chemicals

Cisplatin and CoQ10 (Sigma–Aldrich); Phosphate buffer and Tween 80 (Biodiagnostic CO, Cairo, Egypt).

Induction testicular toxicity by cisplatin

Animals were weighed and randomly allocated into four groups (n = 10/each). In group I (control group), the rats received 1% of Tween-80 through intraperitoneal (i.p.) injection for 15 days. Group II (CoQ10 group) were i.p. treated for 15 days with CoQ10 in 1% tween-80 at a dosage of 10mg/kg/day for 15 days. Rats in

group III (Cisplatin group) were i.p. treated with a single i.p. injection of cisplatin at a dosage of 7mg/kg on the 5th day of the experiment. Group IV (CoQ10/cisplatin) were i.p. treated with CoQ10 at a dosage of 10mg/kg/day for 15 days and cisplatin at a dosage of 7mg/kg on the 5th day of the experiment. All rats were sacrificed then immediately the epididymal content of each rat was collected by cutting the epididymis' tail and gently squeezing it to obtain fresh semen for sperm examination. The testes were gently removed and washed in saline then weighed and the testicular dimensions were recorded. Venous blood samples from the retro-orbital plexus were obtained in heparinized capillary tubes, centrifuged at 500×g for 20 minutes at 4°C for serum separation. The serum was then preserved at –80°C. Testosterone level was measured by ELISA kits (Biodiagnostic Co., Cairo, Egypt) and the results were expressed in (ng/dl). Rat ELISA kits were used to measure the serum levels of tumor necrosis factor alpha (TNF-α) and interleukin-10 (IL-10) (Biospes Co., Ltd, Chongqing, China), the results were expressed in Pg/dl. Testis of each rat was dissected out, soaked by phosphate buffer saline with (PH 7.4). The surrounding tissues were removed, weighed, and used for biochemical studies or kept at -80 °C.

To prepare testes homogenate were, 100 mg of each testicular tissues was homogenized using a glass tissue homogenizer in (0.1 mol/l, pH 7.4), phosphate buffers then centrifuged at 1500×g for 10 min and then at 10,000×g for 15 min. The supernatant was collected to measure lipid peroxidation malondialdehyde (MDA), SOD, and reduced GSH spectrophotometrically using available commercial kits (Biodiagnostic Co., Cairo, Egypt). the results were expressed in units/mg protein. NO levels in testicular tissue homogenate were measured using available commercial kits (Biodiagnostic Co., Cairo, Egypt) and the results were expressed in nmol/100 mg tissue.

The left testis samples were fixed in Bouin's solution and processed into 5µm – thick paraffin sections for histopathology by hematoxylin and eosin (H&E) stain and for histochemistry assessment by Periodic acid Schiff's stain.

Ki-67 and BAX immunohistochemical staining

Poly-L-lysine coated slides were deparaffinized and rehydrated, and then immersed in 3% hydrogen peroxide to block the endogenous peroxidase. Microwave antigen retrieval procedure was used. The slides were then incubated with primary rabbit polyclonal anti Ki67 antibodies (ab833) and anti Bax antibodies (ab53154). Both antibodies were bought from (Abcam Co., Cambridge, UK).

Statistical analysis

The collected data of the testes weight, sperm and dimensions parameters were recorded and tabulated. Testosterone, MDA, SOD, GSH, NO, TNF- α and IL-10 levels were recorded and tabulated. The morphometric data from the histological study were recorded and tabulated. All findings were analyzed using one-way analysis of variance (ANOVA) and the Bonferroni post hoc test and expressed as mean \pm standard deviation of mean (SD). Graph Pad Prism 4.03 was used to analyze the data statistically (Graph Pad Software, San Diego, California, USA). Statistical significance was defined as a value of $p < 0.05$.

RESULTS

CoQ10 ameliorates cisplatin-induced alterations in histopathology

There were non-significant differences on comparing the CoQ10 group with control group and cisplatin treated group by CoQ10 with control group regarding all results. Testis weight in the cisplatin group revealed significant decrease ($P < 0.05$) as compared to the control group. In contrast to cisplatin rats, rats treated with both cisplatin and CoQ10 revealed significant increase ($P < 0.05$) in the testes weight (Table 1).

The testis length and thickness in the cisplatin group was significantly decreased ($P < 0.05$) more than in the control group. Rats treated with cisplatin and CoQ10 revealed significant increase ($P < 0.05$) in the testis length (Table 1). Cisplatin group revealed significant decrease ($P < 0.05$) in sperm count, motility and viability when compared with control group. These parameters, however, were significantly increased ($P < 0.05$) in rats treated with cisplatin

and CoQ10 in comparison to the cisplatin group (Table 2).

For testosterone level, cisplatin group revealed significant decreases ($P < 0.05$) in the serum level of this hormone as compared to control normal rats. Rats treated with cisplatin and CoQ10 showed significant higher testosterone level ($P < 0.05$) than cisplatin treated rats (Table 3).

CoQ10 ameliorates cisplatin-induced alterations in cytokines

For tumor necrosis factor- α (TNF- α), we found that Cisplatin group, when as compared to control normal rats, revealed significant decrease in the serum level of this cytokine. CoQ10 in combination with cisplatin reduced TNF- α level ($P < 0.05$) when used to treat the cisplatin group in comparison to the group treated with cisplatin alone (Table 3). For interleukin-10 (IL-10), cisplatin group revealed significant decrease in IL-10 in contrast to the normal group. Also, CoQ10 in combination with cisplatin caused a significant increase in IL-10 level ($P < 0.05$) in comparison with the cisplatin group only (Table 3).

CoQ10 lowers cisplatin-induced oxidation by inducing high anti-oxidant effects

Nitric oxide (NO) in testes homogenate, was significantly increased ($P < 0.05$) in the cisplatin treated group in contrast to control group. Similarly, the CoQ10-treated cisplatin group had a significantly lower NO level ($P < 0.05$) than the cisplatin group (Table 4). Malondialdehyde (MDA) level in testes tissue homogenate, was significantly increased ($P < 0.05$) in the cisplatin treated group in contrast to control group. Also, MDA levels were significantly decreased ($P < 0.05$) in the cisplatin treated by CoQ10 group in contrast to the cisplatin group. (Table 4). Superoxide dismutase (SOD) in testes homogenate, was significantly decreased ($P < 0.05$) in the cisplatin treated group in contrast to control group. Also, the CoQ10-treated cisplatin group had a significantly higher SOD level ($P < 0.05$) than the cisplatin group (Table 4). Reduced glutathione (GSH) in testes homogenate was significantly lower ($P < 0.05$) in cisplatin treated rats than in the control group. Treatment with cisplatin followed by treatment with CoQ10 resulted in higher GSH level

($P < 0.05$) than in rats treated with cisplatin alone (Table 4).

CoQ10 ameliorated cisplatin-induced histological and morphometric changes in testes

In sections from testis of control group, the seminiferous tubules showed normal histological appearance of spermatogonia and Sertoli cells resting on intact basement membrane. The large rounded primary spermatocytes with rounded nuclei and the spermatids were observed. Moreover, the sperms filled the seminiferous tubules lumen. The interstitial tissue is separating the seminiferous tubules containing the Leydig cells with rounded vesicular nuclei and the supplying blood vessels (Figure 1). In the testis of cisplatin group, there were sloughed germinal epithelium in the lumina of some seminiferous tubules; the basement membranes appeared thick and hyalinized. Most of spermatogenic cells had pyknotic nuclei and the sperms were undergone the hyaline degeneration. The interstitial connective tissue revealed hyaline material and dilated congested blood vessels. Some seminiferous tubules were devoid of sperms (Figure 2). Interestingly, the testis of rats treated with CoQ10, and cisplatin showed preservation of normal histological appearance except for slight nuclear pyknosis of some spermatogenic cells in some seminiferous tubules (Figure 3).

CoQ10 ameliorated cisplatin-induced histochemical changes in testes

The testis section from control rats showed intensely positive PAS reactivity in the basement membrane and the spermatogenic lining of seminiferous tubules (Fig. 4A, D). As compared to the control group, treatment of the rats with cisplatin led to significant decrease in the surface area percentage of PAS reaction in the basement membrane and the lining spermatogenic cells of the seminiferous tubules (Fig. 4B, D). Treatment with Q10 coenzyme following cisplatin treatment led to significant increases in the % surface area of PAS reaction in the basement membrane and the lining spermatogenic cells of the seminiferous tubules as compared to the cisplatin group, indicating to better spermatogenesis (Figure 4C, D).

The testis section of control group showed the normal distribution of collagen fibers in the tunica albuginea stained by Masson's trichrome stain (Figure 5A, D). While that of cisplatin group showed significant increase in the surface area percentage of Masson's trichrome stain as compared to control group, denoting excessive deposition of collagen fibers in the tunica albuginea, the wall of blood vessels and the basement membrane of seminiferous tubules (Figure 5B, D). Rats treated with Q10 coenzyme and cisplatin showed significant decrease of the surface area percentage of Masson's trichrome stain as compared to cisplatin group, denoting minimal deposition of collagen fibers in the tunica albuginea (Figure 5C, D).

CoQ10 ameliorated high expression of apoptotic markers induced by cisplatin in testes

The testis section of control group showed strong positive expression for Ki in the nuclei of spermatogenic cells (Figure 6A, D). While that of cisplatin group showed significant decrease of the number of Ki-immunopositively reacted cells as compared to control group (Figure 6B, D). Rats treated with both CoQ10, and cisplatin showed significant increase in the number of Ki-immunopositively reacted cells as compared to cisplatin group (Figure 6C, D). The testis section of control group showed weak BAX immunopositively expression in the cytoplasm of spermatogenic cells (Figure 7A, D). While that of cisplatin group showed significant increase in the percentage of BAX-immunopositively reacted surface area as compared to control group (Figure 7B, D). However, treatment with CoQ10 after cisplatin induced significant decrease of the percentage of BAX-immunopositively reacted surface area as compared to cisplatin group (Figure 7C, D).

DISCUSSION

Oxidative stress causes exhaustion of the anti-oxidants enzymes, which are crucial for the well-being of cells, tissues and the whole organs functionality. In the present study, exposure of the testicular tissues to oxidative stress performed by cisplatin administration revealed significant decreases in their weight and alteration in the epididymal sperm parameters, including sperm total, motility and viability as compared to control group.

Table 1. Coenzyme 10 effects on the testicular weights and testicular dimensions at the end of the experiment of Cisplatin induced testicular toxicity.

Parameters	Control Group	Coenzyme 10 Group	Cisplatin Group	Protected Group
Testis weights at the end of experiments (gm) P- Value	1.68±0.18	1.58±0.23 P1= 0.297	0.68±0.17 P2 <0.001	1.38±0.28 P3 <0.001
Testes length (cm) P- Value	1.58±0.103	1.57±0.082 P1=0.501	1.15±0.14 P2<0.001	1.450±0.085 P3<0.001
Testes thickness (cm) P- Value	0.670±0.067	0.640±0.055 P1=0.471	0.410±0.081 P2<0.001	0.520±0.063 P3<0.001

Foot note: P1 > 0.05 on comparing coenzyme Q10 (G2) to control group (G1), P2 < 0.05 on comparing cisplatin group (G3) to control group (G1) and P3 <0.05 on comparing protected group (G4) to cisplatin group (G3).

Table 2. Coenzyme 10 effects on the sperm count, motility % and viability % at the end of the experiment of Cisplatin induced testicular toxicity.

Parameters	Control Group	Coenzyme 10 Group	Cisplatin Group	Protected Group
Sperm count million/ml P- Value	75.00±2.26	76.00±2.00 P1= 0.297	38.00±3.46 P2 <0.001	69.00±2.58 P3 <0.001
Sperm motility % P- Value	86.00±2.58	88.00±2.58 P1=0.501	47.00±2.58 P2<0.001	74.00±2.58 P3<0.001
Testes thickness (cm) P- Value	94.00±2.58	96.00±2.58 P1=0.471	52.00±2.58 P2<0.001	86.00±2.58 P3<0.001

Foot note: P1 > 0.05 on comparing coenzyme Q10 (G2) to control group (G1), P2 < 0.05 on comparing cisplatin group (G3) to control group (G1) and P3 <0.05 on comparing protected group (G4) to cisplatin group (G3).

Table 3. Coenzyme 10 effect on the serum Testosterone, Tumor necrosis factor –α (TNF-α) and Interlukin-10 (IL-10) levels in the cisplatin induced testicular toxicity in rats.

Parameters	Control Group	Coenzyme 10 Group	Cisplatin Group	Protected Group
Testosterone (ng/dl) P- Value	118.7±1.35	118.7±1.12 P1=1.00	37.65±2.14 P2 <0.001	79.55±2.71 P3 <0.001
TNF-alpha (Pg/dl) P- Value	34.27±1.84	32.34±2.50 P1=0.158	120.58±2.60 P2 <0.001	47.10±2.30 P3 <0.001
IL-10 (Pg/dl) P- Value	51.08±1.58	51.29±1.82 P1=0.805	13.68±1.67 P2 <0.001	37.47±2.35 P3 <0.001

Foot note: P1 > 0.05 on comparing coenzyme Q10 (G2) to control group (G1), P2 < 0.05 on comparing cisplatin group (G3) to control group (G1) and P3 <0.05 on comparing protected group (G4) to cisplatin group (G3).

Table 4. Coenzyme 10 effect on the lipid peroxidation (malondialdehyde MDA), Superoxide dismutase (SOD), Glutathione dehydrogenase (GSH) and nitric oxide (NO) in the tissue homogenates of cisplatin induced testicular toxicity in rats.

Parameters	Control Group	Coenzyme 10 Group	Cisplatin Group	Protected Group
MDA (nmol/g tissue) P- Value	24.98±0.99	26.05±1.67 P1=0.187	78.92±1.60 P2 <0.001	33.43±2.52 P3 <0.001
SOD (U/g tissue) P- Value	80.85±2.12	82.94±3.26 P1=0.065	35.52±1.27 P2 <0.001	68.51±2.75 P3 <0.001
GSH (mg/g tissue) P- Value	97.24±2.05	102.81±2.93 P1<0.001	41.04±1.94 P2 <0.001	82.48±2.98 P3 <0.001
NO (nmol/100 mg tissue) P- Value	41.75±1.24	37.67±1.67 P1<0.001	133.35±1.95 P2 <0.001	60.91±2.59 P3 <0.001

Foot note: P1 > 0.05 on comparing coenzyme Q10 (G2) to control group (G1), P2 < 0.05 on comparing cisplatin group (G3) to control group (G1) and P3 <0.05 on comparing protected group (G4) to cisplatin group (G3).

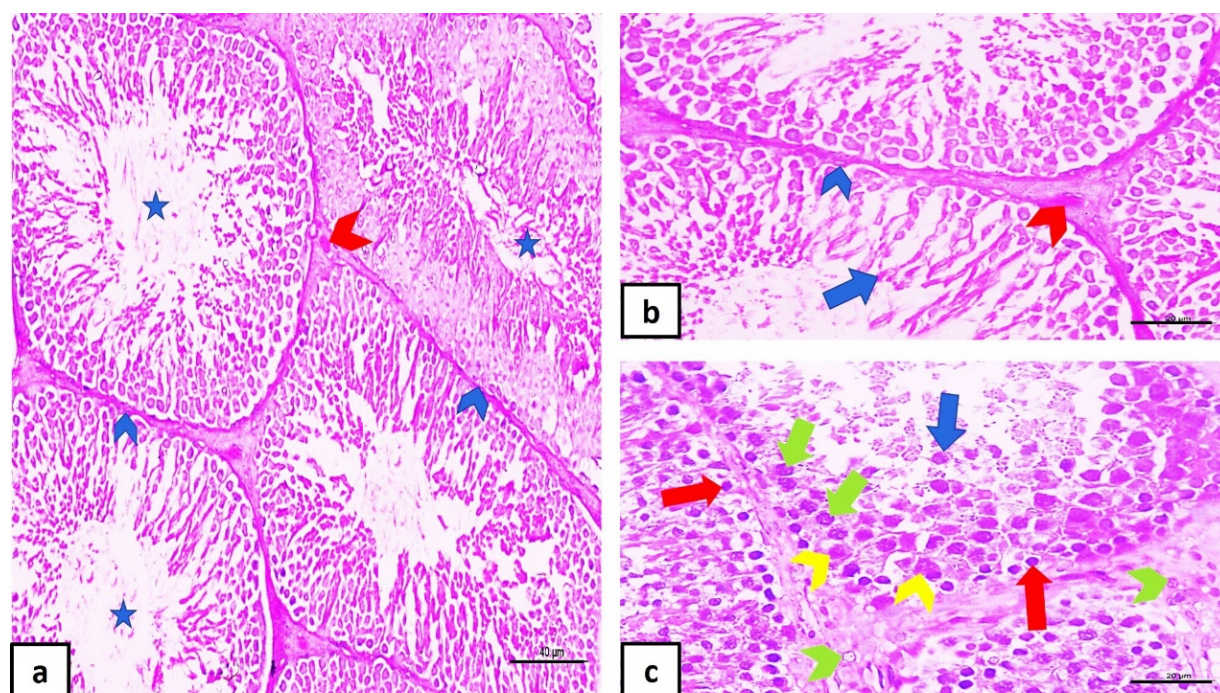


Figure 1. H.&E.-stained testis sections of control rat, the testis is showing the spermatogonia (red arrow) together with Sertoli cells (yellow arrowhead) resting on intact basement membrane (blue arrowhead) seminiferous tubules which separated from each other by the interstitial tissue containing the Leydig cells (green arrowhead) and blood vessels (red arrowhead). The primary spermatocytes (green arrow), the spermatids (blue arrow) and sperm (blue star) are observed in the seminiferous tubules. (hematoxylin and eosin, a (x200, scale bar = 40 μ m), b & c (x400, scale bar = 20 μ m))




Figure 2. H.&E.-stained testis sections of rat treated with cisplatin, the testis is showing hyalinization of basement membrane (blue arrowhead), interstitial tissue (green star) and sperm (blue star). Also, the blood vessels (red arrowhead) are dilated and congested. Moreover, other sections revealing sloughed germinal epithelium (red star), pyknotic nuclei of spermatogenic cells (yellow star) and absence of sperm (black star). (hematoxylin and eosin, a, c (x200, scale bar = 40 μ m), b & d (x400, scale bar = 20 μ m))

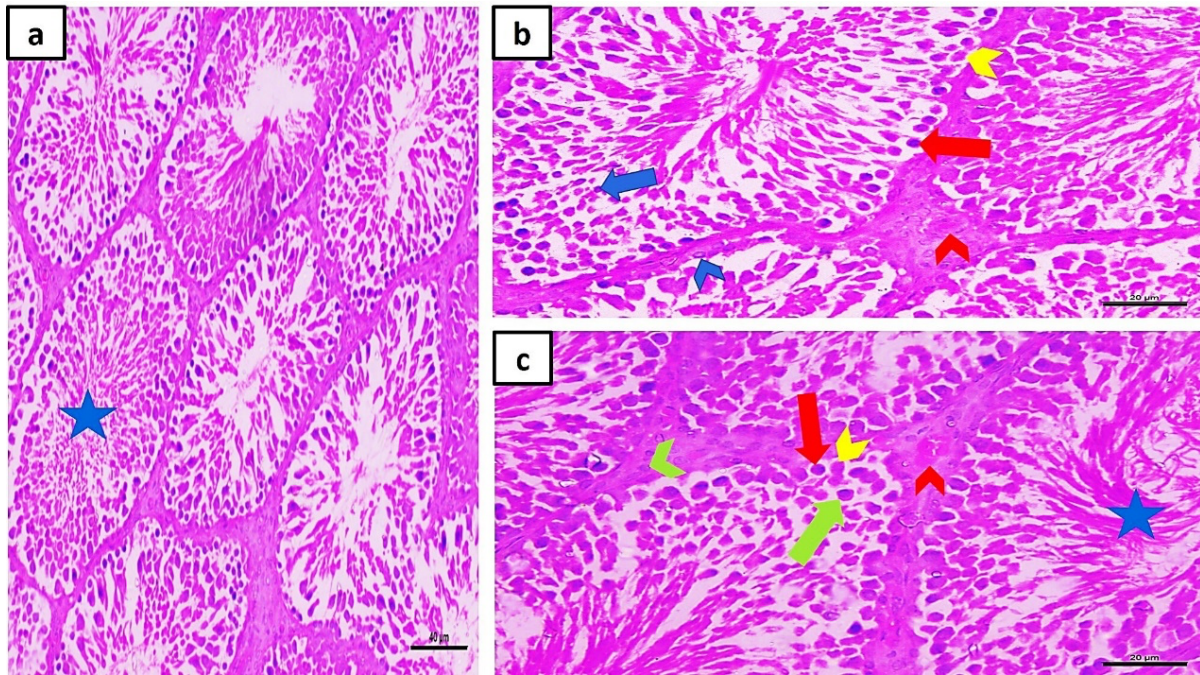


Figure 3. H.&E.-stained testis sections of rat treated with Q10 and cisplatin, the testis is showing intact basement membrane (blue arrowhead) of seminiferous tubules separated by normal interstitial blood vessels (red arrowhead) and cells (green arrowhead). The nuclei of some spermatogonia (red arrow), Sertoli cells (yellow arrowhead), primary spermatocytes (green arrow) and spermatids (blue arrow) show slight pyknosis. The sperms (blue star) are filling the lumen of most seminiferous tubules. (hematoxylin and eosin, a (x200, scale bar = 40 μ m), b & c (x400, scale bar = 20 μ m))

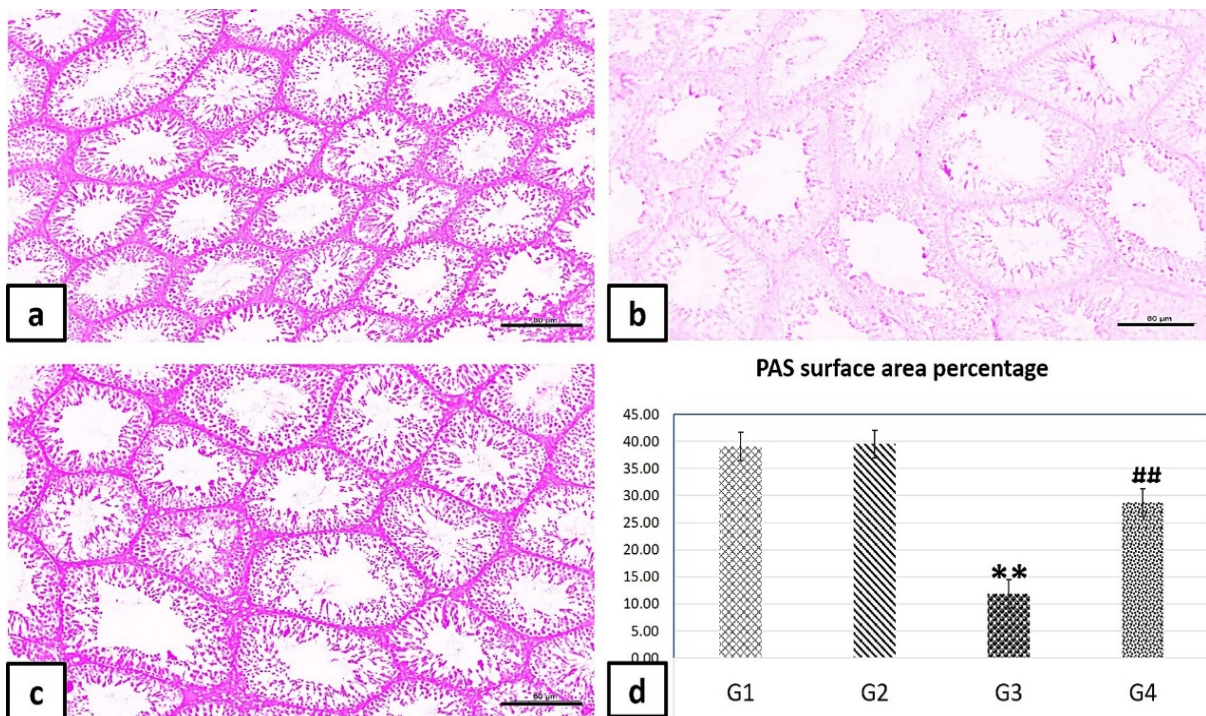


Figure 4. a) PAS -stained testis sections of experimental groups, b) Significant decrease (**p value < 0.001) in surface area percentage of PAS reaction of cisplatin group (G3) compared to the control group (G1). c) Significant increase (##p value < 0.001) in surface area percentage of PAS reaction of Q10 coenzyme cisplatin group (G4) as compared to cisplatin group (G3). d) Statistical representation of all experimental groups. (PAS, x100, scale bar = 80 μ m)

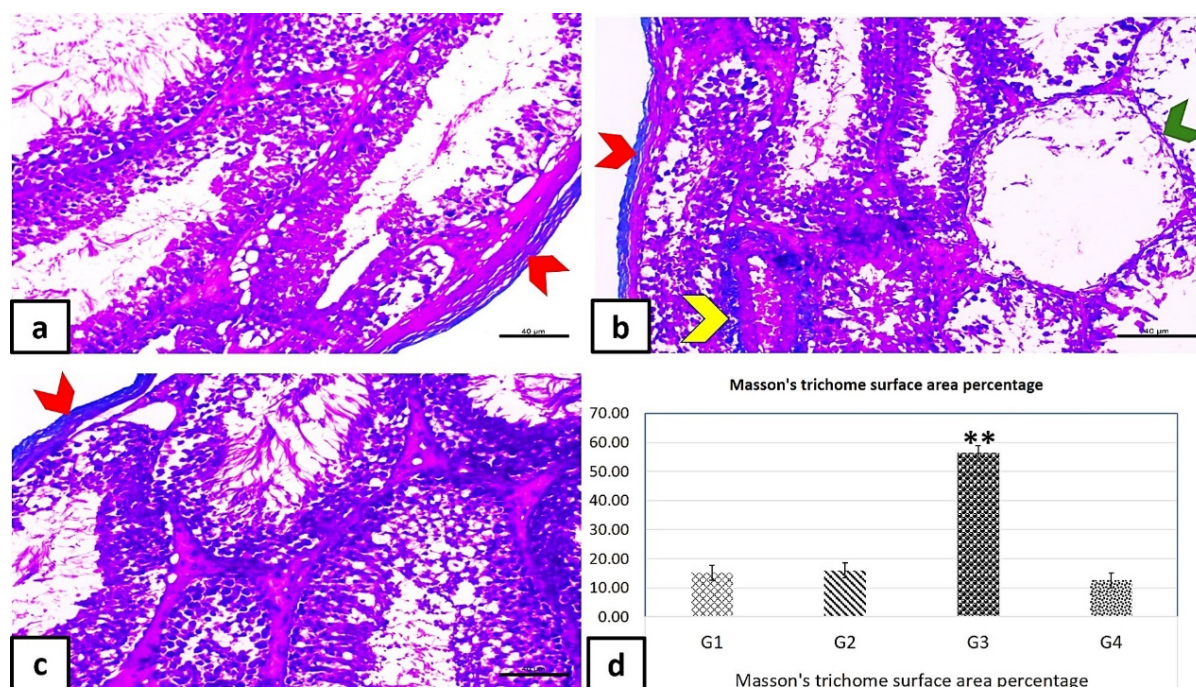


Figure 5. a) Masson's trichrome-stained testis sections of experimental groups, b) Significant increase (**p value < 0.001) in the surface area percentage of Masson's trichrome stain in tunica albuginea (red arrowhead), wall of blood vessels (yellow arrowhead) and basement membrane (green arrowhead) of cisplatin group (G3) as compared to control group (G1). c) Significant decrease (##p value < 0.001) in the surface area percentage of Masson's trichrome stain in Q10 coenzyme cisplatin group (G4) as compared to cisplatin group (G3). d) Statistical representation of all experimental groups. (Masson's trichrome, x400, scale bar = 20 μm)

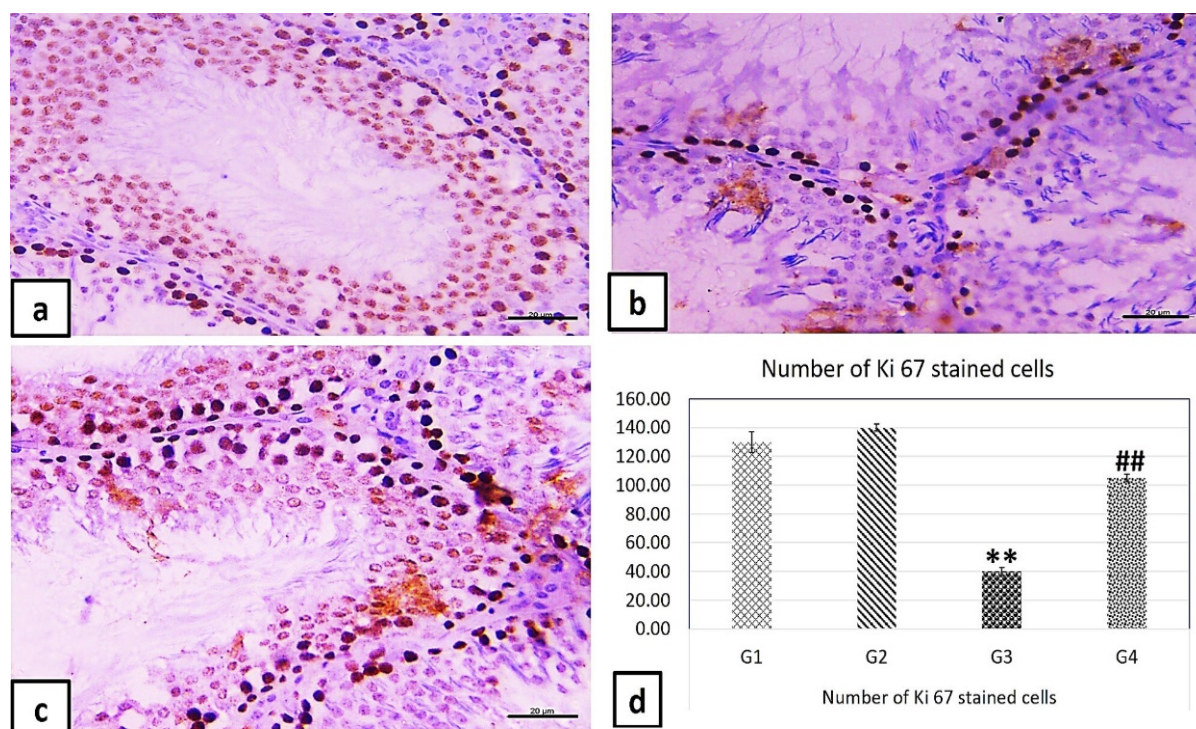


Figure 6. a) Ki-stained testis sections of experimental groups, b) Significant decrease (**p value < 0.001) in the number of Ki-stained cells in the testis section of cisplatin group (G3) compared to the control group (G1). c) Significant increase (##p value < 0.001) in the number of Ki-stained cells in the testis section of Q10 coenzyme cisplatin group (G4) as compared to cisplatin (G3). d) Statistical representation of all experimental groups. (Ki immunohistochemical stain, x400, scale bar = 20 μm)

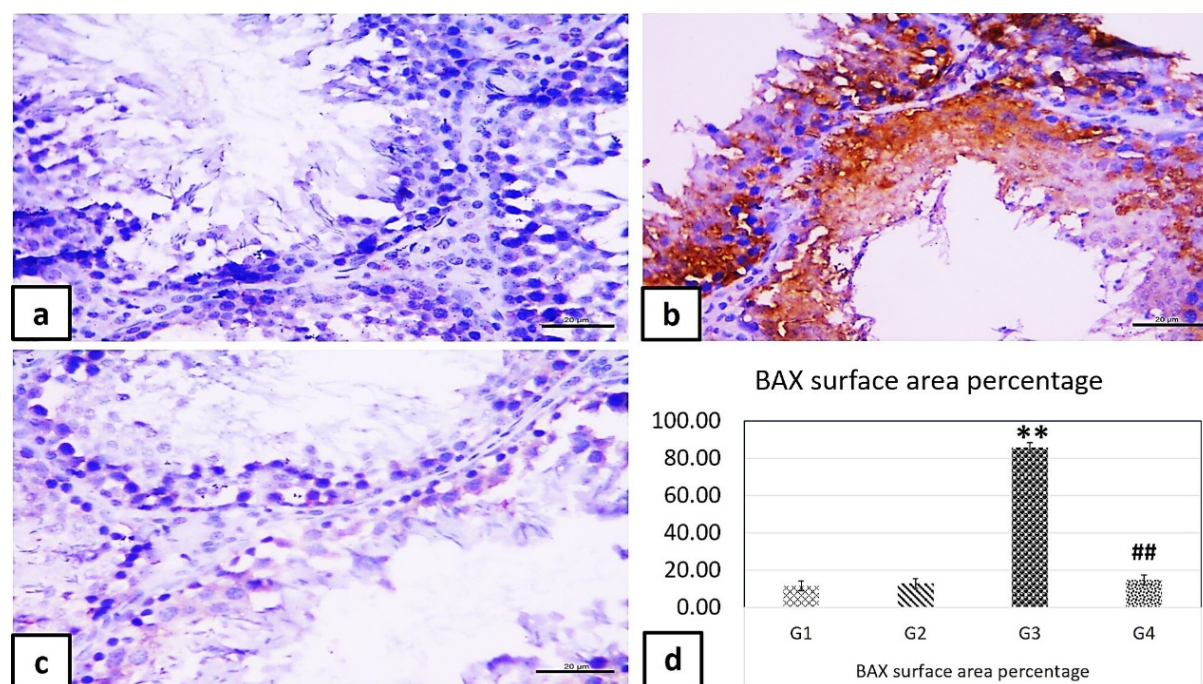


Figure 7. a) BAX -stained testis sections of experimental groups, b) Significant increase (**p value < 0.001) in the BAX-immunopositively stained surface area percentage in the testis section of cisplatin group (G3) as compared to control group (G1). c) Significant decrease (##p value < 0.001) in BAX- immunopositively stained surface area percentage in the testis section of Q10 coenzyme cisplatin group (G4) as compared to cisplatin (G3). d) Statistical representation of all experimental groups. (BAX immunohistochemical stain, x400, scale bar = 20 μ m).

These adverse effects of cisplatin could be attributed to its direct cytotoxic effect on the testes besides its general cytotoxic side effects (Ilbey et al., 2009). Once cisplatin entered the cell, its chloride groups are substituted with water molecules, these hydrophilic changes help this effective chemotherapeutic drug to be incorporated into the cellular macromolecules and nitrogen donor atoms on nucleic acids (Kartalou & Essigmann, 2001). The latter would hinder the maturation progression of the spermatogonia stem cells sequences, reducing spermatogenesis, and results in azoospermia (Zhang et al., 2001). This would explain the absence of luminal sperms in most of testes seminiferous tubules of cisplatin treated rats that showed significant degenerative changes such as hyaline degeneration of basement membrane and sloughing of germinal epithelium.

Administration of CoQ10 after cisplatin resulted in significant improvement in the testes weight, epididymal sperm parameters including sperm total, motility and viability compared to the cisplatin treated only. These findings are in line with previous studies (Türk et al., 2008) which

postulated that the testis weight is one of the excellent indicators of the testis toxicity induced by cisplatin. This toxicity was associated with extensive tubular atrophy induced by enormous construction of ROS performed by cisplatin administration (Azu et al., 2010). Indeed, we observed in the present study significant increases in collagen fibers deposition in the testes tissues from cisplatin treated rats when stained with Masson's trichrome as compared to control group, indicating to fibrosis to play critical role in testis dysfunction as reported previously (Hussein et al., 2020).

It has been reported that oxidative stress has direct disturbing properties on the testosterone release due to disrupting the hypothalamic-pituitary testicular axis (Adejuwon et al., 2015). This suggestion is in agreement with our histological results that included the hyalinization of the interstitial tissue together with vasodilatation and congestion of its blood vessels of cisplatin group which showed serum substantial decreases of testosterone level in comparison to the control group. That might be the reason of abnormal spermatogenesis process because testosterone is the basic

hormone responsible for development of the spermatogonia stem cells to mature sperm cells (Joensen et al., 2008), and as accordingly explain the significant decrease of the testicular weights and dimensions in cisplatin group. Cisplatin co-administrated with CoQ10 induced substantial increase in the testosterone level in comparison to cisplatin group that might be due to its antioxidant effects. These observations are in line with previous studies (Adelakun et al., 2018) that postulated that antioxidant compounds might significantly increase the testosterone serum level (Adelakun et al., 2018). This explains the nearly normal histological appearance of the testis from Q10 coenzyme cisplatin group.

Malondialdehyde, which is an indicator to lipid oxidation and causes overproduction of oxidative stress and free radicals, was significantly increased in the cisplatin treated rat. This was associated with depletion of the protective antioxidant enzymes such GSH and SOD, as both significantly decrease in the cisplatin group. This imbalance in oxidation/anti-oxidation axis would explain the damaged spermatogonia and the testicular dysfunction. This is supported by the significant decrease of the PAS reaction to the cytoplasmic (carbohydrate and its metabolites) in the cisplatin group testis in comparison to the control group, indicating to the structural and functional testicular impairment as reported previously (Razi et al., 2012).

Rats treated with CoQ10 and cisplatin showed significant decrease of MDA through significant increase in antioxidant enzymes as GSH and SOD, and both act as guards to the testicular cell by detoxification of chemically reactive species and free radicals produced by administration of cisplatin drug. Moreover, both antioxidant enzymes significantly increased in the group treated with CoQ10 and cisplatin as compared with cisplatin treated group. These results are in parallel with previous studies (Khalifa et al., 2020) which found that CoQ10 protects against lipid peroxidation by improving antioxidant enzyme activity. This explains the significant increase in the PAS reaction in the testis of Q10 coenzyme cisplatin group that were associated with preservation of the normal structure and function of the testis.

Extra production of nitric oxide interacts with superoxide anion to produce peroxynitrite radical which contributes to additional cell damage through oxidizing and nitrating cellular macromolecules; the extra nitric oxide also diminishes intracellular reduced GSH and thus escalates the vulnerability to oxidative stress (Clancy & Abramson, 1995). The current study revealed that the nitric oxide production was significantly increased in the cisplatin group as compared with the control group. That overproduction of nitric oxide might have a crucial role in the cisplatin-mediated cytotoxicity and oxidative damage. These results run parallel to previous studies which concluded that nitric oxide possesses an injurious damaging effect on the different cells (Asit Kumar et al., 2009). This may explain the significant increase in the apoptotic marker BAX which was coincided with a significant decrease of the proliferative marker Ki 67 in the testis of the cisplatin group as compared to the control group, indicating to arrest of spermatogenesis as reported previously (Sakr & Nooh, 2013).

CoQ10 treated rats revealed significant decreases in the levels of nitric oxide. This effect could be attributed to the potent antioxidant effect of CoQ1 and its hydrophobic nature, which is an essential component in the mitochondrial respiratory cycle. CoQ10 prevents the production of NADPH oxidase enzyme that is the main cause of generation of ROS, that is highly reactive with NO and produce reactive nitrogen species (RNS) like peroxynitrite compound, leading to a significant decrease in NO, peroxynitrite, and nitrogen dioxide levels (Sohet et al., 2009). Hence, CoQ10 suppresses NO overproduction and prevents nitrative tissue trauma (Jung et al., 2009). These effects of CoQ10 would explain the significant decrease of collagen fibers deposition in the testes of CoQ10/cisplatin treated rats observed in the present study.

As expected, treatment of rats with cisplatin induced significant increases in the levels of TNF- α in comparison to control group. Treatment with cisplatin/CoQ10, however, induced significant decreases in the level of this cytokine. Given that elevated levels of TNF- α is the key for stimulation of the NF- κ B signaling pathway (Shukla et al., 2011) that stimulates the

transcription of NADPH oxidase, TNF- α and iNOS genes (Morishima et al., 2009), we suggest that amelioration of cisplatin-induced toxicity by Co-Q10 is mediated by its TNF- α , and ultimately decreasing the resultant oxidative stress. Our suggestion is in line with previous studies (Fouad et al., 2013) which postulated that CoQ10 treatment significantly reduced TNF- α overproduction, NF- κ B expression, and COX2 in the liver of rats with hepatocellular carcinoma (Fouad et al., 2013). Furthermore, cisplatin treated group revealed significant reduction in the anti-inflammatory cytokine interleukin-10 (IL-10) in comparison with control group. In contrast, coinjection of CoQ10 with cisplatin induced significant increases in IL-10 in comparison to cisplatin treated group. IL-10 confines the assembly of pro-inflammatory cytokines and chemokines and their injurious effects (Moore et al., 2001). These results in agreement with an earlier study that postulated blocking IL-10 signaling could cause significant damage and even cell death in acutely infected individuals (Couper et al., 2008). As such, CoQ10 caused down-regulation of pro-inflammatory cytokine as TNF- α with up regulation of anti-inflammatory cytokine as IL-10. Pro-inflammatory cytokines attract the immune cells to the site of injury causing a significant adverse effect, including testicular toxicity as those induced by cisplatin drug.

CONCLUSION

It could be concluded that CoQ10 provides significant protecting effects against cisplatin induced acute toxicity of testicular tissues in male rats. The antioxidant and anti-inflammatory mechanisms are the keys factors mediating its testicular tissue protection. Therefore, CoQ10 can be an adjuvant therapy for preventing testicular damage and dysfunction induced by cisplatin therapy.

AUTHORS' CONTRIBUTION

Not applicable.

CONFLICT OF INTEREST

All authors declare no conflicts of interest.

FUNDING

No fund was received for this work.

REFERENCES

- Adejuwon, SA, Femi-Akinlosotu, OM, Omirinde, JO (2015). Cisplatin-induced testicular dysfunction and its amelioration by *Launaea taraxacifolia* leaf extract. *Andrologia*, 47(5): 553-559.
- Adelakun, SA, Akinola, BK, Akingbade, GT (2018). Fertility Enhancing Activities of Bioactive Components of *Cochlospermum planchonii* Rhizome on Cisplatin Induced Reproductive Dysfunctions in Sprague-Dawley Rats. *Journal of Family Reproductive Health*, 12(3): 148-159.
- Asit Kumar, B, Rana, T, Das, S, Bandyopadhyay, S, Bhattacharya, D, Pan, D (2009). L-Ascorbate protects rat hepatocytes against sodium arsenite-induced cytotoxicity and oxidative damage. *Human & Experimental Toxicology*, 29(2): 103-111.
- Azu, OO, Duru, FIO, Osinubi, AA, Oremosu, AA, Noronha, CC, Elesha, SO, Okanlawon, AO (2010). Histomorphometric effects of *Kigelia africana* (Bignoniaceae) fruit extract on the testis following short-term treatment with cisplatin in male Sprague-Dawley rats. *Middle East Fertility Society Journal*, 15(3): 200-208.
- Clancy, RM, Abramson, SB (1995). Nitric oxide: a novel mediator of inflammation. *Proceedings of the Society for Experimental Biology and Medicine*, 210(2): 93-101.
- Colpi, GM, Contalbi, GF, Nerva, F, Sagone, P, Piediferro, G (2004). Testicular function following chemo-radiotherapy. *European Journal of Obstetrics & Gynecology and Reproductive Biology*, 113: S2-S6.
- Couper, KN, Blount, DG, Riley, EM (2008). IL-10: the master regulator of immunity to infection. *The Journal of Immunology*, 180(9): 5771-5777.
- Ebisch, IM, Thomas, CM, Peters, WH, Braat, DD, Steegers-Theunissen, RP (2007). The importance of folate, zinc and antioxidants in the pathogenesis and prevention of subfertility. *Human reproductive update*, 13(2): 163-174.
- Fleischman, RW, Stadnicki, SW, Etheir, MF, Schaeppi, U (1975). Ototoxicity of cis-dichlorodiammine platinum (II) in the guinea pig. *Toxicology and Applied Pharmacology*, 33(2): 320-332.
- Fouad, AA, Al-Mulhim, AS, Jresat, I (2013). Therapeutic effect of coenzyme Q10 against experimentally-induced hepatocellular carcinoma in rats. *Environmental Toxicology and Pharmacology*, 35(1): 100-108.
- Fung, C, Vaughn, DJ (2011). Complications associated with chemotherapy in testicular cancer

- management. *Nature Reviews Urology*, 8(4): 213-222.
- Hassan, AI, Alam, SS (2014). Evaluation of mesenchymal stem cells in treatment of infertility in male rats. *Stem Cell Research & Therapy*, 5(6): 131.
- Hussein, SM, El-Fadaly, AB, Metawea, AG, Khaled, BEA (2020). Aging changes of the testis in albino rat: light, electron microscopic, morphometric, immunohistochemical and biochemical study. *Folia Morphologica (Warsz)*, 79(3): 503-515.
- Hussein, YM, Mohamed, RH, Shalaby, SM, Abd El-Haleem, MR, Abd El Motteleb, DM (2015). Anti-oxidative and anti-apoptotic roles of spermatogonial stem cells in reversing cisplatin-induced testicular toxicity. *Cytotherapy*, 17(11): 1646-1654.
- Ilbey, YO, Ozbek, E, Cekmen, M, Simsek, A, Otuntemur, A, Somay, A (2009). Protective effect of curcumin in cisplatin-induced oxidative injury in rat testis: mitogen-activated protein kinase and nuclear factor-kappa B signaling pathways. *Human Reproduction*, 24(7): 1717-1725.
- Joensen, UN, Jørgensen, N, Meyts, ERD, Skakkebaek, NE (2008). Testicular dysgenesis syndrome and Leydig cell function. *Basic & clinical pharmacology & toxicology*, 102(2): 155-161.
- Jung, HJ, Park, EH, Lim, C J (2009). Evaluation of anti-angiogenic, anti-inflammatory and antinociceptive activity of coenzyme Q(10) in experimental animals. *Journal of Pharmacy and Pharmacology*, 61(10): 1391-1395.
- Kartalou, M, Essigmann, JM (2001). Mechanisms of resistance to cisplatin. *Mutation Research*, 478(1-2): 23-43.
- Khalifa, EA, Nabil Ahmed, A, Hashem, KS, Allah, AG (2020). Therapeutic Effects of the Combination of Alpha-Lipoic Acid (ALA) and Coenzyme Q10 (CoQ10) on Cisplatin-Induced Nephrotoxicity. *International Journal of Inflammation*, 2020, 5369797.
- Martenies, SE, Perry, MJ (2013). Environmental and occupational pesticide exposure and human sperm parameters: a systematic review. *Toxicology*, 307, 66-73.
- Moore, KW, de Waal Malefyt, R, Coffman, RL, O'Garra, A (2001). Interleukin-10 and the interleukin-10 receptor. *Annual Review of Immunology*, 19: 683-765.
- Razi, M, Najafi, G, Feyzi, S, Karimi, A, Shahmohammadloo, S, Nejati, V (2012). Histological and histochemical effects of Glyphosate on testicular tissue and function. *Iranian journal of reproductive medicine*, 10(3): 181-192.
- Sakr, SA, Nooh, HZ (2013). Effect of *Ocimum basilicum* extract on cadmium-induced testicular histomorphometric and immunohistochemical alterations in albino rats. *Anatomy & cell biology*, 46(2): 122-130.
- Sherif, IO, Abdel-Aziz, A, Sarhan, OM (2014). Cisplatin-induced testicular toxicity in rats: the protective effect of arjunolic acid. *Journal of Biochemical and Molecular Toxicology*, 28(11): 515-521.
- Sohet, FM, Neyrinck, AM, Pachikian, BD, de Backer, FC, Bindels, LB, Niklowitz, P, Delzenne, NM (2009). Coenzyme Q10 supplementation lowers hepatic oxidative stress and inflammation associated with diet-induced obesity in mice. *Biochemical Pharmacology*, 78(11): 1391-1400.
- Türk, G, Ateşşahin, A, Sönmez, M, Ceribaşı, AO, Yüce, A (2008). Improvement of cisplatin-induced injuries to sperm quality, the oxidant-antioxidant system, and the histologic structure of the rat testis by ellagic acid. *Fertility and Sterility*, 89(5 Suppl): 1474-1481.
- Zhang, X, Yamamoto, N, Soramoto, S, Takenaka, I (2001). Cisplatin-induced germ cell apoptosis in mouse testes. *Archives of Andrology*, 46(1): 43-49.