



EGYPTIAN ACADEMIC JOURNAL OF
BIOLOGICAL SCIENCES
ZOOLOGY

B




ISSN
2090-0759

WWW.EAJBS.EG.NET

Vol. 13 No. 2 (2021)

www.eajbs.eg.net



Tramadol Biological Effects, 2: Effective Therapeutic Efficacy of *Lagenaria siceraria* Preparation and Melatonin on Cell Biological, Histochemical and Histopathological Changes in Hepatocytes of Tramadol-Induced Male Mice

Abdel-Baset M. Aref

Zoology Department, Faculty of Science, South Valley University, Egypt.

E.mail*: aref322189@yahoo.com & abdelbasset.aref@sci.svu.edu.eg

ARTICLE INFO

Article History

Received:8/8/2021

Accepted:19/9/2021

Keywords:

Tramadol -
Lagenaria
Siceraria -
Melatonin – Liver
– Male Mice
Cytologically,
histochemically,
and
histopathologically

ABSTRACT

Goal: the present work aimed to study of biological effects of tramadol and treat its side effects via *Lagenaria siceraria* or melatonin.

Results: Cytologically, histochemically, and histopathologically the present results showed the injection of tramadol for 20 and 40 days highly decreased the volume nuclei; DNA, RNA, total protein, and polysaccharides contents; and highly increased collagen content in normal hepatocytes of the male mice. Also, the present results showed the injection of tramadol showed a severe degree of histopathological changes in hepatocytes of the male mice.

Cytologically histochemically, the present results showed that: the treatment via *Lagenaria siceraria* or melatonin pronounced increased the volume nuclei; DNA, RNA, and total protein contents; and pronounced decreased collagen content in tramadol-induced hepatocytes of the male mice. Also, *Lagenaria siceraria* pronounced increased polysaccharides content. The stopping tramadol modulatory increased RNA and total protein contents and decreased collagen content in tramadol-induced hepatocytes. Histopathologically, *Lagenaria siceraria* or melatonin displayed normal histological architecture and normal regeneration and division of the hepatocytes in the tramadol-induced male mice.

Conclusion: tramadol induced various cytological, histochemical, and histopathological alterations, while the treatments resist and repair tramadol's side effects.

INTRODUCTION

Chemically, Raffa *et al.*, (1992) reported that tramadol (1RS, 2RS)-2-[(dimethylamino) methyl]-1-(3-methoxyphenyl)-cyclo-hexanol) is a synthetic opioid from the aminocyclohexanol group, an analgesic with opioid agonist properties that acts on the neurotransmission of noradrenaline and serotonin. Grond and Sablotzki, (2004) mentioned that tramadol shows structural resemblance with codeine. Tramadol is a synthetic analogue of codeine with central effects (Afshari *et al.*, 2011).

The liver and kidney are responsible for tramadol metabolism and excretion. It may induce hepatotoxicity and nephrotoxicity during its metabolism (Janssen-Ortho Inc., 2005). Tramadol metabolism takes place in the liver by the cytochrome p450 enzyme system and by-products are excreted through kidneys (Dickman, 2007).

Tramadol is a centrally-acting opioid analgesic that is mainly used for the relief of moderate to severe pain (Nossaman *et al.*, 2010).

In overdose, tramadol has a multi-organ failure; which involving acute liver failure due to fulminant liver necrosis and renal failure, besides urine retention also mentioned (Jick *et al.*, 1998). Abou El Fatoh *et al.*, (2014) mentioned that the possible risks of increased hepatic, renal dysfunction are evoked by repeated administration of tramadol for long periods. Tramadol toxicity led to significantly hepatorenal dysfunction (Heba and Azza, 2015). Increased risk of hepatic adenoma in males and non-dose-related pulmonary adenoma in females was recorded (Mugunthan and Davoren (2012).

Saha *et al.*, (2011) studied that a novel protein, Lagenin has also been isolated from *Lagenaria siceraria* seeds, where it possesses antitumor, immunoprotective, and antiproliferative properties. The fruits possess significant hepatoprotective activity. *Lagenaria siceraria* is traditionally used in liver disorders and various free radical-induced diseases. Ghosh *et al.*, (2009) displayed the antioxidant potential of *Lagenaria siceraria* which accounts for cytotoxic activity.

The fresh fruit juice of *Lagenaria siceraria* has also shown radical scavenging activity (Deshpande *et al.*, 2009). Zhang and Zhang, (2014) reported that melatonin and its metabolites reduced oxidative damage to proteins, lipids, and DNA. It also plays a protective role in mitochondria, by preventing them from undergoing oxidative damage. Melatonin improves or preserves ATP production, mitochondrial respiration, membrane potential, and permeability transition and consequently prevents electron leakage and reactive oxygen species (ROS) production. In addition, studies from the last years suggested that melatonin also exerts prooxidant effects under certain circumstances. Reiter *et al.*, (2003) mentioned that melatonin is capable of prevention molecular damages caused by toxic oxygen-and nitrogen-based reactants. Melatonin functions in scavenging free radicals might be classified into four main categories: (1) as an antioxidant directly scavenges ROS (Reiter, 2000), (2) stimulates the antioxidant enzymes production and activation (Rodriguez *et al.*, 2004) and (3) increases the efficacy of mitochondrial functions by improving MPTP, inhibition of cytochrome c release and refining of oxidative phosphorylation in the mitochondrial respiratory chain which further will decrease the peroxidation of membrane lipids (Acuna-Castroviejo *et al.*, 2007).

In the mature organism, every cellular community has special behavior in the process of cell proliferation that causes it to divide naturally at a rate proportional to the natural rate of loss of its cells by the programmed mortality, therefore each cellular community proliferates via its special behavior under the abnormal conditions, whether experimental stress or pathological events (Aref *et al.*, 2020).

MATERIALS AND METHODS

Animals:

A total number of 70 adult male Swiss albino mice were obtained from the Autoradiographic lab. of Cell Biology and Immunology, Faculty of Science, South Valley University. At the time of the experiments, the mice were each aged 90 ± 5 days and weighed 30 ± 2 g. All male mice were kept under the same conditions, an artificial light-dark cycle (12h-12h), a constant temperature ($23 \pm 2^\circ\text{C}$), and a level of humidity (37-40%). They were supplied standard food and water *ad libitum*.

Chemicals:

1- **Tramadol HCl ampoules** were purchased from October Pharma S.A.E., 6 October City, Egypt) was diluted with distilled water to a concentration of 150ug/1ml.

2- **Melatonin** [Sigma-Aldrich, Co. 3050 spruce street, St. Louis, MO 63103 USA 314-

771-5765] was dissolved in a few drops of absolute ethanol and diluted with distilled water to a concentration of 500 µg/ml.

3- *Lagenaria siceraria*: special preparation of *Lagenaria siceraria*, (Gamal & Aref₁), were prepared by Gamal Yagteen and Abdel-baset Aref via squeezer on 6 October City, Egypt (Aref *et al.*, 2018 & Aref *et al.*, 2020 & Aref *et al.*, 2021).

3. Experimental Design:

Two experiments were performed differing in exposure to the various treatments.

Experiment I:

Treated animals were divided into 3 groups, including 10 males each.

Group T₁: animals were daily subcutaneously injected with tramadol HCl (125ug / 100g b.w.) for 20 days.

Group T₂: animals were daily subcutaneously injected with tramadol HCl (125ug / 100g b.w.) for 40 days.

Group C: animals were daily subcutaneously injected with distilled water (0.25ml/ 30g b.w.) and served as control.

Experiment II:

All male mice were injected subcutaneously with a daily injection of tramadol (125ug / 100g b.w) for 40 days and subdivided into 4 groups, concluding 10 males each, designated as groups T, T_S, T_L, and T_M as follows:

Group T: Animals were treated with tramadol only.

Group T_S: tramadol-treated animals were injected with a daily injection of distilled water (0.25ml / 30g b.w.) for 40 days.

Group T_L: tramadol-treated animals were treated with a daily oral dose of a special preparation of *Lagenaria siceraria* (Gamal & Aref₁) (0.5 mg/ b.w.) for 40 days.

Group T_M: tramadol-treated animals were daily injected with a subcutaneous injection of Melatonin (100µg / 100g b.w.) for 40 days at 16h, 2h before the end of the light cycle for 40 days.

The mice of group T in experiment II were similar to mice of group T₂ in experiment I, which were daily injected with tramadol for 40 days only before sacrifice.

All male mice were anesthetized by Chloroform and were sacrificed the day following the last injection or oral dose.

Experiments of this research were conducted in a lab. achieved stability of environmental conditions, with a separation between treated animals and control ones and IACUC targets.

Tissues Preparation:

Tissue specimens of the liver excised, fixed in neutral formalin 10%, dehydrated in graded series of ethanol, cleared, embedded in paraffin wax, and sectioned at 5 microns thickness. The liver sections were stained according to the different examinations and techniques as follows:

1-Cell Biological and Histopathological Examinations:

Hematoxylin and eosin stain.

2-Histochemical Examinations of Liver Tissue:

Feulgen reaction for DNA content change.

Toluidine blue technique for RNA materials content changes.

Bromophenol blue technique for protein content changes.

Masson's trichrome method for collagen contents changes.

The periodic acid-Schiff reaction (PAS) for polysaccharides content changes.

3-Karyometric Studies:

The measurements of the volume of hepatocytes nuclei were carried out by using a camera program (LAS ZA) according to nucleus shape (rounded nuclei) and the following

equation was applied: $V = \frac{4}{3}\pi r^3$. Where: V= volume of nucleus, r = semi diameter (Lewinski *et al.*, 1984).

RESULTS

Cell Biological Changes in the Liver (Karyometric studies):

In Experiment I:

In the liver of control mice, the value of mean volume nuclei of hepatocytes was 531.1μ (Table 1). While in the liver of the mice which daily received tramadol for 20 days (T_1) or 40 days (T_2) showed values 227.3μ and 176.4μ respectively of the mean volume nuclei of hepatocytes in the liver of mice.

From the histochemical quantitative point of view, the daily injection of tramadol for 20 or 40 days decreased by 57.2% and 66.8% respectively the value of mean volume nuclei of hepatocytes in the liver of mice versus with that of control mice. While the daily injection of tramadol for 40 days (T_2) decreased by 22.4% value of mean volume nuclei of the hepatocytes versus that of the mice of (T_1) (Table 1).

From the cytological point of view, although tramadol has an inhibitory effect on volume nuclei of hepatocytes in the liver of mice but with time, this inhibitory effect will be decreased. From the cell biological point of view, tramadol is an inhibitor for cellular activities.

Table 1: Mean volume of nuclei of hepatocytes in the liver of control (C) and tramadol treated male mice for 20, 40 days (T_1 , T_2) of experiment 1 and tramadol treated male mice for 40 days (T), tramadol treated mice for 40 days and then treated with D.W. (T_S) or *Lagenaria siceraria*. (T_L) or melatonin (T_M) for 40 days in experiment 2. Also should is the percentage stimulation (S%) or percentage inhibition (I%) of the mean.

Liver	Experiment 1			Experiment 2			
Groups	C	T_1	T_2	T	T_S	T_L	T_M
Measurements							
Mean volume nuclei of hepatocytes	$531.1\pm 4.8\mu$	$227.3\pm 2.7\mu$	$176.4\pm 1.4\mu$	$176.4\pm 1.4\mu$	$252.6\pm 1.5\mu$	$402.4\pm 0.8\mu$	$426.3\pm 2.7\mu$
(S%) or (I%) of mean volume nuclei of hepatocytes		I=57.2%	I=66.8%		S=30.2%	S=56.2%	S=58.6%
			I=22.4%				%

In Experiment II:

The liver of mice after 40 days from stop tramadol injection (T_S) showed a value of 252.6μ of the mean volume nuclei of hepatocytes. While in the liver of the mice which were received *Lagenaria siceraria* (T_L) or melatonin (T_M) for 40 days, the values of mean volume nuclei of both of them were 402.4μ and 426.3μ respectively (Table 1).

From the histochemical quantitative point of view, the treatments with stop tramadol or *Lagenaria siceraria* or melatonin increased by 30.2%, 56.2%, and 58.6% respectively the value of mean volume nuclei hepatocytes in the liver of mice versus those of mice which received tramadol only for 40 days (Table 1).

From the cytological point of view, all previous treatments have the inhibitory effect on

the effect of tramadol on volume nuclei of hepatocytes in the liver in mice but did not reach control mice.

From the cell biological point of view, tramadol is an inhibitor for cellular activities, while previous treatments have the inhibitory effect on the effect of tramadol on volume nuclei of hepatocytes in the liver in mice but did not reach control mice

Histochemical Results of The Liver:

1-DNA Content:

In Experiment I:-

The liver of the control mice stained with DNA stain showed high DNA contents with deeply stained coloration (Fig. 1, C). The liver of the mice who received tramadol for 20 days (T₁) showed few DNA contents with faintly stained coloration (Fig.1, T₁). The liver of the mice who received tramadol for 40 days (T₂) showed few DNA contents with faintly stained coloration (Fig. 1, T₂).

Histochemically, tramadol remarkably decreased DNA content in the hepatocyte versus control mice. From the histochemical point of view, tramadol has an inhibitory effect on DNA synthesis in hepatocytes of male mice.

In Experiment II:-

The liver of the mice after stop tramadol injection (T_S) showed few DNA contents with moderately stained coloration (Fig. 1, T_S). The liver of the mice received tramadol plus *Lagenaria siceraria* (T_L) showed moderate DNA contents with moderately stained coloration (Fig. 1, T_L). The liver of the mice who received tramadol plus melatonin (T_M) showed moderate DNA contents with moderately stained coloration (Fig. 1, T_M).

Histochemically, the treatments with *Lagenaria siceraria* or melatonin increased DNA content in the hepatocyte of the mice versus that of the mice which received tramadol only for 40 days.

From the histochemical point of view, both *Lagenaria siceraria* or melatonin resist the tramadol effect on hepatocytes of the male mice. From the histochemical point of view, tramadol has an inhibitory effect on DNA synthesis in hepatocytes of the male mice, While the treatment via both *Lagenaria siceraria* or melatonin resistant the tramadol side effect on hepatocytes of the male mice.

2-RNA Content:

In Experiment I:-

The liver of the control mice stained with RNA stain showed high RNA contents with deeply stained coloration (Fig. 2, C). The liver of the mice who received tramadol (T₁) showed low RNA contents with faintly stained coloration (Fig. 2, T₁). The liver of the mice who received tramadol (T₂) showed minimal RNA contents with faintly stained coloration (Fig. 2, T₂).

Histochemistry, the injection of tramadol for 20 and 40 days highly decreased the RNA content in the hepatocytes of the male mice compared with that of control mice. From the histochemical point of view, tramadol has a higher inhibitory effect on the RNA synthesis in the hepatocytes of mice.

In Experiment II:-

The liver of the mice after stop tramadol injection (T_S) showed moderate RNA contents with moderately stained coloration (Fig. 2, T_S). The liver of the mice received tramadol plus *Lagenaria siceraria* (T_L) showed moderate RNA contents with deeply stained coloration (Fig. 2, T_L). The liver of the mice that received tramadol plus melatonin (T_M) showed moderate RNA contents with moderately stained coloration (Fig. 2, T_M).

Histochemically, the treatment via stopping tramadol injection or *Lagenaria siceraria* or melatonin modulatory increased the RNA content in the hepatocytes versus

the mice that treated with tramadol.

From the histochemical point of view, the treatment with stopping tramadol injection or *Lagenaria siceraria* or melatonin has a resistant effect on tramadol side effect on the hepatocytes of male mice. From the histochemical point of view, tramadol has a higher inhibitory effect on the RNA synthesis in the hepatocytes of mice, while the treatment with stopping tramadol injection or *Lagenaria siceraria* or melatonin has a resistant effect on tramadol side effect on the hepatocytes of male mice.

3- Total Protein Content:

In Experiment I:-

The liver of the control mice stained with bromophenol showed high protein content inside hepatocytes indicated with deeply blue stainability (Fig. 3, C). While the mice received tramadol at T₁ and T₂ detected slight and weak protein content inside hepatocytes with faint or weak blue stainability, respectively (Figs. 3, T₁ & T₂). Liver of Histochemistry, the tramadol injection for 20 and 40 days highly decreased the total protein content in the hepatocytes versus that of the control male mice. From the histochemical concept, tramadol highly inhibits protein synthesis in the hepatocytes of male mice.

In Experiment II:-

The mice after stop tramadol injection (T_S) showed moderately protein content inside hepatocytes with moderate blue stainability (Fig. 3, T_S). Also, the liver of the mice treated with *Lagenaria siceraria* (T_L) and melatonin (T_M) displayed moderate protein content inside hepatocytes with moderate blue stainability (Figs 3 T_L & T_M).

Histochemically, the three treatments stopping tramadol or *Lagenaria siceraria* or melatonin, modulatory increased the total protein content in hepatocytes compared with the mice that were injected with tramadol for 40 days.

From the concept of histochemistry, partially the stopping tramadol or *Lagenaria siceraria* or melatonin treated the tramadol side effect on protein synthesis in hepatocytes of the male mice. From the histochemical point of view, tramadol inhibits the protein synthesis in the hepatocytes of male mice, while partially stopping tramadol or *Lagenaria siceraria* or melatonin treated this tramadol side effect.

4- Collagen Content:

In Experiment I:-

The liver of the control mice stained with Mallory trichrome showed normally distributed collagen fibers around hepatocytes (Fig. 4, C). The liver of the mice who received tramadol (T₁) revealed interstitial collagen fibrosis. Also, a marked degree of perivascular fibrosis was detected (Fig. 4, T₁). The liver of the mice who received tramadol (T₂) showed increase collagen fibers distribution around blood vessels (Fig 4, T₂) in addition to interstitial fibrosis was observed.

Histochemically, Tramadol injection, for 20 and 40 days, highly increased the collagen content in the liver versus the control mice. From the histochemical point of view, tramadol highly induced collagen synthesis in the liver of male mice.

In Experiment II:-

The liver of the mice after stop tramadol injection (T_S) exhibited pronounced interstitial fibrosis (Fig. 4, T_S) with pronounced perivascular fibrosis. The liver of the mice received tramadol plus *Lagenaria siceraria* (T_L) and melatonin (T_M) recorded minimal and sometimes normal distribution of collagen fibers (Figs. 4, T_L & T_M).

Histochemically, the three treatments pronounced decreased collagen content in the liver compared with that of the mice injected with tramadol for 40 days.

From the histochemical point of view, stopping tramadol or *Lagenaria siceraria* or melatonin treats the side effect of tramadol on collagen synthesis in the liver of

mice. From the histochemical point of view, tramadol highly induced collagen synthesis in the liver of male mice, while stopping tramadol, *Lagenaria siceraria*, and melatonin resistant this tramadol side effect.

5- Polysaccharides Content:

In Experiment I:-

The liver of the control mice stained with the PAS technique showed high polysaccharides content in hepatocytes with deeply stained red coloration (Fig. 5, C). The liver of the mice who received tramadol (T₁) exhibited low polysaccharides content in hepatocytes with faint stained red coloration (Fig. 5, T₁). Also, the liver of the mice who received tramadol (T₂) detected low polysaccharides content in hepatocytes with weak stained red coloration (Fig. 5, T₂).

Histochemically, tramadol highly decreased the polysaccharides content in the hepatocytes of the male mice, versus control mice.

Tramadol has an inhibitory effect on the formation of polysaccharides in the hepatocytes of male mice.

In Experiment II:-

While after stop tramadol injection (T_S), the liver showed low polysaccharides infiltration inside hepatocytes with low stained red coloration (Fig. 5, T_S). However, the mice treated with *Lagenaria siceraria* (T_L) and melatonin (T_M) showed modulate and low polysaccharides content respectively in hepatocytes with modulatory and faintly stained red coloration (Figs. 5, T_L & T_M).

Histochemically, *Lagenaria siceraria* remarkably increased polysaccharides content in the hepatocytes versus the mice that received tramadol for 40 days, while both stopping tramadol and melatonin did not change polysaccharides content.

From the histochemical point of view, *Lagenaria siceraria*, partially, treats the tramadol side effect on the formation of polysaccharides in the liver of male mice. From the histochemical point of view, tramadol has an inhibitory effect on the formation of polysaccharides in the hepatocytes of male mice, while *Lagenaria siceraria*, partially, treats the tramadol side effect.

Histopathological Changes in the Liver:

The histological structure of the liver of the control mice showed normal criteria (Fig. 6, C). Since the hepatocytes appeared within normal architecture with hexagonal shapes. The hepatic lobule exhibited a roughly hexagonal arrangement of plates of hepatocytes radiating outward from a central vein; in addition reflecting normal blood vessels involving the central vein, portal area, and blood sinusoid.

While the mice received tramadol only, they exhibited pronounced pathological deteriorations. Since the mice received tramadol at the first stage (T₁=20 days) displayed severe necrosis of the hepatocytes characterized by karyolysis of the nuclei and extensive mononuclear cells infiltration mainly lymphocytes. There was a remarkable degree of hemorrhagic inflammation demonstrated by erythrocytes and inflammatory cells infiltration. Abnormal hyperchromasia phenomena with high mitotic figures were detected. Concerning blood vessels, thrombotic congestion of the hepatic blood vessels was observed characterized by dilatation and distension of the blood vessels with stagnant red blood cells, inflammatory cells, and fibrinous fluids. Also, there was perivascular infiltration of the blood vessels with lymphocytes infiltration. Some hepatocytes showed fatty cells infiltration since they appeared as large distended cells. The blood sinusoid suffered severe dilatation and distension (Figs. 6, T₁).

The mice that received tramadol at the second stage (T₂=40 days) recorded severe degree necrosis of hepatocytes, besides hemorrhagic inflammation with extensive red blood cells and lymphocytes infiltration. There was pronounced fatty cells infiltration,

besides high mitotic division. Severe portal dilatation and inflammation with mononuclear cells mainly lymphocytes infiltration was noticed. Moreover, blood sinusoids exhibited severe dilatation in addition to focal lymphocytes infiltration was detected (Fig. 6, T₂).

Histopathologically, The injection of tramadol showed a severe degree of histopathological changes in hepatocytes of the male mice. While the mice stop tramadol injection (T_S) showed moderate pathological changes in the liver involving showing moderate hyperchromasia and some hepatocytes displayed normal mitotic division and few fatty cells infiltration. Blood vessels exhibited slight congestion of blood vessels. Also, there was portal congestion and inflammation, in addition to, a slight degree of hemorrhagic inflammation characterized by few red blood cells infiltration. Moreover, slight dilatation in the hepatic sinusoid was observed with focal mononuclear cells infiltration (Figs. 6, T_S).

The liver of the mice received tramadol and was treated with *Lagenaria siceraria* (T_L) displayed normal regeneration and division of the hepatocytes, also mild fatty cells infiltration was detected. Some hepatocytes suffered slight hemorrhage with red blood cells infiltration and mild dilatation of the hepatic sinusoids. The central vein showed slight inflammation and dilatation (Figs. 6, T_L).

Moreover, the liver of the mice who received tramadol and were treated with melatonin (T_M) exhibited normal regeneration and division of the hepatocytes, and mild inflammatory cells inflammation, besides mild hemorrhagic inflammation, was noticed. The hepatic blood vessels including the central vein, blood sinusoids, and portal area recorded a mild degree of inflammation with slight dilatation, besides less mitotic division (Figs. 6, T_M).

The liver of the mice received tramadol and was treated with *Lagenaria siceraria* or melatonin displayed normal histological architecture and normal regeneration and division of the hepatocytes in the tramadol-induced male mice. Histopathologically, The injection of tramadol showed a severe degree of histopathological changes in hepatocytes of the male mice. The liver of the mice received tramadol and was treated with *Lagenaria siceraria* or melatonin displayed normal histological architecture and normal regeneration and division of the hepatocytes in the tramadol-induced male mice.

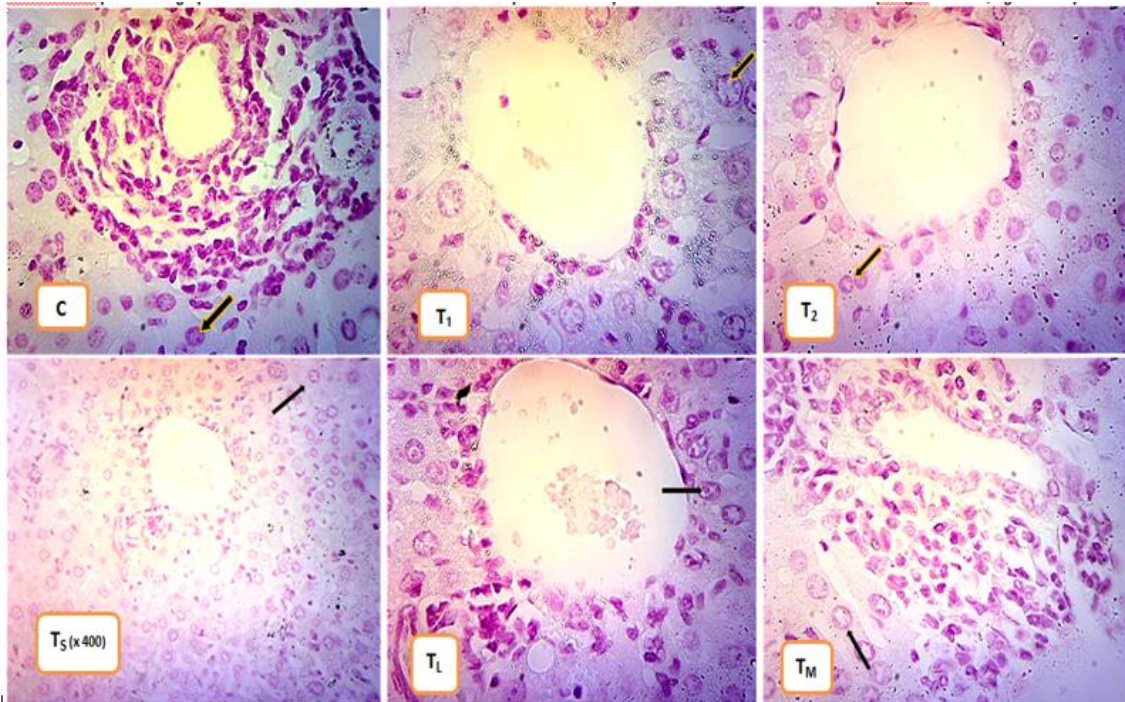


Fig. 1: photomicrographs of DNA content in nuclei of the hepatocytes of the male mice in experiment I and II. (Feulgen reaction, X1000)

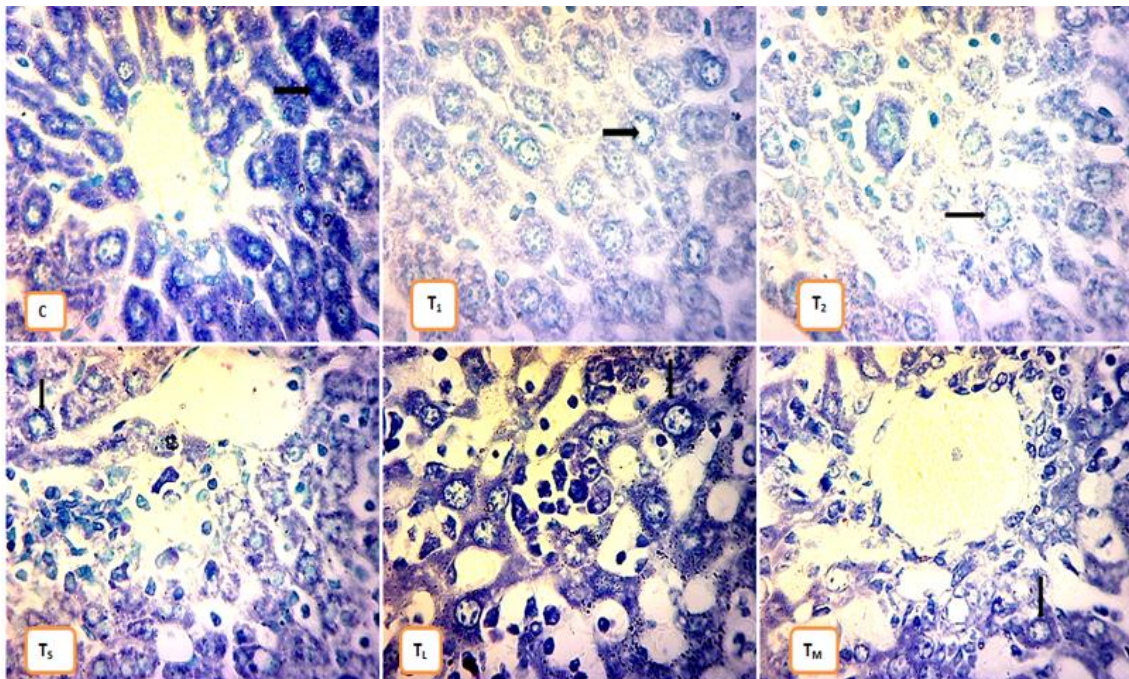


Fig. 2: photomicrographs of RNA content in the liver of the male mice in experiment I and II. (Toluidine blue technique, x 1000).

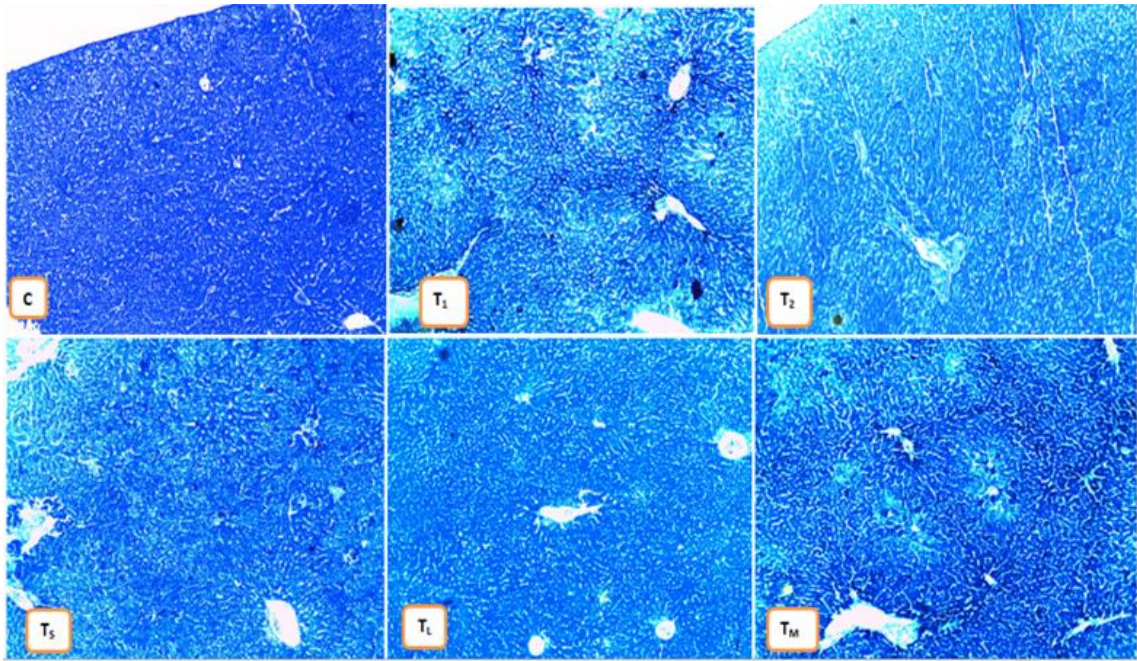


Fig. 3: photomicrographs of total protein content in the liver of the male mice in experiment I and II. (Bromophenol blue technique, x 100).

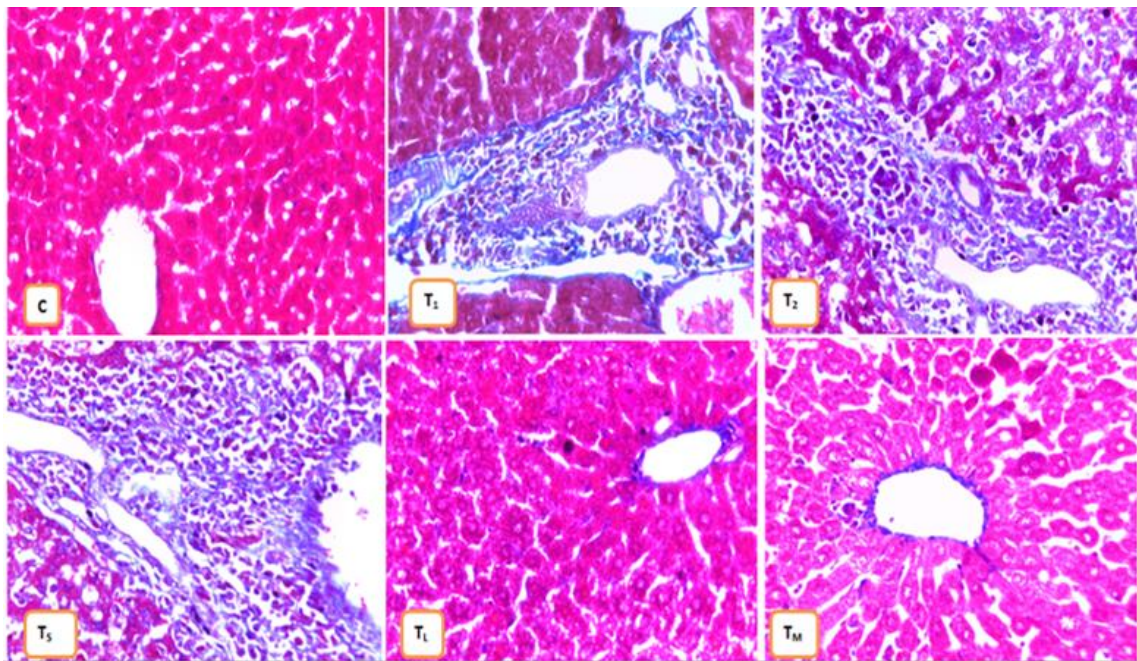


Fig. 4: photomicrographs of total collagen content in the liver of the male mice in experiment I and II. (Mallory trichrome technique, x 400).

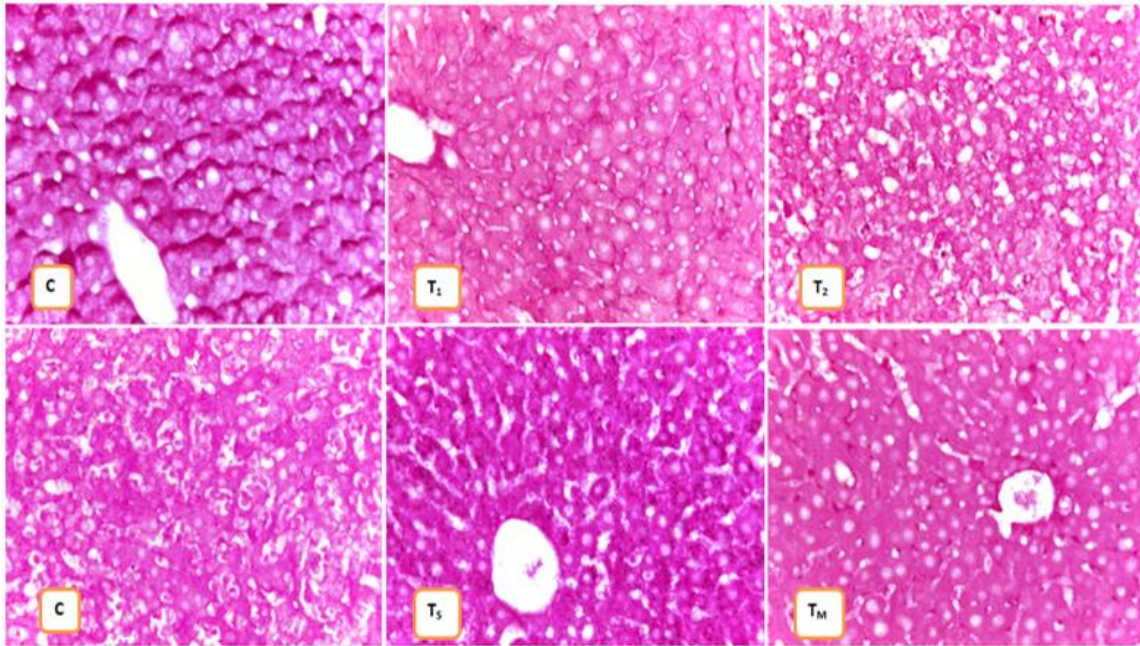


Fig. 5: photomicrographs of polysaccharides content in the liver of the male mice in experiment I and II. (PAS technique, x 100).

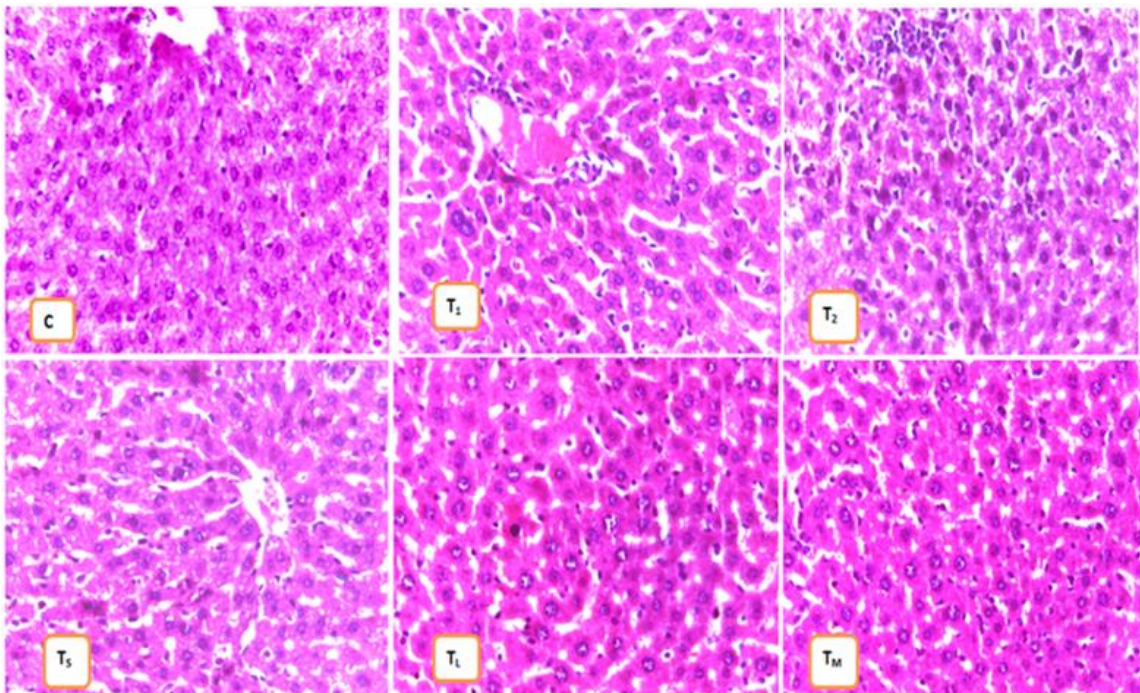


Fig. 6: photomicrographs of Histopathological changes in the liver of the male mice in experiment I and II. (H and E technique, x 100).

DISCUSSION

Cytologically, histochemically, and histopathologically the present results showed the injection of tramadol for 20 and 40 days highly decreased the volume nuclei; DNA, RNA, total protein, and polysaccharides contents; and highly increased collagen content in normal hepatocytes of the male mice. Also, the present results showed the injection of tramadol showed a severe degree of histopathological changes in hepatocytes of the male mice.

Cytologically histochemically, the present results showed that: the treatment via *Lagenaria siceraria* or melatonin pronounced increased the volume nuclei; DNA, RNA, and total protein contents; and pronounced decreased collagen content in tramadol-induced hepatocytes of the male mice. Also, *Lagenaria siceraria* pronounced increased polysaccharides content. The stopping tramadol modulatory increased RNA and total protein contents and decreased collagen content in tramadol-induced hepatocytes. Histopathologically, *Lagenaria siceraria* or melatonin displayed normal histological architecture and normal regeneration and division of the hepatocytes in the tramadol-induced male mice.

"From a biological point of view, the chemistry of cellular structure and function is well established. Therefore, studying the chemical components in their natural locations in the cells and tissues, and tracking the changes that occur to them under abnormal conditions, whether pathological or experimental, is very important, as any change that occurs to these substances is often accompanied by some pathological manifestations (Aref *et al.*, 2021).

There is little or no published literature concerning to study of the biological effect of tramadol and *Lagenaria siceraria* on the liver of the male mice, therefore may it is difficult to discuss the results of the present work with the other published works previously.

From the cell biological point of view, tramadol is an inhibitor for cellular activities, while previous treatments have the inhibitory effect on the effect of tramadol on volume nuclei of hepatocytes in the liver in mice but did not reach control mice. From the histochemical point of view, tramadol has an inhibitory effect on DNA synthesis in hepatocytes of the male mice, While the treatment via both *Lagenaria siceraria* or melatonin resistant the tramadol side effect on hepatocytes of the male mice. From the histochemical point of view, tramadol has a higher inhibitory effect on the RNA synthesis in the hepatocytes of mice, while the treatment with stopping tramadol injection or *Lagenaria siceraria* or melatonin has a resistant effect on tramadol side effect on the hepatocytes of male mice.

From the histochemical point of view, tramadol inhibits the protein synthesis in the hepatocytes of male mice, while partially stopping tramadol or *Lagenaria siceraria* or melatonin treated this tramadol side effect.

From the histochemical point of view, tramadol highly induced collagen synthesis in the liver of male mice, while stopping tramadol, *Lagenaria siceraria*, and melatonin resistant this tramadol side effect.

From the histochemical point of view, tramadol has an inhibitory effect on the formation of polysaccharides in the hepatocytes of male mice, while *Lagenaria siceraria*, partially, treats the tramadol side effect.

Histopathologically, The injection of tramadol showed a severe degree of histopathological changes in hepatocytes of the male mice, the present results agree to some extent with those of some authors in rabbits and rats.

Histopathologically. in overdose, tramadol has a multi-organ failure; which

involving acute liver failure due to fulminant liver necrosis and renal failure, besides urine retention also mentioned (Jick *et al.*, 1998).

Atici *et al.*, (2005) revealed severe pathological changes in rabbits exposed to tramadol including congestion in blood vessels of the central vein and sinusoids, periportal fibrosis with the proliferation of fibroblastic cells, inflammatory cells infiltration, fatty changes, degeneration of some hepatocytes and hepatocytes vacuolation especially in those treated with tramadol for a longer duration at 30 days and more. The congestion in the central vein and sinusoids were detected at 10 days and more. Zuhtu Utku *et al.*, (2006) demonstrated that morphine and tramadol may lead to some pathological changes in liver tissue. The postoperative effects of morphine and tramadol induced hepatocytes degeneration, dilatation of central vein, and mononuclear cell infiltration on of liver in rabbits exposed to morphine and tramadol. In addition, sinusoidal dilatation in the tramadol group was more severe than that of the morphine group. Salem *et al.*, (2010) illustrated hepatotoxicity in albino rats after using tramadol in case of daily treatment with a single therapeutic dose for a month, were including congestion and vascular dilatation of the hepatic blood vessels. The double dose revealed in addition to the preceding alterations, cellular infiltration, and necrotic changes around the central vein. Rabei, (2011) exhibited that tramadol and/or APAP induced DNA alterations of hepatocytes in a dose-dependent pattern. Liver displayed vacuolation in hepatocytes with dilated sinusoid and proliferated kupffer cells; atrophied hepatocytes with nuclei reduced in size and darkly stained. Congestion in blood vessels with edema and the inflammatory reaction was detected.

Histopathologically, our results showed the liver of the mice that received tramadol and was treated with *Lagenaria siceraria* or melatonin displayed normal histological architecture and normal regeneration and division of the hepatocytes in the tramadol-induced male mice.

REFERENCES

- Abou El Fatoh, M. F., Farag, M. R., ESayed, Sh. A., Kamel, M. A, Nora E. Abd, Hussein, M. A., and Salem, G. A. (2014): Some Biochemical, Neurochemical, Pharmacotoxicological and Histopathological Alterations Induced by Long-term Administration of Tramadol in Male Rats. *Research Article, International Journal of Pharma Sciences*, 4 (3): 565-571.
- Acuna-Castroviejo, D., Escames, G., Rodriguez, M.I. and Lopez, L.C. (2007): Melatonin role in the mitochondrial function. *Front. Bioscience*, 12, 947-963.
- Afshari, R., Afshar, R., and Mégarbane, B. (2011): Tramadol overdose: review of the literature. *Ré animation*, 20 (5):436-41.
- Aref, A. B. M., Momenah, M. A., Jad, M. M., & Semmler, M. (2018): Tramadol Biological Effects: I: Effective Therapeutic Efficacy of *Lagenaria siceraria* Preparation (Gamal & Aref1) and Melatonin on Cell Biological, Histochemical and histopathological Changes in Ileum of Tramadol-Induced Male Mice. *Egyptian Academic Journal of Biological Sciences. C, Physiology and Molecular Biology*, 10(2), 99-124.
- Aref, A. B. M., Momenah, M. A., Jad, M. M., Semmler, M., Mohamedaiin, H. S., Ahmed, A., & Mohamedien, D. (2021): Tramadol Biological Effects: 4: Effective Therapeutic Efficacy of *Lagenaria siceraria* Preparation (Gamal & Aref1) and Melatonin on Cell Biological, Histochemical, and Histopathological Changes in the Kidney of Tramadol-Induced Male Mice. *Microscopy and Microanalysis*, 1-13.

- Aref, A. B. M., Semmler, M., Jad, M. M., Mohamadain, H. S . (2020): DMBA and Lagenaria Siceraria Biological Effects: 1: Is it Possible for Lagenaria Siceraria to be a Treatment for The Carcinogenesis in The Ileum of DMBA-Induced Male Swiss Albino Mice. *Egyptian Academic Journal of Biological Sciences, D. Histology & Histochemistry*, 12(2), 59-75.
- Atici, S., Cinel, I., Cinel, L., Doruk, N., Eskandari, G., & Oral, U. (2005). Liver and kidney toxicity in chronic use of opioids: an experimental long term treatment model. *Journal of biosciences*, 30(2), 245-252.
- Dickman, A. (2007): Tramadol: a review of this atypical opioid. *European Journal of Palliative Care*, 14: 181-185.
- Ghosh, K., Chandra, K., Ojha A.K., Sarkar, S. and Islam, S.S. (2009): Structural identification and cytotoxic activity of a polysaccharide from the fruits of Lagenaria siceraria. *Carbohydrate Research*, 2009; 344(5):693-698.
- Grond, S., and Sablotzki, A. (2004): Clinical pharmacology of tramadol. *Clinical Pharmacokinetics*, 43 (13): 879-923. doi:10.2165/00003088-200443130-00004.
- Heba, A. El. (2015): Effects of tramadol on the reproductive function of wistar albino rats. *European Journal of Experimental Biology*, 5 (1): 56-64.
- Janssen-Ortho Inc. (2005): Tramacet, a product monograph., pp.1-36, www.janssen-ortho.com.
- Jick, H., Derby, L. E., Vasilakis, C., and Fife, D. (1998): The risk of seizures associated with tramadol. *Pharmacotherapy: The Journal of Human Pharmacology and Drug Therapy*, 18 (3):607-611.
- Lewiński, A., Vaughan, M. K., Champney, T. H., Reiter, R. J., & Smith, N. K. (1984). Inhibitory action of the pineal gland on the nuclear volume of thyroid follicular cells in male gerbils (*Meriones unguiculatus*). *Experimental and Clinical Endocrinology & Diabetes*, 84(05), 239-244.
- Mugunthan, N., and Davoren, P. (2012): Danger of Hypoglycemia Due to Acute Tramadol Poisoning. *Endocrine Practice*, 18 (6):e151-e2.
- Nossaman, V.E., Ramadhani, U., Kadowitz, P.J. et al. (2010): Advances in perioperative pain management: use of medication with dual analgesic mechanisms, tramadol and tapentadol. *Anesthesiology Clinics*, 28(4): 647- 677.
- Rabei, H. M. (2011): The immunological and histopathological changes of Tramadol, Tramadol/Acetaminophen and Acetaminophen in male Albino rats“Comparative study. *The Egyptian Journal of Hospital Medicine*, (Oct. 2011) Vol., 45: 477-503.
- Raffa, R.B., Friderichs, E., Reimann, W., Shank, R.P., Codd, E.E., and Vaught, J.L. (1992): Opioid and nonopioid components independently contribute to the mechanism of action of tramadol, an „ atypical” opioid analgesic. *Journal of Pharmacological Experimental Therapy*, 260: 275-285.
- Reiter, R.J., Tan, D.X., Mayo, J.C., Sainz, R.M. Leon, J. et al. (2003): Melatonin as an antioxidant: biochemical mechanisms and pathophysiological implications in humans. *Acta Biochimica Polonica*, 50(4), 1129-1146.
- Reiter R.J. (2000): Melatonin: Lowering the High Price of Free Radicals. *News. Physiological Science*, 15(5), 246-250.
- Rodriguez, C., Mayo, J.C., Sainz, R.M., Antolín, I., Herrera, F. et al. (2004): Regulation of antioxidant enzymes: a significant role for melatonin. *Journal of Pineal Research*, 36(1), 1-9.
- Saha, P., Mazumder, U.K., Halder, P.K., Gupta, M., Kundu Sen, S. and Islam. A. (2011): Antioxidant and Hepatoprotective Activity of Lagenariasiceraria Aerial parts. *Pharmacognosy Journal* ,2011;vol 3(23): 67-74.

- Salem, S. I., Elgayed, S. S. A., El-Kelany, W. M. and Abd El-Baky, A. A. (2010): Diagnostic studies on acetaminophen toxicosis in dogs. *Global Veterinaria*, 5(2): 72-83.
- Zhang, H.M. and Zhang, Y. (2014): Melatonin: a well-documented antioxidant with conditional pro-oxidant actions. *Journal of Pineal. Research*, 57: 131–146.
- Zuhtu Utku, S., Hakan, D. and Fazli, E. (2006): Histopathologic changes in liver induced by morphine and tramadol. *The Pain Clinic.*, 18 (4):321-325.