

Double Calcaneal Osteotomy in Treatment of Flexible FlatFoot

M.S.AIZahhar, E.A.Tabl, M.S.Abou Zied and M.M.Abdelmalak
Orthopaedic ,Dept.,Faculty of Medicine, Benha Univ., Benha, Egypt
E-Mail:dr.mario.2020@hotmail.com

Abstract

Double Calcaneal osteotomy is the gold standard surgery for treatment of flexible flatfoot in patients who have both forefoot abduction and heel valgus. MCO (Medializing calcaneal osteotomy) corrects the heel valgus while Evan's osteotomy corrects the forefoot abduction. Most of the cases are satisfied with the results. They returned back to their normal activities within 2 months. The procedure has little complications the most common is wound dehiscence. Our study was on 16 feet all of them were diagnosed as flexible flatfoot with mean age 18 years old. We used AOFAS for follow up. Heel valgus , Mearye`s angle , TNC angle and VAS score were used for assessment .Most of the patients were satisfied either from the improvement of the pain or the shape of the heel. There are a lot of operations used in treatment of FFF like arthroeresis ,calcaneal stop ,evan's osteotomy but DCO is superior to those as it corrects both heel valgus anf forefoot abduction at the same session.

Keywords: DCO, MCO, Evan's osteotomy, Mearey`s angle, Heel valgus.

1. Introduction

Flatfoot may be classified into types that are flexible and stiff. Flexible flat foot is characterised by an asymptomatic or symptomatic arc during non-weight-bearing and arch flattening at posture. Rigid flatfoot is characterised by a rigid, smooth arch in both weight and non-weight position. Most inflexible flatfeet are linked to a disease that needs specific care. Flatfoot may occur as a solitary disease (whether flexible or stiff), or as a broader clinical entity. [1]

Foot and ankle experts believe that flatfoot is a common pathology often seen. The flatfoot of adolescents is described as a foot problem which continues or develops after skeleton maturation and is characterised by partial or total loss (collapse). Adult flatfoot may occur as an accidental or symptomatic condition with clinical implications ranging from modest limits to severe disability and life impairment discomfort.[1] A teenage flatfoot includes a range of pathological etiologies which may include a benign process indicating the continuing of a systematic pathological issue, trauma and condition. The adult flatfoot is typically a complicated disease with different symptoms and deformities. Pathology and symptoms are produced by structural abnormalities in the foot and plantar arch and by the middle foot collapse and impingements of the lateral and back legs. [2]

Literature on the prevalence and symptoms of the adult flat feet is sparse. In all children and adults Ferciot predicted a 5% incidence of flatfoot. Harris and Beath examined 619 Royal Canadian army recruits, finding that 15 percent had a simple flatfoot hypermobile, 6 percent had a simple flatfoot hypermobile with a tight heel and 2 percent had a tarsal coalition. [2]

2. Patient and Methods

This work is a prospective study From June 2020 to June 2021, 16 patients operated with DCO when they were diagnosed as adolescent flexible flatfoot deformity and they were operated at Benha University Hospitals and Al Helal Hospital. All these patients,

they have flexible flatfoot with heel valgus and forefoot abduction .The mean age of the studied patients was 18 years, with a standard deviation of 4 years.

2.1. Epidemiology of the patients

2.1.1. Number of Patients

16 Feet in 16 patients were included in this study in the period between June 2020 and Jan 2021.Follow-up every1 month for 6 months.

- **Sex and age distribution:** 9males and 7 females.
- **Patient's occupation:** All of them were Students.
- **Special habits:** All of them are non smokers except one case.

2.2. Methodology

2.2.1. Preoperative evaluation

Patient selection

Criteria of inclusion

It include Symptomatic flatfoot., Flexible flatfoot., Older than 12 years old., Hindfoot valgus., Forefoot Abduction, No D.M or risk factors preventing surgery, No Arthritis and Age more than 12 years and less than 30 years old.

Criteria of exclusion

Rigid flatfoot excluded clinically by heel raise test, Age more than 30 years old, Patient complaining of Diseases preventing the Surgery, Non Diabetic and Mid or Hindfoot Arthritis.

Patient counseling

This was a crucial part of the study. The management plan included the necessary investigations, operative details and time schedule after the surgery needed for rehabilitation was discussed in detail with every patient. This counseling was essential to make the patients more comfortable and cooperative. Written informed consent was taken from every patient or his parents. Conservative methods including orthotics, custom-fit insoles, and Achilles tendon stretching exercises were recommended before the operation. We usually recommend these treatments for 6months to observe whether the symptoms disappear.

A careful history and clinical examination must be taken before the surgery.

Patients with rigid flatfoot were excluded.

Full pre-operative laboratory investigations before surgery planning

Clinical Photo of foot and heel before and after Surgery.

(ANOVA) was used, the relationship between two qualitative variables was examined using Chi-Square test, the relationship between two qualitative variables when the expected count is less than 5 in more than 20% of cells was examined using Fisher's exact test, the strength of association between two quantitative variables was assessed by correlational analysis. Reliability test was made by using Cronbach's Alpha and was (alpha= 0.841) which is very good. P value is significant if <0.05 at confidence interval 95%.

Patient evaluation

Clinical and radiological evaluation for each patient was conducted according to the following protocol Past history:

Medical history of the patients:

If they have medical condition preventing surgery, all of them don't have any medical problems.

History of previous trauma to the Foot

To exclude mid foot and hind foot fractures.

The time from onset of affected Foot pain to surgery 5 patients were complaining of pain 3 years duration before surgery. 6 patients were complaining of pain 2 years duration before surgery. 3 patients were complaining of pain 1 year duration before surgery. 2 patients were complaining of pain 7 months duration before surgery.

Present history

a- General examination

This was done to assess every patient's general fitness for the surgery.

Pre-assessment of the patient by anesthesiologist was done to identify prerequisites of surgery.

b- Local examination

Meticulous local examination of the affected Foot was done for each patient.

Assessment of Ankle and subtalar motion.

Heel Raise Test to Confirm the Flexibility. Arch is restored and heel valgus is corrected while Tip toe standing. Fig no 1

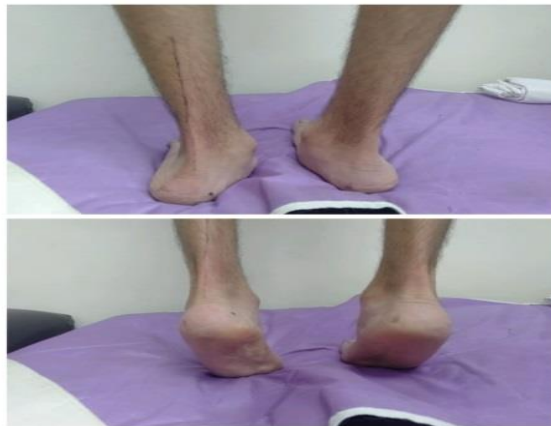

Fig. (1) Heel Raise Test.

The equinus deformity was defined according to the Silfverskiöld test. The isolated gastrocnemius contracture was defined as when the knee was fully extended, the passive ankle dorsiflexion was smaller than 5°. The gastrocnemius-soleus complex contracture was defined as when the knee was in 90° flexion, the ankle dorsiflexion was smaller than 10°.

Neurovascular status of the extremity was documented.

c- Preoperative scoring

The American Orthopaedic Foot and Ankle Society (AOFAS) Score was adopted to determine the functional outcomes of flatfoot patients. The scores are rated as excellent (90 to 100 points), good (80 to 89 points), fair (70 to 79 points), and poor (< 70 points).

Vas Score for pain is applied to determine the pain before and after.

Measuring Valgus angle of the Hind Foot by Goniometer to compare it after correction by

measuring the angle formed by the axis of the leg with the axis of the heel (which is in valgus). Normal valgus angle is about 7 degrees.

General characteristics

The mean age of the studied patients was 18 years, with a standard deviation of 4 years. Regarding gender, more than half of the patients were males (56.3%). The mean weight was 57 kg, with a standard deviation of 9 kg. fig (2)

- **Technique:** Two small incisions one for evans osteotomy 1.5cm from the calcenocuboid joint and 1 cm base bone graft from the iliac crest was inserted inside. Another incision 1cm posterior to the lateral malleolus and calcaneal osteotomy is done then we displace it medially 1cm and fix it by 2 k wires (if there is still physis) or cannulated screws. Below knee backslap for 2 weeks then below knee cast for another 1 months .Weight bearing is allowed after removal of the cast.

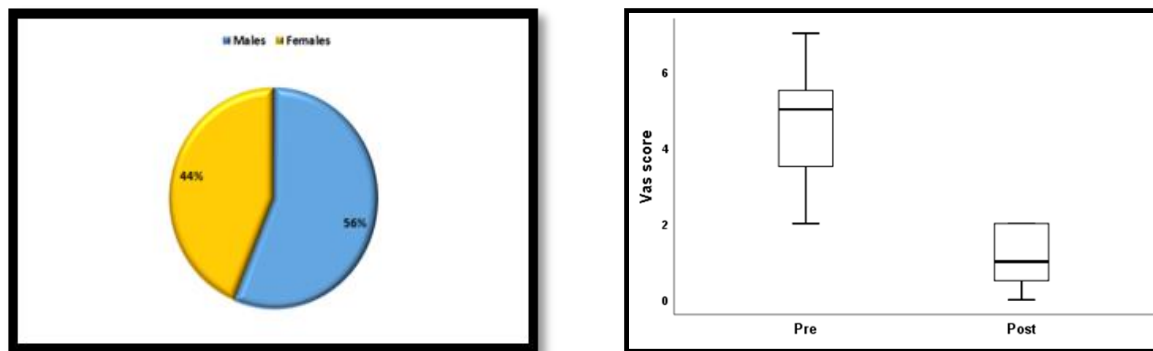


Fig. (2) Gender distribution of the studied patients.

Table (1) Gender distribution of the studied patients.

General characteristics		
Age (years)	Mean ±SD	18 ±4
Sex	Males n (%)	9 (56.3)
	Females n (%)	7 (43.8)
Smoking	n (%)	1 (6.3)
Weight (kg)	n (%)	57 ±9

3. Results

3.1 Pre and post-operative AOFAS Score Mean AOFAS -OH showed a significant increase post-operative (77) compared to pre-operative (42); P-value was <0.001.

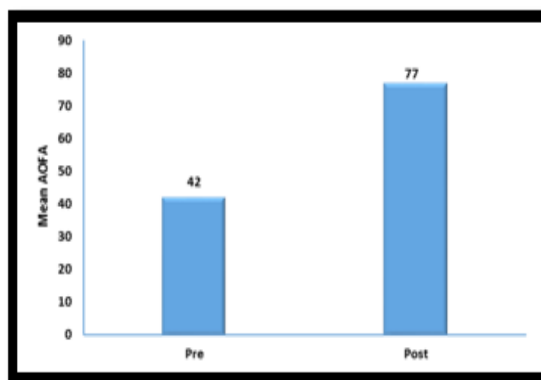


Fig. (3) Pre and post-operative AOFAS

Pre and post-operative VAS

Median VAS showed a significant decrease post-operative (1) compared to pre-operative (5); P-value was 0.001.

Pre and post-operative Meary's angle

Median Meary's angle showed a significant decrease post-operative (3) compared to pre-operative (4); P-value was <0.001.Fig (3)

Pre and post-operative talonavicular coverage angle

Median talonavicular angle showed a significant decrease post-operative (6) compared to pre-operative (5); P-value was <0.001.

Pre and post-operative heel valgus angle

Median heel valgus angle showed a significant decrease post-operative (6) compared to pre-operative (7); P-value was <0.001. Correlation between weight and post-operative changes of different outcomes. Weight showed a significant negative correlation with post-operative percent decrease of VAS (r = -0.541 & P value = 0.03), Meary's angle (r = -0.671 & P value = 0.003), and talonavicular coverage angle (r = -0.610 & P value = 0.012). Weight over 70kg had less results.

4. Discussion

There are numerous benefits using double calcaneal osteotomy alone. Structural arch restoration may be achieved without the rebuilding of soft tissue. The technique's flexibility has been shown to include patients with flexible, flat feet whatever their nature provided radiological alterations are not made.

The mean AOFAS score indicated a substantial postoperative [9] increase over preoperative [8]; P value was <0.001. This finding corresponded to previous research. Within A research by Yang Xu and others in 2017, AOFAS improved postoperatively from 68.9 ± 12.3 to 94.6 ± 3.9 . [10] The 2011 average preoperative AO FAS score was substantially increased from 48.4 ± 15.1 (17–69) to 78.7 ± 6.7 (60–90) at final follow-up ($p < 0.00128$) in another research was out by Yehia Basioni, Abdel-Rahman El-Ganainy and Ahmed El-Hawary. [11] The score for preoperative mean AOFAS has risen substantially from 56.76 to 95.29 in another research conducted by TahirOugt and etal. [12] The angle of the Midian Meary was significantly lower after surgery [3] compared to preoperative (13); P-value was less than 0.001. This has been consistent with previous research. A research carried out in 2018 by HanyMourkus & HariPrem. Meary's average angle improvement was 14.99° . [13] The average preoperative and postoperative talo-first metatarsal angles in 2017 also amounted to 18.1 ± 5.5 and 4.9 ± 4.4 for another research by Yang Xu and Etal. [14] The median talonavicular coverage angle revealed a substantial post-operative decline [15] compared to the preoperative angle, according to the present research [21]; the P-value was <0.001. This finding was in accordance with another research by TahirOugt and others in 2016 improved by mean ($p = 0.007$) in which talonavicular coverage in AP radiographs. [16] A number of operations in flexible flat foot therapy, such as the calcaneal stop procedure and the arthrodesis and osteotomy of Evan alone, are performed. In comparison with several of our research we discovered that Evan's osteotomy can only repair the removal from the forefoot and heel valgus does not. It has no effect on the improvement of heel valgus following surgery. [17] Sinus tarsi discomfort is the most common consequence of arthrodesis, sometimes necessitating removal of the implant. To present, there are low quality data available in the literature (Level IV and V), with no strong recommendations provided by just one comparative non-randomised research (Level II). The long-term result and complication rates are still unknown (particularly osteoarthritis). [18] Calcaneal stop is also an excellent choice for FFF therapy but is age-limited as cant be done beyond 13 years of age, while DCO does not. Calcaneo stop surgery is a viable and successful therapeutic option for idiopathic pesplanovalgus with minimal intra and postoperative problems in children below 15 years old.

It also had excellent outcomes in a research by HanyHamed, in 2020

It revealed a substantial increase in the preoperative mean AOFAS score from 56.76 (range: 48-73) to 95.29 (range: 90-100; $p < 0.001$).

Local reactions to an external body showed no indications of inflammation. Meary's median pre-operational talon-first metatarsal angle was 159 degrees and the median post-operative talon-First metatarsal angle was 180 degrees (minimum 168 degrees and maximum 190 degrees). It was improved substantially after surgery ($p < 0,0001$). (19) The lateral column lengthening combinations with the re-enhancing of soft tissue to treat Plano-valgus soc deformity were further studied by Elshafey et al. in 2019. In the final follow-up, it found that the AnkleHindfoot score(AOFAS) improved from 43.45(31-55) preoperatively to 85.52 (68-92) ($P < .001$) with pair t-testing as a meaning test for evaluation or Radiology improving the mean of the lateral talometatarsal angle at last, from $26,9^\circ$ preoperative to $3,96^\circ$, and the mean AP– talonavicular angle improvement at final follow up, from 32° preoperative to $7,21^\circ$ ($P < 0,05$). (20) In our research, the range of motions showed good outcomes. Within 6 months, all our patients recover their complete range of ankle and subtalar joints. The findings were nearly the same compared to other research (Elshafey et al 2019 and HanyHamed et al 2020). (57)(58) In most instances, the VAS score was aggressively improved. Median VAS revealed substantial postoperative [1] decreases compared to preoperative [5]; P-value was 0.001. The Vas Score was not used as a pain reference for most of the other research mentioned. [22, 23]

The angle of Hindfoot valgus showed aggressive improvement in our research. The median angle of the heel valgus was considerable after surgery [5] compared to the preoperative [19]; P-value was <0.001. This finding has been consistent with previous research, even with alternative treatment methods such as subtalararthrosis. In Philip J. Bresnahan1 and Mario A. Juanto 2020 a great improvement in the post-operative heel valgus angle following subtalararthrosis. (59) Within 4 to 6 months after surgery all of the patients returned to their work and sport, which was in compliance with HanyHamed, MD2020 and the research by Philip J. Bresnahan and Mario A. Juanto2020, most patients returned to their regular activities within the same time frame. [24, 25] There were several limitations in our research. In our research, the number of cases were seventeen feet, which was higher than previous studies, and fewer than other studies. In comparison with the HanyMourkus and HariPrem research, 10 cases were carried out. [26] The number of Vincenzo Detal2021 patients in a study consisted of 14 instances, which were also fewer than ours. [27] In our research, the follow-up duration was just six months, which is a short follow-up period unlike previous studies. All patients were evaluated in a study by Vincenzo D etal 2021 after an average follow-up of 7 years and 7 months (from 6 y and 5m to 12 y).[28]

Unlike previous investigations, Vincenzo Detal 2021 was a controlled study, our research was non-randomized. [29]

5. Conclusions

Double calcaneal osteotomy (DCO) is a suitable option for flat-foot patients with high talonavicular coverage angle and hind-foot valgus angle in order to restore the mid-foot and hind-foot line. Flexible flatfoot deformity is a difficult issue for children and teenagers. Double Calcaneal osteotomy is the surgical repair gold standard in this scenario. The primary benefit of aperiarticular osteotomy is that joint function is maintained while structural alignment is enhanced.

DCO showed better outcomes in both pre-foot kidnapping and Valgus heel correction compared to other methods. DCO has minimal complexity and considerable patience.

References

- [1] S. Michael. Lee et al. Diagnosis and Treatment of Adult Flatfoot. *J. of foot & Ankle Surgery*. vol. 1, pp. 44, 2005.
- [2] IT. Chu, MS. Myerson, BG. Parks. Experimental flatfoot model: the contribution of dynamic loading, *J. Foot Ankle Int*. vol. 22, pp. 220 -225, 2001.
- [3] Taghi Baghdadi et al. Evaluation of Clinical and Radiological Results of calcaneal Lengthening osteotomy in pediatrics Idiopathic Flat Foot, *Arch Bone Jt Surg*. vol. 6, pp. 402-411, 2018.
- [4] M. Pfeiffer, R. Kotz, T. Ledi, G. Hauser, M. Sluga. Prevalence of flat foot in preschool aged children *Pediatrics*. Vol. 9, pp. 118, 634, 2006.
- [5] AM. Evan's. The flat-footed child to treat or not to treat: what is the clinician to do. *J Am Podiatr Med Assoc*. vol. 98, pp. 386-93, 2008.
- [6] SE. Yeagerman, MB. Cross, R. Positano, SM. Doyle, Evaluation and treatment of symptomatic pesplanus, *Curr. Opin Pediatr*. Vol. 23, pp. 262-7, 2011.
- [7] S. Necip Yontar, et al. Surgical Treatment Results For Flat Foot in Adolescents, *Acta Orthop. Traumatol Turcica*. vol. 50, pp. 655-659, 2016.
- [8] Stephen Greenfield and Bruce Cohen, Calcaneal Osteotomies Pearls and Pitfalls, *Foot Ankle Clin N*. vol. 22, pp. 563-572, 2017.
- [9] M. Hani and P. Hari. Double calcaneal osteotomy with minimally invasive surgery for the treatment of severe flexible flatfeet, *International Orthopedics*. Vol. 42, pp. 2123-2129, 2018.
- [10] WB. Leadbetter. Cell-matrix response in tendon injury, *Clin Sports Med*. Vol. 78, pp. 11-533, 1992.
- [11] H. Gray. *Anatomy of the Human Body*. P II. Osteology. Vol. 2, pp. 469, 1918.
- [12] EJ. Harris, JV. Vanore, JL. Thomas, et al. Diagnosis and treatment of pediatric flatfoot. *J Foot Ankle Surg*, vol. 43, pp. 341-73, 2004.
- [13] N. Rodriguez, DJ. Choung, MB. Dobbs. Rigid pediatric pes planovalgus: conservative and surgical treatment options, *Clin Podiatr Med Surg*. vol. 27, pp. 79-92, 2010.
- [14] H. Farzin, M. Reza, M. Maryam, A. Ladan. Pediatric Flexible Flatfoot; Clinical Aspects and Algorithmic Approach. *Iran J Pediatr Jun*. vol. 23, pp. 247-260, 2007.
- [15] JC. Adams and H. David. *Outline of Orthopaedics*. 12th Ed. Edinburgh. Churchill Livingstone. vol. 3, pp. 380-383, 1996.
- [16] SL. Weinstein and JA. Buckwalter. *Turek's Orthopaedics. Principles and Their Application*. 5th Ed. Philadelphia. J B Lippincott Company. Vol. 672, pp. 615-635, 1994.
- [17] T. Claire. D. Matthew Gardiner, M. Ann and A. Stefanis. A guide to the management of paediatric pes planus *Australian Journal of General Practice*. vol. 4, pp. 49, 2020.
- [18] AM. Evan's, K. Rome, L. Peet. The foot posture index, ankle lunge test, Beighton scale and the lower limb assessment score in healthy children: a reliability study, *J Foot Ankle Res*. Vol. 5, pp. 2012, 2012.
- [19] VS. Mosca. Flexible flatfoot in children and adolescents. *J Child Orthop*, 4, 107-21, 2010.
- [20] Arya M, et al, Painful Flatfoot in Children and Adolescents: They're Not All the Same, *JPOSNA*. vol. 2, pp. 546, 2020.
- [21] J.B. Carr, S. Yang, L.A. Lather. Pediatric Pes Planus: A State-of-the-Art Review. *Pediatrics*. Vol. 137, pp. 2015-1230, 2016.
- [22] KR. Tileston, A. Griffin, JFM. Wagner, MN. O'day, EJ. Krane. Team Approach: Complex Regional Pain Syndrome in Children and Adolescents, *JBJS Rev*. vol. 8, pp. 174, 2020.
- [23] VS. Mosca. Principles and Management of Pediatric Foot and Ankle Deformities and Malformations. Philadelphia, PA: Wolters Kluwer/Lippincott Williams & Wilkins. Vol. 3, pp. 546, 2014.
- [24] I. Ghanem, et al, Understanding the foot's functional anatomy in physiological and pathological conditions: The calcaneopedal unit concept, *J Child Orthop*. Vol. 13, pp. 134-146, 2019.
- [25] J.R. Denning. Tarsal Coalition in Children, *Pediatr Ann*. Vol. 45, pp. 39-43, 2016.
- [26] JR. Crim, and KM. Kjeldsberg. Radiographic diagnosis of tarsal coalition, *AJR Am J Roentgenol*. Vol. 8, pp. 182: 323, 2004.
- [27] L. Moraleda, SJ. Mubarak. Flexible flatfoot: differences in the relative alignment of each

- segment of the foot between symptomatic and asymptomatic patients. *J PediatrOrthop.* Vol.8, pp. 31, 421, 2011.
- [28] G. Fabry. Clinical practice.Static, axial, and rotational deformities of the lower extremities in children, *Eur J Pediatr.* Vol. 169,pp. 529-34, 2010.
- [29] M. EVAN'S, K. ROMEA. review of the evidence for non-surgical interventions for flexible pediatric flat feet, *EUR J PHYS REHABIL MED.* Vol.47, pp.1-2, 2011.