

## Comparison between Conservative and Surgical Treatment of Base of Fifth Metatarsal Fracture

M.G.Al-Ashhab, A.S.El-Gazzar, A.S.El-Hammady and M.E.Awad-Allah  
Orthopedic Surgery, Dept., Faculty of Medicine, Benha Univ., Benha, Egypt  
E-mail:dr.mostafaezzat@yahoo.com

### Abstract

**Background:** Foot injuries common in emergency rooms include metatarsal fractures. The base of the 5th metatarsal is the most frequent. **Aim:** To compare the clinical and radiological results of conservative therapy versus surgical treatment of the 5th metatarsal bone fracture base. PRISMA standards were used to conduct this electronic literature on four academic databases: the Cochrane Library, Excerpta Medica Database (Embase), and Medline/PubMed. **Methods:** This study found eight trials, involving a total of 405 individuals, 137 were surgically treated and 270 were treated in a non-operational way. Those in the non-operative group showed a substantially greater non-union fracture odds ratio (OR) and reported a protracted period of healing and lengthy time to return to sport. **Results and conclusion:** This systematic review and meta-analysis provides a level of evidence supporting the use of operational interventions to reduce non-union rates, union duration, sporting time, duration for return to normal daily activity and visual analogue scale score compared to non-operative interventions. Operational treatments also improved treatment result as measured by the American orthopaedic foot & ankle scale in order to manage the base fracture of the fifth metatarsal compared with non-operative interventions. Results from current meta-analyses may have a broad impact on the development of orthopaedic emergency recommendations for best practise fracture treatment on the base of the fifth metatarsal.

**Keywords:** Conservative, Surgical, Base, Metatarsal, Fracture.

### 1. Introduction

The basis of the fifth metatarsal fractures is that between tuberosity and the fifth metatarsal bone proximal diaphysis in the foot. Fifth metatarsal fractures are the most frequent metatarsal fractures in children aged 5 years and adults. The fifth metatarsal bone comprises about 45–70% of all metatarsal fractures. This fracture increases in women because of the postmenopausal drop in oestrogen leading to osteoporosis and an increased overall risk of fracture [1].

The radiological evaluation of the 5th metatarsal bone by X-Ray consists of three standard points: the antero-posterior (AP) and the lateral and oblique points of view. In these conventional views, however, some avulsion fractures near the tip of tuberosity may not be seen. If clinical symptoms show a fracture, further AP view of the ankle, including the base of the near fifth metatarsal, should be obtained [2].

Studies utilising MR and computed tomography (CT) imagery subsequently revealed that both structures were probably implicated. The treatment of metatarsal fractures has been the subject of considerable discussion for a long time. Intra-articular, severe malalignment, and load-bearing dysfunction are frequently indicators of closed or open reduction and fixation. [3]

The simultaneous insult to the envelope of the soft tissue in crushed injuries and an open metatarsal fracture is regarded as a unique kind of injury and the restricted covering of local soft tissue has a significant result effect and remains a key problem for foot trauma treatment. While the majority of injuries entail a good prognosis, certain kinds of metatarsal damage such as Lisfranc injury and Jones' fractures are still creating a problem reflected in severe surpluses reported in the literature. [1].

The choice of non-operational treatment should be dependent on the patient and the kind of fracture. A number of non-operational methods include elastic dressing and a stiff shoe, short leg cast, posterior splint and a tolerable hard plastic cast [4].

There are several operational modalities for the handling of proximal five-metar fractures including intra-medullary fastening, corticocancellous bone grafting, closing and cross-sectioning with Kirschner-wire (K-wire) fixation, or open reduction and internal attachment with mini fragment plate and screws. The most frequently described method is to fit intramedullary compression screw with or without bone grafts [5].

This research aims to evaluate the clinical and radiological findings of conservative therapy versus surgical treatment of a fifth metatarsal bone fracture base.

### 2. Subjects and methods

All randomized and non-randomized Comparative studies were included in evaluating both Jones fracture surgery and conservative treatments. These articles were included in papers that reported on the Jones fractures and other metatarsal fractures but only information on the Jones fractures was utilised. Studies that did not compare operative and non-operational techniques, did not intervene immediately with surgery or focused on the fracture of Jones were omitted. The examination did not involve animal and cadaver research. Studies have also been omitted when acute fractures treated conservatively compared to chronic or stress fractures treated with surgery.

From the start until January 2020, the following online databases were searched using a preferred search strategy reporting item for systemic reviews

and meta-Analysis (PRISMA): Cochrane Library, Excerpta Medica Database (Embase). Papers were not restricted because of the language, status of the publication or kind of publishing. In all search boxes the Boolean operations utilised Jones, metatarsal and fracture as keywords. An author examined all titles and abstracts retrieved using the search technique. Potential papers were then examined for a list of eligible studies.

Original interest results included non-union rates, delayed union rates, radiological union time, and kinds and occurrence complications. The secondary measures included sport time and sick leave length. If no clear difference was made between non-union and delayed union as a result, it was regarded as non-union. Time to healing is given in the original research in Table 8.

The search strategies resulted in 483 Cochrane Library results, 3788 Embase results and 3269 Medline/PubMed searches, totaling 7540 articles. The first search screening resulted in 10 studies in the Cochrane Library, 77 in Embase and 145 in Medline/Pubmed having been left with a total of 282 studies. Duplicates have been deleted and 260 have been left. Abstracts of the remaining 260 papers were examined and 45 articles remained following additional screening. These 45 publications were examined, eight of which were considered to meet the criteria for inclusion and exclusion.

### 2.1. Inclusion criteria

- Clinical human studies
- Randomized Control Trials
- English literature only
- Jones fracture type II of base of 5th metatarsal.

### 2.2. Exclusion criteria

- Cadaveric studies.
- Animal studies.
- Open or Pathological Fracture.

- In vitro studies
- Type I and type III fracture base of 5th metatarsal
- Case control, case series and case reports studies.

### 2.3. Statistical analysis

Statistical analysis was carried out using Review Manager (RevMan) Version 5.3 (Copenhagen: The Nordic Cochrane Centre, The Cochrane Collaboration). A chi-squared test and  $I^2$  statistic were used to measure significant heterogeneity. Where significant heterogeneity was found ( $I^2 > 50\%$ ,  $p < 0.05$  from chi-squared test), a random effects model was used instead of a fixed effects model. Because of the zero or low number of non-unions in the surgery group, a Peto odds-ratio method of estimation was used for this analysis.

### 3. Results

A meta-analysis was performed to calculate the pooled odds ratio (OR) of complications after using conservative measures against surgical intervention. This meta-analysis showed none statistically significant difference in the odds of complications in those treated conservatively against those who underwent surgical intervention (33/243 vs. 16/146, OR 0.37, 95% CI [0.08, 1.65],  $P < 0.19$ ,  $I^2 = 70\%$ ). The Forest plot illustrating odds ratio for complications is shown in Fig. (1).

A meta-analysis was performed to calculate the pooled odds ratio (OR) of non-union using conservative measures against surgical intervention. Our meta-analysis showed a statistically significant difference in the odds of non-union in those treated conservatively against those who underwent surgical intervention (30/173 vs. 5/245, OR 0.16, 95% CI [0.07, 0.40],  $P < 0.001$ ,  $I^2 = 0\%$ ). The Forest plot illustrating odds ratio for non-union is shown in Fig. (2).

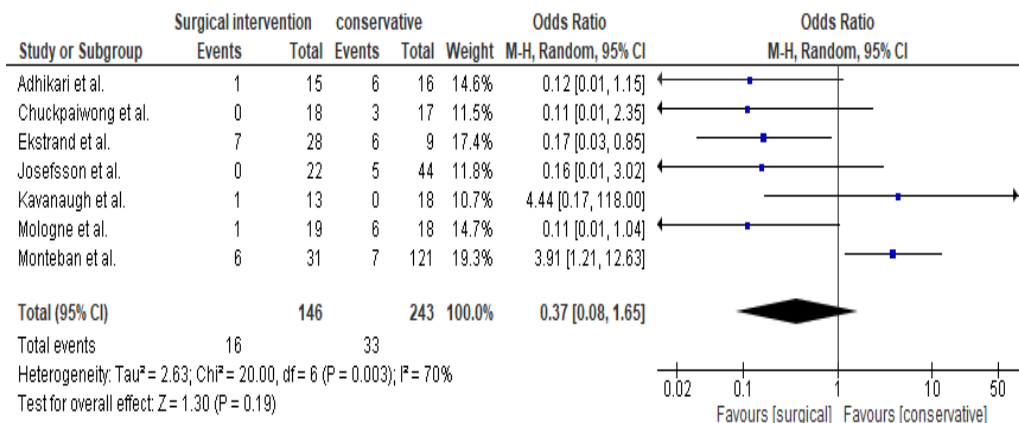


Fig. (1) Meta-analysis of complication rate of the included studies.

The above diagram is the meta-analysis showing that non-union rate is much higher in operative than conservative treatment.

A meta-analysis was performed on time to union using conservative measures against surgical intervention. Our meta-analysis showed a statistically significant difference in time to union in those treated conservatively against those who underwent surgical intervention (OR 0.56, 95% CI 0.27, 0.85], P<0.001, I<sup>2</sup>=98%). shown in Fig. (3).

Figure (4), figure (5) was constructed to evaluate types of bias in the included studies. Randomized trials are not frequent. Selection bias is present in most of the studies. Blinding neither was nor reported in all of included studies. Outcomes are not all present such as Time to union (weeks), Return to sport (weeks), Sick leave (weeks), Satisfaction rate, Return to normal activity (weeks) and Visual analogue pain score. Non-union rate was reported in all of the studies and we've conducted a meta-analysis for it.

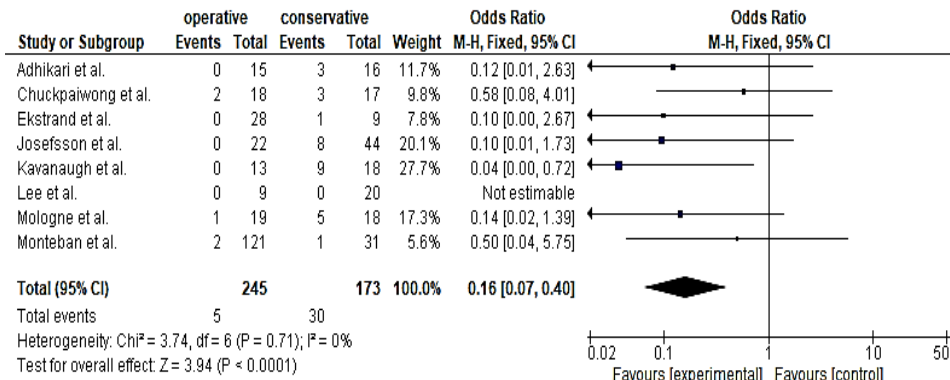


Fig. (2) Meta-analysis for non-union rate.

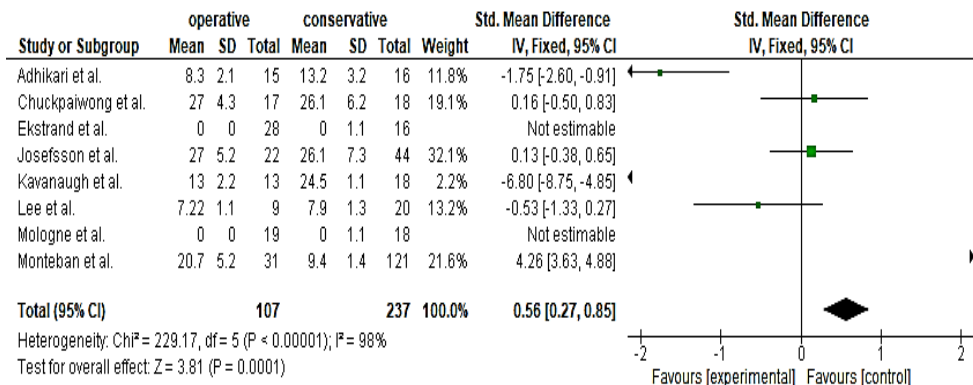


Fig. (3) Meta-analysis for time to union (weeks)

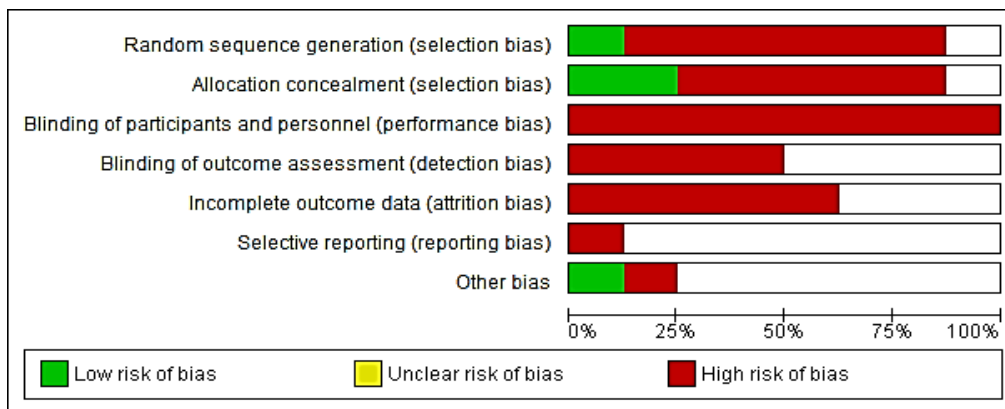


Fig. (4) Risk of bias graph: review authors' judgements about each risk of bias item presented as percentages across all included studies.

Author	Random sequence generation (selection bias)	Allocation concealment (selection bias)	Blinding of participants and personnel (performance bias)	Blinding of outcome assessment (detection bias)	Incomplete outcome data (attrition bias)	Selective reporting (reporting bias)	Other bias
Monteban et al.	●	●	●	●	●		
Moligne et al.	●	●	●	●	●		●
Lee et al.	●	●	●	●	●		
Kavanaugh et al.	●	●	●	●	●		
Josefsson et al.	●	●	●	●	●		
Ekstrand et al.	●	●	●	●	●	●	
Chungkwang et al.	●	●	●	●	●		
Adhikari et al.	●	●	●	●	●		●

Fig. (5) Risk of bias summary: review authors' judgements about each risk of bias item for each included study.

## 5. Discussion

A meta-analysis was conducted to determine the pooled complication odds ratio (OR) when conservative methods were used versus surgery. This meta-analysis did not reveal a statistically significant difference in the chances of complications in conservatively treated individuals vs operators (33/243 versus 16/146, OR 0.37, 95% CI [0.08, 1.65],  $P < 0.19$ ,  $I^2 = 70\%$ ).

A meta-analysis was carried out using conservative methods to determine the non-union pooled odds ratio (OR). Our meta-analysis has shown that the non-union chances are statistically significantly different from those treated in conservatives (30/173 vs. 5/245, OR 0.16, 95% CI [0.07, 0.40], and  $P < 0.001$ ,  $I^2 = 0$  percent).

A time-to-union meta-analysis was conducted using conservative methods versus surgery. Our meta-analysis revealed that there were statistically significant time-to-union difference from the surgeon (OR 0.56, 95% CI 0.27, 0.85],  $P < 0.001$ ,  $I^2 = 98\%$ ).

With Ekstrand & van Dijk, [6]; 0.5% (67) of 13 754 injuries were MT-5 fractures. Its incidence was 0.04 lesions/1000 hours of exposure. Thus, every fifth season a squad of 25 players might anticipate an MT-5 fracture. Of them, 67% (38) were primary fractures and 33% were refractures. One of the 38 main fractures was a tuberosity avulsion; all the others (97 percent) were at the base. Overall, 32% of players with MT-5 fracture were younger than 21 years, 40% of players had pre-season fractures, and 45% of players exhibited prodromal symptoms. In all, 54% of the first X-rays were categorised as Torg Type II (stress fractures) and 46% as Torg Type I. (acute type). After surgery, fractures healed more quickly than conservative therapy (75% vs. 33%,  $p < 0.05$ ). The lay-off days did not vary significantly between operated and unoperated players (80 vs 74 days,  $p = 0.67$ ). Most MT-5 fractures are stress fractures and occur mostly among young athletes. Often healing difficulties are caused by the stress nature of the injury. After surgery, compared to conservative surgery, there are less healing issues.

In Adhikari & Thakur [7], the average follow-up was 12 months (ranges 6-18 months). Six of 16

(37.5%) patients were deemed treatment failure in the cast group (3 nonunion, 3 delayed union.). All individuals undergoing surgery were deemed successful in treating some minor problems. In the operation groups, the median time for clinical union and return to normal activity were 8 and 9 weeks; whereas the median durations for clinical union were 12 and 14, respectively, in the cast group. Early fastening of the screw in a Jones acute fracture leads to faster clinical union and enables patients to resume to regular activities more quickly than cast therapy.

Kavanaugh et al., [8] have also shown that 23 patients have reported an injury initially described by Jones of the proximal portion of the fifth metatarsal diaphysis with 23 fractures. The average monitoring time was 3.5 years. Delayed union occurred in twelve (66.7%) of the eighteen conservatively treated patients. In two weeks after damage, four patients were operated. In nine of the 22, the clinical picture indicated that the injury was a stress fracture. Force-platform analysis showed, in 11 instances, that the damage was produced by vertical and mediolateral forces concentrating on the fifth metatarsal, and is not caused by reversal. Treteen of the 23 fractures were among young athletes, frequently while training and causing considerable impairment. This group of patients and a limited number of recreational athletes and non athletes with delayed union are recommended to repair the fracture with intramedullary screws.

They stress that the Jones fracture in an athlete may be very disabled. Five patients in their study experienced incapacity spells that were lengthy enough to damage their prospects for sports career. They thus recommend rapid fracture fixation in this patient population. The technique is safe and straightforward and we enable early mobility since experience has been acquired. Now they suggest non-weight bearing in a compressive bandage for 10 days as a post operation therapy, followed by tolerance in a cast shoe for the following two to four weeks. Return to sport is permitted six weeks after the operation. They believe that slot-grafting is superior than screw fixation. This procedure needs a prolonged time of non-weight and immobilisation resulting to muscle

and bone atrophy; a failure of this technique occurred in one of their patients [8].

The fifth metatarsal bone is an essential component of the lateral column's longitudinal and transverse arc, which plays a vital function in tamping and keeping the lateral arc. Under Peroneus brevis, fibularis tertius and lateral plantar fascia, anatomical reduction and stability is difficult to accomplish in misplaced avulsion fifth metatarsal base area I. The treatment of the fifth metatarsal base fracture in young people and athletes, especially zone I fracture with moderate displacement, continues to be a contentious subject. Noteworthy, while some specialists describe non-operative therapy as a high patient satisfaction, there is little assessment of the post-operative results of non-operative therapy [9].

The objective of surgical fixing is to speed up healing and rehabilitation, particularly minimum invasive surgery and to reduce the risk of complications compared with non-operative therapy. When the foot has significant trauma, a basic avulsion fracture is readily caused by tendon or ligament tension. If left untreated, serious consequences may occur. Unsuitable therapies may lead to delayed union or nonunion discomfort, peripheral nerve damage, an irregular distribution of plantar pressures that may impair midfoot functioning. The integrity of the fifth metatarsal is important to patients, particularly young people and athletes[10].

Although the fifth metatarsal plays an essential role in the midfoot function, it still remains contentious to deal with the fifth metatarsal base fracture, in particular the Zone I fractures with moderate displacement in young adults and athletes. Rammelt et al. [11] indicated that surgical treatment was essential when the fragment gap was more than 2 mm and the damaged joint surface greater than 30%. Zwitter et al.[12] similarly hold a similar view that surgical treatment was needed if an avulsion fracture of the fifth metatarsal base was comminuted or had substantial (>2 mm) displacement of >30% or more intraarticular fracture. Operational procedure may preserve the fifth metatarsal length and the stability of tendon and ligament insertions. In the meanwhile, surgery may reduce anatomical activity (displacement, angulation, and rotational deformity), enable early rehabilitation and reduce the occurrence of sequelae.

## 6. Conclusion

Our research provides a degree of evidence to encourage the use of operational treatments to decrease non-union rate, length of union activity, duration of return to sports, duration of return to regular daily activities and visual analogue scale in comparison to non-operational interventions.

## References

- [1] N. Romano . “5th metatarsal bone: let’s freshen up! Anatomy and pathology from pediatric to adult age,” vol. 3, pp. 60-74, 2018.
- [2] C.N.Cheung and T. H. Lui, “Proximal fifth metatarsal fractures: anatomy, classification, treatment and complications,” Arch. trauma Res., vol. 5, 99. 44-52, 2016.
- [3] M. Mostafa, O. Abd Allah, and M. Fathey, “Surgical Treatment of Fracture Base of Fifth Metatarsal in Adults,” J Clin Case Rep, vol. 8, pp. 2, 2018.
- [4] J. L. Marsh et al., “Fracture and dislocation classification compendium-2007: Orthopaedic Trauma Association classification, database and outcomes committee,” J. Orthop. Trauma, vol. 21, Suppl, pp. S1-133, 2007.
- [5] F. Kaneko, M. Edama, M. Ikezu, K. Matsuzawa, R. Hirabayashi, and I. Kageyama, “Anatomic characteristics of tissues attached to the fifth metatarsal bone,” Orthop. J. Sport. Med., vol. 8, pp. 2325967120947725, 2020.
- [6] J. Ekstrand and C. N. van Dijk, “Fifth metatarsal fractures among male professional footballers: a potential career-ending disease,” Br. J. Sports Med., vol. 47, pp. 754–758, 2013.
- [7] G. G. B. R. Adhikari and R. Thakur, “Comparative study of early screw fixation versus cast application on the treatment of acute Jones fracture,” Post-Graduate Med. J. NAMS, vol. 10, pp. 33-42, 2010.
- [8] J. H. Kavanaugh, T. D. Brower, and R. V Mann, “The Jones fracture revisited,” JBJS, vol. 60, pp. 776–782, 1978.
- [9] M. K. Shahid, S. Punwar, C. Boulind, and G. Bannister, “Aircast walking boot and below-knee walking cast for avulsion fractures of the base of the fifth metatarsal: a comparative cohort study,” Foot ankle Int., vol. 34, pp. 75–79, 2013.
- [10] G.-B. Wu, B. Li, and Y.-F. Yang, “Comparative study of surgical and conservative treatments for fifth metatarsal base avulsion fractures (type I) in young adults or athletes,” J. Orthop. Surg., vol. 26, pp. 2309499017747128, 2017.
- [11] S. Rammelt, J. Heineck, and H. Zwipp, “Metatarsal fractures,” Injury, vol. 35, pp. SB77-86, 2004.
- [12] E. W. Zwitter and R. S. Breederveld, “Fractures of the fifth metatarsal; diagnosis and treatment,” Injury, vol. 41, pp. 555–562, 2010.