

## ROOT AND ROOT CANAL MORPHOLOGY OF PERMANENT MANDIBULAR ANTERIOR TEETH IN A SAMPLE OF EGYPTIAN POPULATION

Hend El-Messiry\* and Marwa Mohamed Abd ElHameed\*\*

### **ABSTRACT**

**Objectives:** The aim of this work was to study the morphology of root and root canals of permanent mandibular anterior teeth in a sample of the Egyptian population.

**Methods:** A total of 16 permanent mandibular central incisors (I1), 25 permanent mandibular lateral incisors (I2) and 15 permanent mandibular canines (C) were collected and classified into groups according to shape and number of roots. Molds of pink wax with the samples were submitted for cone beam computed tomography (CBCT). The number and shapes of roots were determined and types of root canals were assessed and classified according to Vertucci's classification. Finally, data was statistically analyzed.

**Results:** Regarding the macroscopic appearance of I1, all the samples had one root while I2 had one root with 92%. As for C, 80% of the sample was with one root. CBCT revealed the following configurations, according to Vertucci's classification; Regarding I1, Type I was the most common canal configuration (75%) followed by type II (12.5%) and type III (12.5%) Regarding I2, Type I (60%) was the most common configuration followed by type III (28%). As for C, 66.7% of the sample was represented by type I followed by type III and IV, where each was represented by 13.3%.

**Conclusions:** There are morphological variations in the root and root canal anatomies of the mandibular central incisors, lateral incisors, and canines of Egyptian population as compared to other populations.

**KEYWORD:** Cone beam computed tomography (CBCT); Egyptians; mandibular anterior teeth; root morphology

\* Lecturer, Oral Biology, Faculty of Dentistry, Ain Shams University, Cairo, Egypt.

\*\* Associate Professor, Oral Biology, Faculty of Dentistry, Ain Shams University, Cairo, Egypt

## INTRODUCTION

There are large variations among different populations in dental morphological features. Thus, a trait of the human dentition can be an important diagnostic tool for classifying and characterizing different types of populations <sup>[1]</sup>.

Studying root morphology involves the process of registration, analysis and understanding all the information regarding radicular morphology which categorizes each population <sup>[2]</sup>.

Proper knowledge of the anatomy of root canal systems is a primary prerequisite for a successful endodontic treatment. Inadequate understanding of the root canal anatomy might lead to many problems that might occur during and after root canal treatment <sup>[3]</sup>.

The external and internal anatomy of root canals is a genetically -determined process that implies an important role in Anthropology and may be also affected by environmental conditions leading to variations among different populations <sup>[4]</sup>. So, the aim of this study was to investigate different root and root canal morphologies in permanent mandibular anterior teeth in a sample of Egyptian population.

## MATERIALS AND METHODS

### Preparation of samples

A total of 16 permanent mandibular central incisors (I1), 25 permanent mandibular lateral incisors (I2) and 15 permanent mandibular canines (C) were collected from the department of Oral Surgery, faculty of Dentistry Ain Shams University. Teeth were cleaned and washed to remove any debris. Calculus was removed using hand scalers then the teeth were stored in glass containers containing 10% formalin solution until experimentation <sup>[5]</sup>.

### Number of roots was classified into:

- One root
- Two roots

Thick rectangular molds were made using pink wax to hold our samples. Samples were embedded in the pink wax and aligned in rows leaving 0.5 cm space between them.

### Scanning technique

Molds were then submitted for Cone Beam Computed Tomography (CBCT) scan, CBCT images were acquired using i-CAT next generation device.

The machine was operating with tube voltage of 120 kilovoltage peak, 37.07 milliamperes and voxel size of 0.2 mm for 26.9 seconds with field of view of 8 cm height and 8 cm diameter. Data was exported, transferred in i-CAT format and downloaded via a compact disk to a personal computer for linear measurements. After importing i-CAT data into the software, data was ensured to be contained at the captured field of view.

### Image evaluation

CBCT images were then examined and evaluated types of root canals were categorized according to Vertucci's classification <sup>[6]</sup>.

- Type I: A single canal which is present from the pulp chamber to the apex.
- Type II: Two separate canals leaving the pulp chamber, but joining to form one canal to the site of exiting.
- Type III: One canal leaving the pulp chamber, dividing into two within the root, and then merging to exit as one canal.
- Type IV: Two separate and distinct canals extending from the pulp chamber to the apex.
- Type V: Single canal leaving the pulp chamber but then dividing into two separate canals exiting through two separate apical foramina.

CBCT images were evaluated continuously by moving the toolbar from the floor of the pulp chamber to the apex and drawing a line passing along each root canal in every anterior tooth to determine the types of root canals.

**RESULTS**

Recorded data was analyzed using the statistical package for social sciences, version 20.0 (SPSS Inc., Chicago, Illinois, USA). Qualitative data was expressed as frequency and percentage.

**The following tests were done:**

- ← Chi-square ( $\chi^2$ ) test of significance was used in order to compare proportions between qualitative parameters.
- ← The confidence interval was set to 95% and the margin of error accepted was set to 5%. So, the p-value was considered significant as the following:
- ← Probability (P-value)
  - P-value  $\leq 0.05$  was considered significant.
  - P-value  $\leq 0.001$  was considered as highly significant.
  - P-value  $> 0.05$  was considered insignificant.

**Number of roots**

Regarding the macroscopic appearance of I1, all the samples had one root (100%) (Table 1), while I2 had one root with 92% and two roots with 8% one buccal and one lingual (Table (1) and (fig. 1). As for C, 80% of the sample was with one root and 20 % showed two roots, one buccal and one lingual (Table 1) and (fig. 1). Chi-square ( $\chi^2$ ) test showed no statistical significant difference between I1, I2 and C regarding number of roots as shown in table (1) and (fig. 2).

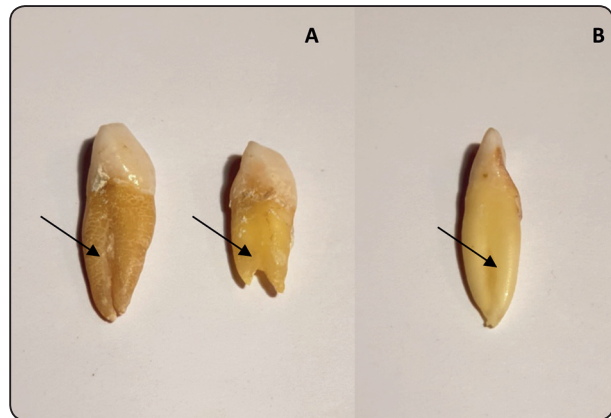


Fig. (1) (A) A photograph showing C with two roots (arrow). (B) A photograph of I2 showing two roots (arrow).

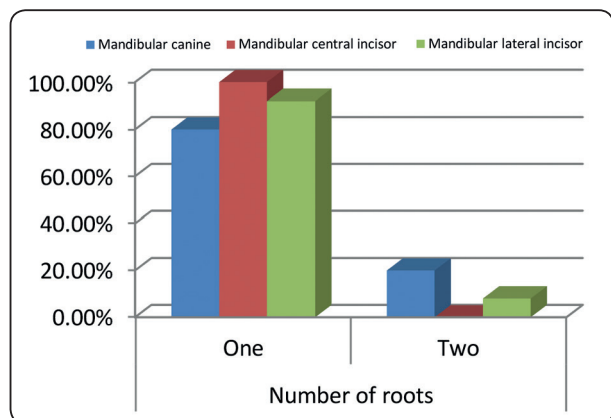


Fig. (2) Bar chart comparing between I1 and I2 and C regarding number of roots.

**Root canal morphology**

CBCT revealed the following configurations, according to Vertucci’s classification. Regarding I1, Type I was the most common canal configuration (75%) followed by type II (12.5%) and type III (12.5%) (Table 2) and (fig. 3). While the I2, Type I (60%) was the most common configuration followed by type III (28%) then type II (12%) (Table 2) and (fig. 3). As for C, 66.7% of the sample was represented by type I, 13.3% was represented by type III, 13.3% was represented by IV and 6.7% was represented by type V (Table 2) and (fig. 4) Chi-square ( $\chi^2$ ) test showed no statistical significant difference between I1, I2 and C regarding root canal morphology which is represented in (Table 2) and (fig. 5)

TABLE (1) Number of roots in permanent mandibular central incisor (I1), permanent mandibular lateral incisor (I2) and permanent mandibular canine group (C). Comparison between I1, I2 and C regarding number of roots.

Number of roots	Mandibular canine		Mandibular central incisor		Mandibular lateral incisor		Total	
	No.	%	No.	%	No.	%	No.	%
1.00	12	80.0%	16	100.0%	23	92.0%	51	91.1%
2.00	3	20.0%	0	0.0%	2	8.0%	5	8.9%
Total	15	100.0%	16	100.0%	25	100.0%	56	100.0%
Chi-square test	3.856							
p-value	0.145							

*p-value>0.05 NS: Non significant*

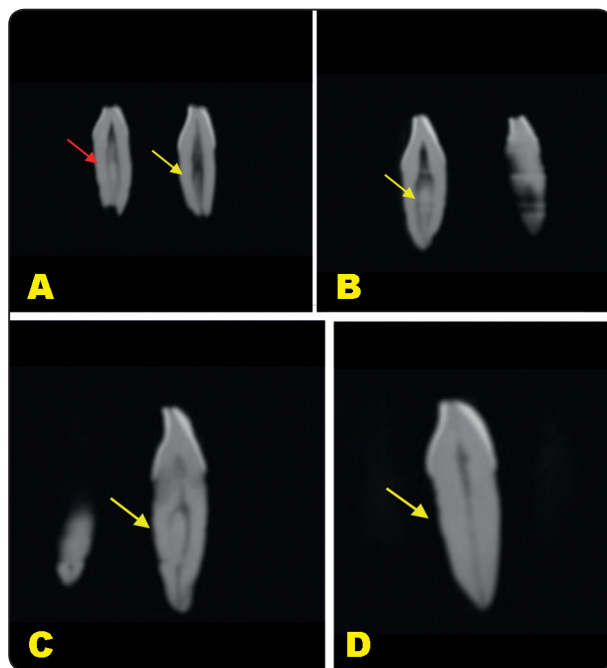


Fig. (3) (A) Cone beam computed tomography (CBCT) showing I1 with type I (yellow arrow) and type II (red arrow) root canal configuration, (B) CBCT showing I2 with type II (yellow arrow) root canal configuration, (C) CBCT showing I2 with type III (yellow arrow) root canal configuration, (D) CBCT showing I2 with type I (yellow arrow) root canal configuration.

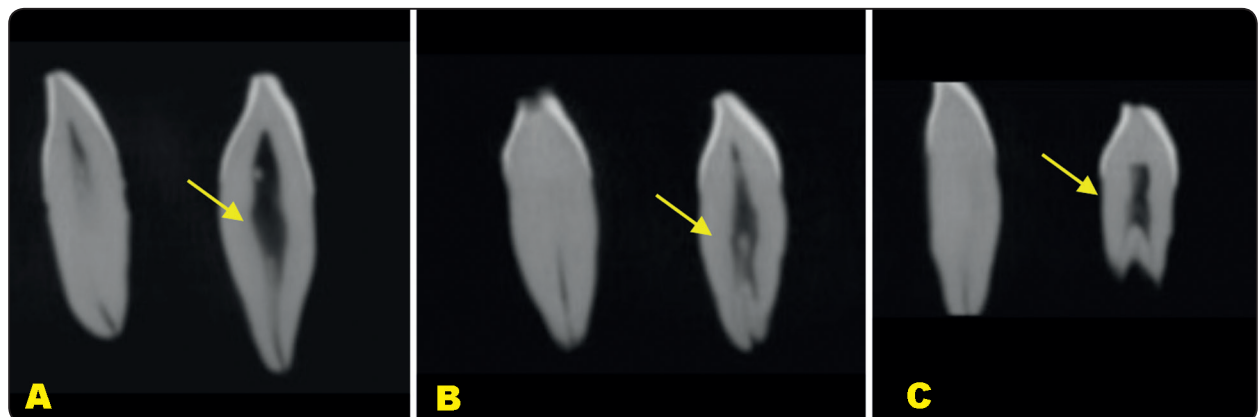


Fig. 4 (A) Cone beam computed tomography (CBCT) showing C with type I (yellow arrow) root canal configuration, (B) CBCT showing C with type IV (yellow arrow) root canal configuration, (C) CBCT showing C with type V (yellow arrow) root canal configuration.

TABLE (2) Root canal morphology of permanent mandibular central incisor (I1), permanent mandibular lateral incisor (I2) and permanent mandibular canine (C). Comparison between I1, I2 and C regarding root canal morphology.

Root Canal Morphology	C		I1		I2		Total	
	No.	%	No.	%	No.	%	No.	%
I	10	66.7%	12	75.0%	15	60.0%	37	66.1%
II	0	0.0%	2	12.5%	3	12.0%	5	8.9%
III	2	13.3%	2	12.5%	7	28.0%	11	19.6%
IV	2	13.3%	0	0.0%	0	0.0%	2	3.6%
V	1	6.7%	0	0.0%	0	0.0%	1	1.8%
Total	15	100.0%	16	100.0%	25	100.0%	56	100.0%
Chi-square test	11.974							
p-value	0.152							

*p-value>0.05 NS: Non significant*

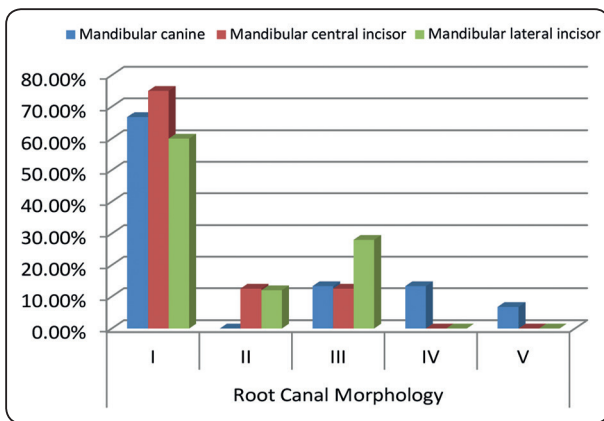


Fig. (5) Bar chart comparing between I1 and I2 and C regarding

**DISCUSSION**

The root and root canal morphology of human teeth has always charmed the dentists, lack of awareness what to expect once access preparation is done. The number and varied morphology of the root and root canals always position a challenge to the operator during endodontic treatment which sometimes results in a missed infected canal or an unfilled canal [7]. Thus, the operators must be

provided with a strong database on the occurrence and prevalence of various root canal anatomic variations in the respective teeth according to racial or genetic characteristics. This sure will aid in their successful management during canal preparation and obturation [8].

Root canal anatomy pattern linked to various racial and genetic factors has encouraged researchers to study root canal pattern of teeth in the Caucasians, the Indians, the Burmese, the Japanese, the Chinese, and the Thais [9, 10].

This study aimed to investigate the root canal morphology of mandibular incisors and canines in a sample of Egyptian teeth and inspect any variation in order to properly understand the root canal anatomy in these teeth which would eventually help the operator to perform and deliver a better quality of endodontic therapy.

Cone beam computed tomography (CBCT) was used here to properly examine the root canal configuration. CBCT scans allow the identification of anatomic features [11]. Two-dimensional images such as periapical radiographs do not allow accurate

measurement and could be distorted depending on the angle between the tooth and the film. Panoramic radiographs may show vertical magnification and they are also sensitive to patient positioning, even under optimal conditions <sup>[12]</sup>.

Our results revealed that the prevalence of two roots in permanent mandibular anteriors was 8% in I2 and 20% in C. However, I1 was not encountered for this in our population samples.

Similarly, accessory roots have been reported in mandibular anterior teeth that seem to exhibit more complex anatomical variations than their maxillary counterparts. These have been identified in different population groups using different techniques such as staining and clearing <sup>[13,14]</sup>; microcomputed tomography <sup>[15,16]</sup> as well as clinical investigations using CBCT <sup>[17]</sup>.

Unlike our findings, Han et al. 2014<sup>[17]</sup> found that all incisors had one root and 1.32% of the canines had two roots in Chinese population. Also, Singh and Pawar in 2014<sup>[10]</sup> documented that the examined mandibular anterior teeth in South Asian Indian population by using the clearing technique were all single rooted. Two-rooted mandibular canines have been documented in several investigations <sup>[18, 19]</sup> which may have three canals <sup>[20]</sup>. The occurrence of two roots in mandibular incisors has also been reported <sup>[21, 22]</sup>.

The examined CBCT in the current work revealed that the prevalence of type I root canal configuration predominating in all examined teeth (I1:75%, I2: 60%, C:66.7%).

However the frequency of occurrence of type II was 12.5% in central incisors, 12% in lateral incisors and 0% in canines. On the other hand, type III was 12.5% in central incisors, 28% in lateral incisors and 13.3% in canines. According to our statistical results, the majority of examined teeth showed 66.1% type I and 19.6% type III. This was in accordance with Milanezi de Almeida et al. 2013<sup>[15]</sup> who revealed that type I and III canal configurations

represent 92% of the mandibular incisors studied in sample of Brazilian population.

Type IV configuration accounts for 13.3% in the currently examined lower canines, while type V accounts for only 6.7% in same teeth category. Investigated mandibular incisors did not show any of these configuration types. This was opposite to what had been reported by Versiani et al. 2011 and Han et al. 2014 <sup>[23, 17]</sup> which were; root canal configuration types IV and V are the most common accessory anatomical variations in single-rooted mandibular anteriors in Brazilian and Chinese populations respectively.

## CONCLUSIONS

It is worthy to note that there are variations in the root and root canal morphology of the permanent mandibular central incisors, lateral incisors, and canines in a sample of Egyptian teeth as compared to other races. From the results of this study, it could be hypothesized that the mandibular canines had a higher prevalence of two roots followed by the mandibular lateral incisors then the central ones. Further research on inter-racial anatomical characteristics from different geographical locations would be beneficial for a comparative study.

Modern diagnostic devices, recent endodontic (and periodontal) techniques and current advances in endodontic biomaterials could cover the way for high levels of success in managing such anatomical variations in the human anterior dentition.

## ACKNOWLEDGEMENTS

None.

## Compliance with ethical standered

### Human rights statements and informed consent/ Animal rights statements

This article does not contain any studies with human or animal subjects performed by the any of the authors.



### Conflict of Interest

Author Hend El-Messiry and Author Marwa Abd El-Hameed declare that they have no conflict of interest

### REFERENCES

- King NM, Tsai JS, Wong HM. Morphological and numerical characteristics of the Southern Chinese dentitions. Part II: Traits in the permanent dentition. *Open Anthropol J.* 2010;3:71–84.
- Marcovich I, Prado E, Díaz P, Ortiz Y, Martínez C, Moreno F. Dental morphology analysis of Afro-Colombian school children from Villa Rica, Cauca, Colombia. *Rev Fac Odontol Univ Antioq.* 2012; 24 (1):37–61.
- Boruah LC, Bhuyan AC. Morphologic characteristics of root canal of mandibular incisors in North-East Indian population: An in vitro study. *J ConservDent.* 2011; 14(4):346–350.
- Silva EJ, Nejam Y, Silva AV, Haiter-Neto F, Cohenca N. Evaluation of Root Canal Configuration of Mandibular Molars in a Brazilian Population by Using Cone-beam Computed Tomography: An In Vivo Study. *J Endod.* 2013; 39(7):849–852.
- Gulabivala K, Aung TH, Alavi A, Ng, YL. Root and canal morphology of Burmese mandibular molars. *International Endodontic Journal.* 2001;34(5):359–370.
- Vertucci FJ. Root canal anatomy of the human permanent teeth. *Oral Surgery Oral medicine and Oral Pathology.* 1984;58:589–99.
- Vertucci FJ. Root canal morphology and its relationship to endodontic procedures. *Endod Topics.* 2005;10:3–29.
- Singh S, Pawar M. Root and canal morphology of mandibular incisors and canines in South Asian Indian population by canal staining and tooth clearing technique. *Endodontology.* 2016; 28(2):148–53.
- Singh S, Pawar M. Root canal morphology of South Asian Indian mandibular premolar teeth. *J Endod.* 2014;40: 1338–41.
- Singh S, Pawar M. Root canal morphology of South Asian Indian maxillary molar teeth. *Eur J Dent.* 2015;9:133–44.
- Mukhaimer RH. Evaluation of Root Canal Configuration of Mandibular First Molars in a Palestinian Population by Using Cone-Beam Computed Tomography: An Ex Vivo Study. *International Scholarly Research Notices.* 2014;2014:583621.
- Lund H, Gröndahl K, Gröndahl HG. Cone beam computed tomography for assessment of root length and marginal bone level during orthodontic treatment. *Angle Orthod.* 2010;80:466–473.
- Sert S, Bayirli GS. Evaluation of the root canal configurations of the mandibular and maxillary permanent teeth by gender in the Turkish population. *Journal of Endodontics.* 2004;30: 391–8.
- Sert S, Aslanalp V, Tanalp J. Investigation of the root canal configurations of mandibular permanent teeth in the Turkish population. *International Endodontic Journal.* 2004;37: 494–9.
- Milanezi de Almeida M, Bernardineli N, Ordinola-Zapata R. Micro-computed tomography analysis of the root canal anatomy and prevalence of oval canals in mandibular incisors. *Journal of Endodontics.* 2013;39: 1529–33.
- Leoni GB, Versiani MA, Pecora JD, Damiao de Sousa-Neto M. Micro-computed tomographic analysis of the root canal morphology of mandibular incisors. *Journal of Endodontics.* 2014;40: 710–6.
- Han T, Ma Y, Yang L, Chen X, Zhang X, Wang Y. A study of the root canal morphology of mandibular anterior teeth using cone-beam computed tomography in a Chinese sub-population. *Journal of Endodontics.* 2014;40(9):1309–14.
- Sharma R, Pecora JD, Lumley PJ, Walmsley AD. The external and internal anatomy of human mandibular canine teeth with two roots. *Endodontics and Dental Traumatology.* 1998;14: 88–92.
- Mikrogeorgis G, Lyroudia KL, Nikopoulos N, Pitas I, Molyvdas I, Lambrianidis TH. 3D computer-aided reconstruction of six teeth with morphological abnormalities. *International Endodontic Journal.* 1999; 32: 88–93.
- Heling I, Gottlieb-Dadon I, Chandler NP. Mandibular canine with two roots and three root canals. *Endodontics and Dental Traumatology.* 1995;11:301–2.
- Kocsis GS, Marcsik A. Accessory root formation on a lower medial incisor. *Oral Surgery Oral Medicine Oral Pathology.* 1989;68:644–5.
- Loushine RJ, Jurcak JJ, Jeffalone DM. A two-rooted mandibular incisor. *Journal of Endodontics.* 1993;19:250–1.
- Versiani MA, Pecora JD, Sousa-Neto MD. The anatomy of two-rooted mandibular canines determined using micro-computed tomography. *International Endodontic Journal.* 2011;44:682–687.