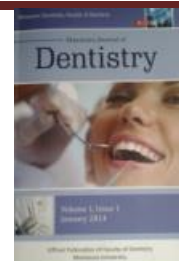



The Efficacy of a Magnetic Resonance Imaging in characterization of parotid tumors



Ghady A.A.Sheta¹, Bassant H.Mowafy², Islam A El zahaby³, Ahmed A Abdel Razek⁴

¹Teaching Assistant, Oral Medicine and Periodontology, Faculty of Dentistry, Mansoura Univ.

²Assistant Professor of, Oral Medicine and Periodontology, Faculty of Dentistry, Mansoura Univ

³Assistant Professor of surgical oncology, Faculty of Medicine, Mansoura Univ..

⁴Professor of Diagnostic Radiology, Faculty of Medicine, Mansoura Univ.

Abstract:

Objectives: Magnetic Resonance Imaging is a valuable technique for the assessment of parotid tumors. This study was designed to investigate the role of conventional MRI in the diagnosis of parotid tumors.

Methods: Twenty four patients were included in this study, they presented with pain and swelling in the region of the parotid gland. All patients were subjected to conventional MRI examination. The results were statistically analysed by using chi-square test.

Results: It was found that there was statistically significant difference between benign parotid tumors and malignant parotid neoplasms regarding signal intensity on T2, tumor margin and infiltration into surrounding tissue.

Conclusions: MRI remains the superior imaging modality for characterization of the parotid tumors. It is sensitive in detection of parotid abnormalities.

Keywords: MRI, parotid tumors.

Introduction

Salivary gland tumors form approximately 2-5% of head and neck tumors^{1,2}. Nearly 80% of salivary gland tumors occur in parotid glands. Parotid gland neoplasms include a various group subtypes³. Precise distinction among neoplastic and benignity is significant in planning therapeutic strategy and estimation of condition prognosis⁴.

It is also significant to assure if neoplasm is intra or extra glandular and also superficial or deep to determine operative lines; so, by radiological methods aim not only in determining surgery but help in assessing additional probable relapses and catastrophes⁵.

There are many radiological methods like ultrasound, computed tomography, magnetic resonance imaging and SPECT for assessment of salivary gland neoplasms⁶. MRI is the most dependable tool to determine if tumors are benign or neoplastic. MRI also still the most favorable radiological method for staging salivary gland neoplasm due to its precious soft tissue contrast & its excellent representation at different planes and superior anatomic presentation. represents the key for evaluation of neoplasm site⁷.

High-resolution multiplanar turbo spin-echo (TSE) T1, T2 and post contrast (Gadolinium) images with fat saturation (FS) represents the key for evaluation of neoplasm site⁸.

MATERIALS AND METHODS

We prospectively estimated MRI features of twenty four patients having pain and swelling in the region of

parotid, with an age ranged from twenty nine to sixty three years with an average age of forty six year. There were fifteen females and nine males. All patients were subjected to conventional MRI examination.

Our Neck MRI exam included the following sequences: Axial T1 turbo spin echo (TSE) without Fat suppression, Axial T2 Turbo-spin echo without fat suppression, and Coronal T2 sequence with fat suppression.

The MRI features included (lesion margin well defined or ill defined, signal intensity hypo intense or hyperintense on T1, T2, homogeneity of tumors, infiltration into surrounding tissue and enhancement of the neoplasm).

Lesion with major dimension was selected for analysis. Image analysis was done via two radiologists (reader one: with seven years; reader two: two years of experience in Head & Neck radiology) that are unaware of pathological report and research design.

Statistical Analysis: the resulting data will be statistically analysed by using χ^2 test. The significance level will be set at P value less than 0.05.

RESULTS

This prospective study was conducted on 24 patients complaining of parotid tumors. Patients were referred Oncology Center of Mansoura University and Mansoura University Hospitals. Those patients underwent conventional weighted MRI examination of the parotid masses and MRI characteristics were evaluated for all cases. Two radiologists evaluated the MRI features to establish a consensus

Table (1): The different pathologic groups of the parotid tumors of the studied patients.

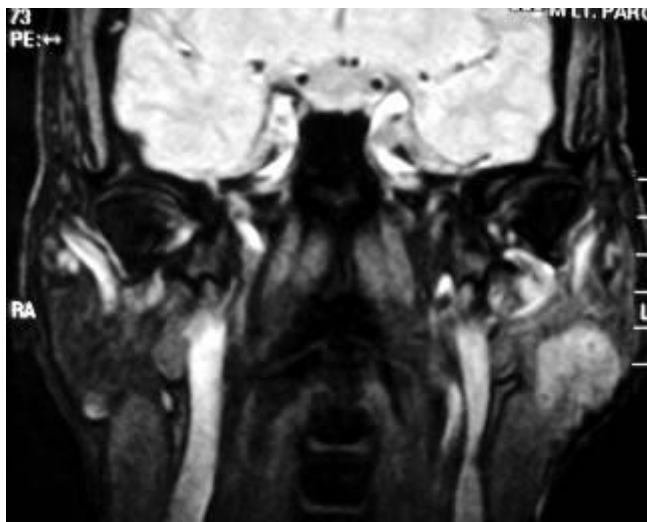
	Histopathology	No. of Patient 24	% 100
I)Benign Tumors	No.19		79.1%
	Pleomorphic adenoma	11	45.8%
	Warthin tumor	7	29.1%
	oncocytoma	1	4.1%
II)Malignant tumors	No. 5		20.8%
	Mucoepidermoid carcinoma	3	12.5%
	Adenoid cystic carcinoma	2	8.3%
Total No.		24	100%

Table 2 Comparison between benign and malignant tumors regarding conventional MRI findings

MRI characters	Benign n=19	malignant n=5	Significance
Margin definition of MRI			
• Well defined	19(100%)	1(20%)	P<0.02*
• Ill defined	0	4(80%)	
T2 intensity on MRI			
• high	16(84.2%)	0	P< 0.03*
• mixed	3(15.7%)	1(20%)	
• low	0	4(80%)	
Infiltration of surrounding			
• +ve	0	5(100%)	P<0.001*
• -ve	19(100%)	0	

Regarding T2, signal intensity sixteen out of nineteen benign lesions showed high SI with the remaining three lesions showed mixed SI and from five malignant lesions, four lesions showed low SI, only one lesion showed mixed SI. There was statistically significant difference between benign and malignant lesions with $P < 0.03$.

Case 1 Female aged 63 year with LT parotid mass Pathological assessment show PA



DISCUSSION:-

Parotid neoplasms involve different varieties of benign and malignant subtypes. Precise discrepancy among malignancy and benignity is essential in planning of management processes and estimation of disorder outcome⁹.

MRI is essential within diagnosis and assessment of different disorders within clinical practice due to benefits of many soft-tissue contrasts and nonexistence of ionizing radiation. In parotid neoplasms, MRI can identify tumor site and spread, and relation among neoplasm and CNVII¹⁰.

The present study included twenty four patients who were classified into nineteen benign parotid tumors (representing 79.1%) and five malignant tumors (representing 20.8%) and this was in agreement with **Zajkowski, (2000)** who stated that 70-80% of tumors of salivary glands are benign¹¹.

In the present study, all nineteen benign lesions in our study had well defined margin and four out of five malignant lesions had ill-defined margin. There was statistically significant difference between benign and malignant lesions regarding signal intensity on T2 and margin definition. These results were in agreement with **Christe et al., (2011)** and **Xu et al., (2013)** who strongly suggested that a sharp margin was associated with a benign tumor^{12,13}. Similar results reported by **Ikeda et al., (2004)** who found 11 out of 17 malignant tumors showed partially unclear or invasive margins on all MR images¹⁴. Our results were in contrast to **Freling et al. (1992)** who reported that signal intensity and tumor margin were not valuable factors to predict benign or malignant disease¹⁵.

Infiltration into deep structures was observed only in patients with malignant tumors. None of the benign tumors had infiltrative margins. Our study revealed statistically

significant difference between benign and malignant tumors regarding tumor infiltration into surrounding tissues.

CONCLUSIONS:-

Therefore, it can be concluded that, MRI is the best imaging diagnostic modality for characterization of the parotid tumors.

References

- Assili S, Fathi Kazerooni A, Aghaghazvini L, Saligheh Rad HR, Pirayesh Islamian J.** Dynamic Contrast Magnetic Resonance Imaging (DCE-MRI) and Diffusion Weighted MR Imaging (DWI) for Differentiation between Benign and Malignant Salivary Gland Tumors. *J Biomed Phys Eng*, 2015; 5: 157–68.
- Lee WH, Tseng TM, Hsu HT, Lee FP, Hung SH, Chen PY.** Salivary gland tumors: A 20-year review of clinical diagnostic accuracy at a single center. *Oncol Lett*, 2014; 7:583-7.
- El-Naggar AK.** WHO classification of tumors of salivary glands. In: El-Naggar AK, Chan JKC, Grandis JR, Takata T, Sliotweg PJ (eds) WHO classification of head and neck tumours, 4th edn. IARC, Lyon, 2017; p 160.
- Takumi K, Fukukura Y, Hakamada H, Ideue J, Kumagae Y, Yoshiura T.** Value of diffusion tensor imaging in differentiating malignant from benign parotid gland tumors. *Eur J Radiol*, 2017; 95:249–256.
- Behrooz Davachi, Mahrokh Imanimoghaddam, Mohamad Reza Majidi, Ahmad Sahebalam, Masoomeh Johari, Adineh Javadian Langaroodi et al.** Imaging Findings of Salivary Gland Tumors. *J Dent Res Dent Clin Dent Prospect*, 2014; 8(4) 246-251.
- Abdel Razek AA, Ashmalla GA, Gaballa G, Nada N.** Pilot study of ultrasound. *Parotid Imaging Reporting and Data System*

(PIRADS): inter-observer agreement. *Eur J Radiol*, 2015; 84:2533- 2538.

7. **Celebi I, Mahmutoglu AS.** Early results of real-time qualitative sono elastography in the evaluation of parotid gland masses: a study with histopathological correlation. *Acta Radiol*, 2013; 54:35- 41.

8. **Kato H, Kanematsu M, Watanabe H, Mizuta K, Aoki M.** Salivary gland tumors of the parotid gland: CT and MRI imaging findings with emphasis on intratumoral cystic components. *Neuroradiology*, 2014; 56:789–95.

9. **Antony J, Gopalan V, Smith RA, Lam AK.** Carcinoma ex pleomorphic adenoma: a comprehensive review of clinical, pathological and molecular data. *Antony J Head and Neck Pathol*, 2012.

10. **Yerli H, Aydin E, Haberal N, Harman A, Kaskati T, Alibek S.** Diagnosing common parotid tumours with magnetic resonance imaging including diffusion-weighted imaging vs fine-needle aspiration cytology: a comparative study. *Dentomaxillofac Radiol*, 2010; 39: 349-55.

11. **Zajkowski P, Jakubowski W, Bialek EJ, Wysocki M, Osmólski A, Serafin-Król M.** Pleomorphic Adenoma and Adenolymphoma in Ultrasonography. *Eur J Ultrasound*, 2000; 12(1): 23-29.

12. **Christe A, Waldherr C, Hallett R, et al. Imaging of Parotid Tumors: Typical Lesion Characteristics in MR Imaging Improve Discrimination between Benign and Malignant Disease.** *Am J Neuroradiol*, 2011; 32:1202- 1207.

13. **Xu ZF, Yong F, Yu T, et al.** Different histological subtypes of parotid gland tumors: CT findings and diagnostic strategy. *World J Radiol* 2013; 5: 313-320.

14. **Ikeda M, Motoori K, Hanazawa T, et al.** Warthin tumor of the parotid gland: diagnostic value of MR imaging with histopathologic correlation. *AJNR Am J Neuroradiol*, 2004;25:1256–1262.

15. **Freling NJ, Molenaar WM, Vermey A, et al.** Malignant parotid tumors: clinical use of MR imaging and histologic correlation. *Radiology* , 1992; 185: 691-696.