

## Use of Multislice CT in Evaluation of Different Grades of COVID 19 Patients in Addition to Correlation with Serum Ferritin Level: A Cross Sectional Study

MENNATALLAH ELSAYED, M.D.\* and MENNATALLAH ELAGUIZY, M.D.\*\*

*The Departements of Radiodiganosis\* and Chemical Pathology\*\*, Kasr Al-Aini Hospital, Cairo University*

### Abstract

**Background:** During the worldwide COVID 19 pandemic, both labs and Computed tomography play an important role as prognostic factors for disease severity. Ferritin, the cellular protein storage for iron, is an indicator for systemic inflammation and computed tomography shows characteristic pulmonary changes in COVID 19 patients.

**Aim of Study:** The target of this study is to assess the role of Ferritin and computed tomography in evaluation of mild, moderate and severe COVID 19 patients and to correlate between ferritin level, CT findings and disease severity.

**Patients and Methods:** Between first of July till end of September 2020, 75 patients (21 males and 54 females) with PCR confirmed COVID-19 infection from Cairo, Egypt, were referred for laboratory and multislice computed tomographic assessment.

**Results:** The most prominent radiological findings in moderate and severe cases were ground glass opacities (54.2% and 89.5%), lung nodules (54.2% and 52.6%) and reticular pattern (37.5% and 52.6%) respectively. Some imaging features like ground glass opacities, interlobular septal thickening and pleural effusion with elevated ferritin levels were shown to correlate with disease severity.

**Conclusion:** Computed tomography and serum ferritin levels have a significant role in evaluation and assessment of severity of patients with COVID 19.

**Key Words:** COVID 19 patients – Serum ferritin level – Multislice CT.

### Introduction

**STARTING** December 2019, some cases of “unknown viral pneumonia” were recorded in Wuhan City, Hubei Province, China [1]. A novel coronavirus (SARS-CoV-2) was doubted to be the cause [2]. In just two months, the virus has spread from Wuhan to the whole China, and another 33 countries [3]. In this epidemic, reverse transcription

**Correspondence to:** Dr. Mennatallah Elsayed, The Departement of Radiodiganosis, Kasr Al-Aini Hospital, Cairo University

polymerase chain reaction showed the causative agent of this outbreak. The SARS-CoV-2 could be detected in secretions of respiratory tract or plasma samples [4]. However, nucleic acid detection is influenced by factors such as lack of kits, patients' immunity, disease status, and slow test reporting, which may complicate the diagnostic process [5].

Chest high-resolution computed tomography (HRCT) is a very important method for evaluation of lung abnormalities. It plays a very important role in the screening of suspicious cases, the diagnosis and differential diagnosis of diseased patients, classification and triage of cases, evaluation of disease progression, identification of pulmonary complications, and follow-up after discharge of patients [5]. The conducted researches revealed multiple scattered patchy areas of consolidation and ground-glass opacity (GGO) on chest X-ray and computed tomography in COVID 19 patients [6]. Chest radiographs have low sensitivity for pneumonia. Also chest radiographs can hardly distinguish pneumonia caused by COVID 19 virus from pneumonia caused by other coronaviruses [7]. In addition, the disease caused by COVID 19 virus progresses rapidly and the symptoms of this disease show a large variation. That is why, it is very crucial to interpret the chest CT findings that complicate this disease in order to insure proper application of the timely isolation of the patients, respiratory care, and early application of infection prevention and control plan [4].

### List of Abbreviations:

CT	: Computed tomography.
COVID-19	: Coronavirus disease 2019.
RT-PCR	: Real time polymerase chain reaction.
SARS	: Severe acute respiratory syndrome.
MERS	: Middle East respiratory syndrome.
Kda	: Kilodalton.

Data obtained from reports provided by health policy agencies, allows dividing the COVID-19 patients into mild, moderate and severe cases [8]. Some laboratory features, particularly lymphopenia and elevated D-dimer, have been shown to correlate with an unfavorable outcome [9]. The potential role of anti-inflammatory drugs in the treatment of critical COVID-19 patients was noted [10]. It has been well-established that elevated serum ferritin levels may suggest not only the presence of an iron overload state, but is also a marker of inflammatory, autoimmune, infectious or malignant conditions [11]. Ferritin is a large protein (440 kDa) present within the cytosol, or less often, within the mitochondria of the cell, and it can sequester up to approximately 4500 atoms of iron [12]. Due to its crucial role in cellular iron homeostasis, it is not surprising that ferritin synthesis is tightly regulated [13]. In a preliminary cross-sectional study, conducted by Dahan et al., elevated ferritin levels were shown to be associated with a more severe disease in 39 patients from Israel with confirmed COVID-19 infection [14].

*Aim of study:* The target of this study was to systematically analyze the CT findings of the COVID 19 patients and to evaluate the association between ferritin level, CT findings and disease severity in COVID-19, hoping to find a novel prognostic marker that would predict the clinical outcomes in ill patients.

### Patients and Methods

#### Patients:

This is a cross-sectional study. Data regarding 75 patients (21 males and 54 females) with confirmed COVID-19 infection was obtained from multiple private radiological centers. Their age range is from 21 to 70 (mean age of 43.4 years  $\pm$  15.6 SD). Confirmed cases of COVID-19 were defined as a positive result on polymerase-chain-reaction (PCR) assay of nasal and pharyngeal swab specimens. They were all referred to laboratory assessment and multislice CT assessment of the chest. These patients were reviewed between first of July till end of September 2020. Written consent was obtained from all patients. Ethical approval was waived because of the retrospective nature of the study.

#### Inclusion criteria:

Mild, moderate and severe laboratory proven PCR positive COVID 19 patients. The degree of severity of COVID-19 at the time of admission was specified using the Diagnosis and Treatment Protocol for Novel Coronavirus Pneumonia (Trial

Version 7), Released by National Health Commission & State Administration of Traditional Chinese Medicine on March 3, 2020 [15].

- 1- Mild cases: The clinical symptoms were mild (flu like symptoms, which may include dry cough and mild fever which may not reach 38.7 degrees), and there was no evidence of pneumonia on imaging evaluation.
- 2- Moderate cases: Showing fever and respiratory symptoms with radiological evidence of pneumonia.
- 3- Severe disease: Adult cases meeting any of the following criteria:
  - Respiratory distress ( $\geq 30$  breaths/min);
  - Oxygen saturation  $\leq 93\%$  at rest;
  - Arterial partial pressure of oxygen (PaO<sub>2</sub>)/fraction of inspired oxygen (FiO<sub>2</sub>)  $\leq 300$  mmHg (1 mmHg = 0.133 kPa).

#### Exclusion criteria:

Critical disease, which was defined as respiratory failure, septic shock, and/or multiple organ dysfunction/failure.

#### Methods:

All patients were subjected to the following:

- History taking.
- Laboratory assessments at initial hospital visit consisted of WBCs count, Lymphocyte count, Percent lymphocyte (relative), Neutrophilic count, Percent monocyte, Hemoglobin, ALT, AST, Creatine kinase total, CRP, D-dimer and Serum Ferritin.

#### Acquisition of CT data:

All patients underwent non-contrast CT scanning on multislice computed tomography set of the thorax in the supine position during end-inspiration, 80-120kVp, automated tube current modulation, mA ranges from 60 to 120, rotate time 0.5 s, pitch 0.984:1, a slice thickness of 1mm (some differences according to the machine types).

#### Analysis of CT data:

In this study, we analyzed CT images showing ground glass opacity, consolidation, ground glass opacity with consolidation, nodules, cavitation, reticular pattern, crazy-paving, peribronchial thickening, subpleural lines, and fibrosis of pulmonary parenchyma. The appearance, distribution, and size of these computed tomographic findings were assessed in all patients. Also, the presence of thoracic lymph nodes enlargement (lymph node measures larger than or equal to 10mm in the short-axis dimension) and pleural effusion or thickening

was assessed. The distribution of radiological findings was classified as central (affecting the inner two-thirds of the lung), peripheral (affecting the outer third of the lung) or diffuse (affecting multiple lung segments), in a way similar to the work done by Ooi GC et al., [16]. The CT score, a semiquantitative method, was applied to evaluate the extent of COVID-19 according to previous studies done by Ooi GC et al. and Chang YC et al., [16,17]. We started by assessing the extent of the lesions in each lobe and a score of zero (none), one (affecting less than 5% of the lobe), two (affecting 5-25% of the lobe), three (affecting 26-49% of the lobe), four (affecting 50-75% of the lobe), or five (affecting more than 75% of the lobe) was set. This was followed by calculation of the CT score by summation of the scores of the five lobes. A CT score from 0 to 25 was applied for each patient. All CTscans were reviewed and assessed by a single chest radiologist.

#### *Statistical analysis:*

Data was entered and statistically analyzed on the Statistical Package of Social Science Software program, version 25 (IBM SPSS Statistics for Windows, Version 25.0. Armonk, NY: IBM Corp.). Data was presented using mean, standard deviation, median and interquartile range for quantitative variables and frequency and percentage for qualitative ones. Comparison between groups for qualitative variables was performed using Chi square or Fisher's exact tests while for quantitative variables the comparison was conducted using Kruskal Wallis test. *p*-values less than or equal to 0.05 were considered statistically significant.

## **Results**

#### *Demographic data, exposure history and symptoms of the study population:*

We obtained data regarding 75 patients (21 males and 54 females) with confirmed COVID-19 infection. Their age range is from 21 to 70 (mean age of 43.4 years  $\pm$  15.6 SD). 69 patients (92%) had a history of previous exposure to known cases of COVID 19 patients. 57 patients (76%) had obvious symptoms (Table 1).

#### *Laboratory tests and severity in patients with COVID-19 disease:*

In this study, 32 patients were considered as mild cases, 24 patients were considered as moderate cases and 19 patients were considered as severe cases.

White blood cell count was reduced in 5.3% of patients. Relative lymphopenia was noted in 30.7%

of patients. C-reactive protein, D-dimer and Ferritin levels were increased in 34.7, 30.7 and 42.7 percent of patients respectively (Tables 2,5).

#### *CT findings in patients with moderate and severe COVID-19 (41 patients):*

The CT feature are detailed in Tables (3,4). Mild cases of COVID 19 included in this study did not show radiological evidence of pneumonia. 46.9% of mild cases showed no radiological CT findings, 25% of them showed lung nodules and 28.1% showed subpleural curvilinear lines. The most prominent radiological findings in moderate and severe cases were ground glass opacities (54.2% and 89.5%), lung nodules (54.2% and 52.6%) and reticular pattern (37.5% and 52.6%) respectively.

Ground glass opacity, Consolidation, Ground glass opacity associated with consolidation, Crazy paving, Air bronchogram, Bronchial wall thickening, Subpleural curvilinear line, Thoracic lymphadenopathy, Pleural effusion or thickening and Pulmonary fibrosis were significantly more prominent in severe patients compared to moderate patients with COVID 19.

Concerning the lesions size, 12 patient (20.7%) had lesions with a measurement larger than 5cm; 8 patients had lesions with a measurement of 3-4.9cm (13.8%); 15 patients had lesions with a measurement of 1-2.9cm (25.9%); and 23 patients had lesions with a measurement less than 1 cm (39.7%). Lesion size was significantly higher in severe compared to mild and moderate cases (*p*-value: 0.000).

Concerning the distribution of CT findings, Bilateral lung involvement was noted in 72.4% of cases. Lesions that were located in both the central and peripheral lung zones accounted for 29.3% and lesions located in the peripheral lung were present in (70.7.5%) of patients. No lesions were located in the central lung.

Regarding the CT score, 55 (73.3%) patients had CT scores in the range of 0-5; 5 (6.7%) patients had CT scores of 6-10, 4 patients (5.3%) had CT score of 11-15 and 11 patients (14.7%) had a CT score higher than 15. 87.5% of patients with moderate disease had a CT score of 0-5 while 57.9% of severe cases had a CT score of more than 15.

#### *Ferritin levels by COVID severity:*

Description of ferritin range, mean and standard deviation with comparison between mild, moderate and severe groups were detailed in Tables (2,5). The mean ferritin level of the entire study sample

was 1701.7ng/ml ± 3013.2 SD, with a range starting from 7.1ng/ml and toping at 10048ng/ml. Patients with mild disease had a lower ferritin level with a mean of 59.3ng/ml ± 59.3 SD. Patients in the moderate group had a mean of 184.3ng/ml ± 174.8 SD. Patients in severe group had a mean level of 6384.6±2503.4 SD. Increased ferritin level was positively associated with severity of COVID 19. Out of 32 patients with mild COVID 19 infection, 2 patient had increased ferritin level (6.3%). Out of 24 patients with moderate COVID 19 infection, 11 patients had an increased ferritin level (45.8%). All of the 19 patients with severe COVID 19 had increased serum ferritin level.

Table (1): Demographic data, exposure history and symptoms of the study population.

	Description (n=75)
<b>Gender:</b>	
Male	21 (28)
Female	54 (72)
<b>Age (years):</b>	
Range	21 -70
Mean ± SD	43.4±15.6
Median (IQR)	43 (28-56)
Exposure history	69 (92)
<b>Symptoms:</b>	
Obvious symptoms	57 (76)
Fever	38 (50.7)
Cough	23 (30.7)
Expectoration	15 (20)
Fatigue	21 (28)
Shortness of breath	34 (45.3)
Sore throat	14 (18.7)
Muscle soreness	36 (48)
Headache	15 (20)
Nausea and or vomiting	7 (9.3)
Diarrhea	12 (16)
No obvious symptoms	18 (24)

Table (2): Severity and laboratory tests in COVID 19 patients.

	Description (n=75)
<b>COVID-19 Severity:</b>	
Mild	32 (42.7)
Moderate	24 (32)
Severe	19 (25.3)
<b>WBCs count:</b>	
Range	3.2-12.3
Mean ± SD	6.8±2.3
Median (IQR)	6 (5.4-7.5)
<b>Lymphocyte count:</b>	
Range	0.6-4.6
Mean ± SD	1.8±1.1
Median (IQR)	1.4 (0.9-2.1)
<b>Percent lymphocyte relative:</b>	
Range	6.3-69.8
Mean ± SD	28.3±16.7
Median (IQR)	25.6 (8.3-41)
<b>Neutrophilic count:</b>	
Range	1.1-9.6
Mean ± SD	4.5±1.8
Median (IQR)	4.6 (3.7-5.6)

Table (2): Count.

	Description (n=75)
<b>Percent monocyte:</b>	
Range	0.3-12.1
Mean ± SD	6.1±2.1
Median (IQR)	5.8 (5-6.9)
<b>Hemoglobin:</b>	
Range	9.5-15.8
Mean ± SD	12.5±1.6
Median (IQR)	12.1 (11.4-13.4)
<b>ALT:</b>	
Range	8-90.2
Mean ± SD	38.1±21
Median (IQR)	36 (22-48)
<b>AST:</b>	
Range	12-60.2
Mean ± SD	29.5±12.2
Median (IQR)	28 (19-40.1)
<b>Creatine kinase total:</b>	
Range	55-150.2
Mean ± SD	91.6±29.7
Median (IQR)	100 (55-120.5)
<b>CRP:</b>	
Range	0.3-70.8
Mean ± SD	18±24.4
Median (IQR)	5.4 (1-48.9)
<b>D-dimer:</b>	
Range	0-5.2
Mean ± SD	1.1±1.6
Median (IQR)	0.5 (0.2-2.1)
<b>Serum Ferritin:</b>	
Range	7.1-10048
Mean ± SD	1701.7±3013.2
Median (IQR)	136.6 (23.3-2817)
<b>WBCs count:</b>	
Increased	10 (13.3)
Decreased	4 (5.3)
Normal	61 (81.3)
<b>Lymphocyte count:</b>	
Increased	9 (12)
Decreased	21 (28)
Normal	45 (60)
<b>Percent lymphocyte (relative):</b>	
Increased	10 (13.3)
Decreased	23 (30.7)
Normal	42 (56)
<b>Neutrophilic count:</b>	
Increased	6 (8)
Decreased	6 (8)
Normal	63 (84)
<b>Percent monocyte:</b>	
Increased	0 (0)
Decreased	2 (2.7)
Normal	73 (97.3)
<b>Hemoglobin:</b>	
Increased	4 (5.3)
Decreased	36 (48)
Normal	35 (46.7)
<b>ALT:</b>	
Increased	23 (30.7)
Decreased	0 (0)
Normal	52 (69.3)

Table (2): Count.

	Description (n=75)
<b>AST:</b>	
Increased	19 (25.3)
Decreased	0 (0)
Normal	56 (74.7)
<b>Creatine kinase total:</b>	
Increased	0 (0)
Decreased	0 (0)
Normal	75 (100)
<b>CRP:</b>	
Increased	26 (34.7)
Decreased	0 (0)
Normal	49 (65.3)
<b>D-dimer:</b>	
Increased	23 (30.7)
Decreased	0 (0)
Normal	52 (69.3)
<b>Serum Ferritin:</b>	
Increased	32 (42.7)
Decreased	16 (21.3)
Normal	27 (36)

SD = Standard deviation.

IQR = Interquartile range (range between 25th & 75th percentiles).

Table (3): CT findings in mild, moderate and severe COVID 19 cases.

	Description (n=75)
<b>CT FINDINGS:</b>	
Yes	58 (77.3)
No	17 (22.7)
<b>Laterality (n=58):</b>	
Unilateral	16 (27.6)
Bilateral	42 (72.4)
Ground glass opacity	30 (40)
Consolidation	8 (10.7)
Ground glass opacity and consolidation	11 (14.7)
Reticular pattern	19 (25.3)
Nodule	31 (41.3)
Cavitation	0 (0)
Crazy paving	13 (17.3)
Air bronchogram	11 (14.7)
Bronchial wall thickening	9 (12)
Subpleural curvilinear line	29 (38.7)
Thoracic lymphadenopathy	5 (6.7)
Pleural effusion or thickening	5 (6.7)
Pulmonary fibrosis	19 (25.3)
<b>Maximum diameter of lesion (cm) (n=58):</b>	
<1 cm	23 (39.7)
1-2.9 cm	15 (25.9)
3-4.9 cm	8 (13.8)
>5 cm	12 (20.7)
<b>Distribution (n=58):</b>	
Central	0 (0)
Peripheral	41 (70.7)
Central and Peripheral	17 (29.3)
<b>CT score:</b>	
0-5	55 (73.3)
6-10	5 (6.7)
11-15	4 (5.3)
>15	11 (14.7)

Table (4): Comparison between CT findings in mild, moderate and severe COVID 19 cases.

	COVID-19 Severity			p <sup>-</sup> value
	Mild (n=32)	Moderate (n=24)	Severe (n=19)	
<b>CT FINDINGS:</b>				
Yes	17 (53.1)	24 (100)	17 (89.5)	<b>0.000</b>
No	15 (46.9)	0 (0)	2 (10.5)	
<b>Laterality:</b>				
Unilateral	(52.9)	5 (20.8)	2 (11.8)	<b>0.017</b>
Bilateral	(47.1)	19 (79.2)	15 (88.2)	
Ground glass opacity	(0)	13 (54.2)	17 (89.5)	<b>0.000</b>
Consolidation	(0)	0 (0)	8 (42.1)	<b>0.000</b>
Ground glass opacity and consolidation	(0)	3 (12.5)	8 (42.1)	<b>0.000</b>
Reticular pattern	(0)	9 (37.5)	10 (52.6)	<b>0.000</b>
Nodule	(25)	13 (54.2)	10 (52.6)	<b>0.046</b>
Cavitation	(0)	0 (0)	0 (0)	-
Crazy paving	(0)	0 (0)	13 (68.4)	<b>0.000</b>
Air bronchogram	(0)	3 (12.5)	8 (42.1)	<b>0.000</b>
Bronchial wall thickening	(0)	2 (8.3)	7 (36.8)	<b>0.000</b>
Subpleural curvilinear line	(28.1)	7 (29.2)	13 (68.4)	<b>0.009</b>
Thoracic lymphadenopathy	(0)	0 (0)	5 (26.3)	<b>0.000</b>
Pleural effusion or thickening	(0)	0 (0)	5 (26.3)	<b>0.000</b>
Pulmonary fibrosis	(0)	6 (25)	13 (68.4)	<b>0.000</b>
<b>Maximum diameter of lesion (cm):</b>				
<1 cm	17 (100)	6 (25)	0 (0)	<b>0.000</b>
1-2.9 cm	0 (0)	13 (54.2)	2 (11.8)	
3-4.9 cm	0 (0)	3 (12.5)	5 (29.4)	
>5 cm	0 (0)	2 (8.3)	10 (58.8)	
<b>Distribution:</b>				
Central	0 (0)	0 (0)	0 (0)	<b>0.000</b>
Peripheral	17 (100)	20 (83.3)	4 (23.5)	
Central and Peripheral	0 (0)	4 (16.7)	13 (76.5)	
<b>CT score:</b>				
0-5	32 (100)	21 (87.5)	2 (10.5)	<b>0.000</b>
6-10	0 (0)	3 (12.5)	2 (10.5)	
11-15	0 (0)	0 (0)	4 (21.1)	
>15	0 (0)	0 (0)	11 (57.9)	

Table (5): Comparison between mild, moderate and severe covid 19 cases regarding their demographic data, exposure history, symptoms and laboratory findings.

	COVID-19 Severity			p <sup>-</sup> value
	Mild (n=32)	Moderate (n=24)	Severe (n=19)	
<b>Gender:</b>				
Male	10 (31.3)	2 (8.3)	9 (47.4)	<b>0.016</b>
Female	22 (68.8)	22 (91.7)	10 (52.6)	
<b>Age (years):</b>				
Range	21-67	21-56	55-70	<b>0.000</b>
Mean ± SD	32.9±10.9	41.8±11	63.1±5.3	
Median (IQR)	27.5 (27-34)	43 (33-51.5)	63 (60-68)	
Exposure history	30 (93.8)	20 (83.3)	19 (100)	0.120
<b>Symptoms:</b>				
Obvious symptoms	24 (75)	14 (58.3)	19 (100)	<b>0.006</b>
Fever	16 (50)	6 (25)	16 (84.2)	<b>0.001</b>
Cough	2 (6.3)	2 (8.3)	19 (100)	<b>0.000</b>
Expectoration	0 (0)	0 (0)	15 (78.9)	<b>0.000</b>
Fatigue	0 (0)	2 (8.3)	19 (100)	<b>0.000</b>
Shortness of breath	14 (43.8)	5 (20.8)	15 (78.9)	<b>0.001</b>
Sore throat	2 (6.3)	3 (12.5)	9 (47.4)	<b>0.001</b>
Muscle soreness	16 (50)	9 (37.5)	11 (57.9)	0.395
Headache	6 (18.8)	2 (8.3)	7 (36.8)	0.066
Nausea and or vomiting	0 (0)	0 (0)	7 (36.8)	<b>0.000</b>
Diarrhea	4 (12.5)	4 (16.7)	4 (21.1)	0.719
No obvious symptoms	8 (25)	10 (41.7)	0 (0)	<b>0.006</b>

Table (5): Count.

	COVID-19 Severity			<i>p</i> -value
	Mild (n=32)	Moderate (n=24)	Severe (n=19)	
<i>WBCs count:</i>				
Range	3.2-11	4.6-11	3.9-12.3	<b>0.000</b>
Mean ± SD	5.9±1.8	7.9±2.2	6.8±2.6	
Median (IQR)	5.4 (5.3-6)	7.4 (6.2-11)	6 (5.6-7.3)	
<i>Lymphocyte count:</i>				
Range	0.9-2.5	1.2-4.6	0.6-1.2	<b>0.000</b>
Mean ± SD	1.6±0.4	2.9±1.4	0.8±0.2	
Median (IQR)	1.4 (1.4-1.8)	2.3 (1.7-4.5)	0.7 (0.7-0.9)	
<i>% lymphocyte relative:</i>				
Range	8-53.9	26.3-69.8	6.3-9	<b>0.000</b>
Mean ± SD	31.2±12.9	40.7±12.6	7.8±0.8	
Median (IQR)	25.6 (25.6-43.6)	41 (30-47.2)	8.2 (7.2-8.3)	
<i>Neutrophilic count:</i>				
Range	1.1-9.6	1.3-8.7	3.8-8.5	<b>0.000</b>
Mean ± SD	3.9±1.9	4.7±1.6	5.5±1.6	
Median (IQR)	3.7 (3.2-4.3)	4.9 (4.4-5.6)	5.1 (4.1-7.1)	
<i>Percent monocyte:</i>				
Range	0.3-12.1	0.3-9.1	5.8-8	0.078
Mean ± SD	6±2.6	5.9±2	6.5±0.7	
Median (IQR)	5 (5-7.8)	5.8 (5.7-6.9)	5.9 (5.8-6.9)	
<i>Hemoglobin:</i>				
Range	11.4-15.6	11-15.8	9.5-13.4	<b>0.018</b>
Mean ± SD	12.9±1.5	12.9±1.6	11.4±1.3	
Median (IQR)	12.8 (11.4-14.6)	12.5 (12.1-13.5)	11.5 (10.2-12.2)	
<i>ALT:</i>				
Range	8-48	8-37	41.5-90.2	<b>0.000</b>
Mean ± SD	26.8±10.6	29.6±10.2	68±15.1	
Median (IQR)	32 (17.5-32)	36 (22-36.5)	67.2 (60.2-80.3)	
<i>AST:</i>				
Range	12-32	13-37	40.1-60.2	<b>0.000</b>
Mean ± SD	21.7±5.3	25.6±5.9	47.7±6.4	
Median (IQR)	23 (18-23)	28 (19-28)	46.1 (43.3-50.3)	
<i>Creatine kinase total:</i>				
Range	55-102	55-102	120.5-150.2	<b>0.000</b>
Mean ± SD	69±19	91±18.3	130.5±9	
Median (IQR)	55 (55-88.5)	100 (89-102)	127.3 (125.1-132.5)	
<i>CRP:</i>				
Range	0.4-13.1	0.3-48.3	48.9-70.8	<b>0.000</b>
Mean ± SD	4.1±3	5±10.2	57.8±7.8	
Median (IQR)	4.7 (1.7-5.4)	1 (0.3-5.4)	58.3 (50.2-65.7)	
<i>D-dimer:</i>				
Range	0-0.6	0.1-0.7	2.1-5.2	<b>0.000</b>
Mean ± SD	0.4±0.2	0.3±0.2	3.6±1.2	
Median (IQR)	0.5 (0.2-0.5)	0.2 (0.1-0.4)	3.2 (2.3-5.1)	
<i>Serum Ferritin:</i>				
Range	9.1-181	7.1-435.2	2817-10048	<b>0.000</b>
Mean ± SD	59.3±59.3	184.3±174.8	6384.6±2503.4	
Median (IQR)	46.2 (9.1-85.3)	143 (24.7-435.2)	6918 (4205-9345)	
<i>WBCs count:</i>				
Increased	0 (0)	7 (29.2)	3 (15.8)	<b>0.005</b>
Decreased	4 (12.5)	0 (0)	0 (0)	
Normal	28 (87.5)	17 (70.8)	16 (84.2)	
<i>Lymphocyte count:</i>				
Increased	0 (0)	9 (37.5)	0 (0)	<b>0.000</b>
Decreased	2 (6.3)	0 (0)	19 (100)	
Normal	30 (93.8)	15 (62.5)	0 (0)	
<i>% lymphocyte (relative):</i>				
Increased	4 (12.5)	6 (25)	0 (0)	<b>0.000</b>
Decreased	4 (12.5)	0 (0)	19 (100)	
Normal	24 (75)	18 (75)	0 (0)	

Table (5): Count.

	COVID-19 Severity			p-value
	Mild (n=32)	Moderate (n=24)	Severe (n=19)	
<b>Neutrophilic count:</b>				
Increased	2 (6.3)	1 (4.2)	3 (15.8)	0.354
Decreased	4 (12.5)	2 (8.3)	0 (0)	
Normal	26 (81.3)	21 (87.5)	16 (84.2)	
<b>Percent monocyte:</b>				
Increased	0 (0)	0 (0)	0 (0)	0.251
Decreased	2 (6.3)	0 (0)	0 (0)	
Normal	30 (93.8)	24 (100)	19 (100)	
<b>Hemoglobin:</b>				
Increased	4 (12.5)	0 (0)	0 (0)	<b>0.047</b>
Decreased	16 (50)	14 (58.3)	6 (31.6)	
Normal	12 (37.5)	10 (41.7)	13 (68.4)	
<b>ALT:</b>				
Increased	2 (6.3)	2 (8.3)	19 (100)	<b>0.000</b>
Decreased	0 (0)	0 (0)	0 (0)	
Normal	30 (93.8)	22 (91.7)	0 (0)	
<b>AST:</b>				
Increased	0 (0)	0 (0)	19 (100)	<b>0.000</b>
Decreased	0 (0)	0 (0)	0 (0)	
Normal	32 (100)	24 (100)	0 (0)	
<b>Creatine kinase total:</b>				
Increased	0 (0)	0 (0)	0 (0)	-
Decreased	0 (0)	0 (0)	0 (0)	
Normal	32 (100)	24 (100)	19 (100)	
<b>CRP:</b>				
Increased	2 (6.3)	5 (20.8)	19 (100)	<b>0.000</b>
Decreased	0 (0)	0 (0)	0 (0)	
Normal	30 (93.8)	19 (79.2)	0 (0)	
<b>D-dimer:</b>				
Increased	2 (6.3)	2 (8.3)	19 (100)	<b>0.000</b>
Decreased	0 (0)	0 (0)	0 (0)	
Normal	30 (93.8)	22 (91.7)	0 (0)	
<b>Serum Ferritin:</b>				
Increased	2 (6.3)	11 (45.8)	19 (100)	<b>0.000</b>
Decreased	14 (43.8)	2 (8.3)	0 (0)	
Normal	16 (50)	11 (45.8)	0 (0)	

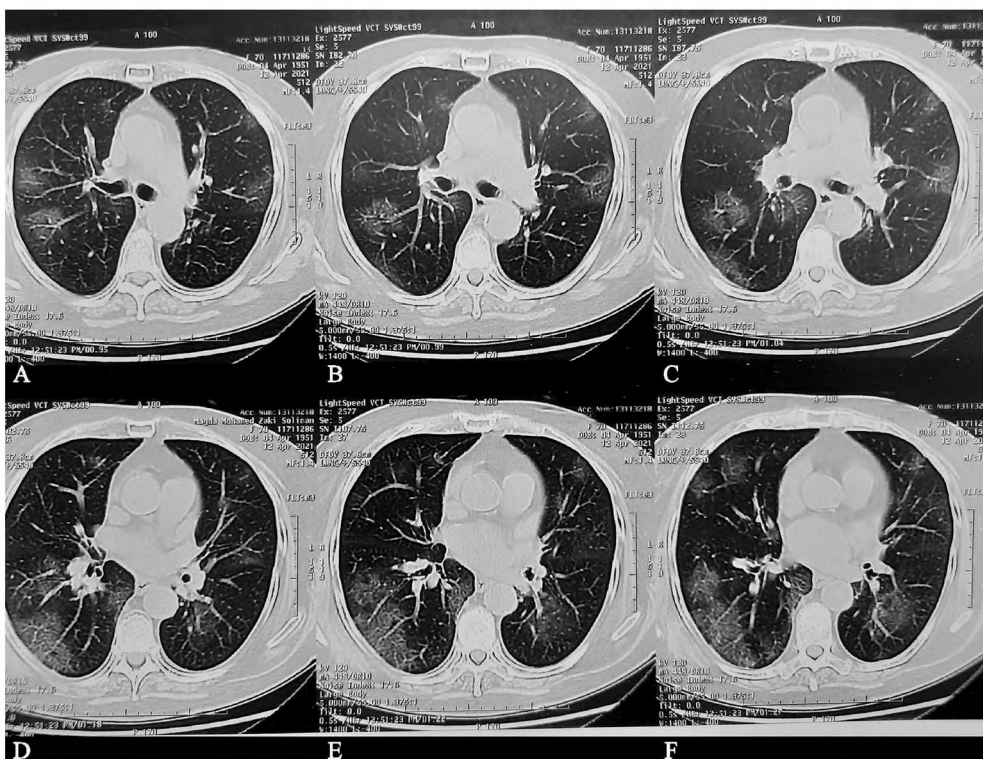


Fig. (1A,B,C,E,F): Showing initial CT of a 71 year old female patient with moderate COVID 19 infection illustrating bilateral subpleural ground glass opacities with vascular thickening.

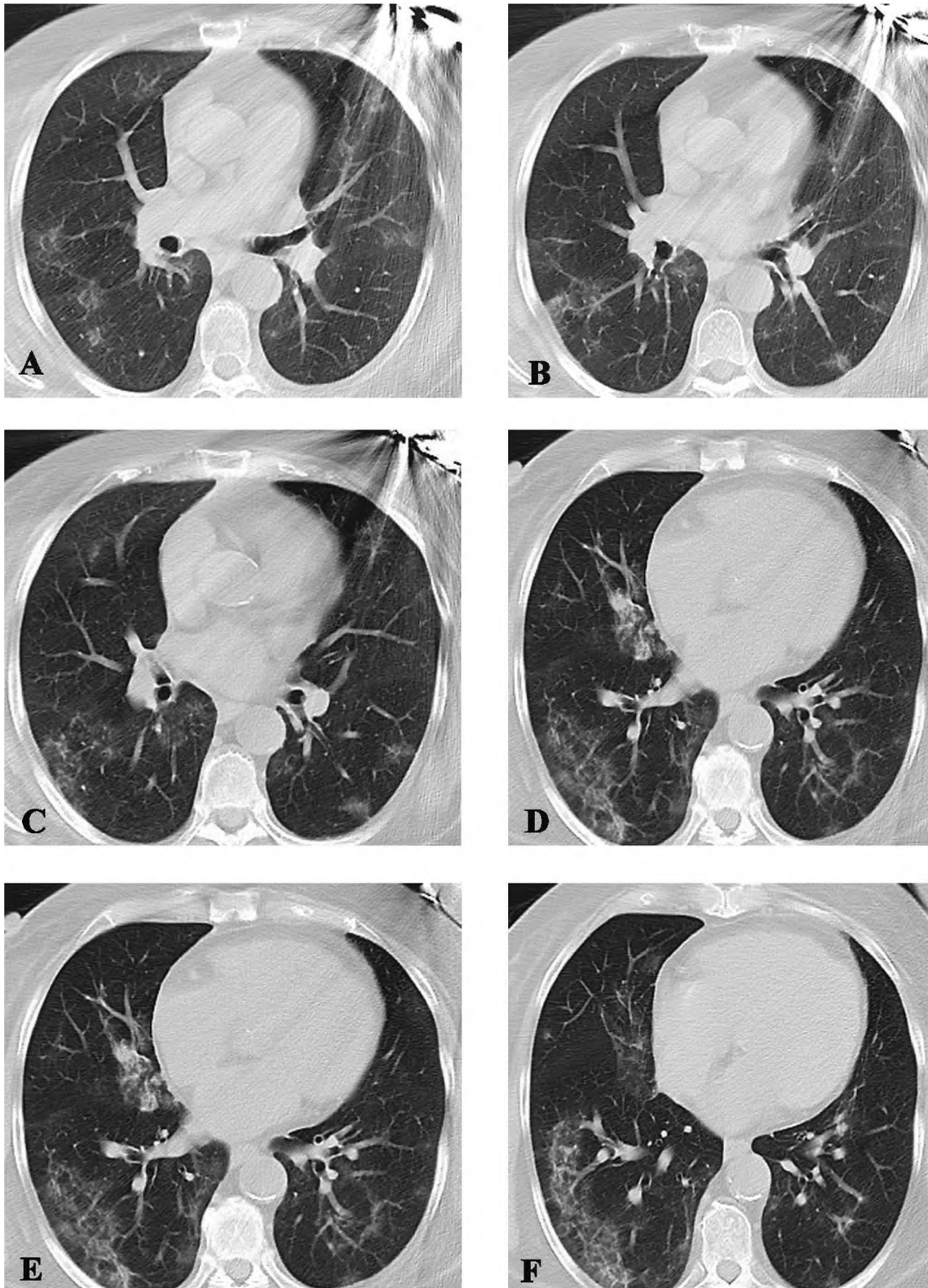


Fig. (2A,B,C,E,F): Showing a one month follow-up CT for the previously mentioned 71 years year old female patient with moderate COVID 19 infection, illustrating mild regression of the extent of previously noted bilateral ground glass opacities with newly developed fibrotic bands.



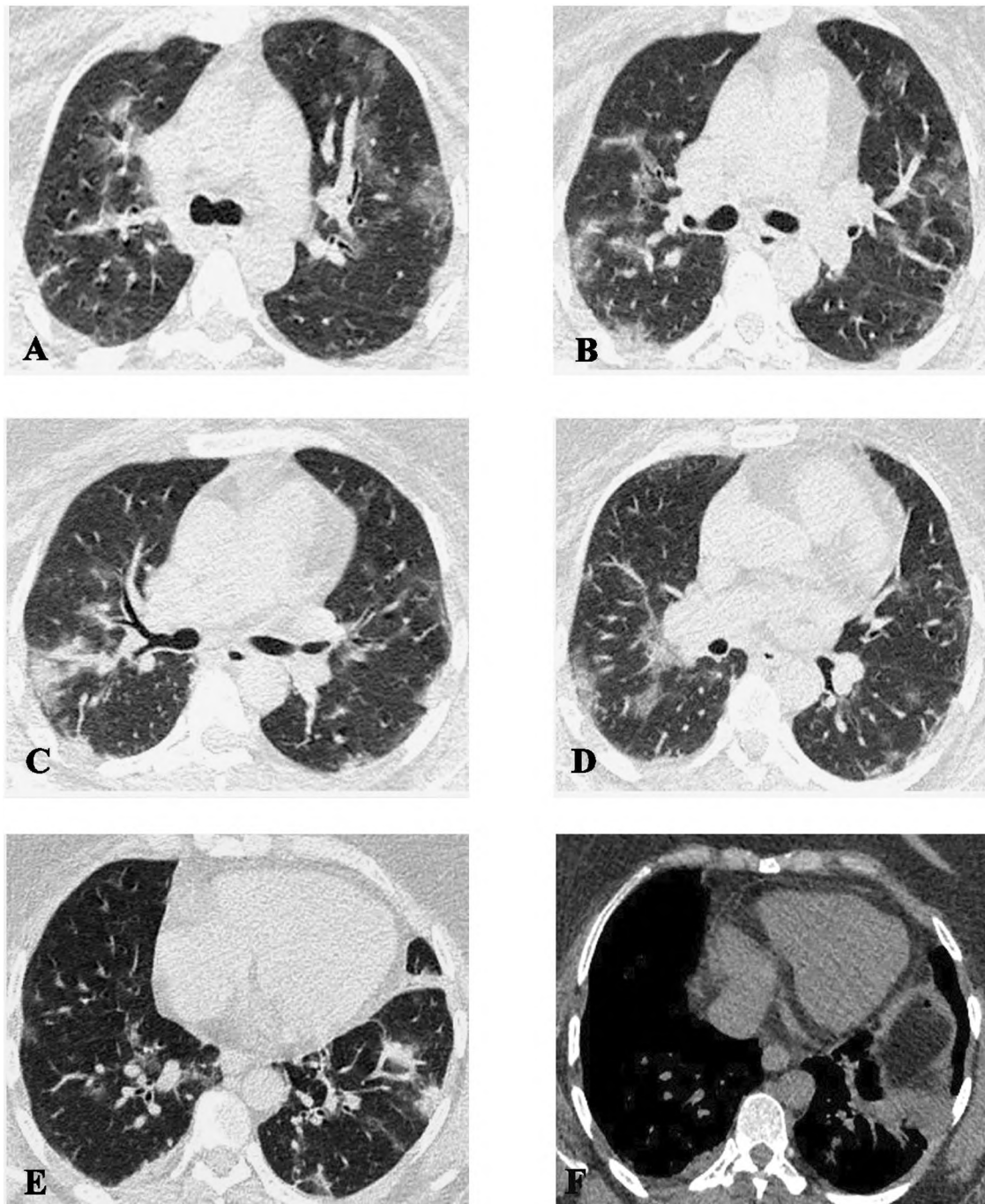


Fig. (3A,B,C,E) Showing initial CT of a 42 years old diabetic patient with severe COVID 19 infection illustrating bilateral predominantly subpleural ground glass opacities, patchy consolidation and fibrotic bands. (E) Mediastinal window scan showing right mild pleural effusion.

### Discussion

Our study is a cross sectional study, describing and comparing the CT features in mild, moderate and severe COVID 19 patients, with correlation to serum ferritin level in Cairo, Egypt.

In terms of gender distribution, our study was different from other published studies, where most of our patients were female patients (72%), while

most of patients in other studies were male patients [14,18]. Clinical symptoms also did not match those of other initial reports [19,20] who found that fever and cough are the most common symptoms while in our study, muscle soreness and fever were the most common symptoms. The majority of our patients had normal white blood cell count and lymphocyte count at presentation which was similar to Liang et al., [18].

Regarding the CT features, in our study, ground glass opacity was the most common of all the abnormalities (40%), followed by nodules and reticular pattern. In moderate cases, ground glass opacities were the predominant pattern being shown in 54.2% of cases (Fig. 1), while in severe cases, the predominant pattern were also ground glass opacities present in 89.5% of cases and interlobular septal thickening giving the crazy paving appearance which was present in 68.4% of cases. This was matching the results of the study done by Dai M. et al., conducted on 73 patients in Wuhan, China [21]. Such imaging finding of ground glass opacities with or without interlobular septal thickening was similar to previously reported CT features of viral pneumonia induced by severe acute respiratory distress syndrome (SARS) and middle east respiratory distress syndrome (MERS) [16,22,23,24].

In our study, lung consolidation and pulmonary fibrosis were highly correlated to disease severity (Figs. 2,3). Chon Y. J. et al., [25] stated that although consolidation opacity was frequently observed in patients in the severe group, it was not found to be a predictor of poor prognosis in their study. Dai M. et al., [25], who studied the temporal lung changes between non severe and severe cases of COVID 19 patents, stated that residual pulmonary fibrosis was highly noted in severe cases of COVID 19.

In our study, pleural effusion was not a common features, and was found in 6.7% of patients who were all severe cases (Fig. 3). This was consistent with the results of the study done by Chon Y.J et al., in Korea [25].

Chon Y.J. et al., [25] also noted that a CT score more than 5 at the time of admission were prognostic independent factors for COVID-19, which was similar to our study.

In this cross sectional evaluation, we found that ferritin levels were shown to correlate with illness severity in 75 patients with confirmed COVID-19 disease. Dahan et al., [14], described the epidemiological and clinical characteristics of COVID-19 patients in Israel. In their study, ferritin levels were shown to correlate with illness severity in 39 patients with confirmed COVID-19 disease. In their study, severe patients had significantly higher levels of ferritin (2817.6ng/ml) compared to non-severe patients (708.6ng/ml) = 0.02.

Similar to our findings, a recent retrospective, multicenter study identified elevated levels of ferritin (mean 1297.6ng/ml in non-survivors vs 614.0ng/ml in survivors; <0.001) and IL-6

(<0.0001) as predictors of mortality among 150 confirmed COVID-19 cases [26]. Ferritin levels were also elevated in severe compared to moderate cases in a smaller retrospective study of 21 patients with COVID-19 conducted in China [27].

In our study, the patients were categorized into mild, moderate and severe levels of severity which was similar to the work done by Dahan et al., [14]. On the other hand, Chon Y.J. et al., [25] and Dai M. et al., [21] divided the patients into two groups based on clinical criteria, namely, severe and non-severe groups.

Our study has some limitations. First, our sample size was small. We described a limited sized case series of patients in addition to correlation with serum ferritin level. In order to better define the imaging characteristics, clinical course of the disease, natural history, and risk factors for mortality, collection of data for a larger cohort would be needed. Additionally, the critically ill patients were not included in our study. Our data was collected from multiple sites with variable CT scanning parameters. Therefore, the data heterogeneity reflects the different practice parameters and settings. In addition, we didn't present data regarding the total body iron storage in these patients. This could affect our results, since ferritin levels are expected to be lower in patients with iron deficiency anemia, even if they have severe COVID-19 disease.

#### Conclusion:

In conclusion, some imaging features like ground glass opacities, interlobular septal thickening and pleural effusion with elevated ferritin levels were shown to correlate with disease severity in 75 patients from Egypt with confirmed COVID-19 infection. Both Computed tomography and serum ferritin have a significant role in evaluation and assessment of severity of patients with COVID 19.

#### References

- 1- HUANG C., WANG Y., LI X., REN L., ZHAO J., HU Y., et al.: Clinical features of patients infected with 2019 novel coronavirus in Wuhan, China. *Lancet*, Feb. 15; 395 (10223): 497-506, 2020.
- 2- WHO: Clinical management of severe acute respiratory infection when novel coronavirus (nCoV) infection is suspected: Interim guidance, Jan. 11, 2020.
- 3- National Health Commission of the People's Republic of China. <http://www.nhc.gov.cn> (Assessed on February 25th, 2020).
- 4- ZHOU Z., GUO D., LI C., FANG Z., CHEN L., YANG R., et al.: Coronavirus disease 2019: Initial chest CT findings. *Eur. Radiol.*, Aug. 30 (8): 4398-4406, 2020.

- 5- PAN F., YE T., SUN P., GUI S., LIANG B., LI L., et al.: Time Course of Lung Changes at Chest CT during Recovery from Coronavirus Disease 2019 (COVID-19). *Radiology*, Jun. 295 (3): 715-721, 2020.
- 6- LEI J., LI J., LI X. and QI X.: CT imaging of the 2019 novel coronavirus (2019-nCoV) pneumonia. *Radiology*, 2020.
- 7- YIN Y., WUNDERINK R.G. MERS, SARS and other coronaviruses as causes of pneumonia. *Respirology*, 23: 130-137, 2018.
- 8- KOGAN A., SEGEL M.J., RAM E., RAANANI E., PELED-POTASHNIK Y., LEVIN S., et al.: Acute Respiratory Distress Syndrome following Cardiac Surgery: Comparison of the American-European Consensus Conference Definition versus the Berlin Definition. *Respiration*, 97 (6): 518-524, 2019.
- 9- ZHOU F., YU T., DU R., FAN G., LIU Y., LIU Z., et al.: Clinical course and risk factors for mortality of adult inpatients with COVID-19 in Wuhan, China: A retrospective cohort study. *Lancet*, Mar. 28; 395 (10229): 1054-1062, 2020.
- 10- PIRES da R.G. and FERREIRA E.: Therapies used in rheumatology with relevance to coronavirus disease 2019. *Clin. Exp. Rheumatol.*, 38 (2): 370, 2020.
- 11- AGMON-LEVIN N., ROSÁRIO C., KATZ B.S., ZANDMAN-GODDARD G., MERONI P., CERVERA R., et al.: Ferritin in the antiphospholipid syndrome and its catastrophic variant (cAPS). *Lupus*, Nov. 22 (13): 1327-35, 2013.
- 12- HARRISON P.M. and AROSIO P.: The ferritins: Molecular properties, iron storage function and cellular regulation. *Biochim Biophys Acta BBA-Bioenerg.* 1275 (3): 161-203, 1996.
- 13- HINTZE K.J. and THEIL E.C.: DNA and mRNA element with complementary responses to hemin, antioxidant inducers, and iron control ferritin-L expression. *Proc. Natl. Acad. Sci.*, 102 (42): 15048-52, 2005.
- 14- DAHAN S., SEGAL G., KATZ I., HELLOU T., TIETEL M., BRYK G., et al.: Ferritin as a Marker of Severity in COVID-19 Patients: A Fatal Correlation. *Isr Med Assoc J.*, Aug. 22 (8): 494-500, 2020. Wei, Pei-Fang Diagnosis and Treatment Protocol for Novel Coronavirus Pneumonia (Trial Version 7), *Chinese Medical Journal*: May 5, Volume 133 - Issue 9 - p 1087-1095, 2020.
- 15- OOI G.C., KHONG P.L., MÜLLER N.L., YIU W.C., ZHOU L.J., HO J.C., et al.: Severe acute respiratory syndrome: Temporal lung changes at thin-section CT in 30 patients. *Radiology*, Mar. 230 (3): 836-44, 2004.
- 16- CHANG Y.C., YU C.J., CHANG S.C., GALVIN J.R., LIU H.M., HSIAO C.H., et al.: Pulmonary sequelae in convalescent patients after severe acute respiratory syndrome: Evaluation with thin-section CT. *Radiology*, Sep. 236 (3): 1067-75, 2005.
- 17- LIANG T., LIU Z., WU C.C., JIN C., ZHAO H. and WANG Y.: Evolution of CT findings in patients with mild COVID-19 pneumonia. *Eur. Radiol.*, 30 (9): 4865-4873, 2020.
- 18- WORMANNS D. and HAMER O.W.: Glossary of terms for thoracic imaging-German version of the Fleischner Society recommendations. *Rofo.*, 187 (8): 638-661, 2015.
- 19- WU J., WU X., ZENG W., GUO D., FANG Z., CHEN L., et al.: Chest CT Findings in Patients With Coronavirus Disease 2019 and Its Relationship With Clinical Features. *Invest Radiol.* May, 55 (5): 257-261, 2020.
- 20- DAI M., LIU X., ZHU X., LIU T., XU C., YE F., et al.: Temporal changes of CT findings between non-severe and severe cases of COVID-19 pneumonia: A multi-center, retrospective, longitudinal Study. *Int. J. Med. Sci.*, 17 (17): 2653-2662, 2020.
- 21- ANTONIO G.E., OOI C.G.C., WONG K.T., TSUI E.L.H., WONG J.S.W., SY A.N.L., et al.: Radiographic-Clinical Correlation in Severe Acute Respiratory Syndrome: Study of 1373 Patients in Hong Kong. *Radiology*, 237 (3): 1081-1090, 2005.
- 22- DAS K.M., LEE E.Y., ENANI M.A., ALJAWDER S.E., SINGH R., BASHIR S., et al.: CT Correlation With Outcomes in 15 Patients With Acute Middle East Respiratory Syndrome Coronavirus. *Ajr American Journal of Roentgenology*, 204 (4): 736-742, 2015.
- 23- AJLAN A.M., AHYAD R.A., JAMJOOM L.G., ALHARTHY A. and MADANI T.A.: Middle East respiratory syndrome coronavirus (MERS-CoV) infection: Chest CT findings. *AJR American Journal of Roentgenology*, 203 (4): 782-787, 2014.
- 24- CHON Y.J., KIM J.Y., SUH Y.J., LEE J.Y., PARK J.S., MOON S.M., et al.: Adverse initial CT findings associated with poor prognosis of coronavirus disease. *Journal of Korean Medical Science*, 35 (34), 2020.
- 25- RUAN Q., YANG K., WANG W., JIANG L. and SONG J.: Clinical predictors of mortality due to COVID-19 based on an analysis of data of 150 patients from Wuhan, China. *Intensive Care Med.*, 46 (5): 846-8, 2020.
- 26- CHEN G., WU D., GUO W., CAO Y., HUANG D., WANG H., et al.: Clinical and immunological features of severe and moderate coronavirus disease 2019. *J. Clin. Invest.* May 1; 130 (5): 2620-2629, 2020.

## استخدام التصوير المقطعى المحوسب متعدد الشرائح فى تقييم الدرجات المختلفة لمرضى كوفيد ١٩ بالإضافة إلى الارتباط بمستوى فيريتين المصل : دراسة مقطعية

الهدف من هذه الدراسة: هو تقييم دور الفيريتين والتصوير المقطعى المحوسب فى تقييم مرضى COVID 19 الخفيف والمتوسط والشديد والربط بين مستوى الفيريتين ونتائج التصوير المقطعى وشدة المرض.

بين الأول من يوليو وحتى نهاية سبتمبر ٢٠٢٠، تمت إحالة ٧٥ مريضاً (٢١ ذكراً و ٥٤ إناثاً) مصابين بفيروس كورونا المستجد PCR من القاهرة، مصر، لإجراء التقييم المختبرى والتصوير المقطعى المحوسب متعدد الشرائح

أبرز النتائج الإشعاعية فى الحالات المتوسطة والشديدة كانت عتامة الزجاج المطحون (٥٤.٢٪ و ٨٩.٥٪)، عقيدات الرئة (٥٤.٢٪ و ٥٢.٦٪) والنمط الشبكي (٣٧.٥٪ و ٥٢.٦٪) على التوالي. أظهرت بعض ميزات التصوير مثل عتامة الزجاج الأرضى، سماكة الحاجز بين الفصوص والانصباب الجنبى مع مستويات مرتفعة من الفيريتين، مرتبطة مع شدة المرض.

نستنتج: أنه يلعب التصوير المقطعى المحوسب ومستويات الفيريتين فى الدم دوراً مهماً فى تقييم وتقييم شدة مرضى COVID 19.