

Therapeutic role of Stem cells pretreated with Hyaluronic acid against chronic kidney disease in rat model

Mohammed E. Elshehabi¹, Nashwa Barakat², Faten Zahran³, Hany S. Hafez⁴, Waleed M. Serag^{1,*}

¹Chemistry Department, Faculty of Science, Suez University, Suez, Egypt.

²Urology and Nephrology Center, Mansoura University, Mansoura, Egypt

³Chemistry Department, Faculty of Science, Zagazig University, Zagazig, Egypt.

⁴Zoology Department, Faculty of Science, Suez University, Suez, Egypt.

ARTICLE INFO

Article history:

Received 29 October 2021

Accepted 16 November 2021

Available online 19 November 2021

Keywords

Hyaluronic acid;

Bone marrow mesenchymal stem cell;

Chronic renal disease;

Apoptosis.

ABSTRACT

Purpose: This study aimed to evaluate the impact of Hyaluronic acid (HA) in enhancing the migration and the therapeutic efficacy of bone marrow mesenchymal stem cells (BMSCs) in chronic renal disease. **Material and Methods:** Sixty Sprague Dawley male rats were alienated into 4 equal groups; control group: rats received two saline injections at 1 and 14 days, Adriamycin (ADR) group: rats were injected iv twice via tail vein at day one and after 2 weeks, BMSCs group; rats were injected iv twice after 5 days of each ADR injection, and HA+ BMSCs group; rats were iv injected twice with BMSCs pretreated with 1mg/ml HA after 5 days of each ADR injection. Viability and proliferation of BMSCs was assessed, protective role of BMSCs on renal function and morphology was detected using biochemical analysis, Masson's trichrome staining and the apoptotic marker caspase-3. **Results:** HA was found to increase the BMSCs viability and proliferation than the untreated cells ($p < 0.05$). Meanwhile, serum creatinine, blood urea nitrogen and urinary protein excretion levels were significantly low in BMSCs preconditioned with HA compared to ADR ($p < 0.05$). Moreover, BMSCs treated with HA enhanced the renal regeneration, the antioxidants, and reduce the apoptosis compared to ADR group ($p < 0.05$). **Conclusion:** The results manifested that HA has the potentiality to enhance BMSCs viability and provides renal protection via improving the renal morphology and reduce the apoptosis and restore the balance between enzymes activity and free radicals.

1. Introduction

Chronic kidney diseases (CKDs) are a worldwide health problem associated with irreversible kidney damage and progress to end-stage renal disease (ESRD) [1]. Tubulointerstitial fibrosis and glomerular damage is a main pathway to ESRD, associated with oxidative stress and apoptosis. However kidney possesses interinsic regeneration capacity, this regeneration is limited under chronic condition and can't prevent the fibrosis process [2]. Although many treatment strategies have been implemented for renal fibrosis, arresting CKD progression remains unfulfilled. Therefore, new approaches for cellular regeneration are needed for patients with CKD. Over the past few years, Mesenchymal stem cells (MSCs) have been used in regenerative therapies. They can differentiate into different cell types, ameliorate inflammation, which thereby facilitate renal repair [3]. Experimental models of CKD showed promising results when treated with MSCs [2].

Migration system of the injected MSCs to injured regions is the most important step in tissue repair [4]. Therefore, methods for enhancing MSCs homing to the injured kidney need to be developed.

Hyaluronic acid (HA) which dispersed in the skin, umbilical cords and cartilage, was reported to play a critical role in MSCs migration to damaged renal tissue and to improve renal regeneration in acute kidney injury model [5]. Few studies have discussed the effect of HA on acute renal injury [6, 7]. But non of them discussed its role in CKD. Therefore, this study was designed to study the mechanism by which HA may play a vital role in the migration of the transplanted cells in chronic renal failure model.

2. Materials and Methods

BMSCs preparation

BMSCs were collected from male Sprague–Dawley (SD) rats as described by [8]. Briefly, femur bone was cut from the both side and the bone marrow was flushed and cultured in tissue flasks with complete DMEM medium plus 10% fetal bovine serum (Gibco, Thermo, US), and 100 U/ml penicillin/streptomycin (Gibco, Thermo, US) in an

* Corresponding authors at Suez University

E-mail addresses: waleed.ibrahim@suezuniv.edu.eg (W. M. Serag)

incubator at 37°C and 5% CO₂. Complete media was changed every 72 hours till reached passage three.

Flow cytometric analysis

Cells at third passage were prepared at a concentration of (1x10⁶/ml) and incubated with FITC-conjugated CD45 and CD90 for 30 min at room temperature in the dark. Cells were detected using flow cytometer (FACS calibur, Becton Dickinson).

Pretreatment of BMSCs with HA and a cell proliferation and viability assay

The effect of HA on BMSCs proliferation and viability was performed using a colorimetric MTT assay. Proliferation was first detected by seeding BMSCs in 96-well plates at a concentration of 10x10³ cell/well for 24 hr., and treated with different concentrations of HA (0, 0.25, 0.5, 1 mg/ml) for 14 days. Viability was estimated by treating the cells with 1 mg/ml HA for (1, 5, 7 and 14 days). Cells were incubated with diphenyl tetrazolium bromide (Sigma Aldrich, USA) for 4 hours at 37°C; then, 100 µL of DMSO was added to the cells and incubated for 15 min. The optical density was measured at a wavelength of 570 nm using micro plate reader.

Animals

Sixty male (SD) rats, weighing approximately 180–220 g were kept in a 12 h light/dark cycle, and allowed to food and water *ad libitum*. All the experiments were conducted in conformity with Urology and Nephrology Center, Mansoura University according to the NIH guidelines for use of laboratory animal. The study was approved by the ethics committee of Suez University, Suez, Egypt

Experimental design

Sixty rats were arranged in four equal groups as following; Group I (n=15) rats were intravenous (i.v.) injected twice with 0.5 mL saline. Group II (n=15) (Adriamycin group): rats were i.v. injected twice with 4 mg/kg ADR at day 1 and 14 [9]. Group III (n=15) (BMSCs group): rats were injected with ADR as in group II, and then i.v. injected twice with (2 × 10⁶ cells) BMSCs (5 days after each ADR injection) [8]. Group IV (n=15) (HA-BMSCs group): as group III with the injection of BMSCs preconditioned with 1 mg/ml HA [6].

Blood and urine samples collection and kidney tissue harvesting

After 3 months from Adriamycin or saline injection, urine was collected from rats by placing them in a metabolism cage 24 hours before sacrifice. Blood samples were collected under inhalation halothane anaesthesia from heart puncture and centrifuged at 3000x g, then stored at -20°C for kidney function evaluation. Kidney samples were collected after rats were euthanized using 120 mg/Kg Na thiopental. The abdomen was dissected and the right kidney was harvested and stored in -80°C for oxidative stress measurements, while the left kidney was fixed in formalin for histological examination.

Biochemical measurements

Collected serum was used to detect serum creatinine (S.Cr) and blood urea nitrogen (BUN) levels, while urinary protein excretion was measured in urine samples by specific kits according to manufactured instructions (Diamond Diagnostics, Egypt) using Architect system (Abbott Diagnostics, Germany).

Assay of malondialdehyde (MDA), catalase (CAT) and superoxide dismutase (SOD) activities in kidney tissues

Kidney tissues stored in -80°C were weighed, homogenized and centrifuged at 4,000 rpm for 15 minutes at 4°C. The supernatant was used for analysis of lipid peroxides (malondialdehyde, MDA) and the enzymes activity of superoxide dismutase SOD and catalase CAT. MDA, CAT and SOD were measured according to the manufacturer's instructions using a commercial colorimetric kit (Bio-Diagnostics, Egypt).

Histopathological examination

Kidney tissue were fixed in paraffin, cut into 4-µm thick slices, and stained with H&E and Masson Trichrome stain using Olympus® BX51 light microscopic examination. The histological findings were used to determine the injury score in the renal tissues according to [10] that included necrosis, dilated tubules and interstitial infiltration. Regeneration score incorporated presence of prominent nuclei, solid sheets and mitotic figures.

Immunohistochemical studies

The expression of apoptotic marker caspase-3 was detected in the renal tissue of all studied groups using immunohistochemical staining. Briefly, paraffin-embedded sections were subjected to antigen retrieval. The expression of caspase-3 (RB-1197-P1; Fremont, USA) was detected at a dilution of 1:100 for 1 hour at room temperature. Secondary antibody (Power - Stain 1.0 Poly HRP DAB Kit) was added for 30 min, and the sections were treated with DAB staining to develop the reaction color. The tissue sections were counterstained with hematoxylin, dehydrated, mounted with a coverslip, and observed by an Olympus BX51 light microscopy.

Statistical Analysis

The results are expressed as mean ± standard deviation. One-way ANOVA post hoc test was used to determine any statistical differences between groups, while Kruskal-Wallis test followed by Mann-Whitney's tests was used for histopathological scoring with significant difference at p ≤ 0.05 using SPSS (IBM Corp., USA).

3. Results

Characterization of BMSCs

Flow cytometric analysis showed that BMSCs express CD90 with positive rate (95.5%) and negative rate (4.5%), while CD45 positively expressed with 8.3% and negatively expressed with 81.7%. These results are in agreement with the immunophenotype of BMSCs (Fig. 1A, B).

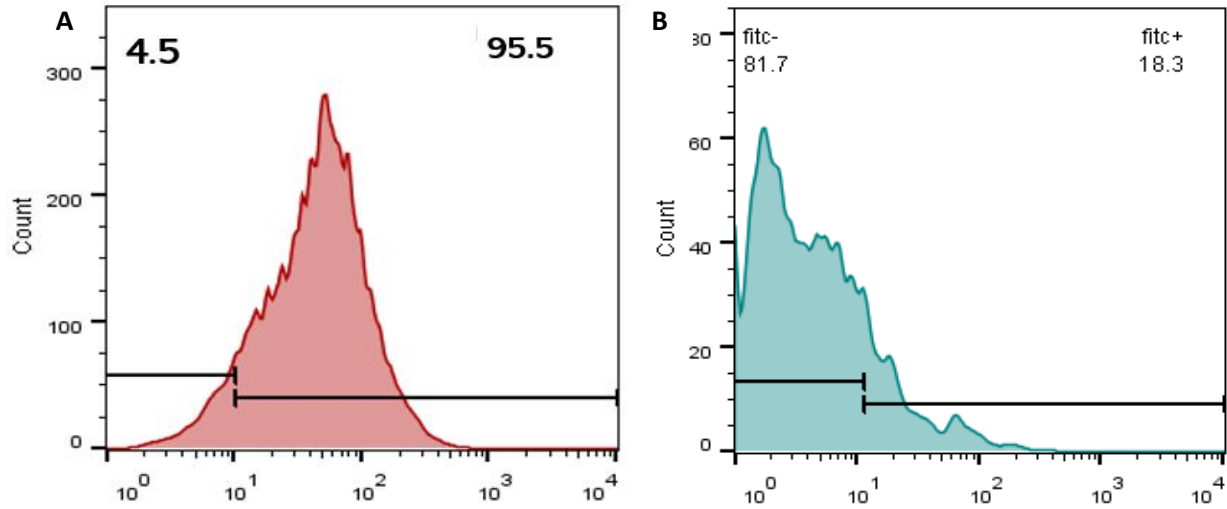


Fig. 1: Immunophenotypic analysis of bone marrow mesenchymal stem cells disclosed their positive expression for CD90 (A) and negative expression for CD45 (B).

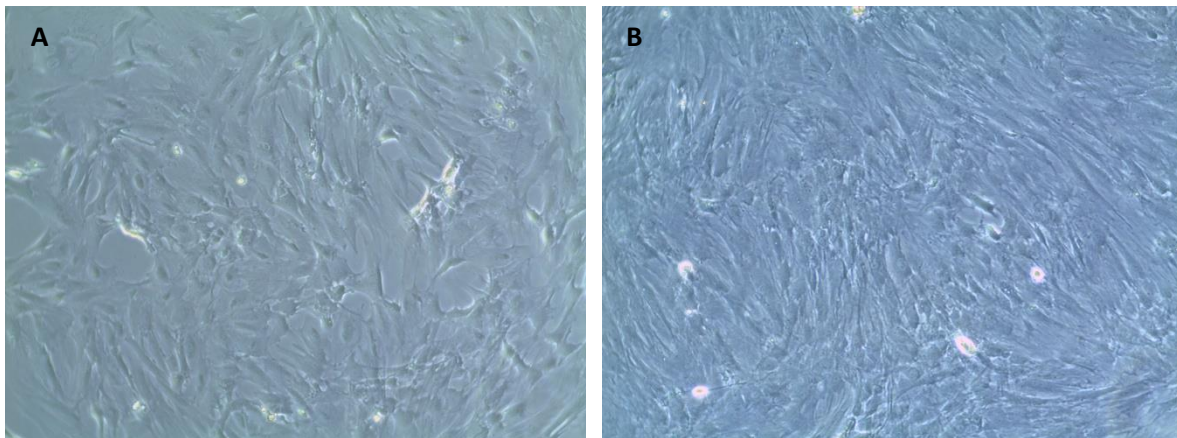


Fig. 2: Photomicrograph showing A: BMSCs at passage three, B: BMSCs treated with hyaluronic acid (HA) (10x).

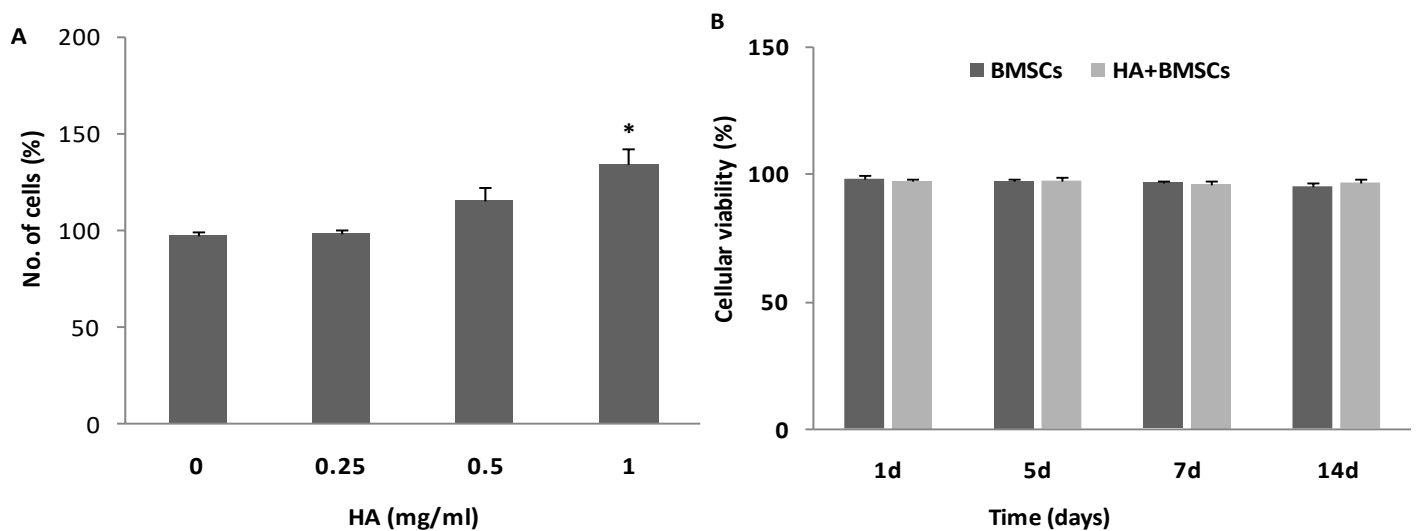


Fig. 3: (A) Effect of different concentrations of HA on cell proliferation, (B) Effect of HA on the cells viability.

Table 1: Effects of BMSCs pretreated with hyaluronic acid on kidney functions (serum creatinine, BUN, and urinary protein excretion after Adriamycin administration)

Groups	SCr (mg/dl)	BUN	Urinary protein excretion (mg /24 hr)
Control	0.51±0.03	37.47±3.05	3.34±1.38
ADR	0.98±0.2 ^a	224.5±33.8 ^a	77.41±12.63 ^a
BMSCs	0.85±0.08 ^a	173±14.3 ^{ab}	61.47±7.08 ^{ab}
HA+ BMSCs	0.71±0.07 ^{ab}	80.64±10.8 ^{abc}	34.38±12.57 ^{abc}
<i>P value</i>	<0.05 ^{***}	<0.05 ^{***}	<0.05 ^{***}

Effect of HA on BMSC proliferation and viability

At the third passage of BMSCs as shown in (Fig. 2A), cells were pretreated with HA which increased the cells proliferation and regeneration (Fig. 2B), the proliferation and viability of BMSCs using different concentrations of HA was tested by colorimetric MTT assay for 1, 5, 7 and 14 days. As shown in (Fig. 3A; $P < 0.05$). HA significantly enhanced the BMSC proliferation with the highest concentration 1 mg/ml. The cellular viability showed significant increase with HA treated media for 14 days (Fig. 3B).

Biochemical results

The results of SCr mg/dl, BUN, and protein excretion are revealed in Table 1. There was a significant increase in the mean values of SCr, BUN, and protein excretion in the ADR group compared to the control group ($p < 0.05$). BMSCs treated group manifested a significant reduction in the BUN and protein excretion levels compared to ADR group ($p < 0.05$). While the levels of SCr didn't show any statistical different with BMSCs treatment compared to ADR group ($p > 0.05$). The group treated with BMSCs preconditioned with HA showed a significant decrease in the SCr, BUN, and protein excretion levels compared to ADR group ($p < 0.05$), and showed the most decrease in their levels compared to the BMSCs treated group alone ($p < 0.05$).

Oxidative stress parameters

Adriamycin increased the renal MDA compared to the control group ($p < 0.05$). BMSCs and BMSCs +HA groups reduced MDA levels compared to the ADR and BMSCs groups ($p < 0.05$). The SOD and CAT activities showed significant decrease in the ADR treated group compared to the control group ($p < 0.05$). Administration of BMSCs significantly increased the renal SOD and CAT activities compared to the ADR group ($p < 0.05$). Moreover, BMSCs pretreated with HA group showed significant increase in SOD activity and decrease in MDA level compared to BMSCs ($p < 0.05$; Table 2).

Histopathological Examination:

Renal tissue damage score was evaluated in all the studied groups. Adriamycin group showed higher injury and chronicity score than the control group ($p < 0.05$). Administration of BMSCs and BMSCs preconditioned with HA showed lower injury than ADR group ($p < 0.01$).

Moreover, HA+BMSCs showed higher regeneration score than ADR and BMSCs alone ($p < 0.01$; Table.3).

The Control group showed normal kidney architecture (Fig. 4A). ADR group showed necrosis, dilated tubules, infiltration of inflammatory cells, and fibrosis in medulla and cortex (Fig. 4B). However, when the rats were treated with BMSCs, less inflammation and dilated tubules were observed (Fig. 4C). Moreover, BMSCs pretreated with HA group showed forms of regeneration included prominent nuclei and mitotic figures (Fig. 5D).

Immunohistochemical investigations

Immunoreactivity of the apoptotic marker caspase-3 in renal tissue was detected in all studied groups. The score of caspase-3 was higher in ADR group compared to the control group and lower in BMSCs and HA+BMSCs compared to ADR group (Fig. 6A). ADR group showed marked caspase-3 expression in renal cells (Fig. 6B). In contrast, BMSCs group showed moderate expression of caspase-3 (Fig. 6C), while HA+BMSCs showed mild expression of caspase-3 (Fig. 6D).

Discussion

Systemic treatment with mesenchymal stem cells (MSCs) are mainly depends on the signals obtained from the injured tissues that promote the migration of the cells to repair the target tissue [11].

In the present study, the potential role of HA on BMSCs viability, migration to injured renal tissue and their impact on the kidney morphology and function was evaluated. The cell surface receptor CD44 is the major receptor for HA, and it was pointed that it is accumulated in the renal ischemia, nephritis, and chronic nephropathy [12]. The binding of HA to CD44 receptor is concerned in angiogenesis, migration, and proliferation [13]. Our findings showed that HA was implicated in facilitating the cells migration potency to damaged tissue in chronic renal disease model induced by Adriamycin.

The current study found that preconditioning of BMSCs with 1mg/ml HA for 14 days increased the cell viability and proliferation, suggesting that BMSCs migration depends on the dose of HA. These results were in harmony with [7], who reported that HA enhanced the cell migration potential.

Table 2: Effects of hyaluronic acid treated BMSCs on the kidney MDA level, CAT and SOD activities.

Groups	CAT(U/ gm)	SOD (U/ gm)	MDA(nmol/gm)
Control	7.34±2.64	301.58±47.2	18.91±8.01
ADR	1.99±0.67 ^a	118.59±44.58 ^a	55.94±13.77 ^a
BMSCs	4.92±1.23 ^b	223.61±49.2 ^{ab}	36.54±9.46 ^{ab}
HA+ BMSCs	6.19±1.41 ^b	287.82±27.28 ^{bc}	22.5±6.97 ^{bc}
P value	<0.05 ^{***}	<0.05 ^{***}	<0.05 ^{***}

Data are expressed as mean ± SD. Statistical analysis was done using one way-ANOVA.

a: Significant difference vs control group,

b: Significant vs ADR group,

c: Significant vs BMSCs group.

*** Statistically high significant at $p \leq 0.05$.

Table 3: Cortical and medullary histopathological changes in different groups.

Histological changes	Cortex	Medulla	P value
	Active injury score		
Control	0(0-0)	0(0-0)	
ADR	3(1-5) ^a	5(2-6) ^a	<0.05 ^{**}
BMSCs	2(1-3) ^a	2.5(2-4) ^{ab}	<0.01 ^{***}
HA+ BMSCs	1.5(0-2) ^{ab}	1(1-3) ^{bc}	<0.01 ^{***}
	Chronicity score		
Control	0(0-0)	0(0-0)	
ADR	4(3-6) ^a	6(3-6) ^a	<0.05 ^{**}
BMSCs	2.5(2-4) ^{ab}	3(2-4) ^{ab}	<0.01 ^{***}
HA+ BMSCs	1 (1-3) ^{bc}	2 (2-3) ^{ab}	<0.01 ^{***}
	Regeneration		
Control	0(0-0)	0(0-0)	
ADR	2(0-2) ^a	1.5(0-3) ^a	<0.05 ^{**}
BMSCs	3.5 (1-3) ^{ab}	3(2-3) ^{ab}	<0.01 ^{***}
HA+ BMSCs	6(2-7) ^{abc}	6(3-7) ^{abc}	<0.01 ^{***}

Data are expressed as median and range. Statistical analysis was done using Kruskal-Wallis test followed by Mann-Whitney's tests.

a: Significant difference vs control group,

b: Significant vs ADR group,

c: Significant vs BMSCs group.

** Statistically high significant at $p \leq 0.05$.

*** Statistically high significant at $p \leq 0.01$.

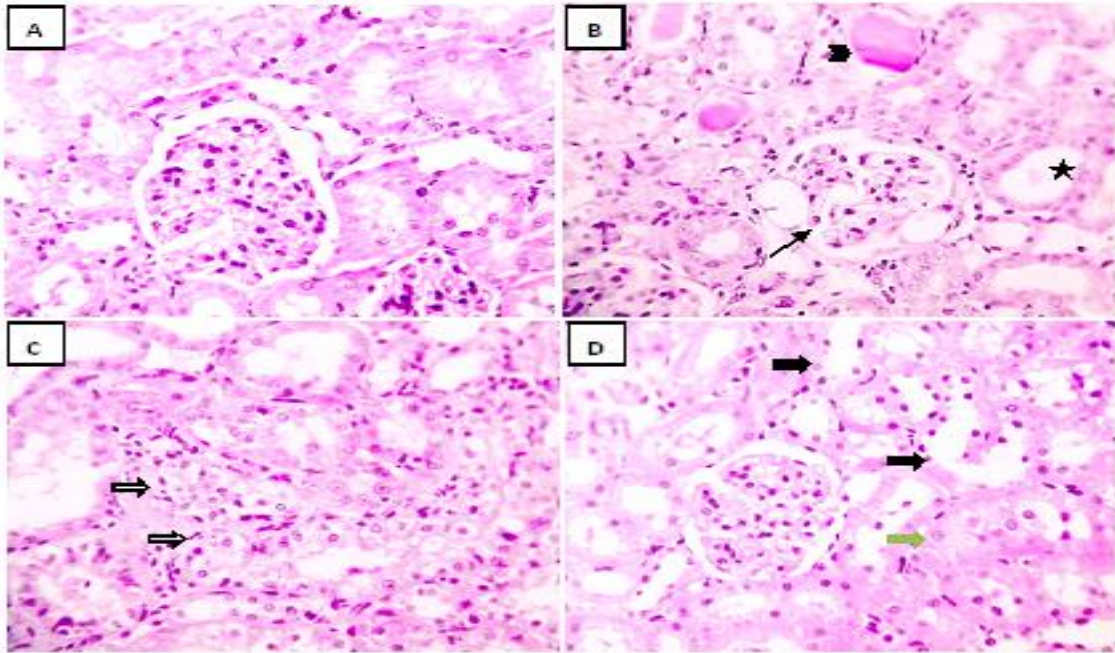


Fig. 4: Photomicrograph of H&E stained renal sections showing (A) the control group with normal glomeruli, tubules and interstitial tissue, (B) ADR group with chronic kidney disease manifested by marked tubular dilation (star) and glomerular atrophy (black arrows) and abundant leakage of protein in the tubular lumen (arrowhead), (C) BMSCs group with mild tubular hydropic dilation (white arrows), (D) HA+BMSCs group with very mild tubular degeneration (bold arrows), prominent nuclei (green arrow); X 400.

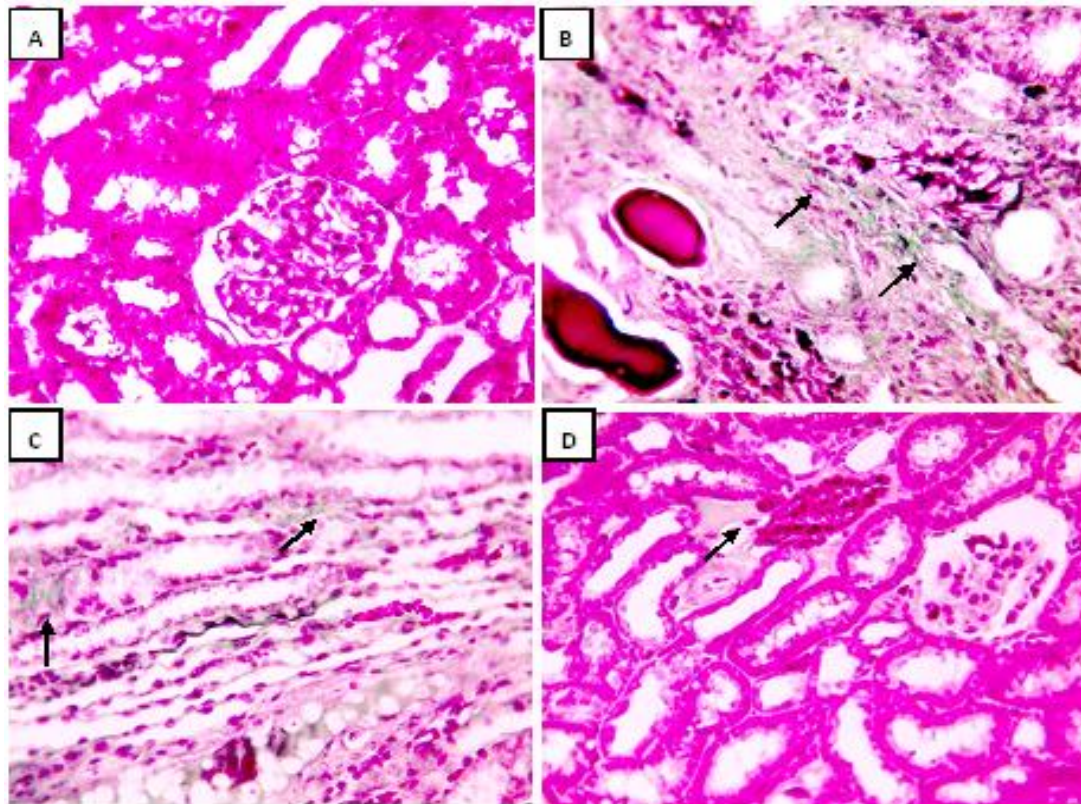


Fig. 5: Photomicrograph of Masson's trichrome stained renal sections showing: (A) Control group with no collagen deposition in interstitial tissue, normal glomeruli and tubules. (B) ADR group with markedly thickened glomerular and tubular, basement membranes with excessive interstitial collagen proliferation (black arrows). (C) BMSCs group with decreased interstitial collagen proliferation (black arrows). (D) HA+BMSCs group with weak interstitial collagen proliferation (black arrows); X 400.

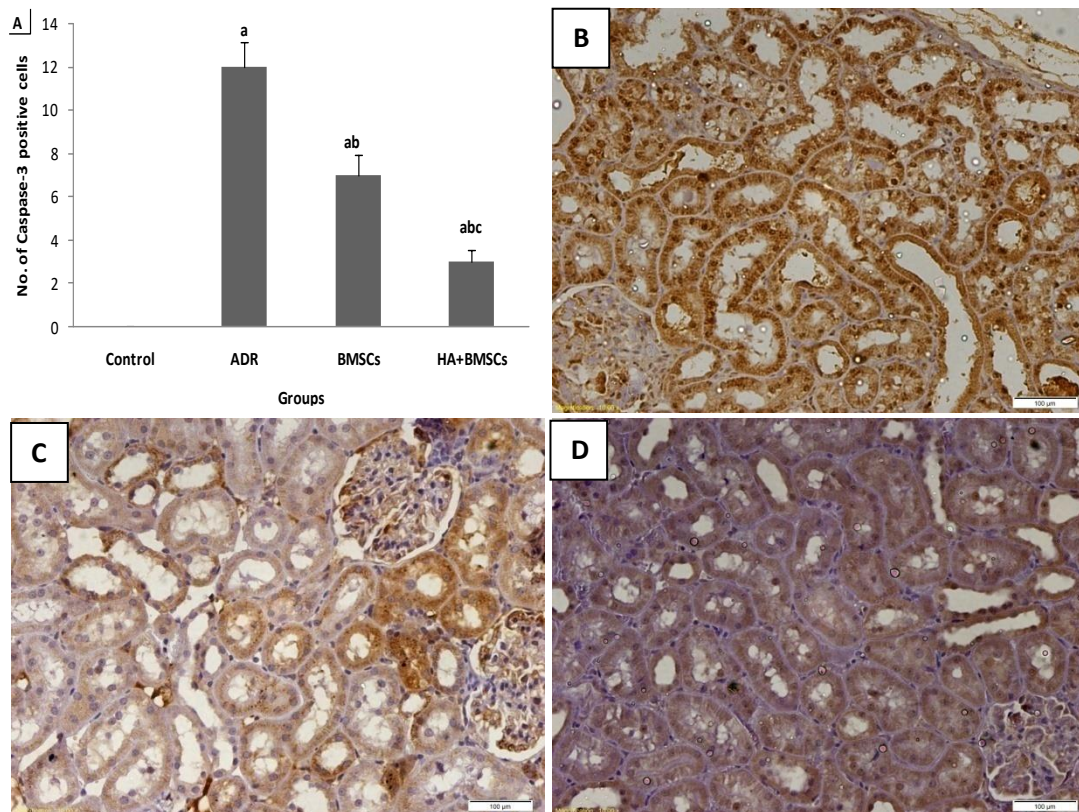


Fig. 6: Microscopic pictures of caspase-3 in renal sections showing: **(A)** Immunoreactivity of caspase-3 in renal tissue, **(B)** marked caspase-3 expression in ADR group, **(C)** Moderate caspase-3 expression in BMSCs group, and **(D)** Mild expression in HA+BMSCs group. X:400.

In addition, the current study evaluates the protective efficacy of HA-BMSCs on the chronic kidney disease rat model. The CKD rat model was adopted in this study by injection of two intravenous doses of 4mg/ml Adriamycin. The model results in significant deteriorations in kidney functions (as evidenced by significant increase in serum creatinine, BUN, and urinary protein excretion) and morphology (as shown in histopathological examination). These results are in agreement with previous findings revealed that, this effect could be attributed to either; direct ADR toxicity mediated by chemokine and free radical release; or indirectly through ADR induced proteinuria which triggers tubular cell activation and injury with attraction of interstitial inflammatory cytokines resulting in tubular interstitial damage with gradual loss of renal function [14, 15].

Treatment with BMSCs could enhance the BUN and the urinary protein and this is in agreement with [8]. Moreover, preconditioning the BMSCs with HA could regulate the S.Cr, BUN and the urinary protein excretion more than the untreated BMSC. This argument is in harmony with those of [6, 7] who demonstrated that MSCs pretreated with HA could improve the renal functions.

In a harmonious with the biochemical data, the histopathological investigation showed high tubulointerstitial damage as necrosis, dilated tubules, fibrosis and leukocyte infiltration in rats treated ADR. This chronic effect of ADR may be due to the indirect effect of excess accumulation of proteins in tubules that activated

the intracellular signaling pathways leading to increase releasing of pro-inflammatory cytokines and podocyte damage ended with glomerulosclerosis and tubulointerstitial fibrosis [16].

Treatment with BMSCs could decrease the necrotic dilated tubules, low apoptotic bodies, minimal fibrosis with the appearance of regeneration findings as, tubules with prominent nuclei and mitotic figures. The results are compatible with the findings of Sarhan et al. (2014) [8].

Furthermore, BMSCs pretreated with HA showed improved therapeutic potential when compared to group treated with BMSCs alone. This effect could be due to potency of HA to improve the BMSCs regenerative capability of and subsequently, increase the treatment efficiency by promoting cell-cell interaction and adhesion in the injured tissue. These results are in parallel with the previous studies reported that HA could improve the therapeutic role of stem cells [7, 12].

In the current study we did not investigate the renoprotective effect of BMSCs pretreated with HA only, but also we investigate the protective mechanisms that may include antioxidant and anti-apoptotic mechanisms. In agreement with previous study by Karanovic et al. (2021) [17], our results manifested excessive concentration of lipid peroxidation and low activity of antioxidant enzymes SOD and CAT in ADR group, suggesting that ADR induced free radical formation and disturb the antioxidant defense in the kidney.

We found significant increase in the antioxidant level of SOD and CAT with remarked decrease in MDA level in the BMSCs treatment groups, while the therapeutic outcome of BMSCs pretreated with HA was better. These results are in parallel with Awadalla et al., 2021 [7], who suggested the attenuation of oxidative stress might be a mechanism for the renoprotective action of BMSCs pretreated with HA.

Also, the present study demonstrated the anti-apoptotic role of HA- BMSCs on ADR induced the renal chronic injury. A significant increase in the expression of caspase-3 was detected in ADR group. This observation was discussed previously by Yang et al., 2012 [9] who pointed that ADR causes podocyte damage and apoptosis by free radicals elevation in the ADR metabolism.

Twice injection of BMSCs could attenuate the release of caspase-3 in the renal glomeruli by decreasing the apoptotic process of podocyte induced by ADR. This is in agreement with Sarhan et al. (2014) [8], who pointed that repeated MSC injections exhibit a notable anti apoptotic effect and reduced podocyte damage.

Interestingly, preconditioning BMSCs with HA showed mild or absence of caspase-3 expression compared to the untreated cells. This confirm the anti-apoptotic property that previously mentioned by Awadalla et al., 2021, [7].

One of our study limitations is the examination of kidney biopsies by electron microscope to observe the change of podocytes. Furthermore, the molecular mechanism by which BMSCs pretreated with HA enhanced the renal function requires further investigation.

In summary, the present study showed the effect of HA on the viability of BMSCs. Furthermore, preconditioning cells with HA could ameliorate the symptoms of ADR-induced chronic kidney disease in rats. This improvement was detected by remodeling the antioxidant activities, reducing the fibrosis and apoptosis induced by ADR. Hence, HA might have a crucial role in the enrollment of injected MSCs to the injured renal tissues.

References

- Zaki, M. E., Hassan, M. M., Bazaraa, H. M., Ahmed, H. F., & Badr, A. M. M. (2012). Nutritional status in children with chronic renal failure on hemodialysis. *Maced J Med Sci*, 5(3), 296-301.
- Eirin, A., & Lerman, L. O. (2014). Mesenchymal stem cell treatment for chronic renal failure. *Stem cell research & therapy*, 5(4), 1-8.
- Shalaby, S., Eid, E., Ali, A., Manawy, S., & Gad, S. (2020). Comparison between the Effect of Hyaluronic Acid and Mesenchymal Stem Cell Therapy on Cornea of Adult Albino Rats after Exposure to Alkali Burn (Light and Electron Microscopic Study). *Benha Medical Journal*, 37(3), 524-541.
- Uccelli, A., Moretta, L., & Pistoia, V. (2008). Mesenchymal stem cells in health and disease. *Nature reviews immunology*, 8(9), 726-736.
- Herrera, M., Bussolati, B., Bruno, S., Morando, L., Mauriello-Romanazzi, G., Sanavio, F., Stamenkovic, I., Biancone, L., & Camussi, G. (2007). Exogenous mesenchymal stem cells localize to the kidney by means of CD44 following acute tubular injury. *Kidney international*, 72(4), 430-441.
- Magar, R. (2018). Hyaluronic Acid induce Follistatin Potentiates the Renoprotective Effects of Wharton Jelly-Derived Mesenchymal Stem Cells in a Rat Model of Renal Ischemia Reperfusion Injury. *Transplantation*, 102, S731.
- Awadalla, A., Hussein, A. M., Ali, M., Barakat, N., Hamam, E. T., Magar, R. W., & Shokeir, A. A. (2021). Possible mechanisms for the renoprotective action of adipose-derived mesenchymal stem cells with CD44-targeted hyaluronic acid against renal ischemia. *Life Sciences*, 272, 119221.
- Sarhan, M., El Serougy, H., Hussein, A. M., El-Dosoky, M., Sobh, M. A., Fouad, S. A., Sobh, M., & Elhousseini, F. (2014). Impact of bone-marrow-derived mesenchymal stem cells on adriamycin-induced chronic nephropathy. *Canadian journal of physiology and pharmacology*, 92(9), 733-743.
- Yang, W., Wang, J., Shi, L., Yu, L., Qian, Y., Liu, Y., Wang, W., & Cheng, S. (2012). Podocyte injury and overexpression of vascular endothelial growth factor and transforming growth factor-beta 1 in adriamycin-induced nephropathy in rats. *Cytokine*, 59(2), 370-376.
- Karpinski, J., Lajoie, G., Cattran, D., Fenton, S., Zaltzman, J., Cardella, C., & Cole, E. (1999). Outcome of kidney transplantation from high-risk donors is determined by both structure and function. *Transplantation*, 67(8), 1162-1167.
- Shi, Y., Hu, G., Su, J., Li, W., Chen, Q., Shou, P., Xu, C., Chen, X., Huang, Y., & Zhu, Z. (2010). Mesenchymal stem cells: a new strategy for immunosuppression and tissue repair. *Cell Research*, 20(5), 510-518.
- Bian, X.-H., Zhou, G.-Y., Wang, L.-N., Ma, J.-F., Fan, Q.-L., Liu, N., Bai, Y., Guo, W., Wang, Y.-Q., & Sun, G.-P. (2013). The role of CD44-hyaluronic acid interaction in exogenous mesenchymal stem cells homing to rat remnant kidney. *Kidney and Blood Pressure Research*, 38(1), 11-20.
- Knopf-Marques, H., Pravda, M., Wolfova, L., Velebny, V., Schaaf, P., Vrana, N. E., & Lavalle, P. (2016). Hyaluronic acid and its derivatives in coating and delivery systems: applications in tissue engineering, regenerative medicine and immunomodulation. *Advanced healthcare materials*, 5(22), 2841-2855.
- Ding, Z.-H., Xu, L.-M., Wang, S.-Z., Kou, J.-Q., Xu, Y.-L., Chen, C.-X., Yu, H.-P., Qin, Z.-H., & Xie, Y. (2014). Ameliorating adriamycin-induced chronic kidney disease in rats by orally administrated cardiotoxin from *Naja naja atra* venom. *Evidence-Based Complementary and Alternative Medicine*, 2014.
- Rania, N., Islam, I. H., Atef, M., & Marwa, M. (2019). Effect of Platelet Rich Plasma on an Experimental Rat Model of Adriamycin Induced Chronic Kidney Disease. *The Medical Journal of Cairo University*, 87(June), 2207-2217.
- Wada, Y., Kondo, M., Sakairi, K., Nagashima, A., Tokita, K., Tominaga, H., Tomiyama, H., & Ishikawa, T. (2020). Renoprotective Effects of a Novel Receptor-interacting Protein Kinase 2 Inhibitor, AS3334034, in Uninephrectomized Adriamycin-induced Chronic Kidney Disease Rats. *Journal of Pharmacology and Experimental Therapeutics*, 374(3), 428-437.
- Karanovic, D., Mihailovic-Stanojevic, N., Miloradovic, Z., Ivanov, M., Vajic, U. J., Grujic-Milanovic, J., Markovic-Lipkovski, J., Dekanski, D., & Jovovic, D. (2021). Olive leaf extract attenuates adriamycin-induced focal segmental glomerulosclerosis in spontaneously hypertensive rats via suppression of oxidative stress, hyperlipidemia, and fibrosis. *Phytotherapy Research*, 35(3), 1534-1545.