



Pulp Tissue Response to Platelets Rich Plasma, Platelets Rich Fibrin and Mineral Trioxide Aggregate as Pulp Capping Materials

Sarah D. Shaheen^{1*}, Maha A. Niazy², Wael E. Jamil³, Ashraf M. Abu-Seida⁴

Codex : 04/21.10

azhardentj@azhar.edu.eg

http://adjg.journals.ekb.eg

DOI: 10.21608/adjg.2021.37107.1280

Restorative Dentistry
(Removable Prosthodontics, Fixed
Prosthodontics, Endodontics, Dental
Biomaterials, Operative Dentistry)

ABSTRACT

Purpose: to evaluate the biological response of the dog teeth to Platelets Rich plasma (PRP), Platelets Rich fibrin (PRF) and mineral trioxide aggregate (MTA) as pulp capping materials. **Material and Methods:** A total of 90 teeth of dogs were included. Class V cavities were prepared. Pulp exposure was performed in the middle of cavity floor. The teeth were divided into three groups of 30 teeth according to the material used; A1: PRP, A2: PRF and A3: MTA. Glass ionomer restoration was applied as restoration for the cavities. The tissue response to the materials was assessed at three different post-operative periods of 7, 30, 60 days. The animal was sacrificed. Histomorphometric analysis was performed. **Result:** the results showed high inflammatory cells count at 7 days for all treated groups; PRP treated teeth showed the highest at 7 days, while PRF showed the least. At 1 and 2 months postoperatively no significant difference was found between all the treated groups. For dentin bridge scores; there was no significant difference between all the materials at 7 days and 1 month. At 2 months; the MTA treated teeth recorded the greatest dentin bridge score as compared to all treated teeth. As for integrity of odontoblast score; results showed no significant difference between different materials at 7 days and 1 month. The MTA treated teeth showed the highest score as compared to PRP and PRF at 2 months. **Conclusion:** Among the three different materials, PRP and PRF appeared to be promising pulp capping agents.

KEYWORDS

*Platelets rich plasma,
platelets rich fibrin,
Mineral trioxide aggregate*

- Paper extracted from doctor Thesis Titled “Pulp Tissue Response to Platelets Rich Plasma, Platelets Rich Fibrin and Mineral Trioxide Aggregate as Pulp Capping Materials”
- 1. Assistant lecturer of operative dentistry, Faculty of dental medicine, Misr University for Science and Technology MUST, Cairo, Egypt.
- 2. Professor of operative dentistry, Faculty of dental medicine for Girls, Al-Azhar University, Cairo, Egypt.
- 3. Professor and head of operative dentistry, Faculty of dental medicine for Girls, Al-Azhar University, Cairo, Egypt.
- 4. Professor of Surgery, Anesthesiology & Radiology, Faculty of veterinary Medicine, Cairo University, Egypt.

* Corresponding author email: sarahdiaashaheen@yahoo.com

INTRODUCTION

Pulp vitality is important to the tooth health. Pulpal exposure may occur following trauma, dental caries and malformation of the teeth. The pulp vitality is maintained by the healing potential of the remaining coronal and the biocompatibility of pulp capping agents as well. Therefore, pulp capping is important in treatment of reversible pulpal exposure through sealing of the pulp. Subsequently, dentine formation occurs⁽¹⁾.

Pulp capping materials have been recommended after the use of gold foil. Also calcium hydroxide has become one of the most popular methods for pulp capping materials to form dentin bridge⁽²⁾. Mineral trioxide aggregate MTA has been an acceptable pulp capping material⁽³⁾. Moreover; many bio materials such as Platelets Rich Plasma (PRP), Platelets Rich Fibrin (PRF) have been used for direct pulp capping⁽⁴⁾.

Platelets rich plasma (PRP) has Antimicrobial effect, biocompatibility and promote healing. So it has been proposed as possible medicament for pulp capping. Platelet-rich fibrin (PRF) is high platelet concentrate which improves soft and hard-tissue healing⁽³⁾.

PRF has upper hand over the known PRP include ease of processing/application, minimal cost and no anticoagulant is required. PRF is a precisely autologous fibrin matrix containing a large number of platelet and leukocyte cytokine which play a substantial role in tissue formation and repair pulp complex⁽⁴⁾.

Mineral trioxide aggregate (MTA) has excellent physical and chemical properties and has been proposed as a potential medicament for use in pulpotomies⁽³⁾.

MTA is very useful material for pulp capping, pulpotomy, apical barrier formation in teeth with necrotic pulps and open apexes, repair of root perforations, root-end filling, and root canal filling⁽³⁾.

MATERIALS AND METHODS

Three pulp capping materials were used: Platelets rich plasma (PRP), Platelet-rich fibrin (PRF) and Mineral trioxide aggregate (MTA).

1. Selection of experimental animals and Randomization:

Six female mongrel dogs, aged between 12 to 18 months with intact dentition were enrolled for the present experimental study. The study was divided into three phases at different time intervals. Two experimental dogs were included in each phase. In each experimental dog; 15 teeth were selected. Randomization and allocation of the teeth were made using a computer-generated random table. Excel software (Microsoft) was used for randomization. Generation of random allocation sequences was done. Randomization, allocation concealment and blinding were implemented in the envelope technique which was applied in the study. The animal ID, location of teeth, the time of assessment and the materials applied were recorded in each envelope.

2- Sample size determination

A total sample size of 90 teeth, in six dogs were sufficient to detect an effect size of 3.24, a power of 0.8 and using a two-sided hypothesis test and a significance level 0.05 for categorical and numerical data. A total sample size of 72 minimum (24 for each group) was found sufficient to detect the effect size 0.40, a power of 95% and significant level of 5% ($p < 0.5$). For higher significance level ($p < 0.01$) a simple size of 30 samples for each group was recommended. Sample size was calculated using G*power program, Germany⁽⁵⁾

3- Animal grouping:

A total of ninety teeth of dogs were included in the study. The selected teeth were divided into three main groups of thirty teeth each ($n=30$) according to the material used for capping; A1: Platelets Rich Plasma, A2: Platelets Rich Fibrin and A3: Mineral Trioxide Aggregate (MTA). The biological tissue response to the tested materials used was assessed

at three different post-operative periods of 7, 30, 60 days⁽⁶⁾ thus each group was further subdivided into three subgroups of ten teeth each according to the time of assessment (n=10); T1: 7 days, T2: 30 days and T3:60 days.

4- Operative procedures:

A cannula was fixed in cephalic vein for each dog and used for injection solution (mixture of xylaine 1.0 mg\ kg body weight in combination with ketamine hydrochloride 5.0 mg/kg body weight) and anesthesia was maintained throughout the operative procedures⁽⁷⁾. Each dog was placed on operating table in supine position with tilted head to avoid obstruction in respiratory air way.

Class V cavities were prepared on the buccal surface of the selected teeth away 2 mm from the gingival margin 2mm in Buccolingual 3mm in mesiodistal 2mm in depth using round carbide bur (Mani, Germany) assembled on low speed micro motor under sterile copious water during preparation to avoid heat generation. A new bur was used for each tooth. Pulp exposure was performed in the middle of cavity floor with rounded carbide bur #1. Immediately after pulp exposure, dentine chips were washed with distilled water and light pressure to stop bleeding.

5- Application of pulp capping materials:

A- Application of PRP: The PRP was carried out with plastic syringe and applied directly at the exposure site. A tissue absorbent material was cut to small pieces 1mm width and 1mm length, a piece of tissue absorbent material membrane was applied over the PRP to ensure holding the material at the exposure site.

B- Application of PRF: The PRF was cut to small pieces 1mm width and 1mm length using tweezers and scalpel and this small piece of PRF was applied to the entire exposure site and small piece of tissue absorbent material membrane was applied onto the PRF pieces to ensure holding it in the exposure site.

C- Application of MTA: powder and purified water were placed on a clean glass slab then were mixed using a metal mixing spatula in ratio of 3:1 powder/ purified water in order to obtain a putty consistency. The excess moisture on the surface of the MTA mix was removed with a sterile cotton pellet and an amalgam carrier was used to deliver the MTA mix onto the pulp exposure site then the mix was compacted lightly with a slightly moistened sterile cotton pellet to ensure an even thickness coverage of 3 to 4 mm.

6- Teeth extraction and animal sacrifices:

The experimental study was approved from the ethical committee of AL-Azhar University (Girls). Two experimental dogs were included in each assessment time. After the testing periods 7 days (T1), 30 days (T2) and 60 days (T3), the dogs on this group were sacrificed by injection of an overdose of 10% thiopental sodium. The maxilla and the mandible of the animal were separated and divided to right and left quadrant and directly was fixed in 10% formaldehyde solution for 10 days. The hemisectioned jaws were demineralized using 50% formic acid and sodium citrate for two months. After complete decalcification, the teeth were extracted from the bone by specified scalpel. The specimens were placed in the demineralizing solution two weeks more.

7- Preparation for histological study

After the teeth were demineralized, the specimens were embedded in paraffin wax and serial sections of 0.5 mm thickness were prepared through the pulp exposure using microtome. All the sections were stained with hematoxylin and eosin.

8- Image analysis

The sections were blindly evaluated by pathologist according to the criteria previously established. All the images of the slide were captured using digital camera which was mounted on light microscope. Images were then transferred to the computer system for image analysis. The image computer

analysis for system used software (Lecia Quin 500) to count automatically inflammatory cells number. The mean count of inflammatory cells was measured from nine fields of different slides. The dentin bridge formation was scaled from the slides by the following scoring system: 0-No presence of dentin bridge formation. 1- Presence of incomplete dentin bridge in the region of pulp injury. 2- Presence of dentin bridge lying at the lateral surface of the pulp. 3- Presence of complete dentin bridge formation. The morphology and the integrity of the odontoblast were scaled from the slides by the following scoring system: 0-Normal pulp tissue. 1- Disorganization of odontoblast like cells proliferation. 2- Complete disorganization of pulp tissue. 3- Pulp necrosis⁽⁸⁾.

Statistical analysis

The Normality test (shaperio wilk test) was used. Inflammatory cell count; the date showed parametric distribution; so regression model using One-way Analysis of Variance (ANOVA) was used in testing significance for the effect of material, time and their interactions on inflammatory cell count. Tukey's post-hoc test was used for pair-wise

comparison between the groups when ANOVA test is significant. The significance level was set at $P \leq 0.05$. Scoring of dentin bridge formation and integrity of odontoblast score; the data were of non-parametric. Hence, kruskal wallis test was used for statistical analysis.

RESULTS

Regarding the effect of different materials following pulp capping on the count of inflammatory cell at intervals; at one week, PRP exhibited the greatest inflammatory cell count, followed by MTA then the least was shown by PRF. The result showed high significant difference between the different groups. While in one month and two months results showed no significant difference between the tested materials.

Regarding the effect of different time intervals on inflammatory cell count after pulp capping using different materials, all the treated material showed high count of inflammatory cells at one week, then the count decrease at one month and two months. The differences were highly significant for different follow up periods, for each material. (Table.1)

Table (1) Inflammatory cells count for PRP, PRF and MTA at different assessment intervals.

Time	Material	Platelet rich plasma (PRP)		Platelet rich fibrin (PRF)		Mineral trioxide aggregate (MTA)		P- value
		Mean	SD	Mean	SD	Mean	SD	
One week		262.9	46.2	166.5	32.9	212.1	24.5	0.000
One month		81.8	40.7	65.1	25.01	80	28.2	0.490
Two months		43.5	23.8	28.7	15.2	25.6	12.2	0.091
P- value		0.000		0.000		0.000		

$P \leq 0.05$: Significant difference, $P > 0.05$: No significant difference.

Assessment of Dentin Bridge Formation: The data were non-parametric hence, kruskal wallis test was used for statistical analysis. For PRP, one week follow up period showed the least dentin bridge score, followed by one month then two months showed the highest dentin bridge score. The difference was highly significant (HS). For PRF, one week follow up period showed the least dentin bridge score, followed by one month then two months showed the highest dentin bridge score. The difference was highly significant (HS). For MTA, one week follow up period showed the least dentin bridge score, followed by one month then two months showed the highest dentin bridge score. The difference was highly significant. Regarding materials effect, at one week and one month showed no significant different between materials. While at two months MTA showed the highest dentin bridge thickness followed by PRF and the least was PRP (Table.2).

Integrity of odontoblast and odontoblast like cells as well as pulp tissue, result revealed that; for PRP and PRF, one week follow up period showed the highest odontoblast score followed by one month and two months showed the least odontoblast score. The difference was not significant. For MTA, one week follow up period showed the highest odontoblast score followed by one month then, two months which showed the least odontoblast score. The difference was highly significant. For each assessment time intervals, for one week, PRP showed the highest odontoblast score followed by PRF then MTA. The difference was not significant. For one month, PRP showed the highest odontoblast score, followed by PRF then, MTA. The difference was not significant. For two months, PRP showed the highest odontoblast score, followed by PRF then, MTA. The difference was significant(S) (Table.3).

Table 2: Dentin bridge scores for PRP, PRF and MTA at different assessment Intervals.

		Material			P-value	
		(PRP)	(PRF)	(MTA)		
Dentin Bridge Formation Score	One week	Median	0	0	0	1.000
		Maximum	0	0	0	
		Minimum	0	0	0	
		Rank	14 ^a	14 ^a	14 ^a	
	One month	Median	1	1	2	0.117
		Maximum	2	2	2	
		Minimum	1	0	1	
		Rank	13.3 ^a	11 ^a	17.67 ^a	
	Two months	Median	2	3	3	0.044
		Maximum	3	3	3	
		Minimum	1	1	2	
		Rank	9.3 ^c	15.33 ^b	17.33 ^a	

P ≤ 0.05: Significant (S) P ≤ 0.01: Highly significant (HS). P > 0.05: Non-significant (NS).

Different superscript in the same row indicated significant difference.

Table 3: Integrity of odontoblast scores for PRP, PRF and MTA at different assessment Intervals.

		Material			P-value	
		(PRP)	(PRF)	(MTA)		
Integrity of Odontoblast	One week	Median	2	1	1	0.273
		Maximum	2	2	2	
		Minimum	1	1	1	
		Rank	17 ^a	12.5 ^a	12.5 ^a	
	1 month	Median	1	1	1	0.129
		Maximum	3	2	2	
		Minimum	1	0	0	
		Rank	17 ^a	13.4 ^a	11.1 ^a	
	2months	Median	1	1	1	0.027
		Maximum	2	2	1	
		Minimum	1	0	0	
		Rank	18.5 ^a	13.6 ^b	9.9 ^c	

$P \leq 0.05$: Significant (S).

Different superscript in the same row indicated significant difference.

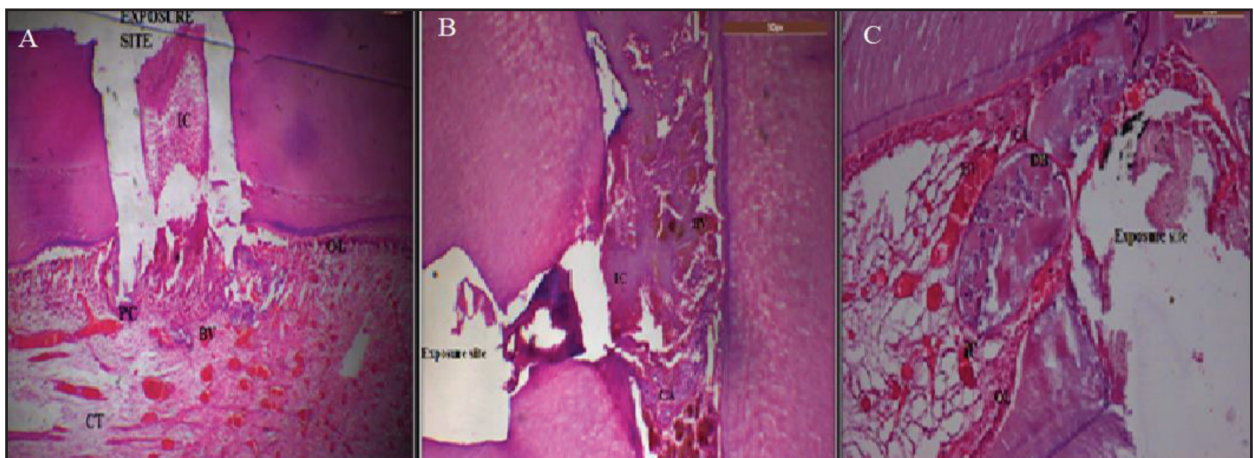


Figure (1) Histomorphology at exposure site using PRP after different testing periods. A: PRP at one week, B: PRP at one month, C: PRP at two months. BV: blood vessels, C: calcified area OL: odontoblastic layer, M: mineralized area. IC: inflammatory cells, V: vacuole.

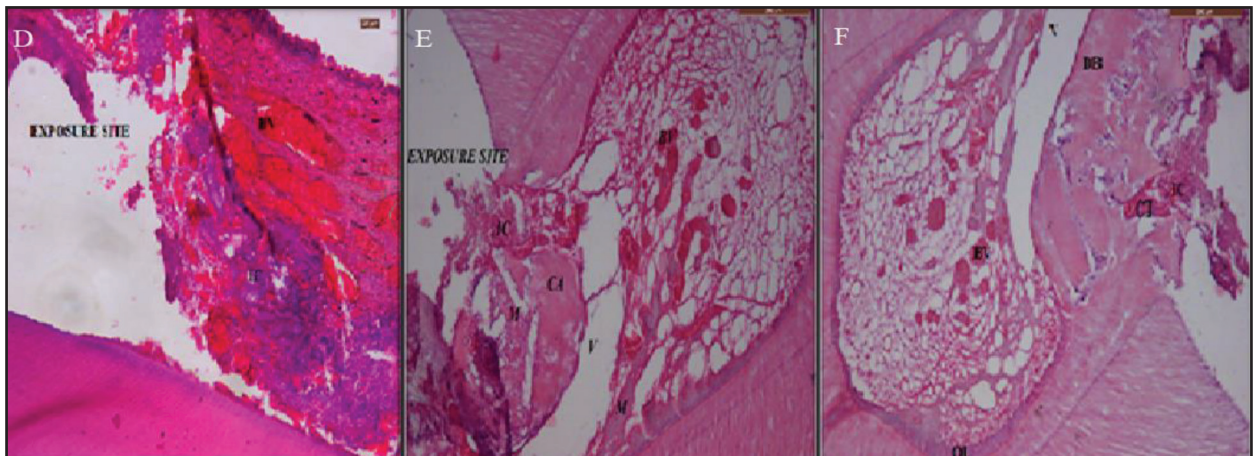


Figure (2) Histomorphology at exposure site using PRF after different testing periods. D: PRF: at one week, E: PRF at one month, F: PRF at two months. BV: blood vessels, C: calcified area OL: odontoblastic layer, M: mineralized area. IC: inflammatory cells, V: vacuole.

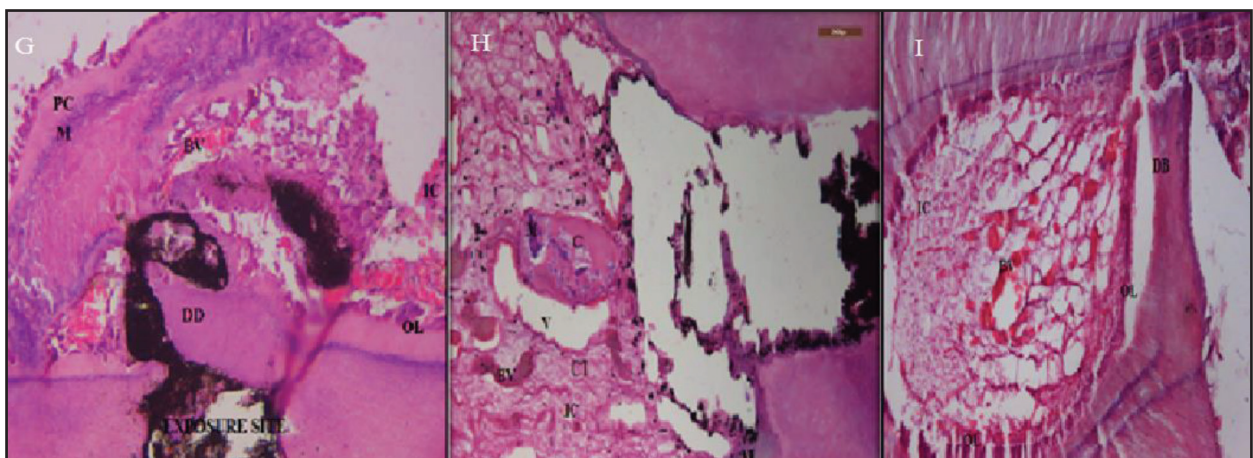


Figure (3) Histomorphology at exposure site using MTA after different testing periods. G: MTA at one week, H: MTA at one month, I: MTA at two months. BV: blood vessels, C: calcified area OL: odontoblastic layer, M: mineralized area. IC: inflammatory cells, V: vacuole

DISCUSSION

On the buccal surface of teeth dogs, class V cavities were prepared, as the cavity was close to pulp tissue and fewer forces applied on it. A new bur was used for each tooth to ensure the cutting efficiency⁽⁹⁾. The pulp exposure was performed. The pulp response was monitored at three periods; a short period of seven days to monitor the initial inflammatory pulp response to the capping materials, then 30 and 60 days to show progressive or limited extension of pulp response⁽¹⁰⁾.

On comparing the effect of treated teeth on the inflammatory cell count, PRP treated teeth showed the highest number of inflammatory cell count as compared to PRF and MTA in 7 days. However, there was no significant difference between the tested materials at one month and two months. This result may be due to the use of thrombin in activating the PRP which stimulate the immunogenic reaction thus increasing the inflammatory reaction⁽¹¹⁾. However, PRF treated teeth exhibit the least count after 7 days. This could be related to the biocompatibility

and bioactivity of PRF⁽¹²⁾. MTA had moderate inflammation reaction compared to the other treated material at one week, this moderate inflammation could be due to high alkalinity and this inflammation is a reversible process⁽¹³⁾.

Regarding the effect of different time intervals on inflammatory cell count was recorded at using different materials; high inflammatory cell count was recorded at 7 days after pulp capping then the count of the cells was decreased at one month and two months. It was found that tissue healing and pulp formation is a precondition to the inflammation. Due to the high alkalinity of the capping agent, inflammatory processes start. Cells move along the root and migrate towards the crown, cells display and proliferate and increase in number and size, thus the mineralization is initiated and becomes thicker. Moreover, the operative trauma may explain the initial slight inflammatory response and tissue organization after 7 days and the decreased inflammatory reaction at one month and two months was due to self-repair processes⁽¹⁴⁾.

On comparing the effect of different materials on dentin bridge formation score at each assessment time, it was found that the MTA treated teeth recorded the highest score in dentin bridge formation compared to PRP and PRF treated teeth at two months assessment time. It was shown that MTA was able to stimulate hard tissue formation after vital pulp therapy with no signs of inflammation due to its excellent control infection via high alkalinity which denatured bacterial proteins, and releasing calcium and hydroxyl ions. Hydroxyl ions react with bacterial DNA, inhibiting replication and destroyed bacterial cellular membrane⁽¹⁵⁾.

PRP the least score in dentin bridge formation compared to MTA and PRF treated teeth at two months assessment time. This was in agreement with a study which reported that the problem lies in the PRP preparation errors as it involves technical sensitivity of the several steps in its preparation⁽¹⁶⁾.

Regarding the PRF treated teeth, results showed that PRF has moderate score in dentin bridge formation compared to MTA and PRP treated teeth at two months assessment time. This result may be explained by the fact that PRF induced cell propagation and differentiation of pulp cells by up-regulating osteoprotegerin and Alkaline phosphatase expression, which express the role of PRF in reparative dentin formation⁽¹⁷⁾.

As for the effect of different time intervals on dentin bridge formation score for each material. Results showed no dentin bridge formation in one week assessment time in all the treated groups with no significant difference between them. It was approved that no hard dentin barriers could be formed in less than 2 weeks. In fact, in most studies, the time needed for hard tissue barrier formation has been reported to be from 30 to 60 days^(18,19).

Regarding the effect of different materials on the integrity of odontoblast, result revealed that, MTA treated teeth stimulated the greatest number of odontoblast-like cells at the site of pulp exposure at two months. It was found that MTA proved to be efficient suppressors of prostaglandins and pro-inflammatory cytokines, and up-regulators of odontoblast cells differentiation or growth factors involved in pulp regeneration⁽²⁰⁾. PRF induced significantly odontoblast cells differentiation when compared with PRP in two months, this was in agreement with other study which approved that PRF contains a supra physiological concentration of leukocytes which are the primary cell responsible for fighting against bacterial invasions and has an influence on odontoblast proliferation⁽²¹⁾. Regarding the PRP treated teeth, the number of odontoblast cells correlating with PRP pulp; it was shown that it stimulates greater number of odontoblast cells at the site of pulp exposure. Odontoblast cells require perfect seal to an appropriate surface before cell proliferation and dentin bridge formation⁽²⁰⁾.

Regarding the effect of different time intervals on the integrity of odontoblast score for each

material; for PRP and PRF, one week follow up period showed the highest odontoblast score followed by one month, while two months showed the least odontoblast score. The difference was not significant. For MTA, one week follow up period showed the highest odontoblast score followed by one month then, two months showed the least odontoblast score. The difference was highly significant.

This finding was in accordance with studies that demonstrated the natural ability of the pulp to form dentine bridges by odontoblastic cell differentiation under most types of pulp capping materials, as long as a perfect seal is provided⁽²¹⁾.

Results revealed that higher dentin bridge formation were associated with higher structural regularity in the organization of the sub odontoblastic layers and this observation was in agreement with previous studies as specimens with the highest cell density showed reparatory bridges with thicker and higher structural regularity^(22,23).

CONCLUSION

1. Pulp capping with different tested materials induced pulp tissue response with varying degrees, in terms of inflammatory cells, dentin bridge formation and odontoblastic integrity.
2. Platelets rich plasma and platelets rich fibrin appeared to be promising pulp capping agents.
3. There was a direct correlation between odontoblastic layer regularity, integrity and dentin bridge formation.

REFERENCES

1. Vafaei A, Azima N, Erfanparast L, Lovschall H, Ranjkesh B. Direct pulp capping of primary molars using novel fast-setting calcium silicate cement: a randomized clinical trial with 12-month follow-up. *J Biomater Dent*. 2019; 6:73-80.
2. Kiranmayi G, Hussainy N, Lavanya A, Swapna S. Clinical performance of mineral trioxide aggregate versus calcium hydroxide as indirect pulp-capping agents in permanent teeth: A systematic review and meta-analysis. *J Int Oral Health*. 2019; 11:235-43.
3. Gomez W, Gopal V, Gaffoor A, Kumar R, Girish S, Prakash R. Comparative evaluation of angiogenesis using a novel platelet-rich product: an in vitro study. *J Conserv Dent*. 2019; 22:23-7.
4. Murray E. Platelet-Rich Plasma and Platelet-Rich Fibrin Can Induce Apical Closure More Frequently Than Blood-Clot Revascularization for the Regeneration of Immature Permanent Teeth: A Meta-Analysis of Clinical Efficacy. *J Eur Dent*. 2018; 11:139-45.
5. Gupta K K, Attri J P, Singh A, Kaur H, Kaur G. Basic concepts for sample size calculation: Critical step for any clinical trials!. *Saudi J Anaesth* 2016; 10:328-31.
6. Verboket R, Herrera-Vizcaino C, Thorwart K, Booms P, Bellen M, Al-Maawi S, Sader R, Marzi I, Henrich D, Ghanaati S. Influence of concentration and preparation of platelet rich fibrin on human bone marrow mononuclear cells (in vitro). *J Blood*. 2019; 30:861-70.
7. Landoni G, Lomivorotov VV, Nigro Neto C, et al. Volatile anesthetics versus total intravenous anesthesia for cardiac surgery. *Eng. J Med*. 2019; 380: 1214- 25.
8. Dou L, Qifang Y, Yang D. Effect of five dental pulp capping agents on cell proliferation, viability, apoptosis and mineralization of human dental pulp cells *J exp med* 2020;19: 2377-83.
9. Ha W, Bvsc R. Direct pulp capping agents in dogs - Systematic Review. *J Endod* 2020; 3:12-6.
10. Metlerska J, Fagogeni I, Nowicka A. Efficacy of Autologous Platelet Concentrates in Regenerative Endodontic Treatment: A Systematic Review of Human Studies. *J Americ Endod*. 2019; 45:50-8.
11. Mudalal M, Sun X, Li X, Zhou Y. The evaluation of leukocyte-platelet rich fibrin as an anti-inflammatory autologous biological additive. A novel in vitro study. *J Saudi Med*. 2019; 40:657-68.
12. Lopes C, Junqueira M, Cosme S, Camila D. Initial inflammatory response after the pulpotomy of rat molars with MTA or ferric sulfate. *J Appl Oral Sci* 2019; 27:40-9.
13. Giraud T, Rombouts C, Bakhtiar H, Laurent P. Pulp capping materials modulate the balance between inflammation and regeneration. *J Dent Mater*. 2019; 35:24-35.
14. Dimitraki D, Papageorgiou D, Kotsanos N. Direct pulp capping versus pulpotomy with MTA for carious primary molars: a randomized clinical trial. *J Eur Pedo Dent*. 2019; 3:102-10.
15. Dhurat R, Sukesh M. Principles and Methods of Preparation of Platelet-Rich Plasma: A Review and Author's Perspective. *J Cutan Aesthet Surg*. 2016; 7: 189-97.

16. Manhas M, Mittal S, Sharma A, Gupta K, Pathania V, Thakur V. Biological approach in repair of partially inflamed dental pulp using second-generation platelet-rich fibrin and mineral trioxide aggregate as a pulp medicament in primary molars. *J Indian Pedo* 2019; 37:399-404.
17. Petta M, Pedroni A, Saavedra F, Faial F, Marques M, Couto D. The effect of three different pulp capping cements on mineralization of dental pulp stem cells. *J Dent Mater.* 2019; 2:12-21.
18. Yuan C, Xinlei C, Yali Z, Fangjie Z, Jiabin D. Materials for pulpotomy in immature permanent teeth: a systematic review and meta-analysis *BMC Oral Health* 2019; 1:227-33.
19. Abdalla M, Lung C, Neelakantan P, Matinlinna J. novel, doped calcium silicate bioceramic synthesized by sol-gel method: Investigation of setting time and biological properties. *J Biomed Mater Res B Appl Biomater.* 2020; 108:56-66.
20. Hong S, Chen W, Jiang B. A comparative evaluation of concentrated growth factor and platelet-rich fibrin on the proliferation, migration, and differentiation of human stem cells of the apical papilla. *J Endod.*2018; 44:977-83.
21. Salem A, Baiomy S, Abdallah A. The effect of triple antibiotic paste on pulp capping of primary teeth. *ADJ-for Girls,* 2018; 3: 205:8.
22. Aidaros N, Niazy M, El-yassaky M, The Effect of Incorporating Nanocalcium Phosphate Particles into Biodentine on Pulpal Tissue Response (In Vitro Study) *ADJ-for Girls,* 2018;2; 181:6.
23. Jin R, Chai J, Yuan G, Kanter V, Miron RJ, Zhang Y. Effect of Liquid Platelet-rich Fibrin and Platelet-rich Plasma on the Regenerative Potential of Dental Pulp Cells Cultured under Inflammatory Conditions: A Comparative Analysis. *J Endod.* 2019; 45:1000-8.