

Dept. of Surgery,
Faculty of Vet. Med., Zagazig Univ., Benha-Branch,
Head of Dept. Prof. Dr. G.M. Othman.

A STUDY OF SOME SURGICAL AFFECTIONS OF THE TAIL IN SOME DOMESTIC ANIMALS (With 1 Table & 8 Figs.)

By
S.F. ISMAIL
(Received at 4/11/1990)

دراسات عن بعض الاصابات الجراحية التي تصيب الذيل في بعض
الحيوانات الأليفة

— سامي فرغلي

تم تسجيل ٧٤ حالة اكلينيكية تعاني من اصابات مختلفة في الذيل وقد تم تقسيم هذه
الاصابات الى اصابات خلقية وأخرى مكتسبة . والاصابات الخلقية التي تم تسجيلها هي :
عدم وجود ذيل ، وجود أكثر من ذيل ، والتواء الذيل وانشطاره الى جزئين . أما الاصابات
المكتسبة فكانت تشمل : جروح الذيل بأشكالها المختلفة ، خراجات الذيل ، تنقرض الذيل
والأورام .

SUMMARY

Different varieties of surgical affections of the tail were recorded in the present study. These affections may be congenital or acquired. The congenital affections include: Anury (2-cases) wrytail (1-case), Double tail (1-case) and Bived tail (1-case). While the acquired affections include: tail injury (39 case), abscesses (11 case), necrosis (16 cases) and tumours (3 cases).

INTRODUCTION

Tail affections may be congenital or acquired. The congenital affections of the tail were recorded alone (FISCHER, 1966 and GATTINGER, 1984), or may be accompanied by other congenital anomalies (BROOKSPANK, 1972 and MISK, BHARGAVA and SINGH, 1984). The congenital affections include complete absence of the tail "Anury" (DREYER, 1964 and MISK, *et al.* 1984), diviation of the tail "Wrytail" (DENNIS, 1972) and presence of more than one tail "Polyury" (DENNIS, 1972 and GATTINGER, 1984).

Different acquired affections of the tail were recorded in the available literatures. These affections include: Wounds (O'CONNOR, 1950 and CHRISMAN, 1982); tail necrosis

(BARAKAT; WAHBY and ABDALLA, 1960; GOHAR; ABDEL-HAMID, AHMED and IBRAHIM, 1988), Tail biting (LOHR, 1983); Abscessation (PENNY, 1975) and Tumours (O'CONNER, 1950).

The aim of the present investigation is to study some surgical affections of the tail in some domestic animals.

MATERIAL and METHODS

A total number of 74 animals (37-buffaloes, 9-cattle, 20 sheep, and 8 camels) were presented to the clinic of the Fac. Vet. Med., Moshtohor & collected from the governmental farms surrounding it. These animals suffered from different varieties of surgical affections of the tail. Each case was fully studied concerning the case history, clinical symptoms, diagnosis and differential diagnosis, and possible medical and/or surgical treatments.

Some surgical affections that recommend docking or amputation of the tail were performed under the effect of posterior epidural anaesthesia. While minor surgical interventions were enough to be performed under the effect of ring block anaesthesia using procaine HCl 2% solution. Viscious animals were tranquilized using Rumpun in a dose rate of 0.08 mg/kg b.w. in buffalo, 0.05 mg/kg b.w. in cattle and 0.2 mg/kg b.w. in sheep.

The tumour specimens were preserved in 10% formaline solution and subjected to histopathological examination.

RESULTS

The different congenital and acquired affections of the tail recorded in the present study were tabulated in Table 1.

I - Congenital affections of the tail: (5-cases).

a) Anury (Taillessness):

Complete absence of the tail was recorded in two cases. One of them in a freisian cattle and not accompanied by any other congenital abnormalities (Fig. 1 a). The second case was recorded in one twine of a conjoined buffalo twins (Fig. 1 b).

b) Wrytail:

Twisted tail was recorded only in one camel (Fig. 2 b).

TAIL AFFECTIONS

c) Polyury:

Double tails was recorded in the other twine of the conjoined buffalo twins (Fig. 1 b).

d) Bived tail:

This condition was recorded in a dicephalus buffalo fetus. The tail started its bifurcation nearly at its middle portion (Fig. 2 a).

II - Acquired affections of the tail:a) Tail injuries:

The causes that lead to traumatic injuries of the tail were stepping over by other animal and barbed wire traumas. Biting the tail by vicious dogs or other wild animals was commonly recorded in newly born lambs (Fig. 3 a). In buffaloes, cattle and camels the cause was mainly due to crushing the tail by the metal doors of the farms or due to rubbing of the tail (infected with mange) against hard objects leading to its laceration (Fig. 5 a). Most of the tail injuries recorded in the present study were in the form of recent or old septic wounds. In sheep, most of these wounds are open and lacerated in type and undergo a large extensive area of skin loss (Fig. 3 a). In most of these cases tail reconstruction was imposible. In one case the traumatic injury was recorded in the form of a subcutaneous traumatic cyst. In such case the inflammatory transudate accumulated between the skin and the fat of tail leading to a cystic formation in the ventral aspect of the fatty tail (Fig. 4 a).

Sheep pox lesions were recorded in the form of skin ulcers over the dorsal aspect of the fatty tail (Fig. 5 b).

Wounds and lacerations of the tail were corrected as usual as the principle line of wound treatment whether recent or old septic wounds. Partial or complete amputation of the tail was performed when the lesions accompanied by fracture of the vertebral column or when the area of skin loss was highly extensive (Fig. 3 b).

b) Tail abscesses:

The abscesses were recorded in 11 cases (10 buffaloes and 1 sheep). The abscesses in the buffalo tails were present on the ventral aspect of its proximal 1/3. These abscesses are characterized by formation of one or more movable subcutaneous capsulated swellings, ranged in size from a pea to a hens egg-like swelling (Fig. 6 b). Complete surgical excision of most of these abscesses was performed.

In sheep the abscess was detected at the lateral margin of the fatty tail near its junction with the animal body. In such case the abscess was treated by opening and evacuation of its contents (Fig. 7 a).

c) Tail necrosis:

Necrosis of the tail was recorded in 16 case (12 buffaloes and 4 cattles). The

lesion begins at the tip of the tail with inflammatory swelling accompanied by falling down of the hairs. The lesion gradually extend upward with thickening and hyperkeratinization of the affected part. As the lesion extends proximally, a line of demarcation is seen between the distal necrosed part and the proximal healthy portion (Fig. 8 a). Surgical amputation 2 cm above the level of the necrosed part was performed in most cases (Fig. 8 b).

d) Tail tumours:

Tumour like swellings of the tail were recorded in 3 cases. Histopathological examination revealed that two out of the 3 cases were neoplastic. They were present at the ventral aspect of the most proximal part of the tail. The first one was recorded in buffalo. It was pedunculated papilloma, cauliflower like in shape, firm in consistency and greyish in colour (Fig. 7 b). This swelling was removed by application of silk ligature at its neck. Sloughing occurred after 3 days. The second case recorded in freisian cattle was a fibropapilloma. It was a cauliflower like in appearance and occupy a large areas of skin in the ventral aspect of the tail (Fig. 6 a). This tumour was surgically excised after application of two artery forceps at its base. Then the skin wound was sutured using simple interrupted manner.

The 3rd swelling was recorded at the distal end of a buffalo tail. Such swelling was diagnosed pathologically as a chronically inflamed granulation tissue. Necrosis was noticed to extend upward with thickening and hyperkeratinization until it involve the distal 1/3 of the tail (Fig. 8 a). In this case partial amputation of the affected part of the tail including the swelling was performed (Fig. 8 b).

Table (1):

Tail affections	Animal species				
	Buffaloes	Cattle	Sheep	Camel	Total
I Congenital affections:					
a) Anury	1	1			2
b) Wrytail				1	1
c) Polyury	1				1
d) Bived tail	1				1
II Acquired affections:					
a) Tail injuries	10	3	19	7	39
b) Tail abscesses	10		1		11
c) Tail necrosis	12	4			16
d) Tail tumours	2	1			3
Total	37	9	20	8	74

TAIL AFFECTIONS

DISCUSSION

The most common congenital affections of the tail recorded in the present study were Anury, Wrytail, Polyury and Bived tail. Most of these affections were recorded with other congenital anomalies. The same results were stated by HUSTON, *et al.* (1958) and MISK, *et al.* (1984). Anury was recorded in freisian cattle without any other congenital anomalies.

Traumatic injuries of the tail were recorded mainly in sheep and less frequently observed in other animals. The high incidence of these injuries in sheep may be due to the large size of the tail and presence of large amount of fats. This render it easily to be lacerated from any direct trauma. The general principles of wound treatment were performed for most of these cases. Partial or complete amputation of the tail was indicated to the highly lacerated wound with an extensive areas of skin loss or accompanied by fracture of the vertebral column.

Abscesses of the tail were recorded mainly in buffaloes. Well circumscribed, capsulated and movable abscesses were present subcutaneously. So, the surgical excision of these abscesses was easily performed (AZIZ, 1990). Presence of these abscesses at the ventral aspect of the proximal 1/3 of the tail may be attributed to the continuous friction to such as area of the tail against the perineal region which is always soiled with the fecal matter.

Tail necrosis was the most common affection recorded in buffaloes in the present study. The same clinical symptoms recorded in these cases were described by BARAKAT, *et al.* (1960) and GOHAR, *et al.* (1988). Partial amputation of the affected part of the tail was the radical treatment in such conditions.

Tumour like swelling of the tail was recorded sporadically in few cases (3 cases). The same results were obtained by O'CONNOR (1950). Only two cases were neoplastic, one of them in buffalo (papilloma) and the second case in freisian cattle (Fibropapilloma). The third swelling was diagnosed as a chronically inflamed granulation tissue. PALLASKE and DIETZ (1955) recorded a similar swelling at the end of the tail in a cow.

REFERENCES

- Aziz, M.S. (1990): Comparative and applied surgical anatomy of the tail with special reference to its surgical affections in some domestic animals. M.Vet.Sc., Fac. Vet. Med., Assiut Univ.
- Barakat, M.Z.; Wahby, A.M. and Abdalla, A. (1960): Necrosis of the tail in the buffalo. British Vet. J.; Vol. 116, No. 4: 151-154.

- Brookspank, N.H. (1958): Congenital deformity of the tail in pigs. *British Vet. J.*, Vol. 114: 50-56.
- Chrisman, C.L. (1982): Problems in small animal neurology. Lea and Febiger. Philadelphia. 1st ed.
- Dennis, S.M. (1972): Congenital tail defects in lambs. *Cornell Veterinarian*, Vol. 62, No. 4: 568-572.
- Dreyer, V.D. (1964): Complete lack of the tail in freisian calf. *Deutsche Tierarztliche wochenschrift*, Vol. 71: 586-589.
- Fischer, H. (1966): Short-tailed Murrah buffaloes *Zentralblatt fur veterinar medezine*, Vol. 13 A, No. 4: 352-355.
- Gattinger, V.C. (1984): Double tail in a cow. *Wien-stierarzti. Mschr*, Vol. 71, No. 2: 74-77.
- Gohar, H.M.; Abdel-Hamid, M.A.; Ahmed, A.S. and Ibrahim, I.M. (1988): Tail necrosis in the horse. *Assiut Vet. Med. J.*, Vol. 19: 92-95.
- Huston, K. and Wearden, S. (1958): Congenital taillessness in cattle. *The journal of dairy science*, Vol. 41: 1359-1362.
- Lohr, J.E. (1983): Tail biting in pigs. *Newzealand Vet. J.*, Vol. 31: 205-208.
- Misk, N.A.; Bhargava, A.K.; Singh, C.R. (1984): Congenital sacral deformity, taillessness and atresia ani in a calf. *Mod. Vet. Pract.*, Vol. 64: 312-316.
- O'Connor, J.J. (1950): *Dollar's. Vet. Surgery*, fourth ed., London. Bailliere, Tindal and Cox.
- Pallaske, V.C. and Dietz, O. (1955): Tumour at the end of the tail in a cow. *Berliner und Munchener Tierarztliche Wochenschrift*, Vol. 68: 55-59.
- Penny, R.H.C. (1975): Tail biting in pigs. *J. Am. Vet. Med. Associ.*, Vol. 166: 963-965.

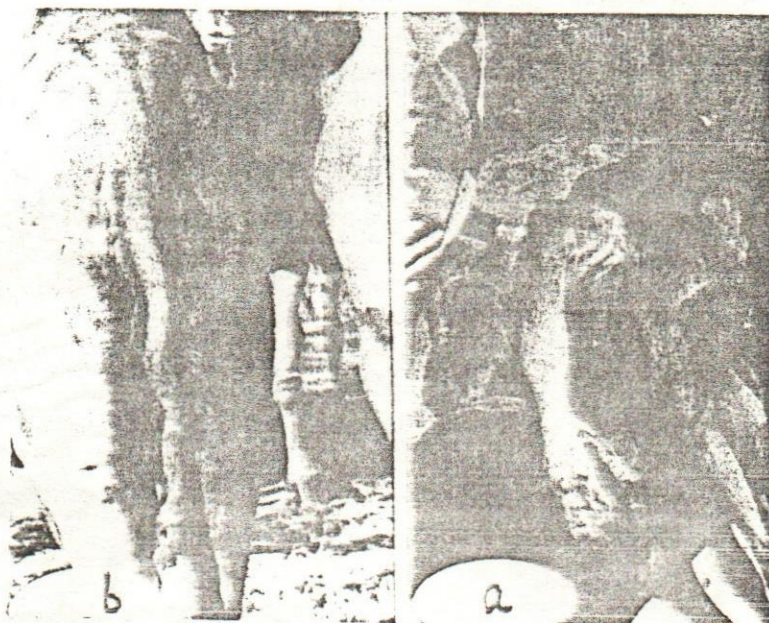

LEGANDS

- Fig. (1): a)** Taillessness in a freisian cattle.
b) A conjoined buffalo twins, taillessness was appeared in the upper twine while the lower one has a double tail.
- Fig. (2): a)** Bived tail in a dicephalus buffalo fetus.
b) Wrytail in a camel.
- Fig. (3): a)** Biting wound in a tail of sheep, lamb, the wound was severely lacerated and udergoes a large extensive area of lossed skin.
b) The same animal after amputation of the severely lacerated wound.
- Fig. (4): a)** A subcutaneous traumatic cyst in fatty tail. Note the transudate exuded from the opening of th exploritory puncture.
b) The same case after incising the cyst wall for further exploration. Note, the skin was separated from the underlying fatty tissues.

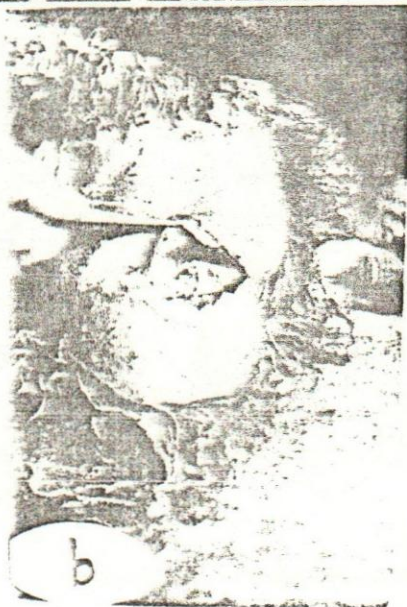TAIL AFFECTIONS

- Fig. (5): a) Tail lesions induced by mange infestation in a buffalo.
b) Sheep pox lesions. Note, the skin ulcers over the dorsal aspect of the fatty tail.
- Fig. (6): a) Cauliflower-like fibropapilloma at the ventral aspect of the tail of freisian cattle.
b) Movable subcutaneous and capsulated abscess at the ventral aspect of a buffalo tail.
- Fig. (7): a) Abscess at the lateral margin of the fatty tail near its junction with the animal body.
b) A cauliflower-like, pedunculated papilloma at the ventral aspect of a buffalo tail.
- Fig. (8): a) A chronically inflamed granulation tissues at the end of the tail (swelling). Necrosis of the tail was seen to be extend upward with thickening and hyperkeratinization.
b) The same case after amputation of the affected part including the swelling.

S.F. ISMAIL



TAIL AFFECTIONS





TAIL AFFECTATIONS

