

Non operative conservative management of blunt trauma to the spleen in Children: A Single Tertiary Hospital Experience

Mabrouk Akl¹, Ayman Albaghdady², Ahmed Elshazly³, Hala Fouad C, Hany Embaby⁴, Mary KeriakosN, Mahmoud Elshahawy⁴, Diaan EldeebN, Mohamed ElshafeyN, Abdelrahman Elsabaa⁴.

¹ Alazhar University (Pediatric surgery department), ² Ain Shams University, ³ Banha University, C: Cairo University, ⁴ Nasser institute for research and treatment

Abstract

Background: Splenic injury is the leading cause of major bleeding in the patients of blunt abdominal trauma. In earlier medical practice, the blunt splenic injury was managed surgically in most cases, but the increased understanding of the splenic function in the immunological process and the identification of post-splenectomy complications have led physicians to prefer the non-operative management.

Material and methods: A retrospective study of the patients with blunt trauma to the spleen in the pediatric age group between the year 2015 and 2018. The study was conducted in (Nasser Institute Hospital for research and treatment). Management of the patients was done using hypovolemic resuscitation and serial follow up. Abdominal ultrasound, complete blood picture and Abdominal CT were done. Data was tabled and analyzed.

Results: A total of 123 blunt splenic trauma patients were identified. Traffic-related accident and falling from height were the main mechanisms of injury. Splenic contusion and hematoma were the most frequent finding on initial computerized tomography (CT) scans, followed by shattered spleen, blush, and devascularization. Non-operative management failed in 6 patients who underwent splenectomy. (95.12%) of the patients managed successfully using hypovolemic resuscitation without need for surgical interference.

Discussion: Non-operative management is considered for patients with low-grade splenic injuries, unless operated upon for other associated injuries. In fact, higher-grade injuries could also be managed non-operatively. Splenic angioembolization of bleeding vessels increased the success rate of non-operative management in hemodynamically stable patients. In our study, although we didn't use splenic angioembolization we were able to reach high rates of success. In comparison with the operative management of blunt splenic trauma, the non-operative management has the added benefit of preserving the splenic functions.

Conclusions: Most blunt splenic trauma patients were successfully treated non-operatively, with a low failure rate. The severity of injury and presence of associated lesions should be carefully considered in developing the management plan.

Key Words: Spleen, Pediatric, Injury, Non-operative management, NOM.

Introduction

Blunt trauma is one of the most common causes of morbidity and mortality in children. In spite of the great prevention efforts, blunt abdominal trauma (BAT) still remains a leading cause of morbidity and mortality especially in children. The mode of trauma is variable but the most common cause is traffic accident, which represents about 75-80%. Other causes include falling from a height, bicycle handlebar injuries, injuries in contact sports or child abuse. The organs most commonly injured are the spleen and the liver followed by the kidney, the pancreas, the urinary bladder and hollow viscera⁽¹⁾. As the

spleen is one of the most commonly injured organ in blunt abdominal trauma patients, its management was a point of controversy.

The risk of laparotomy, the discovery of the immunological role of the spleen and the recognition of the risk of the overwhelming postsplenectomy infection (OPSI), all these factors, made the non-operative management of blunt splenic injuries is the treatment of choice in hemodynamically stable patients⁽²⁾. The Advantages of the non-operative management include a decreased lifetime risk of developing overwhelming postsplenectomy infection, a shorter hospital stay, fewer blood transfusions, and a

decreased overall mortality and morbidity. Despite of these advantages, adult trauma surgeons are still less likely than pediatric surgeons to proceed into a nonoperative management plan when presented with the same clinical scenario of pediatric solid organ injuries⁽³⁾.

Material and methods

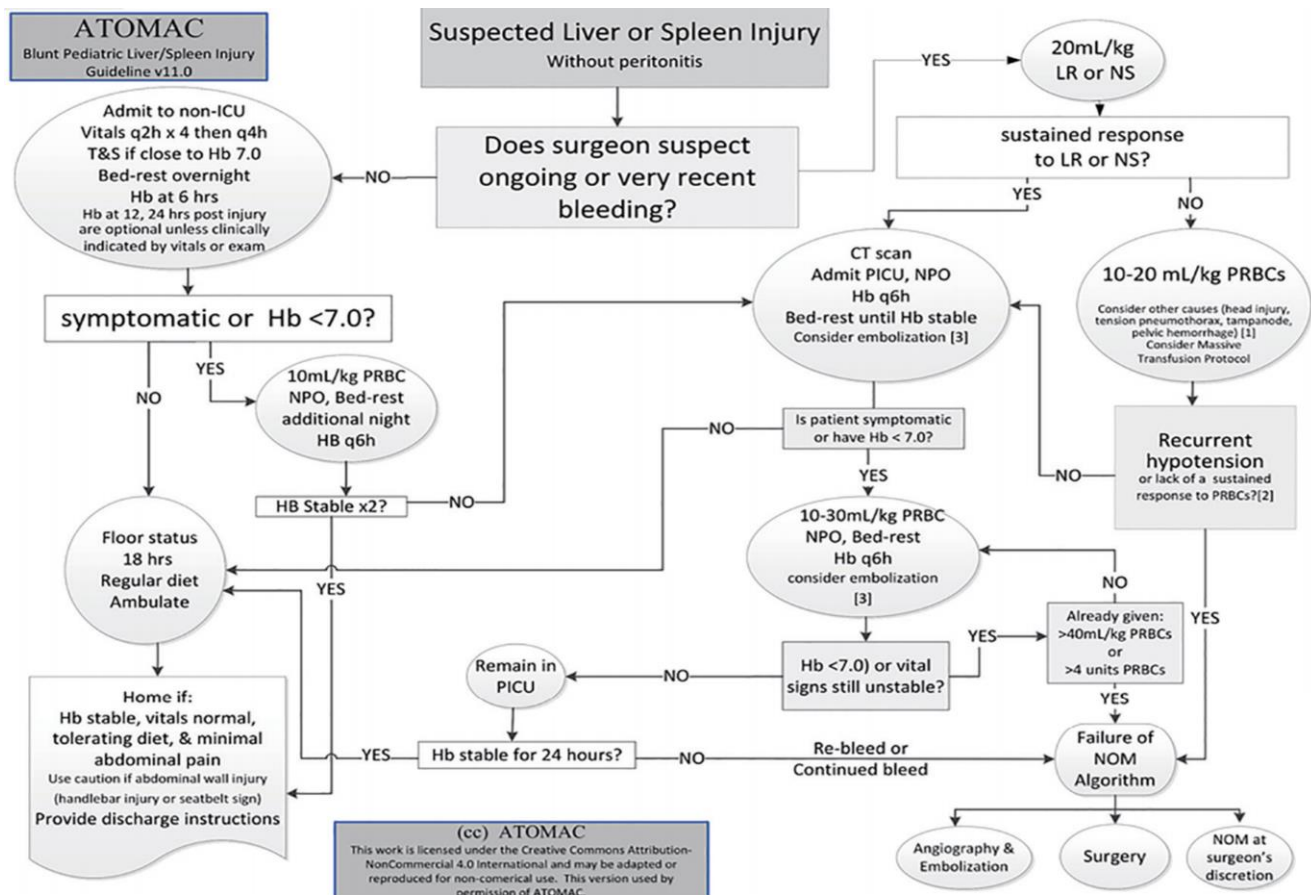
The records of patients who were treated in the Pediatric Surgery Department of Nasser Institute Hospital for research and treatment from Jan 2015 to Jan 2018 for abdominal blunt trauma were retrospectively analyzed. Type of injury, injured organ and mode of treatment were recorded. Along with demographic data of patients, non-operative treatment failure and mortality were also recorded.

In our Department, blunt abdominal trauma patients who were hemodynamically

stable and without any signs of peritonitis underwent conservative non-operative management for their abdominal injuries using hypovolemic resuscitation and serial follow up (abdominal ultrasound, complete blood picture and abdominal CT). These patients were followed up closely with physical examination by the same physician. Informed consent was obtained from all patients. Patients were operated if resistant deterioration of hemodynamic stability developed.

Our management plan depended on the hypovolemic resuscitation technique by giving the patient 90% of its intravenous fluids need. the key point was to keep the patient's blood pressure at the lower edge of its normal range to allow the hemostatic process to function more efficiently. In figure (1), the guidelines used for management are described.

Figure (1): ATOMAC algorithm⁽⁴⁾



In our study, a total of 123 blunt splenic trauma pediatric patients were included. Patients with associated solid organ injuries were excluded from our study. All of these Patients were subjected to initial resuscitation followed by focused assessment with sonography for trauma (FAST) and once the patient was stable, CT abdomen and pelvis

with IV contrast was done to determine the grade of the splenic injury according to the American Association for the Surgery of Trauma Organ Injury Scale (table 1)⁽⁵⁾. The patient was then admitted to the ward or the pediatric ICU and managed according to the guidelines described in figure (1).

Table (1): Spleen OIS ⁽⁵⁾. Advance one grade for multiple injuries up to grade III

Grade	Injury type	Description of injury
I	Hematoma	Subcapsular, <10 % surface area.
	Laceration	Capsular tear, <1 cm parenchymal depth.
II	Hematoma	Subcapsular, 10–50 % surface area. Intraparenchymal, <5 cm in diameter.
	Laceration	Capsular tear, 1–3 cm parenchymal depth that does not involve a trabecular vessel.
III	Hematoma	Subcapsular, >50 % surface area or expanding; ruptured subcapsular or parenchymal.
	Laceration	>3 cm parenchymal depth or involving trabecular vessels.
IV	Laceration	Laceration involving segmental or hilar vessels producing major devascularization.
V	Laceration	Completely shattered spleen.
	Vascular	Hilar vascular injury which devascularizes spleen.

Statistical analysis

Statistical Packages for the Social Sciences (SPSS) version 20.0 for Windows program was used for the analysis of data. Descriptive statistics were presented as mean and standard deviation. Categorical data were analyzed by chi-square test. Significance level was accepted as $p < 0.05$.

Results

A total of 123 blunt splenic trauma patients were included in our study. Their ages ranged from 2 to 12 years old with mean age of 6.43 years old. 67.5% were males and 32.5% were females. The mode of injury was described in table (2).

Table (2): The mode of injury and its rate

The mode of injury	Number of patients	Percentage
Traffic-related accident	73	59.35%
Falling from height	36	29.27%
Animal related injury	4	3.25%
bicycle handlebar injuries	4	3.25%
contact sports	6	4.88%
child abuse	0	0%

Traffic-related accident and falling from height were the main mechanisms of injury with combined total percentage of 88.62 (TRA was 59.34 % and FFH is 29.26%). Other modes of injury included, animal related injury, bicycle handlebar injuries and injuries in contact sports or child abuse with combined percentage of 11.38.

Splenic contusion and hematoma were the most frequent finding on initial computerized tomography (CT) scans, followed by shattered spleen, blush, and devascularization. Grading of the splenic injuries was done using the American Association for the Surgery of Trauma Organ Injury Scale and was described in table 3

Table (3): The grade of injury

The grade of injury	Number of patients	Percentage
I	39	31.71%
II	35	28.46%
III	30	24.39%
IV	15	12.19%
V	4	3.25%

The majority of the patients suffered from an injury grade I-III with percentage of 84.56, while grade IV injury represented only a percentage of 12.19 and grade V injury represented only a percentage of 3.25.

Non-operative management was successful in about 117 patients with percentage of 95.12, while 6 patient showed hemodynamic instability and failure of NOM and underwent splenectomy with percentage of 4.88. Two of these 6 patients required immediate laparotomy and splenectomy, while the other 4 was operated the second day after admission due to hemodynamic instability inspite of resuscitative measures and packed RBCs transfusion. These 4 patients also underwent laparotomy and splenectomy.

Discussion

Non-operative Management is the “gold standard” for pediatric patients with blunt abdominal trauma that are clinically stable. As children have smaller blood vessels and more efficient vasoconstrictive response. Splenic capsule and vessel injury usually stop

bleeding spontaneously regardless of injury type and grade. Consequently, most patients will respond well to non-operative management. Our personal experience support the principle of conservative non-operative management in all haemodynamically stable patients, with overall efficacy rate more than 91%, as was reported in modern literature ^(6,7).

The grade of the splenic injury is an important factor affecting the success of non-operative management. the higher the grade of splenic injury according to the American Association for the Surgery of Trauma Organ Injury Scale (OIS) the higher the risk of failure of NOM ⁽⁵⁾.

The Research Consortium of New England Centers for Trauma (ReCONNECT) examined in New England trauma centers the outcomes of only grade IV and V blunt splenic injuries in 14 trauma centers from 2001 to 2008 ⁽⁶⁾. They studied 388 patients, with approximately about 4 grade IV patients for every one-grade V patient. Of grade IV patients, about 38 % underwent immediate laparotomy and a third of those who managed

using NOM eventually required laparotomy. Of grade V patients, about 60 % underwent immediate operation and another 25 % failed NOM.

Quantity of hemoperitoneum can also be assessed using Focused assessment with sonography for trauma (FAST) and has been reported in several studies to be associated with failure of NOM^(8, 9, 10). Moderate to large volumes of hemoperitoneum have been reported in 59-64 % of patients with splenic injury with failure rates of 10-12 %. However the quantity of hemoperitoneum alone was not associated with a statistically significant increased risk of failure of NOM⁽⁵⁾.

Splenic artery angiography and embolization has been increasingly considered as a supportive measure to NOM. In the higher grades of blunt splenic injury, the advantage of splenic artery embolization seems to be obvious. A retrospective study from 2012 reported on the selective use of angioembolization in hemodynamically stable adult patients selected for NOM⁽¹¹⁾. Of the 539 patients, about 435 underwent observation alone (81%), while 104 (19%) subjected to angioembolization. Failure rates for grades I-III did not differ whether or not angioembolization was used. On the other hand, in grade IV and V injuries, failure of NOM was significantly decreased with the addition of angiography and embolization (23 vs. 3 %, and 63 vs. 9 %, respectively)⁽¹¹⁾.

In 2017 WSES classification for splenic injuries, a new classification and guidelines, was announced. The WSES paper suggested to group splenic injury into 3 groups minor, moderate, and severe. Previously low-grade AAST lesions (grades I to III) are considered as minor or moderate and treated with NOM. However, hemodynamically stable patients with high grade lesions could be also

successfully treated non-operatively, especially with the advancements in bleeding management. On the other hand, minor lesions with hemodynamic instability usually must be treated with laparotomy⁽¹²⁾.

The new WSES classification divides spleen injuries into three classes, depending on both the anatomic AAST-OIS classification and the hemodynamic status. Minor (WSES class I), moderate (WSES classes II and III) and severe (WSES class IV)⁽¹²⁾.

Minor spleen injuries is WSES class I which includes hemodynamically stable AAST-OIS grade I-II blunt and penetrating lesions. Moderate spleen injuries is WSES class II and III. WSES class II, which includes hemodynamically stable AAST-OIS grade III blunt and penetrating lesions and WSES class III which includes hemodynamically stable AAST-OIS grade IV-V blunt and penetrating lesions. Severe spleen injuries is WSES class IV which includes hemodynamically unstable AAST-OIS grade I-V blunt and penetrating lesions⁽¹²⁾. Based on that classification, WSES suggests a new management algorithms as in table (4) and figure (2).

conclusion

The results of this study donates that conservative treatment is the gold standard for all stable patients with blunt splenic trauma regardless of the grade of the organ injury. The choice of non-operative treatment should be based mainly on physiological response of the child, rather than the injury grade on CT scan. Assessment of haemodynamic stability is the most important initial concern in the evaluation of a patient with blunt abdominal trauma. WSES Spleen Trauma Classification depending on both the anatomic AAST-OIS classification and the hemodynamic status and can be used to improve the outcome of NOM.

Non operative conservative management of blunt trauma to the spleen in Children...

	WSES class	Mechanism of injury	AAST	Hemodynamic Status	CT scan	First-line treatment in pediatric
Minor	WSES I	Blunt/penetrating	I-II	Stable	Yes + local exploration in case of stab wound	NOM + serial clinical/laboratory/radiological evaluation. Consider angiography/Angioembolization
Moderate	WSES II	Blunt/penetrating	III	Stable		
	WSES III	Blunt/penetrating	IV-V	Stable		
Severe	WSES IV	Blunt/penetrating	I-V	Unstable	No	OM

Table (4): WSES Spleen Trauma Classification for pediatric patient ⁽¹²⁾.

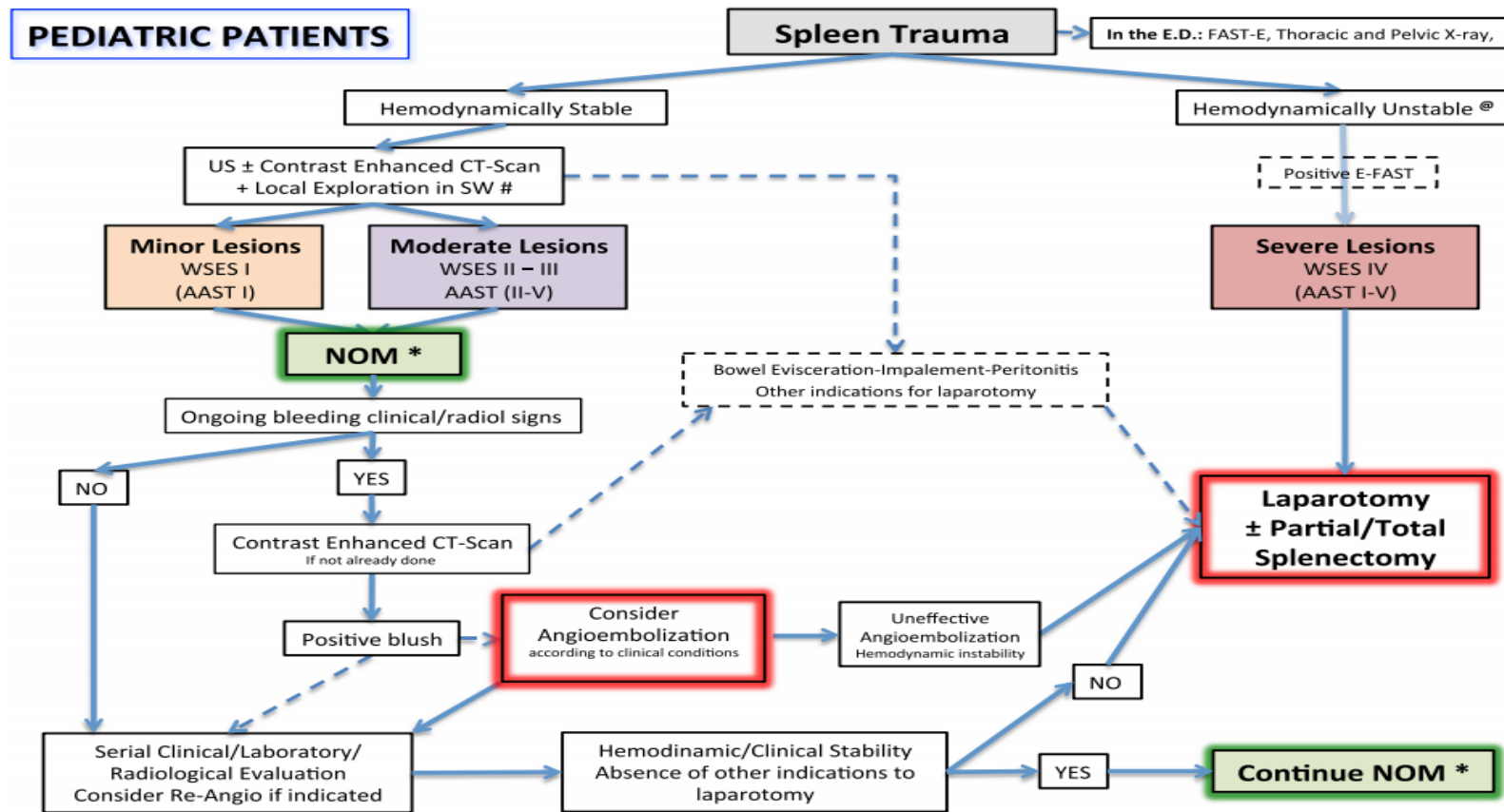


figure (2): WSES Spleen Trauma Management Algorithm for Pediatrics Patients ⁽¹²⁾.

References

1. **Djordjevic I, Slavkovic A, Marjanovic Z, Zivanovic D (2015):** Blunt trauma in paediatric patients - experience from a small centre. *West Indian Med J.* ,64 (2): 126-130.
2. **Skattum J, Naess P A, Gaarder C (2012):** Non-operative management and immune function after splenic injury. *British journal of surgery*, 99 (1): 59-65.
3. **Singer G, Rieder S, Eberl R, Wegmann H , Hoellwarth M E (2013):** Comparison of two treatment eras and sonographic long-term outcome of blunt splenic injuries in children. *Eur J Pediat.r*, 172: 1187-1190.
4. **Minaya-Bravo A M, Aguado-Lopez H (2017):** The Challenge of Blunt Abdominal Trauma in Children: Report of a Case and Review of Management. *J Med Cases*, 8 (11): 340-346.
5. **Watson G A, Hoffman M K, Peitzman A B (2015):** Nonoperative management of blunt splenic injury: what is new? *Eur J Trauma Emerg Surg.*, 41: 219-228.
6. **Velmahos G C, Zacharias N, Emhoff T A et al. (2010):** Management of the Most Severely Injured Spleen: A Multicenter Study of the Research Consortium of New England Centers for Trauma (ReCONNECT). *Arch Surg.*, 145 (5): 456-460.
7. **Harbrecht B G, Ko S H, Watson G A, Forsythe R M, Rosengart M R, Peitzman A B (2007):** Angiography for blunt splenic trauma does not improve success rate of non-operative management. *J Trauma*, 63: 44-49.
8. **Peitzman A B, Heil B, Rivera L, Federle M B et al.(2000):** Blunt splenic injury in adults: multi-institutional study of the Eastern Association for the Surgery of Trauma. *J Trauma-Inj Infect Crit Care*, 49: 177-189.
9. **Bee T K, Croce M A, Miller P R, Pritchard F E, Fabian T (2001):** Failures of splenic nonoperative management: is the glass half empty or half full? *J Trauma Acute Care Surg.*, 50: 230–236.
10. **Haan J M, Bochicchio G V, Kramer N, Scalea T M (2005):** Nonoperative management of blunt splenic injury: a 5-year experience. *J Trauma-Inj Infect Crit Care*, 58: 492-498.
11. **Bhullar I S, Frykberg E R, Siragusa D et al. (2012):** Selective angiographic embolization of blunt splenic traumatic injuries in adults decreases failure rate of nonoperative management. *J Trauma Acute Care Surg.*, 72: 1127-1134.
12. **Coccolini F, Montori G, Catena F et al. (2017):** Splenic trauma: WSES classification and guidelines for adult and pediatric patients. *World J Emerg Surg.*, 18: 12-40