

## Difficult To Treat Recurrent Esophageal Dysphagia Due To Secondary Esophageal Motility Disorders: A 24 Weeks Follow Up Case Report

**Ayman M.E.M. Sadek**

*Internal Medicine Department, Hepatogastroenterology Unit – Zagazig University, Egypt.*

DOI: <https://dx.doi.org/10.52378/esme881988>

### Corresponding Author

**Dr. Ayman M.E.M. Sadek**

Internal Medicine Department, Hepatogastroenterology Unit – Zagazig University

Email address: [amedms@gmail.com](mailto:amedms@gmail.com)

Sharkia, Zagazig, 44519.

Cell phone: +201114480339.

**Received:** November 24, 2018

**Peer-review started:** November 26, 2018

**First decision:** November 29, 2018

**Revised:** December 27, 2018

**The second round of peer review (by journal editors):** January 15, 2019

**Accepted:** February 7, 2019

**Article in press:** February 15, 2019

**First online:** February 16, 2019.

**Informed consent statement:** Informed consent was obtained from the patient.

**Conflict-of-interest statement:** The author declares no conflict-of-interest related to this article.

### Abstract

Limited data are available on the prevalence of esophageal motility disorders (OMD), with a suggested range of 4-12% in cases with dysphagia. The proposed pathophysiology is either impairment of inhibitory innervation or overactivity of excitatory innervation. The optimal treatment is not defined until

now. This case represented one of the secondary OMD in a 70 years year diabetic patient with ischemic cardiomyopathy, who was complaining of recurrent daily intermittent dysphagia to solids and fluids, with a previous vague history of esophageal dilatation without available documentation. After endoscopy with multiple biopsies and barium imaging, the picture of the corkscrew esophagus was revealed. The patient, who was already on nitrates, failed to respond to twice-daily proton pump inhibitor for two months with a prokinetic drug, calcium channel blocker, and the first session of endoscopic esophageal dilatation. After the second dilatation session, we added sodium alginate to substitute nitrates with sildenafil. The patient reported a gradual improvement in dysphagia, especially fluids, decreasing daily attacks. We learn from this case that a different patient-to-patient response necessitates other treatment modalities, even switching between each patient's nitric oxide scavengers.

**Keywords:** Case Report; Dysphagia; esophageal Motility Disorders.

## **Introduction**

Dysphagia is an alarming symptom that warrants prompt evaluation to define the exact cause and initiate appropriate therapy. It may be due to a structural or motility abnormality in the passage of solids or liquids. Dysphagia in older adults should not be attributed to aging. Aging alone causes mild esophageal motility abnormalities, rarely symptomatic (1).

Dysphagia to solids and liquids may be related to either an esophageal motility disorder (OMD) or a functional disorder that can be differentiated by investigations like upper endoscopy, barium image, and manometry studies. Symptoms of dysphagia may be intermittent or present after each meal (2).

Nonspecific esophageal dysmotility (including diffuse esophageal spasm, hypertensive peristalsis "nutcracker or corkscrew esophagus," hyper or hypotensive lower esophageal sphincter, and ineffective esophageal motility) is a type of OMD, which is considered if motility findings exceed two standard deviations from those found in a large group of healthy subjects (3).

OMD may occur as a primary or secondary to other diseases (like systemic sclerosis, Chagas' disease, diabetes mellitus, and chronic gastroesophageal reflux disease), with limited data on the prevalence that is ranging, in some studies, from 4% up to 12% in other reviews, which were carried on individuals referred for esophageal manometry for evaluation of dysphagia or unexplained chest pain (4-6).

Although the underlying pathology is unknown, the supposed pathophysiology of OMD range from impairment of inhibitory innervation, leading to premature and rapidly propagated or simultaneous contractions and overactivity of

excitatory innervation or smooth muscle response to excitatory nerves. Patients may malfunction in endogenous nitric oxide synthesis and degradation (5, 7-10).

There is considerable controversy concerning the clinical implications of these abnormalities and whether they cause or explain the patient's symptoms, contrary to other clear ones like achalasia.

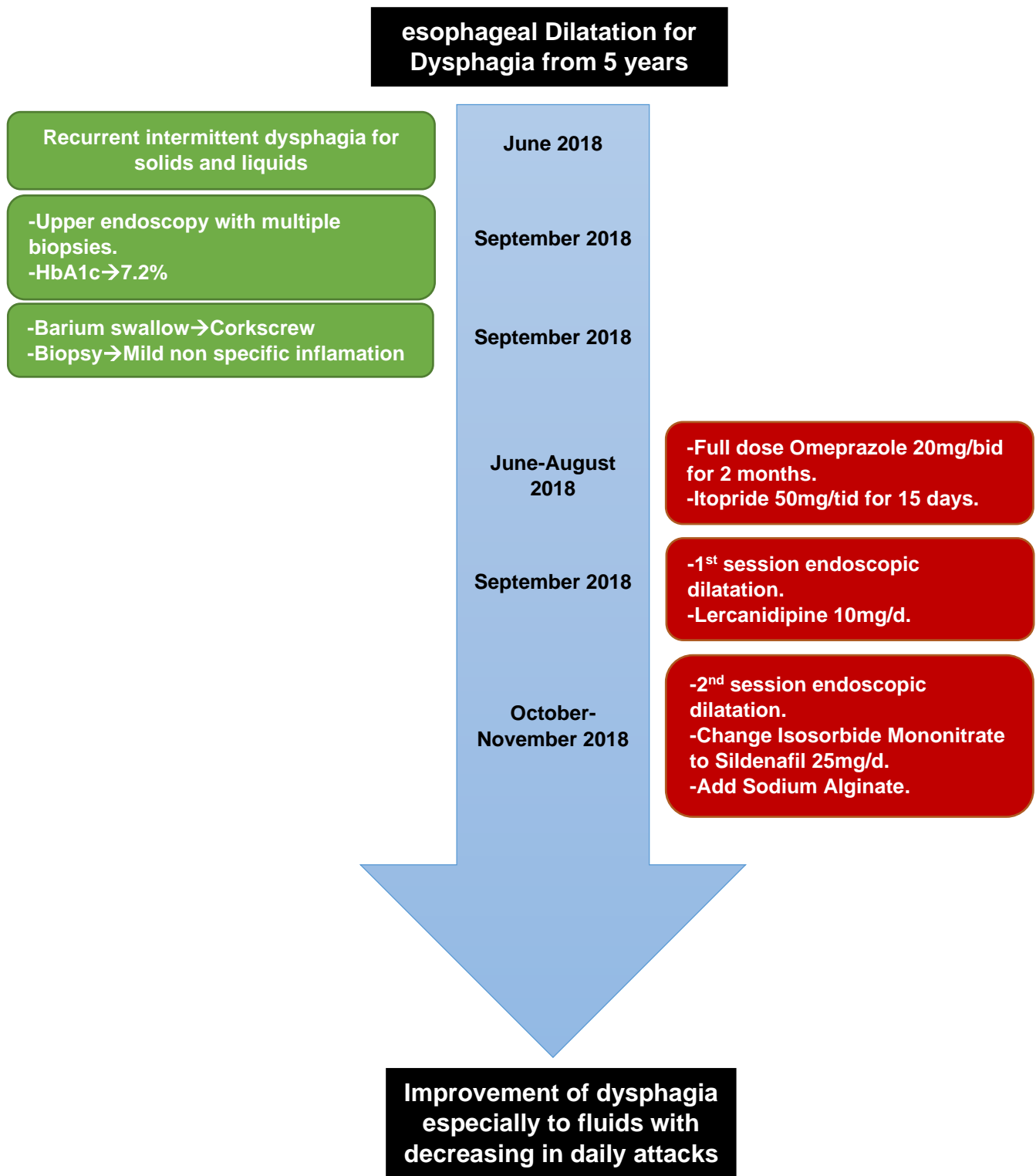
### **Presenting Concerns**

Seventy-year-old male, a previous farmer, married and has four offspring with a medical history of diabetes mellitus for 20 years on insulin therapy, ischemic cardiomyopathy with moderate diastolic dysfunction, and preserved systolic function. For five years, the patient gave a vague history of endoscopic esophageal dilatation (without available documentation) for the same condition, recurrent intermittent dysphagia for solids and liquids with a gradual increase in daily attacks over the last three months from the presentation. There was no history of psychiatric illness. The patient was on the following treatment, Insulin Mixtard 30/70, Furosemide 250mg daily, Isosorbide Mononitrate 50mg daily, Losartan 50mg/Hydrochlorothiazide 12.5mg daily, Ivabradine 5mg daily, Rosuvastatin 10mg daily, Clopidogrel 75mg daily, and Omeprazole 40mg daily.

### **Clinical Findings**

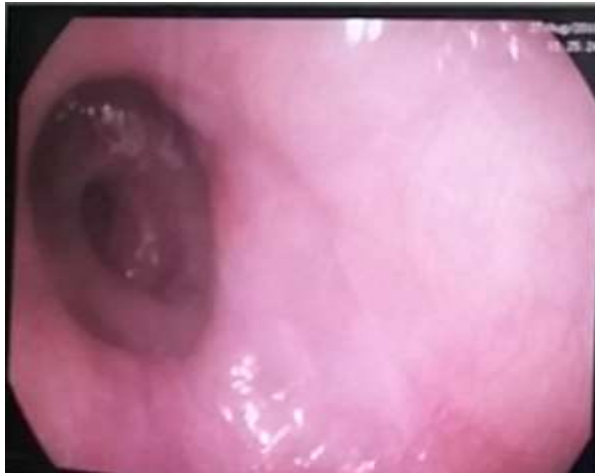There is unremarkable general and local examination except for mild oral thrush, bilateral lower limb edema up to mid-leg, and body mass index of 36.7.

## Timeline



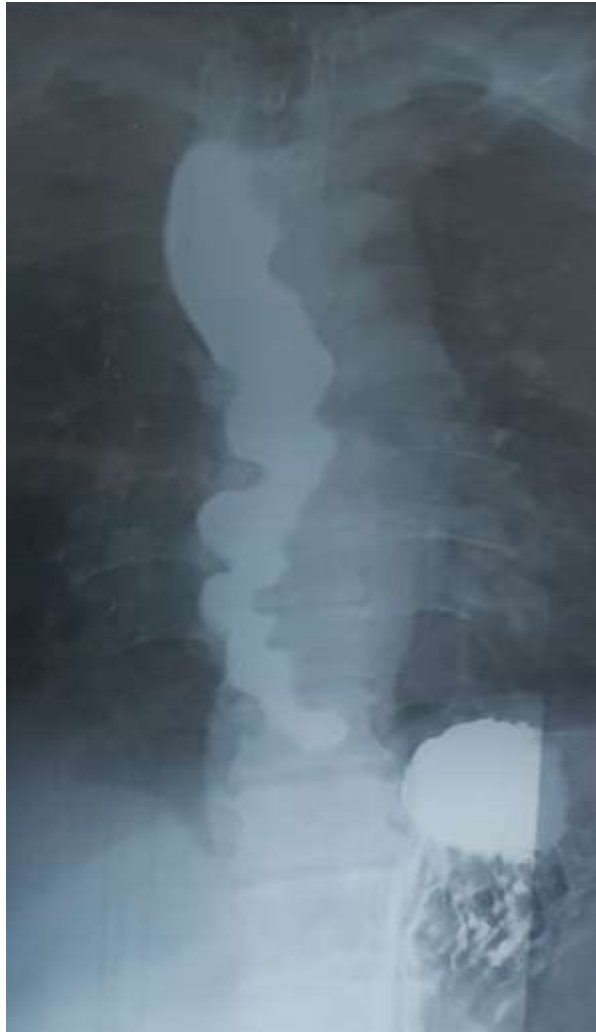## Diagnostic Focus and Assessment

Diabetes was controlled in the past three months as glycated hemoglobin (HbA1c) was 7.2%. Complete blood count, liver chemistry tests, and kidney functions were within the normal range. There are normal chest X-ray findings and abdominal ultrasonography except for fatty liver. Echocardiography revealed moderate diastolic dysfunction with preserved systolic function. Diagnostic upper endoscopy showed multiple circular narrowing in the mid and lower esophagus with the complex proceeding of the endoscope (fig 1).



*Fig 1: Endoscopic view of the multiple circular narrowing in the mid and lower esophagus.*

Multiple biopsies were taken, and the histopathological report revealed esophagitis, mild keratosis, and parakeratosis. Barium swallow imaging of the esophagus revealed the corkscrew appearance (Fig 2).



*Fig 2: Barium swallow showing the corkscrew appearance*

### **Therapeutic Focus and Assessment**

We started with a twice-daily proton pump inhibitor Omeprazole 20mg before the meal for one hour for two months without changing the patient complaint. Then we tried a prokinetic agent, Itopride 50mg tid before the dinner by one hour for 15 days but no response. Then we proceed to the first session of dilatation with Savary-Gilliard® Dilator size 9-10mm (27-30Fr), and we add a calcium channel blocker Lercanidipine 10mg daily after the cardiologist consultation. The patient still had no response, so we performed the second dilatation session with a size 11-12mm (33-36Fr) plus changing the Isosorbide

Mononitrate to Sildenafil 25mg daily and adding Sodium Alginate 10ml tid before meals.

### **Follow-up and Outcomes**

The patient, after one month, gave us positive feedback of a gradual improvement of dysphagia, especially to fluids with decreasing in daily attacks.

### **Discussion**

One of the strengths of this report was the ability to manage this complex case associated with significant cardiac comorbidity that limits our choices in drugs and doses. Although, a considerable limitation was the absence of esophageal manometry study due to patient refusal and the unique treatment modality that needs validation on a large scale of similar conditions. Our approach is consistent with the American Gastroenterological Association, the American Society for Gastrointestinal Endoscopy, and the World Gastroenterology guidelines (11-14). The principal concern, in this case, was esophageal cancer due to the age of the patient. However, the intermittent nature of dysphagia and the absence of alarming signs like significant weight loss and anemia make it unlikely (15). Also, complications of gastroesophageal reflux disease, such as erosive esophagitis, peptic stricture, or adenocarcinoma of the esophagus, were precluded by the absence of chronic heartburn (16, 17). The presence of recurrent, intermittent dysphagia to solids and liquids with long-term diabetes mellitus makes it more reasonable for secondary motility disorders; however, functional conditions may cause. Still, it was excluded due to lacking Rome IV criteria. Also,



eosinophilic esophagitis or lymphocytic one should be excluded; we take multiple biopsies from the esophagus (15, 16). Lastly, we must not ignore the cardiovascular abnormalities in this age, like severe atherosclerosis or a giant aneurysm of the thoracic aorta can result in impingement on the esophagus (17). However, the endoscopic picture, chest X-ray, and echocardiography did not raise suspicion of this possibility.

### **Conclusion**

We learn from this case that a different patient-to-patient response necessitates other treatment modalities, even switching between each patient's nitric oxide scavengers.

### **Informed Consent**

The patient provided his informed consent for the publication of this case report.

### **Conflicts of interest**

The author declares no conflicts of interest.

### **Funding support**

Zagazig University, Faculty of Human Medicine.

### **Acknowledgments**

We appreciated the great help of Prof. Hany M. Elsadek in endoscopic dilatation sessions and the support of Dr. Islam Shehata in cardiological consultations.

## Footnotes

**CARE Checklist (2013) statement:** The author has read the CARE Checklist (2013), and the manuscript was prepared and revised according to the CARE Checklist (2013).

**Citation of this article: Sadek AM.** Sadek AME. Difficult To Treat Recurrent Esophageal Dysphagia Due To Secondary Esophageal Motility Disorders: A 24 Weeks Follow Up Case Report. African journal of gastroenterology and hepatology [Internet]. The Scientific Society of Kafr el-sheik Doctors; 2019 Feb 17;2(1):19-29. Available from: <http://dx.doi.org/10.52378/esme881988>

**Peer- Reviewers:** Usama Khalil, Ayman al Sebaey, Mariam Zaghloul, Mohamed Maaly.

E- Editor: Salem Y Mohamed.

Copyright ©. This open-access article is distributed under the Creative Commons Attribution License (CC BY). The use, distribution, or reproduction in other forums is permitted, provided the original author(s) and the copyright owner(s) are credited. The original publication in this journal is cited by accepted academic practice. No use, distribution, or reproduction is permitted, which does not comply with these terms. Disclaimer: All claims expressed in this article are solely those of the authors and do not necessarily represent their affiliated organizations or those of the publisher, the editors, and the reviewers. Any product that may be evaluated in this article or claim that its manufacturer may make is not guaranteed or endorsed by the publisher

## References

1. Shamburek RD, Farrar JT. Disorders of the digestive system in the elderly. *New England Journal of Medicine*. 1990;322(7):438-43.
2. Aziz Q, Fass R, Gyawali CP, Miwa H, Pandolfino JE, Zerbib F. Esophageal disorders. *Gastroenterology*. 2016;150(6):1368-79.
3. Richter JE, Wu WC, Johns DN, Blackwell JN, Nelson JL, Castell JA, et al. Esophageal manometry in 95 healthy adult volunteers. *Digestive diseases and sciences*. 1987;32(6):583-92.
4. Dalton CB, Castell DO, Hewson EG, Wu WC, Richter JE. Diffuse esophageal spasm. *Digestive diseases and sciences*. 1991;36(8):1025-8.
5. Murray JA, Ledlow A, Launspach J, Evans D, Loveday M, Conklin JL. The effects of recombinant human hemoglobin on esophageal motor function in humans. *Gastroenterology*. 1995;109(4):1241-8.
6. KATZ PO, DALTON CB, RICHTER JE, WU WC, CASTELL DO. Esophageal testing of patients with noncardiac chest pain or dysphagia: results of three years' experience with 1161 patients. *Annals of internal medicine*. 1987;106(4):593-7.
7. . !!! INVALID CITATION !!!
8. Jung H-Y, Puckett JL, Bhalla V, Rojas-Feria M, Bhargava V, Liu J, et al. Asynchrony between the circular and the longitudinal muscle contraction in patients with nutcracker esophagus. *Gastroenterology*. 2005;128(5):1179-86.
9. Spechler SJ. AGA technical review on treatment of patients with dysphagia caused by benign disorders of the distal esophagus. *Gastroenterology*. 1999;117(1):233-54.
10. Agrawal A, Tutuian R, Hila A, Castell DO. Successful use of phosphodiesterase type 5 inhibitors to control symptomatic esophageal hypercontractility: a case report. *Digestive diseases and sciences*. 2005;50(11):2059-62.
11. Muthusamy VR, Lightdale JR, Acosta RD, Chandrasekhara V, Chathadi KV, Eloubeidi MA, et al. The role of endoscopy in the management of GERD. *Gastrointestinal endoscopy*. 2015;81(6):1305-10.
12. Dibaie JK, Quigley EM. Tumor-related dysmotility gastrointestinal dysmotility syndromes associated with tumors. *Digestive diseases and sciences*. 1998;43(7):1369-401.
13. McCullough GH, Martino R. Clinical evaluation of patients with dysphagia: Importance of history taking and physical exam. *Manual of diagnostic and therapeutic techniques for disorders of deglutition*: Springer; 2013. p. 11-30.
14. Marks RD, Richter JE. Peptic strictures of the esophagus. *American Journal of Gastroenterology*. 1993;88(8).
15. Kim HP, Vance RB, Shaheen NJ, Dellon ES. The prevalence and diagnostic utility of endoscopic features of eosinophilic esophagitis: a meta-analysis. *Clinical Gastroenterology and Hepatology*. 2012;10(9):988-96. e5.
16. Cohen S, Saxena A, Waljee A, Piraka C, Purdy J, Appelman H, et al. Lymphocytic esophagitis: a diagnosis of increasing frequency. *Journal of clinical gastroenterology*. 2012;46(10):828.
17. Pitchai S, Goura P, Savlania A, Sukesan S, Kapilamoorthy T, Unnikrishnan M. Dysphagia aortica: Diagnostic dilemma and therapeutic paradigm. *Indian Journal of Vascular and Endovascular Surgery*. 2016;3(2):45-.