**Original Paper****Hepatoprotective effect of *Origanum majorana* against albendazole-induced hepatotoxicity in rats**Mosaad, G. El-sayed¹, Ashraf, A. Elkomy¹, Enas, A. Farag² and Aya, A. Gad¹¹Department of Pharmacology, Faculty of Veterinary Medicine, Benha university, Egypt²Department of pharmacology, Animal Health Research Institute, Benha, Egypt.**ARTICLE INFO****ABSTRACT****Keywords**

Albendazole
Hepatic damage
Origanum majorana extract
Hepatoprotection
rats

Received 09/05/2021

Accepted 12/06/2021

Available On-Line

01/10/2021

Albendazole is an broad spectrum anthelmintic used for treatment of different parasites. Liver toxicity and elevation of liver marker enzymes occur secondary to usage of albendazole (Alb). *Origanum Majorana* extract (OME) has a hepatoprotective effect against Alb-enhanced hepatic toxicity in rats as assayed in the present study. Twenty male rats were divided into four equal groups, five rats for each group. Group1: (Normal control), received no drugs, Group 2: (OM-treated), rats received an oral dose of OME (200 mg/kg b.wt/day) for 30 successive days. Group 3: (Alb-treated) received an oral dose of Alb (7.5 mg/kg b.wt./day) for 15 successive days. Group 4: (OME-protected + Alb), rats pretreated with OME (200 mg/kg b.wt/day) orally for 30 days before Alb treatment for 15 days. Results showed significant ($P<0.05$) raise in the levels of aspartate aminotransferase (AST), alanine aminotransferase (ALT), alkaline phosphatase (ALP), total protein, direct bilirubin and decrease of albumin level in the Alb-treated group compared to control and OME-treated groups. Albendazole also induced histopathological alteration in liver tissue. The OME showed significant protection against Alb-induced hepatotoxicity that was confirmed through serum biochemical analysis and the histopathological examination of liver tissues and therefore, it might be beneficial for the hepatotoxicity.

1. INTRODUCTION

Albendazole acts on a wide range of parasites. It is an anthelmintic benzimidazole carbamate drug that acts by inhibiting tubulin polymerization leading to loss of microtubules of cytoplasm and clinically significant hepatitis is reported with Alb administration (Shah et al., 2013). Acute hepatitis was confirmed by the presence of non-specific symptoms of acute illness accompanied by elevation of AST and/or ALT activities (Narciso-Schiavon et al., 2018). Acute liver injury enhanced by Alb was reported in some patients nearly 16% of people using that drug, patients had clear raise on hepatic enzyme levels that may be 40 times more than normal levels, in addition to changes in electrolyte levels, coagulation factor and changes in blood parameters (Fabio et al., 2015). The oxidative stress and DNA damage caused Alb induced-hepatitis through induction of apoptotic-like events (Espinosa et al., 2015). Oregano was the common name for *Origanum majorana* had two forms used for two commercial purposes: a fresh and dried form which added to food or used in herbal

medicine, it has a hepatoprotective effect due to presence of thymol and carvacrol content in its leaves (Farias et al., 2010). Oregano contains many other useful components as ursolic acids, oleanolic acids, hydroquinone, flavonoids caffeic acids, tannins, and phenolic glycosides which are widely used as cytotoxic, anti-inflammatory, anticarcinogenic and antioxidant effects (Chishti et al., 2013). The purpose of the present study is to evaluate the possible protective effect OME against the hepatotoxic effect of Alb after long term administration in adult male rats through investigation of serum biochemical analysis of liver in addition to histopathological examination of the liver.

2. MATERIAL AND METHODS**2.1. Experimental animals**

Twenty male rats, 4-5 weeks old with an average body weight of 150-200 g were used. Rats were fed on constant ration and a free source of fresh, clean drinking water was supplied. All rats were left in the place for two weeks before the beginning of the study for

* Corresponding author: ayagad82@yahoo.com

adaptation to the environment. The experimental protocols were approved by the Animal Care and Use committee at Benha University and are in accordance with the National Institute of Health Guide for the Care and Use of Laboratory Animals under NO. BUFVTM 01-06-21.

2.2. Chemicals

2.2.1 Albendazole (Alb)

Presents in the form of liquid suspension with a concentration of 2.5% (each 1ml suspension contains 2.5 mg Alb). Its traditional name is Alb 2.5%® and obtained from Pharma Swede company, Egypt. It is obtained and used as suspension. Hepatotoxicity of Alb was induced through oral administration of Alb at dose rate of 7.5 mg/kg b.wt/day for 15 days according to the Committee for Veterinary Medicinal Products (CVMP).

2.2.2. Ethanolic extract of *organium majorana* (OME)

Origanum marjorana (OME) was obtained as a green plant from the market and dried at normal ambient temperature then ground to slight large particles then prepared according to the method of Benhalilou et al., (2019). Dried powder (5.0 g) was added to 100 mL of ethanol 70%, then the mixture was stored for 72 h in a refrigerator. Thereafter the mixture was shaken using a rotary evaporator at room temperature to evaporate the filtrate to dryness. The green residue was kept under vacuum for 2–3 h and its amount was measured. A stock solution was made, and each rat received the calculated dose in 1 mL solvent. OME was used at dose rate of 200 mg/kg.b.wt. according to Pasavei et al., (2020).

2.2.3. Experimental design

2.3.1. Animal grouping

Rats were assigned into four groups (5 rats each) and placed in separated cages and classified according to Omotoso et al., (2013) as the following:

2.3.1. Group 1: (control group): Rats have received ordinary diet with no drug treatment during the experimental period.

2.3.2. Group 2: (OME group): Rats have received OME (200 mg/kg b.wt/day) orally for 30 successive days.

2.3.3. Group 3: (Alb group): Rats have received Alb orally at a dose of (7.5 mg/kg b.wt/day) for 15 days.

2.3.4. Group 4: (OME-Alb group) OME was administered before Alb administration for 30 days then Alb was administered for 15 days.

2.4. Sampling

2.4.1. Blood samples

Blood samples were taken from the medial eye canthus. Blood was left to clot then centrifuged for 15 minutes at 3,000 rpm. Sera were separated in dry sterile tubes by automatic pipette, then stored at -20 °C in a deep freezer until the determination of liver enzymes (ALT, AST, and AP), Albumin, Direct bilirubin and total protein.

2.4.2. Tissue samples and histopathological examination

After collection of the blood samples rats were sacrificed and the abdomen was opened, then livers were collected. Small liver tissue specimens were placed in 10% formalin saline for 7 days, after completion of fixation, the samples were dehydrated in a series of alcohols, cleared in toluene which after that embedded in a purified paraffin with plastic polymers (Paraplast, Sherweed Medical Co, USA). Blocks were cut at 5-7 m. Sections were dewaxed, rehydrated in a series of alcohols, stained with H&E. Sections were mounted and examined using a light microscope. Representative slides were photographed under an Olympus Vanox photomicroscope (Olympus, USA).

2.5. Biochemical analysis

Aspartate aminotransferase (AST), alanine aminotransferase (ALT), alkaline phosphatase (ALP), total protein, direct bilirubin and albumin levels were determined in serum spectrophotometrically by specific kits (Centronic Company®, Germany). Determination of AST, ALT was performed following Reitman and Frankel, (1957), Determination of ALP was performed following Tietz, N.W. et al., (1983) and Determination of total protein and direct bilirubin according to Choosongsanget al ., (2011) and albumin level was measured according to Dou-mas et al.,(1997).

2.6. Statistical analysis

Statistical analysis was carried out with the Statistical Package for Social Science (SPSS 16 Inc. Released, 2009) to examine if variables differed between different groups, one-way ANOVA was used for comparison among means and subsequent Duncan's multiple range test, Probability values of less than 0.05 were considered significant.

3. RESULTS

3.1 Biochemical findings

Albendazole administration induced a significant increase ($P < 0.05$) in the levels of serum AST, ALT and ALP, direct bilirubin and

total protein compared to the control group and OME-treated group (Table 1). Pretreatment of rats with OME 200 mg/kg b.wt for 30 days with Alb protected the liver against the toxic effect of Alb and levels of the previous enzymes returned to a nearly values as control

group, while The concentrations of albumin were significantly reduced ($P < 0.05$) in the Alb group compared to control and OME-treated groups, Co-administration OME with Alb significantly improved albumin levels a nearly normal levels as the control group (Table 1).

Table 1. Effects of pretreatment with OME on serum ALT, AST, ALP, direct bilirubin, total protein, and albumin levels of Alb intoxicated rats.

Groups	ALT(U/L)	AST(U/L)	ALP(U/L)	Direct bilirubin (g/dl)	Total proteins (g/dl)	Albumin (g/dl)
Control group (G1)	39.9 ± 0.8 ^{3b}	62.3 ± 1.44 ^c	127.1 ± 1.09 ^c	0.35 ± 0.017 ^c	4.01 ± 0.104 ^b	5.75 ± 0.22 ^b
OME group (G2)	38.6 ± 1.78 ^c	64.4 ± 0.88 ^b	126.6 ± 0.98 ^c	0.37 ± 0.02 ^c	4.11 ± 0.02 ^b	5.80 ± 0.13 ^b
Alb group (G 3)	88.2 ± 5.44 ^a	75.9 ± 1.07 ^a	159.6 ± 3.86 ^a	0.74 ± 0.02 ^a	6.23 ± 0.13 ^a	3.50 ± 0.17 ^a
OME+Alb (G 4)	40.3 ± 1.07 ^b	63.7 ± 1.51 ^b	129.3 ± 2.9 ^b	0.40 ± 0.017 ^b	4.27 ± 0.23 ^b	5.25 ± 0.17 ^b

Values are presented as means ± SE. Means within a column with different letter superscripts are significantly different.

3.2. Histopathological examination

Microscopical examination of different sections of the liver of normal untreated rats (Group1) showed normal histological structure and normal histological components of the central vein and hepatocytes (Fig.1 A). Liver of OME administrated rat showing normal histological structure of central veins (CV), portal areas (arrow) and hepatic parenchymal cells (HCs) (Fig.1 B). However, the liver of Alb treated group (Group 3) showed widening of the liver sinusoids with inflammatory cellular infiltration of the hepatic parenchyma (Fig.1 C). Congestion of the central veins with the appearance of large eosinophilic areas of coagulative necrosis (N) containing nuclear remnants and vacuolar degeneration (dashed arrow) of necrosis in other areas (Fig .1 D). Portal area in the liver of Alb- intoxicated rat showed congestion of portal vessel (CO) with mononuclear inflammatory cells infiltration (arrow) and mild edema (Ed) (Fig.1 E). Contrarily, the liver of rats received Alb+OME (Group 4) showed a good restoration of the hepatocytes with mild degenerative and necrotic (arrow) changes (Fig.1 F), granular degeneration (arrow) and scattered necrosis (dashed arrow) in the hepatocytes with mild activation of Kupffer cells (short arrow, Fig.1 G).

4. DISCUSSION

Liver diseases are important and common diseases spreading worldwide. Many causes lead to impairment of liver function as Alb leading to increase in the serum levels of the transaminases particularly in creatures which were on their typical eating routine, while antacid phosphatase was either diminished or expanded dependent on dietary factors. They inferred that oral organization of Alb before

dinner or with a greasy eating regimen could restrict extreme rise of liver compounds (Omotoso et al., 2013).

Our findings showed that treatment with alb orally at dose rate of 7.5 mg/kg b.wt caused elevation of liver enzymes (AST, ALT, ALP), direct bilirubin ,total protein and reduction of albumin levels which was confirmed by biochemical tests. While pretreatment with OME at dose of 200 mg/kg b.wt for 30 days caused improvement of levels of AST, ALT, ALP, direct bilirubin ,total protein and albumin toward normal levels due to OME hepatoprotective effect.

Diagnosis of drug-induced hepatic toxicity due to Alb administration depends on information about consumption of a specific drug, clinical record, clinical tests, and laboratory tests which improved after stopping treatment with Alb and after excluding other possible causes (Rios and Restrepo 2013). Injury of hepatocytes caused by different types of drugs and toxicants like chemotherapeutic agents and anthelmintics as benzimidazoles showed alteration of hepatic function with elevation of liver enzymes (El-shafeey and Taha 2013).

Acute liver injury enhanced by Alb was reported in about 16% of people using this medication in which patients had a significant increase in hepatic enzyme levels that may be 40 times more than normal levels, in addition to changes in electrolyte levels, coagulation factors and blood parameters, but the way the decline of the hepatic enzyme values, especially when decline rates are more than 60% of their normal values in 24 h, showing liver failure and treatment of acute hepatic failure depends on specific mechanisms of support like hospitalization with receiving high care and drugs treating complications, like hemorrhage and infections (Fabio et al., 2015)

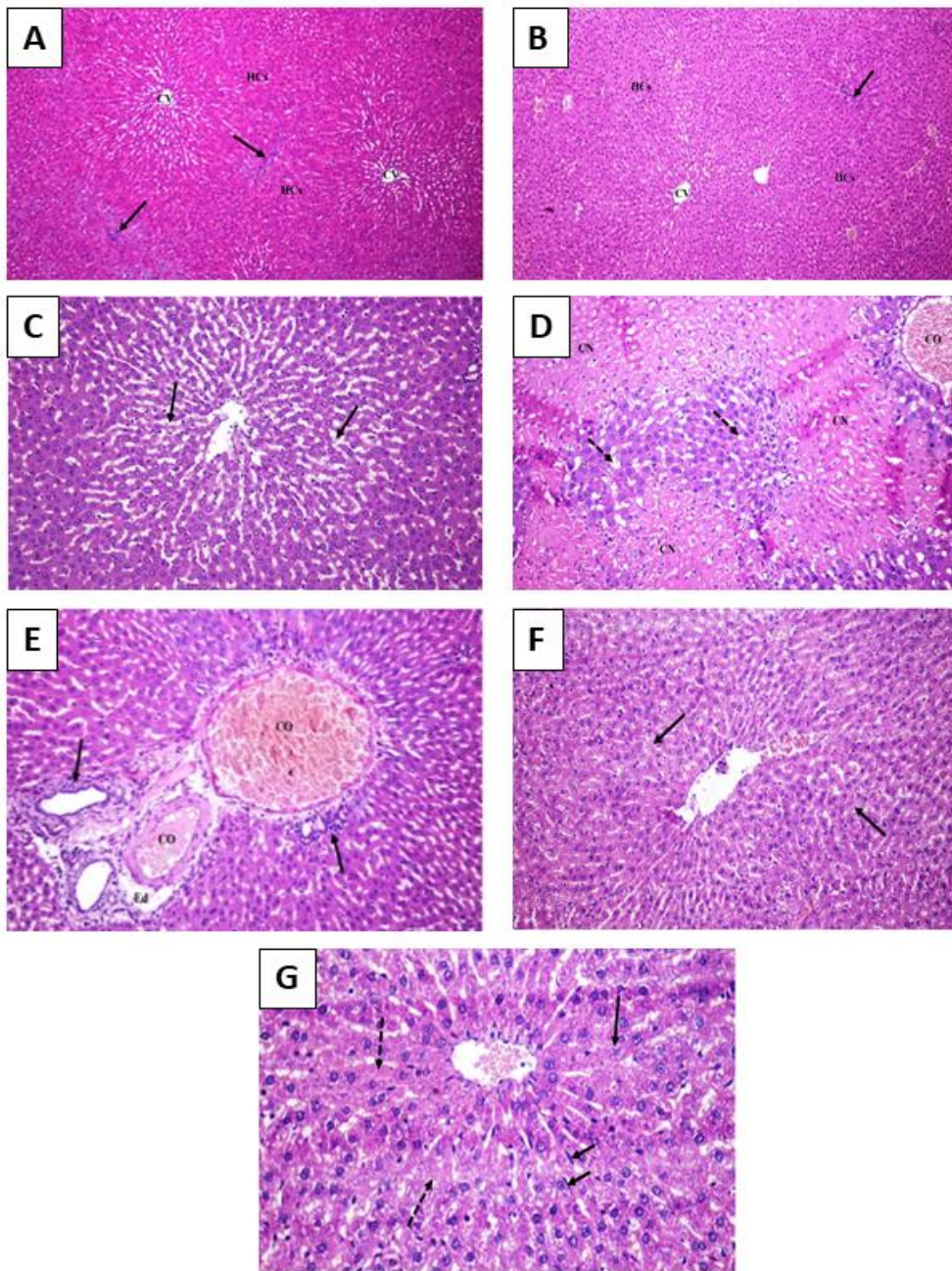


Fig1. Protective effects of *Origanum majorana* against Alb-induced histopathological hepatic alteration in rats. (A) Liver of the control group showing a normal histological structure of central veins (CV) with no alterations, portal areas (arrow), and hepatic cells (HCs). (X100). (B) Liver of OME administrated rat showing histological composition of central veins (CV) with normal histological structure, portal areas (arrow) and hepatic parenchymal cells (HCs). (X100). (C) Liver of Alb intoxicated rat showing dilatation of the hepatic sinusoids (arrow) with inflammatory cellular infiltration. (X200). (D) Liver of Alb administrated rat showing congestion of central vein (CO), large eosinophilic areas of coagulative necrosis (CN) containing nuclear remnants and vacuolar degeneration (dashed arrow) of hepatocytes in other areas. (X200). (E) Portal area in the liver of Alb intoxicated rat showing congestion of portal vessel (CO), mononuclear inflammatory cells infiltration (arrow) and mild edema (Ed). (X200). (F) Liver of rats intoxicated with Alb and pretreated with OME showing good restoration of the hepatic cells with mild degenerative and necrotic (arrow) changes. (X200). (G) Liver of Alb intoxicated and pretreated with OME showing granular degeneration (arrow) and scattered necrosis (dashed arrow) of the hepatic cells with mild activation of Kupffer cells (short arrow). (X400) .

Diagnosis of acute hepatitis was confirmed by the presence of jaundice or non-specific symptoms of acute illness accompanied by elevation of AST and/or ALT activities. The values for diagnosis of acute liver injury are 200 U/L and 300 U/L for AST and ALT respectively. An exacerbation occurred 60 days after discontinuation of the drug, followed by progressive normalization (Narciso-Schiavon et al., 2018).

Our work showed that Alb administration at dose rate of 7.5 mg/kg b.wt. caused hepatocellular injury leading to histopathological alterations of liver tissue as coagulative necrosis and vacuolar degeneration which was confirmed by histopathological studies on liver tissue biopsy. While pretreatment with OME at dose of 200mg/kg b.wt for 30 days caused improvement of liver histopathological structure due to OME hepatoprotective effect.

Our histopathological studies showed that liver of Alb-treated group showed dilatation of the liver sinusoids with leukocytic cell infiltration. The central veins showed congestion with the appearance of large eosinophilic areas of coagulative necrosis containing nuclear remnants and vacuolar degeneration of some hepatocytes. Portal area in the liver of Alb administrated rat showed congestion of portal vessel, mononuclear inflammatory cells infiltration and mild edema. All that comes in agreement with that showed by Narciso-Schiavon et al., (2018) who proved that Alb administration caused changes of overall architecture, portal area containing a small number of mononuclear cells and intact plate, low changes in lobules, and parenchyma containing adjustment and a small number of mononuclear cells. Our results proved also that liver biopsy showed periportal steatosis and periportal necrosis, the abnormal hepatic function test is getting better only with supportive treatment and in early stages, that comes in agreement with Zuluaga et al., (2013) who said that the effect of Alb on liver biopsy showed that portal tracts infiltrated with moderate and mixed inflammatory cells, consisting of lymphocytes, plasma cells, neutrophils, and eosinophils.

The effect of pretreatment with OME (200mg/kg b.wt for 30 days) plus Alb (7.5mg/kg b.wt for 15 days) orally to rats showed a regeneration of hepatocytes which manifested by return of levels of serum alanine

transaminase, aspartate transaminase, alkaline phosphate, total bilirubin, and total protein and albumin level at day 1, 7, and 14 post treatment, to normal levels and improvement of histopathological structure of liver with good restoration of the hepatocytes, granular degeneration, scattered necrosis of the hepatocytes with mild activation of Kupffer cells. The obtained results were consistent with Al-harbi (2011) who showed that *Origanum majorana* has antioxidant activity which protect liver against Alb-induced hepatotoxicity (Saleem and Nasser 2014) mentioned that *Origanum majorana* can increase the metabolism, improve blood circulation, overcome side effects of some drugs and it also, improve liver function and protect liver tissue. Also, Abdel-tawab et al., (2015) evaluated the oxidative damage and hepatotoxicity and indicated that *Origanum majorana* leaves could be used for therapeutic option against hepatic injuries resulting from some chemicals.

In the present work the benefits of OME were confirmed by histopathological observations, oral administration of OME together with Alb results in a great regeneration of damaged liver tissue occurred due to Alb administration. Liver of Alb administrated rat which pretreated with OME showed good restoration of the hepatic cells with mild degenerative and necrotic changes, it also showed granular degeneration and scattered necrosis of hepatocytes with mild activation of Kupffer cells. These results were in agreement with habibi et al., (2015) who proved that OME has high amount of phenolic and flavonoids compounds that induced potent hepatoprotective mechanisms against many toxicants and prevent hepatic damage.

In addition, OME is non-toxic and showed no alteration in liver biomarkers, supported with the reduction in hepatic AST, ALT, ALP, direct bilirubin and total protein to normal levels and increased level of the reduced serum albumin towards the normal levels.

5. Conclusion

It might be concluded that OME (200 mg/kg b.wt) can ameliorate hepatotoxicity induced by Alb. This finding proved that the traditional use of this plant for hepatoprotective action was of a great benefit in rat and might be beneficial for liver toxicity.

6. REFERENCES

1. Abdel-tawab H.M., Tarek M. M., Samia M.M., and Amel A.R. (2015). Antioxidant potential and hepatoprotective activity of *Origanum majorana* leaves extract against oxidative damage and hepatotoxicity induced by pirimiphos-methyl in male mice. *Journal of applied sciences*, 15 (1), 69-79. DOI:10.3923/jas.2015.69.79
2. Al-Harbi N.O. (2011). Effect of Marjoram extract treatment on the cytological and biochemical changes induced by cyclophosphamide in mice. *J Med Plants Res*, 5 (23), 5479-5485.
3. Benhalilou N, Alsamri H, Alneyadi A, Athamneh K, Alrashedi A, Altamimi, N, Al Dhaheri Y, Eid H and RabahIratni, R. (2019). *Origanum majorana* ethanolic extract promotes colorectal cancer cell death by triggering abortive autophagy and activation of the extrinsic apoptotic pathway. *Front oncol.* 9:795. Doi: 10.3389/fonc.2019.00795.
4. Chishti S, Kaloo ZA, Sultan P. (2013). Medicinal importance of genus *Origanum*: A review. *Journal of Pharmacognosy and Phytotherapy* 5(10), 170-177. Article Number -7B02BA440210. Doi.org/10.5897/JPP2013.0285
5. Choosongsang, P.; Anucha Bodhikul, A.; Musigavon, P.; Anothai Pocathikor, A. (2011): Modified Jendrassik-Grof method for measurement of direct bilirubin: an improvement of in-house method. *Songklanagarind Medical Journal*, 29(1) :19-26.
6. Doumas, B.T., Watson W.A., Biggs, H. G. (1997). Albumin standards and the measurement of serum albumin with bromocresol green. *Clinica chimica acta* 258(1), 21-30. Doi.org/10.1016/S0009-8981(96)06447-9
7. El-Shafeey, E. and Taha, T. (2013). Protective effect of oregano water extract against Carbon tetrachloride induced hepatotoxicity in female rats; *Egypt. Acad. J. Biolog. Sci.*, 5(2): 67-76. DOI:10.21608/eajbsc.2013.16096
8. Espinosa, E; García, A; Saavedra, E and Pierres, O (2015). Albendazole induces oxidative stress and DNA damage in the parasitic protozoan *Giardia duodenalis*. *Front Microbiol.*, 6: 800. doi: 10.3389/fmicb.2015.00800.
9. Fabio, J., Maria, L., Gabriel, L. and Renner, P. (2015). Sub fulminant Acute Liver Failure by Albendazole: Case Report. *J Med Cases*. 6(8): 342-345.
10. Farias, G., Brutti, O., Grau, R., Di Leo Lira, P., Retta, D., van Baren, C., Vento, S. and Bandoni, A. L. (2010). Morphological, yielding and quality descriptors of four clones of *Origanum* spp. (Lamiaceae) from the Argentine Littoral region Germplasm bank. *Ind. Crop. Prod.*, 32 (3), 472-480. doi: org/10.1016/j.indcrop.2010.06.019.
11. Habibi E., Shokrzadeh M., Chabra A., Naghshvar F., Keshavarz R. and Ahmadi A. (2015). Protective effects of *Origanum vulgare* ethanol extract against cyclophosphamide-induced liver toxicity in mice; *Pharm Biol.*, 53(1): 10–15. doi:10.3109/13880209.2014.908399.
12. Narciso-Schiavon, J. L., Delziovo, H.A., Santos L.E.B., Shiozawa, M.B.C and Schiavon, L.L. (2018). Hepatitis aguda recorrente inducida por albendazole. *Revista Colombiana De Gastroenterologia*, 33(4), 473-477.
<http://doi.org/10.22516/25007440.206>.
13. Omotoso O, Enaibe U, Oyewopo O and Onanuga, O. (2013). Liver enzymes derangement and the influence of diet in animals given oral albendazole. *Niger med J.* 54(5): 310-312. doi: 10.4103/0300-1652.122333.
14. Pasavei G.; Mohebbati, R.; Boroumand, N.; Ghorbani, A.; Hosseini, A.; Jamshidi, T and Soukhtanloo, M. (2020): anti-hypolipidemic and anti-oxidative effects of hydroalcoholic extract of *Origanum majorana* on the hepatosteatosis induced with high-fat diet in rats. *Malaysian Journal of Medical Sciences*, 27(1): 57-69. DOI:10.21315/mjms2020.27.1.6.
15. Reitman S and Frankel S (1957). A colorimetric method for the determination of serum glutamic oxalacetic and glutamic pyruvic transaminases. *American journal of clinical pathology*, 28, 56-63. <https://doi.org/10.1093/ajcp/28.1.56>.
16. Rios D and Restrepo C (2013). Albendazole-induced liver injury: a case report. *Colomb Med (Cali)*. 44(2): 118–120.
17. Saleem, M and Naseer F (2014): Medicinal plants in the protection and treatment of liver diseases. *Bangladesh J Pharmacol.* 9: 511-526. DOI: 10.3329/bjp.v9i4.20648.
18. Shah C, Shukla A and Bhatia S (2013): Recurrent acute hepatitis caused by albendazole. *Tropical Gastroenterology*, 34(1): 38–39.
19. Tietz, N.W. et al., (1983). A reference method for measurement of alkaline phosphatase activity in human serum study group on alkaline phosphatase. *Clinical Chemistry*, 29(5): 751-61.
20. Zuluaga I, Castro E, Cadavid C and Gutierrez C (2013). Albendazole -induced granulomatous hepatitis: case report. *Journal of Medical Case Reports*, 7:201.