

Manuscript ID ZUMJ-2111-2397 (R3)
DOI 10.21608/ZUMJ.2021.103948.2397

ORIGINAL ARTICLE
ARTHROSCOPIC MANAGEMENT OF INTRA-ARTICULAR ANKLE FRACTURES

*Elsayed abdelmoaty Mohamed **, *Adel Abdelazeem Ahmed*, *Mohamed Abdallah abdel salam*, *Abdelbaset Elsayed adaros*.

Faculty of Medicine, Zagazig University, Department of Orthopedic Surgery, Sharkia, Egypt

Corresponding author:

Submit Date 2021-11-09
Revise Date 2021-12-09
Accept Date 2021-12-20

ABSTRACT

Background: The classic operative management of ankle fractures is open reduction- internal fixation (ORIF). Despite radiographic evidence of anatomic reduction, there is a failure to achieve good clinical outcomes. The high incidence of concomitant intra-articular pathology associated with ankle fractures that may go unrecognized using traditional open approaches is possible reason for this.

Methods: The main target of this research is to evaluate frequency of cartilage injuries with ankle fracture and its effect on functional outcome. This is a prospective study was carried out in orthopedic department at Zagazig university hospital on 49 patients with ankle fracture managed by fixation with concomitant usage of arthroscopy.

Results: In this study 40 patients had cartilage injuries (83%) and 9 cases were free. As regarding syndesmotom injuries, 23 patients (48 %) had syndesmotom injuries which were complete rupture (13 cases) and partial injuries involve rupture of anterior tibiofibular ligament rupture (10 cases). The functional results were graded according AOFAS score as excellent in 16 patients, good in 20 patients, fair in 10 patients, with poor results in 3 patients.

Conclusions: The ankle arthroscopy has prognostic and diagnostic advantages that can help to manage ankle fracture. we expect that arthroscopy will be mandatory in dealing with ankle injuries as it is superior to traditional methods in showing hidden side of trauma.

Keywords: Ankle arthroscopy; cartilage injury; ligamentous injury



INTRODUCTION

Anatomic reduction and rigid fixation of ankle fractures is classically performed through an open approach. Intra operative gross inspection and fluoroscopic assessment are the surgeons tools to achieve anatomical reduction. This technique may fail to fully address the entire injury because intra-articular pathology cannot be completely visualized and therefore may be missed [1]. The missed lesions explain suboptimal results following excellent anatomical reduction and rigid fixation in certain cases [2]. Arthroscopic assisted reduction and fixation of ankle fractures provides a mean to completely assess intra-articular pathology as well as provide direct therapeutic intervention in many instances including debridement of loose intra-articular fragments, assisted fracture reduction, microfracture of chondral injuries and assessment of overall joint stability and minimize operative incisions [3-4].

The purpose of this study is arthroscopic evaluation of trauma insult to ankle cartilage and ligaments and its effect on functional outcome and arthroscopy role in diagnosis and early management of such injuries.

Patients and Method

METHODS

From January 2016 to April 2020, 49 patients with ankle fractures were included in this study(table 1) , From the 49 patients 36 were males, 13 were females , the right ankle was affected in 26 patients while the left ankle was affected in 23 patient and the dominant side was affected in 31 patients. The mean age was 24 years ranging from 15 to 55 years.

According to Weber classification 4 cases had fractures distal to syndesmosis (Weber type A) , 15 fractured at level of syndesmosis (Weber type B), 10 fractured above the syndesmosis (Weber type C).

Using arthroscopy as a method of cartilage and ligaments evaluation and judge accuracy of fracture reduction. We use Outerbridge classification as a method of evaluating cartilage trauma [4].

Patients were evaluated post-operatively and every 2 months, until one year after surgery, during routine clinic follow-up visits. Functional outcomes at one year after operation were graded using the AOFAS scoring scales, which ranges from 0 to 100, with higher scores indicating lesser impairment^[5].

- Excellent : AOFAS score 90-100 points.
- Good : AOFAS score 80-89 points.
- Fair : AOFAS score 65-79 points.
- Poor : AOFAS score <64 points.

Also, radiological evaluation was done Plain x-rays ankle A/P & lat after operation and at expected time of healing. Evaluation of anatomical reduction, bone healing, arthritic changes of the ankle joint are the main topics.

Ethics and consent to participate

All patients included in our study provided written informed consent to participate. The study has been carried out in accordance with the code of Ethics of the World Medical Association (Declaration of Helsinki) for studies involving humans .

surgical technique

The time of surgical intervention is the time of edema subsides and skin wrinkles appear. The average delayed time from injury to surgery from 3 to 7 days.

All surgeries were performed with the patient supine and under spinal anesthesia. A tourniquet was applied around the thigh. Manual distraction by an assistant or a loop of Kerlex around the patient's ankle and controlled by the surgeon's hand or waist was used for distracting the joint. In certain cases, we use external fixator as a method of distraction.

The patient's foot and leg were prepared in the usual manner for a surgical procedure as regarding sterilization and draping. A 2.7 mm 30° angled arthroscopic lens was used in conjunction with a video-camera, video-monitor, light guide and light source. The gravity irrigation system was performed using saline solution according to the needs. The fluid entered the ankle through one valve (*Inflow*) of a double-valve Arthroscopic cannula and exited through the other one (*outflow*). we used only the anteromedial and anterolateral portals to visualize the ankle . Initially by using the anteromedial portal the arthroscope was first directed to the tip of the

medial malleolus, and the deep portion of the deltoid ligament was evaluated.

The arthroscope was then directed up the medial gutter, examining the articulation between the talus and medial malleolus. The examination proceeded around the medial convexity of talus and then over the talar dome with its articulation with the tibial plafond .Then the distal tibiofibular articulation and lateral convexity of the talar dome were visually inspected and traced down to the tip of fibula. As fibular tip was identified, the anterior talofibular ligament was noted anteriorly and was probed using the anterolateral portal.

In this study, however, we didn't used the antero-central portal and did not require the posterior portals. The main target is removal of loose bodies, anatomical reduction of the cartilaginous surface and ligamentous injury evaluation (deltoid and syndesmosis) (**Figures 1-4**).After scoping of ankle joint, fixation of the fracture either open or minimal invasive according to configuration of fracture and available method of fixation.

Post operative splint, leg elevation for first 24 hours, antibiotics and analgesia in the first few days after operation. Anteroposterior and lateral x ray are done after the operation and then monthly to check for bone healing. Suture were removed two weeks post-operative according to wound healing. Follow up visits are conducted every month .No weight bearing was allowed till appearance of bone healing.

Statistical Analysis

Data were coded and entered using statistical package SPSS (statistical package for social sciences).Data was summarized using mean, standard deviation, median, minimum and maximum in quantitative data using frequency (count) and relative frequency (percentage) for categorical data. Comparisons between quantitative variables were done using the non-parametric Kruskal-Wallis and Mann Whitney tests. Correlations between quantitative variables were done using Spearman coefficient P-values less than 0.05 were considered as statistically significant.

RESULTS

In our study 40 patients had cartilage injuries (83%) and 9 cases were free. The majority were in articular surface of the tibia(41%) followed by the talus (38%) then articular surface of the fibula (21%). 20 articular surfaces had cartilage injuries grade 2 and 14 surfaces had cartilage injuries grade 3 and 6 surfaces had cartilage injuries grade 4.

With full thickness cartilage injuries (grade 4), the loose bodies were removed and

microfracture technique to exposed subchondral bone were done. with cartilage injuries grade 2 and 3 ,debridement and confirmation of stability of the injury sites were our target. The trauma to the cartilage have high incidence with Weber type B comparing to type A and C.

As regarding syndesmotic injuries, 23 patients (48 %) had syndesmotic injuries which were complete rupture (13 cases) and partial injuries involve rupture of anterior tibiofibular ligament rupture (10 cases).

Clinical evaluation:

AOFAS score

Ankle – hind foot scale (100 points), American orthopedic foot and ankle scoring system is used as a scale to evaluate functional outcome of our surgical intervention.

The functional results were graded as excellent in 16 patients, good in 20 patients, fair in 10 patients, with poor results in 3 patients. The excellent and good results were considered as satisfactory, while fair and poor results were

considered unsatisfactory. Thus, satisfactory results were found in 36 patients, and unsatisfactory results were found in 13 patients.

Radiological evaluation:

Immediate postoperative x-ray images revealed a good reduction in all Patients. The mean healing time was 2 months (1.5 – 5 months). 6 cases were complicated by ankle arthritis.

Complications

Only one case has saphenous nerve injury at anteromedial portal. 4 cases has superficial infection that respond well to third generation cephalosporin antibiotic. one case had deep infection, surgical debridement and implant removal was done. A case of isolated lateral malleolus was complicated by nonunion and iliac graft was used. One case has an ankle fistula at anterolateral portal and was closed by periosteal flap. 6 cases were complicated with osteoarthritis ankle. 5 cases with mild to moderate symptoms and managed conservatively and the one case had severe pain and ankle arthrodesis was done.

Table 1: Distribution of patients in the study

Type of fracture	No of patients	Percentage
Medial malleolus	7	14 %
Lateral malleolus	14	28.5 %
Bimalleolar	11	22.4 %
Pilon	9	18 %
Syndesmotic disruption	5	10 %
Epiphyseal injury	3	6 %

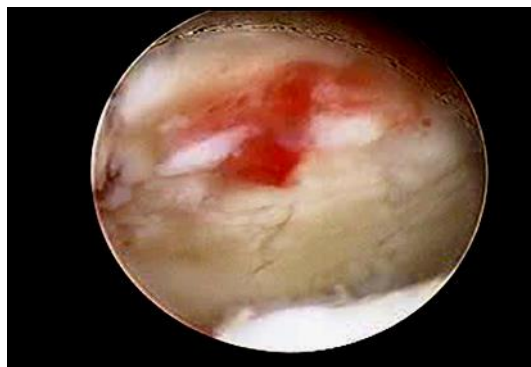


Figure1: Tibial surface showing many fissures and raw surface in the cartilage.

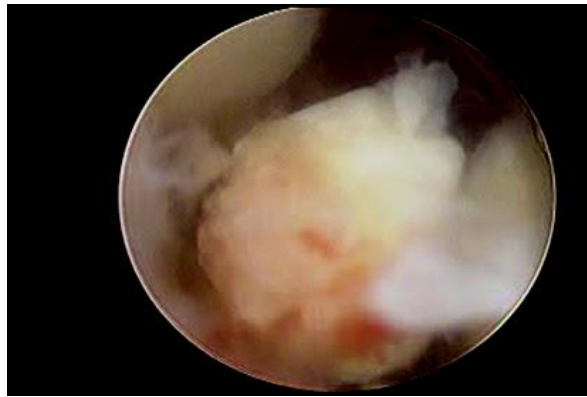


Figure2: Loose body in tibiotalar space.

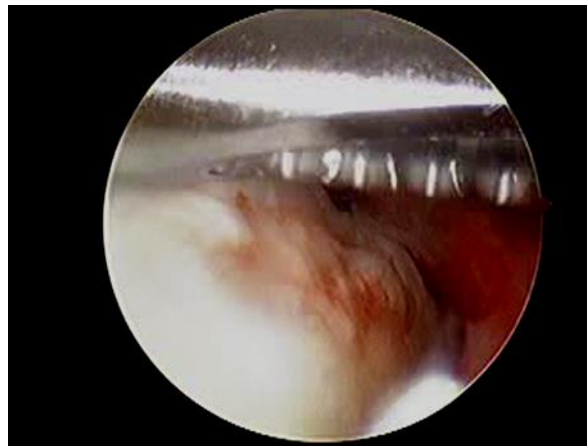


Figure3: Cartilage injury at talus shoulder.

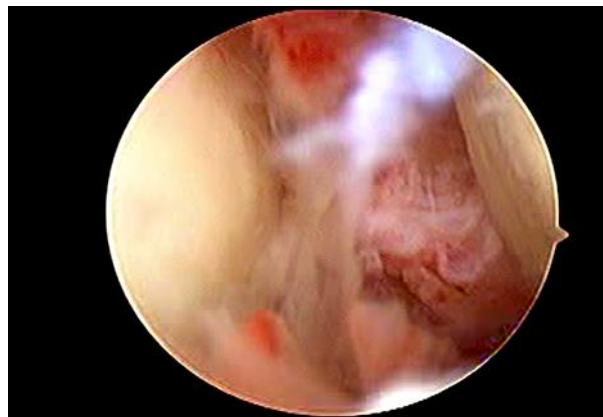


Figure4: Medial gutter view showing partial disruption Of deltoid ligament.

DISCUSSION

Rotational ankle fractures are among the most commonly treated orthopedic injuries account for 9% of fractures [7]. Open reduction and internal fixation (ORIF) remains the gold standard treatment for unstable injuries and studies from as early as 1965 and 1985 have shown good to excellent results in a large number of patients. However, there is still a subset of patients who do not achieve satisfactory results despite appropriate treatment with anatomic reduction and rigid fixation of the fracture. One large systematic review including 1822 patients showed that 21% of patients had a fair or poor outcome at an

average of 5.1 years post operation despite optimally reduced fractures.

One possible explanation for this group of patients failing to achieve satisfactory results is concomitant intra-articular injury occurring at the time of the ankle fracture. The rate of intra-articular injury associated with a rotational ankle fracture has been reported to be as high as 63% to 79% in some studies [8].

This study included 49 patients treated using ARIF (arthroscopic assisted reduction and fixation) and the target is to see the hidden side of ankle trauma involve cartilage and ligamentous injuries. In this study the ankle joint was scoped

before fixation for diagnosis of cartilage and ligamentous injury and after fixation for check reduction of fracture and confirm that no hardware penetrate the joint.

In this study 40 patients had cartilage injuries (83%) and 9 cases were free. As regarding syndesmotic injuries, 23 patients (48 %) had syndesmotic injuries which were complete rupture (13 cases) and partial injuries involve rupture of anterior tibiofibular ligament rupture (10 cases). Comparing arthroscopy and fluoroscopy as tools for reduction evaluation, the arthroscopy was superior to fluoroscopy to evaluated reduction of cartilaginous part of the fracture and the fluoroscopy was used for evaluation of reduction and directing screws. One of the advantage of post fixation arthroscopic evaluation is confirmation that screws are not intra-articular.

The functional results were graded according AOFAS score as excellent in 16 patients, good in 20 patients, fair in 10 patients, with poor results in 3 patients.

The results are comparable with results of Yassin et al [9] who discovered abnormal arthroscopic findings in 15 out of 22 patients (68%) that could not be seen on radiographs. In (6/22) 36% of the patients with grade 4 cartilage damage, a loose body was removed. Most of the patients (78%) had some syndesmotic damage. In 4/22 patients hypertrophic synovitis of the anterior ankle was observed and resected with 2 years follow-up results were quite good with an average AOFAS score of 82±8.

Our results were comparable with Smith et al [10], who compared between two groups the first with using arthroscopy (ARIF) and the second without using arthroscopy (ORIF). The study included 213 total patients (142 traditional ORIF, 71 ARIF) with an average age of 40 years. The average follow-up was 32.4 months. During arthroscopy the findings were a 28% (20/71) rate of full-thickness osteochondral lesions, 33% (24/71) rate of loose bodies, and a 49% (35/71) rate of partial-thickness cartilage injury. In addition, the patient satisfaction rate in Weber B fibula fractures was higher in those patients who underwent arthroscopy compared with ORIF alone (93% vs 75%, $P = 0.05$).

Our results were comparable to study of Cunha, Rachael et al [11], which included 116 consecutive patients undergoing acute ankle fracture ORIF with concurrent arthroscopy. A chondral lesion was identified in 78% (90 of 116). A full-thickness talar dome chondral lesion was identified in 43% of these patients (39 of 90). Patient age was a significant predictor, with patients younger than 30 years being less likely to

have a chondral injury than those aged 30 years or older (59% vs 85%, $P = 0.0077$). Of the patients who sustained a dislocation at the time of injury, 100% had a chondral lesion ($P = 0.039$). Patients with complete syndesmosis disruption and instability were also more likely to have a chondral lesion (96% vs 73%, $P = 0.013$). Patients with chondral lesions had statistically significantly worse clinical outcomes than those without them (Foot and Ankle Outcome Score, 81.2 vs 92.1; $P = 0.009$).

CONCLUSIONS

In conclusion, this study adds to the growing body of evidence indicating the clinical benefits of performing ankle arthroscopy on ankle fractures in adults, and the positive impact this minimally-invasive and revealing technique has on patient outcomes. The ankle arthroscopy has prognostic and diagnostic advantages that can help to manage ankle fracture. There are some disadvantages of using arthroscopy like increase time of operation (mean 30 minutes), fluid extravasation, nerve injury, high learning curve but we expect that arthroscopy will be mandatory in dealing with ankle injuries.

Limitations of the study include a small cohort, and a relatively short follow-up period.

CONFLICT OF INTEREST :None

FINANCIAL DISCLOSURE : None declared

REFERENCES

1. **Stufkens SA, van den Bekerom MP, Kerckhoffs GM, Hintermann B, van Dijk CN.** Long-term outcome after 1822 operatively treated ankle fractures: a systematic review of the literature. *Injury*, 2011 Feb;42(2):119-27. doi: 10.1016/j.injury.2010.04.006. PMID: 20444447.
2. **Hintermann B, Regazzoni P, Lampert C, Stutz G, Gächter A.** Arthroscopic findings in acute fractures of the ankle, 2000. *J Bone Joint Surg Br*;82:345-351.
3. **Thordarson DB, Bains R, Shepherd LE.** The role of ankle arthroscopy on the surgical management of ankle fractures. *Foot Ankle Int* 2001;22(2):123-5. PubMed PMID: 11249221. Epub 2001/03/16. eng.
4. **Casey Slattery, BS and Christopher Y, Kweon, MD.** Outerbridge Classification of Chondral Lesions in *Clin Orthop Relat Res* 2018 Oct; 476(10): 2101-2
5. **Ono A, Nishikawa S, Nagao A, Irie T, Sasaki M, Kouno T.** Arthroscopically assisted treatment of ankle fractures: arthroscopic findings and surgical outcomes, *Arthroscopy*, 2004 Jul;20(6):627-31. doi: 10.1016/j.arthro.2004.04.070. PMID: 15241315.
6. **Paluvadi SV, Lal H, Mittal D, Vidyarthi K.** Management of fractures of the distal third tibia by minimally invasive plate osteosynthesis - A prospective series of 50 patients. *J Clin Orthop Trauma* 2014; 5: 129-136.
7. **Slattery C, Kweon CY.** Classifications in Brief: Outerbridge Classification of Chondral Lesions.

ClinOrthopRelat Res. 2018 Oct;476(10):2101-2104. doi: 10.1007/s11999.0000000000000255. PMID: 29533246; PMCID: PMC6259817.

8. Court-Brown CM, Caesar B. Epidemiology of adult fractures: A review. *Injury*, 2006 Aug;37(8):691-7. doi: 10.1016/j.injury.2006.04.130. Epub 2006 Jun 30. PMID: 16814787.

9. Stufkens SA, van den Bekerom MP, Kerkhoffs GM, Hintermann B, van Dijk CN. Long-term outcome after 1822 operatively treated ankle fractures: a systematic review of the literature. *Injury*, 2011 Feb;42(2):119-27. doi: 10.1016/j.injury.2010.04.006. PMID: 20444447.

10. Yassin M, Garti A, Heller E and Robinson D. Ankle Arthroscopy Findings During Ankle Fracture

Fixation and Mid-Term Prognosis. *SM Musculoskelet Disord*, 2017; 2(3): 1022. DOI 10.36876/smmd.1022.

11. Smith KS, Drexelius K, Challa S, Moon DK, Metzl JA, Hunt KJ. Outcomes Following Ankle Fracture Fixation With or Without Ankle Arthroscopy. *Foot & Ankle Orthopaedics*, January 2020. doi:10.1177/2473011420904046.

12. Rachael J, Da Cunha, Sydney C, Karnovsky, BA, William Schairer and Mark C. Drakos. Ankle arthroscopy for diagnosis of full-thickness talar cartilage lesions in the setting of acute ankle fractures. *Arthroscopy: The Journal of Arthroscopic & Related Surgery* 34.6, 2018: 1950-1957. <https://doi.org/10.1016/j.arthro.2017.12.003>.

To cite:

adaros, A., mohamed, E., Ahmed, A., abdel salam, M. Arthroscopic management of intra-articular ankle fractures. *Zagazig University Medical Journal*, 2024; (103-108): -. doi: 10.21608/zumj.2021.103948.2397