

Role of MRI Diffusion in differentiating of benign and malignant ovarian masses**Ahmed Samir Kamel^a, Mohammad Tharwat Mahmoud Solyman^a,****Ahmed Tageldin Abdelhafez^b and Nahla Mohammed Ali^a**^aDiagnostic Radiology Department, Faculty of Medicine, Sohag University, Sohag, Egypt.^bObstetrics and Gynecology Department, Faculty of Medicine, Sohag University, Sohag, Egypt**Abstract**

Background: Ovarian masses are more common findings incidentally detected in symptomatic patients in every day work, to characterize them MRI is a modality of choice due to its high tissue contrast so MRI has high sensitivity, specificity and accuracy.

Objectives: Assessment of role of MRI diffusion in differentiating of benign and malignant ovarian masses.

Patients and method: Study was carried out on 60 female cases presented by ovarian masses referred from the OB/GYN out clinic and in patients between September 2019 and September 2020. The study was done in MRI unit, Diagnostic Radiology Department at Sohag Faculty of Medicine during the period from September 2019 to September 2020. For every patient a written consent was taken, patient's clinical data, pelvi-abdominal US, laboratory investigations and pelvis MRI were done.

Results: 46 cases (76.7%) had benign ovarian lesions and 14 cases (23.3%) had malignant ovarian lesions. All the malignant cases (100%) show restriction at DWI while only 11 benign cases (23.9%) show restriction at DWI. The mean ADC was $1.76 \times 10^{-3} \text{ mm}^2/\text{s}$, with a range from $0.5 \times 10^{-3} \text{ mm}^2/\text{s}$ to $3 \times 10^{-3} \text{ mm}^2/\text{s}$ (P value <0.001 (HS)). The mean ADC was higher among benign cases ($2.082 \times 10^{-3} \text{ mm}^2/\text{s}$) compared to malignant ones ($0.707 \times 10^{-3} \text{ mm}^2/\text{s}$), ADC cut-off point is $0.895 \times 10^{-3} \text{ mm}^2/\text{s}$, with a sensitivity of 89.1% and a specificity of 92.9% with P value <0.001.

Conclusion: DWI and ADC value increases the accuracy of MRI to discriminate between benign and malignant lesions. Cut-off value was $0.89 \times 10^{-3} \text{ mm}^2/\text{s}$ to differentiate between benign and malignant ovarian masses.

Keywords: Ovary, Diffusion-weighted MR imaging, Ovarian tumors, ADC value.

Copyright: © Kamel et al. (2022) Immediate open access to its content on the principle that making research freely available to the public supports a greater global exchange of knowledge. Users have the right to Read, download, copy, distribute, print or share link to the full texts under a [Creative Commons BY-NC-SA 4.0](https://creativecommons.org/licenses/by-nc-sa/4.0/) International License.

Introduction

Ovarian masses are more common findings incidentally detected or identified in symptomatic patients in every day work and how to characterize them is real diagnostic challenge, this is of great importance in the preoperative assessment in order to obtain adequate surgical management (Foti et al., 2016).

DWI increase the sensitivity, specificity and accuracy of MRI in differentiating between benign and malignant ovarian masses, detect peritoneal implants, tumor staging and follow up (Kyriazi et al., 2010). DWI based on the free movement of the water molecule (the Brownian motion). The strength of the diffusion is the (b) value. Multiple B values are used in scanned the masses of interest (0, 500, 800, and 1000s/mm²), the b value 0 and 500 not assessed due to less diffusion and larger T2 shine through effect however they used to provide ADC map with good resolution and accurate measurement of the ADC value (Coats et al., 2009). Whenever ADC value depend on the free movement of the water molecules, increase tissue cellularity as in malignant tumors will decrease the water molecule movement hence it will reduce the ADC value, also in abscesses, some endometrioma

ADC value is low due to the pus under tension (in abscesses) and deoxyhemoglobin and met hemoglobin (in endometrioma) will decrease the water molecule movement (Tamai et al., 2008; Mohaghegh and Rockall et al., 2012; Imaoka et al., 2006). The mean ADC for benign ovarian masses was $1.2 + 0.34 \times 10^{-3} \text{ mm}^2/\text{s}$, for borderline masses was $1.1 + 0.06 \times 10^{-3} \text{ mm}^2/\text{s}$, and for malignant tumors $0.83 + 0.15 \times 10^{-3} \text{ mm}^2/\text{s}$ (Mansour et al., 2015). The ADC cut-off of $1.1 \times 10^{-3} \text{ mm}^2/\text{s}$ that discriminate between benign and malignant ovarian lesions (Van Nimwegen et al., 2020).

Patients and method

This study comprised 60 female patients, ranging in age from 1 year to 86 years, who had ovarian masses and were referred from an OB/GYN out clinic between September 2019 and September 2020. The research was carried out at the Sohag Faculty of Medicine's MRI facility in the diagnostic radiology department.

Every patient who took part in the trial was put through a series of tests (written consent, obtained clinical data, Pelvi-abdominal US, Laboratory investigation and Pelvis MRI).

Ethical considerations

An approval was taken from the local scientific ethical committee before starting in the protocol of this study.

Inclusion criteria

Female patient presented by ovarian mass.

Exclusion criteria

Patients with non-gynecological urologic causes of pelvi-abdominal mass or pelvic pain.

MRI protocol

- A 1.5-T MR imaging machine was used for the MR examinations (PHILIPS, Achieva 1.5 tesla), the patients were scanned in the supine position with a pelvic phased-array coil.
- Axial, coronal and sagittal T2-weighted fast spin-echo (SE) sequences. Axial T1 and axial Fat saturation was done to assess the presence of fat by demonstrating signal drop out.
- Axial T1-weighted image after contrast was taken, the contrast dose (Gadolinium) is 0.2 mL/kg (0.1 mmol/kg) given as a bolus IV injection.
- Diffusion weighted images were gained before contrast administration, slice thickness 6 mm,

inter-slice gap 1 mm, variable (b) values were done (0, 500, 800& 1000 s/mm²) to get ADC values.

Image analysis

MR images were assessed for: site of the lesion (involvement of one or both ovaries), size of the lesion, signal intensity on both T1 & T2 images, thickness of the lesion wall, septations and vegetation, enhancement of the solid component if present, ascites, peritoneal metastasis or enlarged pelvic lymph nodes, involvement of other pelvic organs.

T1-WI with high signal intensity indicates fat or blood. On fat-suppressed images, the signal decreases, although the signal in the blood remains high.

We considered criteria for prediction of ovarian malignancy: size >4–6 cm; predominantly solid masses, cystic tumors with vegetations inside, wall thickening >3 mm, multiple (more than five) and thick (>3 mm) septa, heterogeneous solid component with intermediate signal intensity at T2-WI.

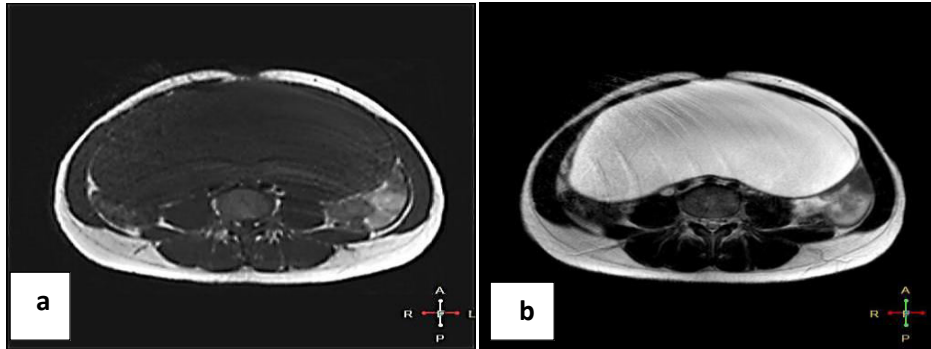


Fig.1. 20-years-old patient, presented with an pelvi-abdominal mass T1WI (a) and T2 (b) revealed well defined smooth thin wall right ovarian cyst hypo intense large at T1WI and hyper intense at T2WI, Showing few internal thin septations measuring +/- 20x18.5x8.5 cm.

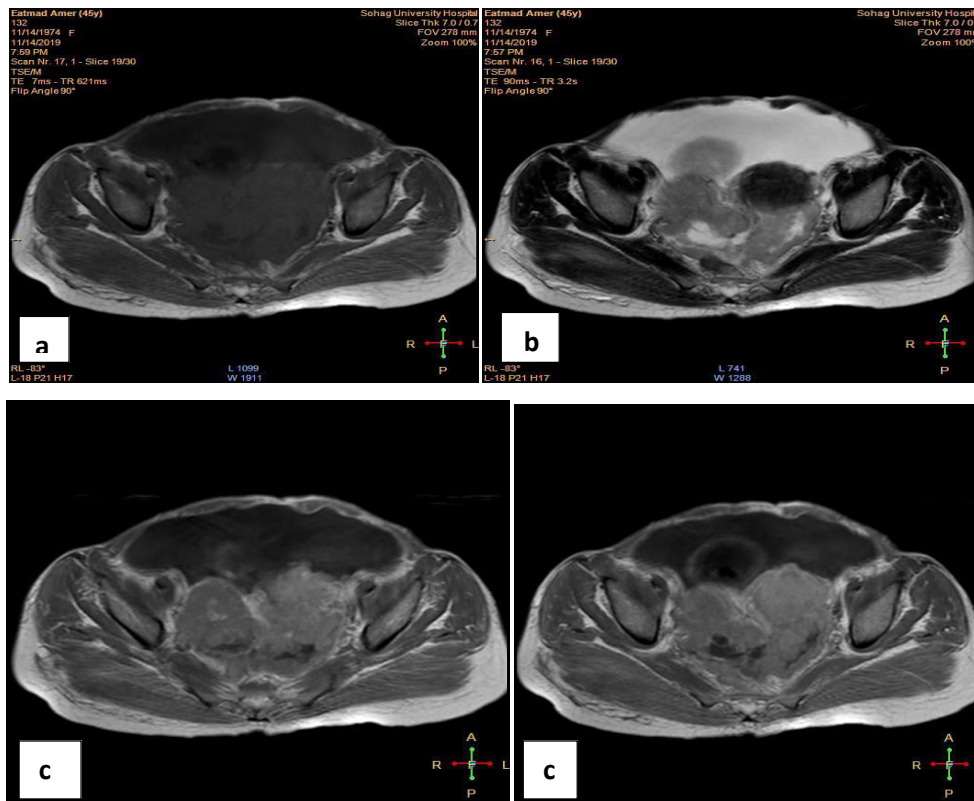


Fig. 2. 45-years-old patient, presented with an pelvi-abdominal mass (Bilateral mucinous epithelial cystadenocarcinoma). MR imaging revealed bilateral complex ovarian mass lesions (cystic and solid components), its cystic component displaying hypo intense signal at T1 (a) and hyper intense signal at T2 (b), the soft tissue component show hypo intense signal at T1 (a) and intermediate signal at T2 (b), enhanced post contrast (c).

DWI analysis

Qualitative analysis:

DW images were taken in the axial oblique orientation and were inspected

for persistent high SI in DWI at $b = 1000 \text{ s/mm}^2$, high signal at DWI with low signal intensity in the corresponding ADC (restricted diffusion) for the solid components of

the lesion are in favor with malignant ovarian lesions, also the signal intensity of the cystic component was observed.

Quantitative analysis:

The ADC values were determined by using ROI on both solid and cystic regions of the masses. In the case of masses with a large solid component, a large ROI was used to cover as much of the pathology as possible; in the case of masses with a small mural nodule, multiple ROIs were used to cover the areas of interest, and at least three measures were obtained and averaged; in all cases ADC values of the cystic component were measured.

Dynamic contrast-enhanced MRI

Post contrast images were used for detection of enhancement of the solid component, the tumor wall, septations, and vegetations.

Standard of reference: In this study the standard of reference was the histopathology of the patient for malignant ovarian lesions and follow up either by pelvi-abdominal US or pelvis MRI for benign lesions.

Statistical analysis

- Demographic, clinical, radiological, and histological data were analyzed descriptively.
- The variable studied were described with mean +/- standard deviation to

measure the degree of dispersion of data around their mean for the different histopathology and the age distribution of the studied patients as well as the mean ADC value of the different ovarian lesions and to distinguish between benign and malignant ovarian lesions.

- Depending on the feature evaluated, the T-test was used to see if there were any significant changes between benign and malignant cases.
- To determine the best ADC value to distinguish between benign and malignant cases, the receiver operating characteristic curve was constructed and its parameters (sensitivity, specificity, positive predictive value, negative predictive value) as well as the accuracy for each ADC threshold were estimated.
- The SPSS statistical software was employed, and a P value of less than 0.001 was considered significant.

Results

DWI was restricted in around 42% of the included cases and DWI restriction was found maximally among malignant cases and ovarian abscess (100%), followed by hemorrhagic cysts (70%) and ovarian dermoid cyst (50%), (**Table.1**).

Table 1. DWI at (b value 1000) for different ovarian lesions

			DWI		Total
			Non restricted DWI	Restricted DWI	
Pathology	Simple ovarian cyst	No	21	0	21
		%	100%	0%	100.0%
	Hemorrhagic cyst	No	3	7	10
		%	30.0%	70.0%	100.0%
	Endometrioma	No	7	1	8
		%	87.5%	12.5%	100.0%
	Ovarian dermoid cyst	No	2	2	4
		%	50.0%	50.0%	100.0%
	Ovarian torsion	No	2	0	2
		%	100.0%	0.0%	100.0%
	Ovarian abscess	No	0	1	1
		%	0.0%	100.0%	100.0%
	Malignant ovarian mass	No	0	14	14
		%	0.0%	100.0%	100.0%
Total		No	35	25	60
		%	58.3%	41.7%	100.0%

Chi square = 10.890, P value = 0.001 (S)

The mean ADC was $1.76 \times 10^{-3} \text{ mm}^2/\text{s}$, with a range from $0.5 \times 10^{-3} \text{ mm}^2/\text{s}$ to $3 \times 10^{-3} \text{ mm}^2/\text{s}$. Low ADC was found in nearly half of the cases (48.3%). Also this table shows that the mean ADC was higher among simple ovarian cyst, ovarian dermoid cyst, hemorrhagic cyst and endometrioma, compared to ovarian torsion, ovarian abscess and malignant ovarian mass, with a highly significant difference, (**Table.2**).

Table. 2. Mean ADC value of different ovarian lesions

Pathology	Mean	Std. Deviation
Simple ovarian cyst	2.427	0.594
Hemorrhagic cyst	1.873	0.942
Endometrioma	1.796	1.052
Ovarian dermoid cyst	2.185	0.998
Ovarian torsion	1.040	0.071
Ovarian abscess	0.900	-
Malignant ovarian mass	0.707	0.135
Total	1.761	0.952

ANOVA = 9.339, P value <0.001 (HS)

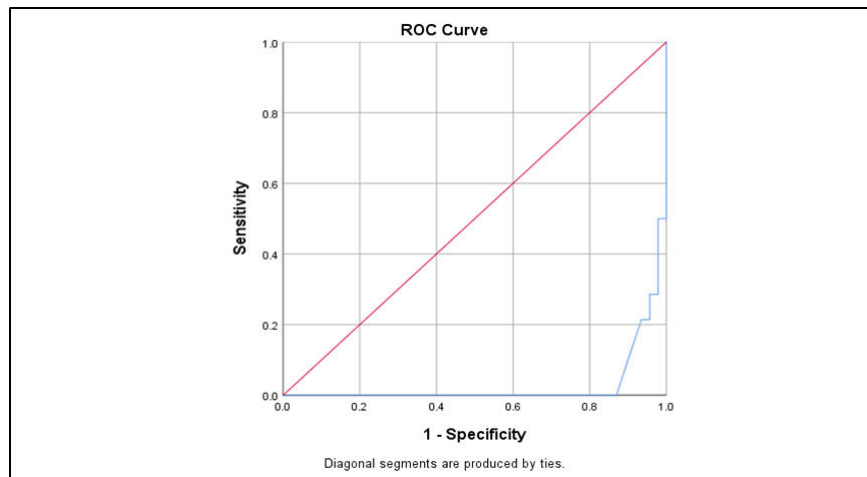


Fig.3. ROC curve analysis for the possible role of ADC to predict malignant ovarian lesions

Discussion

Our findings show that malignant ovarian masses have high signal intensity of its solid components on DW and intermediate to high signal T2-weighted imaging associated with low ADC values, whereas benign ovarian masses have low signal at DWI, low signal at T2, and a high ADC value, agree with our results (Thomassin-Naggara et al., 2011; Bakir et al., 2011; Zhang et al., 2012).

Our findings revealed that ovarian masses were restricted in

around 41.7% of the included cases (25 case) and not restricted at 58.3% (35 case).

In our study, we found that DWI restriction was found in only 24% of the benign cases (Fig. 4,5), compared to 100% of the malignant ones (Fig. 6,7), with a highly significant difference P value <0.001 (HS).

We found that DWI restriction was found maximally among malignant cases and ovarian abscess (100%), followed by hemorrhagic cysts (70%) and ovarian dermoid cyst (50%).

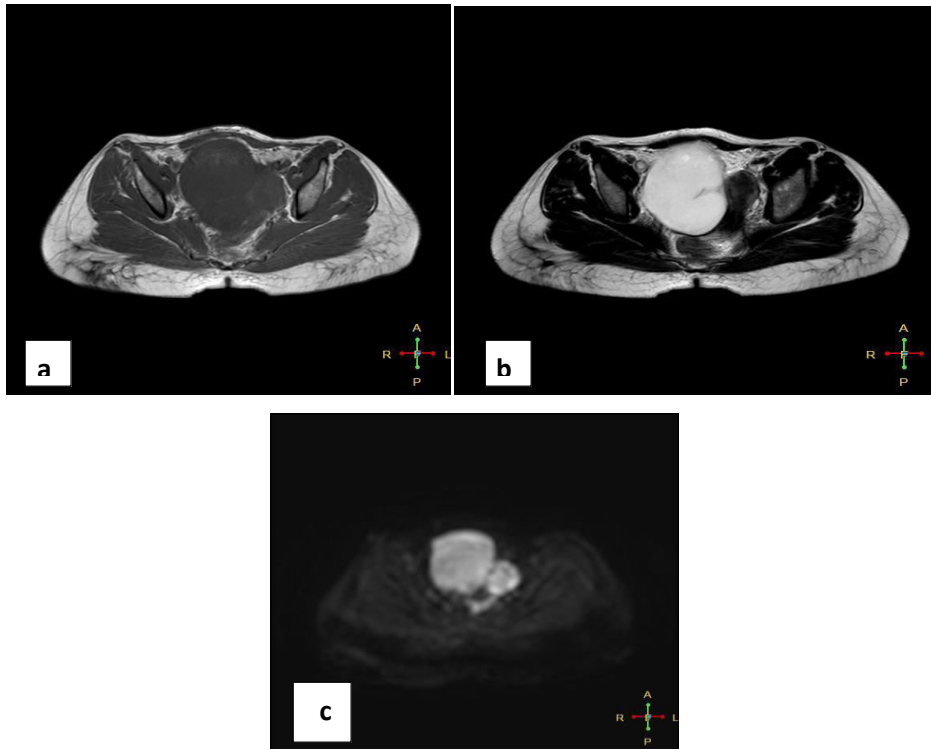


Fig. 4. 30-years-old patient, presented with an pelvi-abdominal mass (Right ovarian mucinous cystadenoma). T1WI (a) revealed right hypo intense well defined smooth thin wall ovarian cyst, Showing few internal thin septations measuring (+/- 10x9x7 cm). Hyper intense at T2WI (b). It show no restriction at DWI (c).

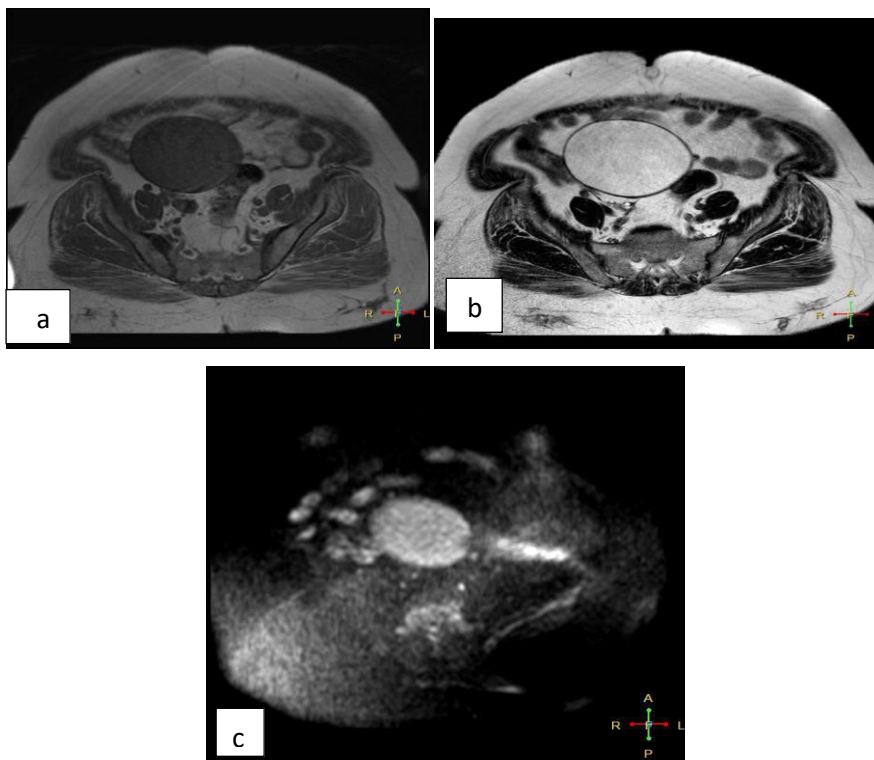


Fig. 5. 62-years-old patient, presented with an pelvi-abdominal mass (Left ovarian serous cystadenoma). T1WI (a) revealed hypo intense large well defined smooth thin wall left ovarian cyst, measuring +/- 10.5x9.5x7.5 cm. Hyper intense at T2WI (b). It shows no restriction at DWI (c).

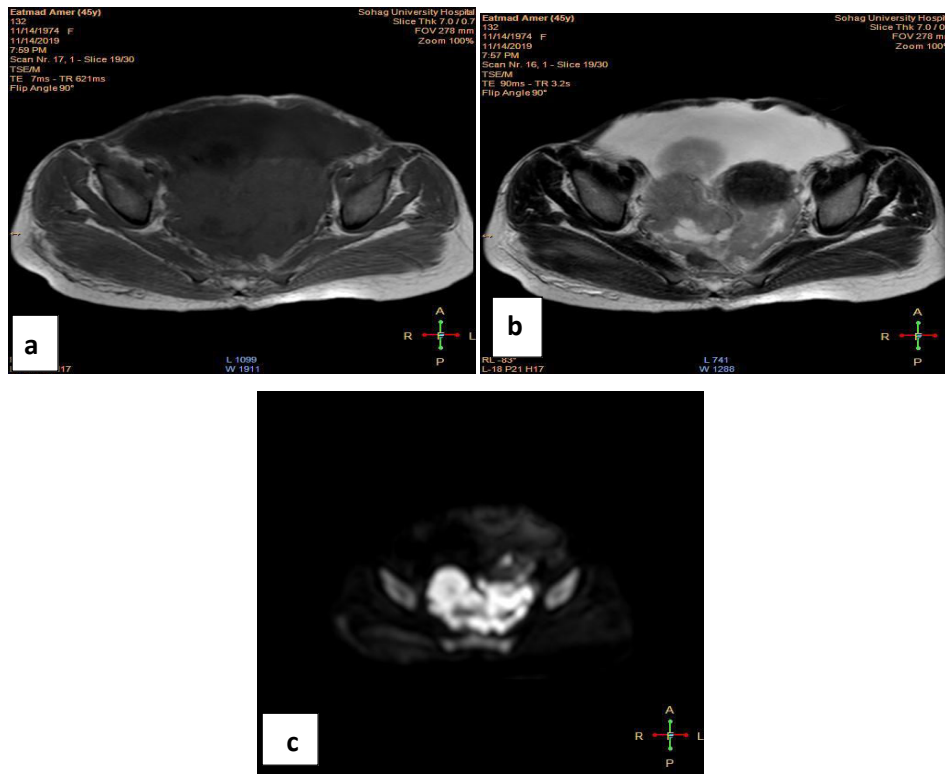


Fig. 6. 45-years-old patient, presented with an pelvi-abdominal mass (Bilateral mucinous epithelial cystadenocarcinoma). MR imaging revealed bilateral complex ovarian mass lesions (cystic and solid components), its cystic component displaying hypo intense signal at T1 (a), hyper intense signal at T2 (b), shows no restriction at DWI (c), the soft tissue component show hypo intense signal at T1 (a) intermediate signal at T2 (b), show restrictions at DWI (c).

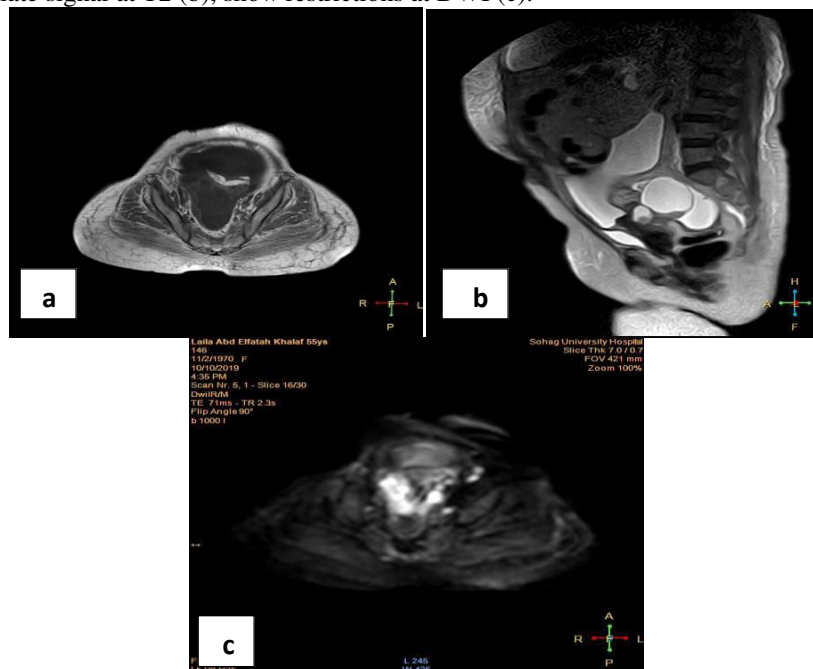

Fig. 7. 55-years-old patient, presented with an pelvi-abdominal mass (Right ovarian undifferentiated massively necrotizing epitheloid cell malignancy/high grade carcinoma). MR imaging revealed right ovarian complex cystic mass lesion measuring +/- 8x8x5 cm, it shows multiple thick septations and multiple vegetations, its cystic component displaying hypo intense signal at T1 (a) hyper intense signal at T2 (b), shows no restriction at DWI (c), the soft tissue internal vegetations are hypo intense at T1 (a), intermediate signal at T2 (b), shows restrictions at DWI (c).

The findings of (El-Sayed et al., 2019) study which included 25 patients with ovarian masses (18 benign and 7 malignant masses), agree with our finding in that the DWI enhance the ability of MRI in differentiation between benign and malignant ovarian masses, Restricted diffusion was noticed in proved malignant masses. Benign tumors with high DWI signal intensity evidence at 24% such as dermoid cyst and ovarian abscess.

Tantawy et al. (2018) according to their study which included 30 patient (17 benign ovarian mass and 13 malignant ovarian masses), all of the malignant masses solid component show restriction at DWI, and 7 ovarian abscess, 4 mature cystic teratoma, 2 ovarian torsion, and 1 case of endometrioma also show restriction at DWI.

We found that the mean ADC was $1.76 \times 10^3 \text{ mm}^2/\text{s}$ with a range from $0.5 \times 10^3 \text{ mm}^2/\text{s}$ to $3.3 \times 10^3 \text{ mm}^2/\text{s}$. Low ADC was found in nearly half of the cases (48.3%).

As regard ADC between benign and malignant cases, we found that the mean ADC was much higher among benign cases ($2.082 \times 10^3 \text{ mm}^2/\text{s}$) (Fig.

8) compared to malignant ones ($0.707 \times 10^3 \text{ mm}^2/\text{s}$) (Fig. 9), with a highly significant difference (P value <0.001 HS).

We found that the mean ADC was significantly higher among simple ovarian cyst, ovarian dermoid cyst, hemorrhagic cyst and endometrioma, compared to ovarian torsion, ovarian abscess and malignant ovarian mass, with a highly significant difference (P value <0.001 (HS).

Our findings show that the mean ADC values for benign and malignant lesions differ significantly, with values for benign masses ranging from $.6 \times 10^3 \text{ mm}^2/\text{s}$ to $3.3 \times 10^3 \text{ mm}^2/\text{s}$, whereas malignant masses ADC values ranged from $0.5 \times 10^3 \text{ mm}^2/\text{s}$ to $.9 \times 10^3 \text{ mm}^2/\text{s}$. Also, the mean ADC value of the solid areas can differs significantly between benign and malignant lesions (p value < 0.001) as it was $1.176 \times 10^{-3} \pm 0.15 \times 10^{-3} \text{ mm}^2/\text{s}$ for benign tumors, and $0.747 \times 10^{-3} \pm 0.12 \times 10^{-3} \text{ mm}^2/\text{s}$ for malignant tumors which also considered statistically significant. Some benign ovarian tumours, such as endometrioma, hemorrhagic ovarian cysts, and dermoid cysts, also have a low ADC value.

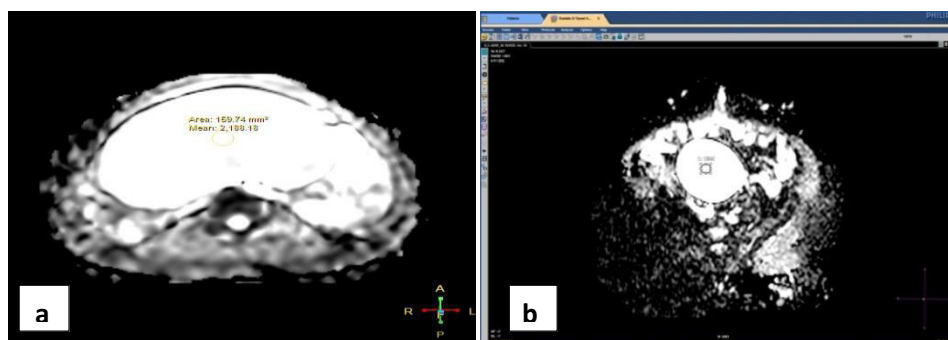


Fig. 8. (a) 20-years-old patient, presented with an pelvi-abdominal mass (Right ovarian serous cystadenoma) large well defined smooth thin wall right ovarian cyst, Showing few internal thin septations measuring +/- 20x18.5x8.5 cm. its ADC value is $(2.1 \times 10^{-3} \text{ mm}^2/\text{s})$.

(b) 62-years-old patient, presented with an pelvi-abdominal mass (Left ovarian serous cystadenoma). Large well defined smooth thin wall left ovarian cyst, measuring +/- 10.5x9.5x7.5 cm, its ADC value is $(1.8 \times 10^{-3} \text{ mm}^2/\text{s})$.

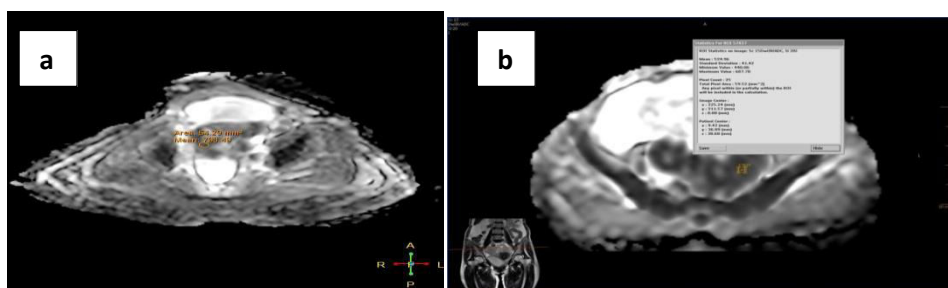


Fig. 9. (a) 55-years-old patient, presented with an pelvi-abdominal mass (Right ovarian undifferentiated massively necrotizing epitheloid cell malignancy/high grade carcinoma). MR imaging revealed right ovarian complex cystic mass lesion measuring +/- 8x8x5 cm, it shows multiple thick septations and multiple vegetations, the soft tissue internal vegetations ADC value is $(.7 \times 10^{-3} \text{ mm}^2/\text{s})$.

(b) 45-years-old patient, presented with an pelvi-abdominal mass (Bilateral mucinous epithelial cystadenocarcinoma). MR imaging revealed bilateral complex ovarian mass lesions (cystic and solid components), its cystic component ADC value is R $(2.1 \times 10^{-3} \text{ mm}^2/\text{s})$ and L $(1.9 \times 10^{-3} \text{ mm}^2/\text{s})$, the soft tissue component ADC value is $(.5 \times 10^{-3} \text{ mm}^2/\text{s})$ for both lesions.

The mean ADC value of malignant ovarian tumors was lower for the malignant ovarian tumors and higher for benign ovarian tumours in (El-Sayed et al, 2019) study. The mean ADC values for malignant tumors were $1.02 \pm 0.38 \times 10^{-3} \text{ mm}^2/\text{s}$,

whereas for benign lesions were $1.4 \pm 0.5 \times 10^{-3} \text{ mm}^2/\text{s}$.

Van Nimwegen et al. (2020) study covered 34 patients and found that mean ADC values for benign and malignant lesions differ significantly, with benign masses values ranging from 1.16 to $2.03 \times 10^{-3} \text{ mm}^2/\text{s}$, and for

malignant tumors values ranging from $0.76 \times 10^{-3} \text{ mm}^2/\text{s}$ to $1.39 \times 10^{-3} \text{ mm}^2/\text{s}$. As regard the cystic component of benign and malignant ovarian masses the ADC value not differs significantly. Also, in (Li et al., 2012) study of 127 patients with pelvic masses, (46 benign and 85 malignant), they observed that the mean ADC value of the cystic component was $2.58 \times 10^{-3} \pm 0.27 \times 10^{-3} \text{ mm}^2/\text{s}$ for benign tumors, and $2.44 \times 10^{-3} \pm 0.33 \times 10^{-3} \text{ mm}^2/\text{s}$ for malignant tumors which is statistically insignificant.

By ROC curve analysis for the possible role of ADC to predict malignant cases, we found that the ADC can differentiate malignant from benign cases, with a highly significant difference (P value <0.001). Using the coordinate points of the above ROC curve, the most suitable cut-off point is 0.895, with a sensitivity of 89.1% and a specificity of 92.9%.

Van Nimwegen et al.(2020) studied 34 patients and found that the ADC cut-off value $1.1 \times 10^{-3} \text{ mm}^2/\text{s}$ could distinguish between benign and malignant ovarian lesions.

Emad-Eldin et al. (2018) studied 59 patients with ovarian masses and found that ADC cutoff value $0.95 \times 10^{-3} \text{ mm}^2/\text{s}$ could distinguish between benign and

malignant lesions with sensitivity of 90.5% and specificity of 63.4%.

Conclusion and recommendation

- Because of its ability to characterize tissue, MRI is a suitable imaging technique for ovarian masses.
- Certain MRI features and the pattern of enhancement on MRI are helpful to distinguish between benign and malignant ovarian masses.
- A combination of DWI and ADC value with conventional MRI increases the accuracy of MRI to discriminate between benign and malignant lesions.
- To distinguish between benign and malignant ovarian tumors, our study recommends a cut-off value of $0.89 \times 10^{-3} \text{ mm}^2/\text{s}$.

References

- Bakir B, Bakan S, Tunaci M, Bakir VL, Iyibozkurt AC, Berkman S (2011). Diffusion-weighted imaging of solid or predominantly solid gynaecological adnexial masses: is it useful in the differential diagnosis?. The British journal of radiology, 84(1003): 600-611.
- Coats JS, Freeberg A, Pajela EG, Obenaus A, Ashwal S (2009). Meta-analysis of apparent diffusion coefficients in the newborn brain. Pediatric neurology, 41(4): 263-274.

- **El-Sayed ESM, Abdullah MS, Ali HG (2019).** The role of diffusion-weighted MRI on the differentiation of complex adnexal masses. *Menoufia Medical Journal*, 32(3): 881.
- **Emad-Eldin S, Grace MN, Wahba MH, Abdella RM (2018).** The diagnostic potential of diffusion weighted and dynamic contrast enhanced MR imaging in the characterization of complex ovarian lesions. *The Egyptian Journal of Radiology and Nuclear Medicine*, 49(3): 884-891.
- **Foti PV, Attinà G, Spadola S, Caltabiano R, Farina R, Palmucci S, et al. (2016).** MR imaging of ovarian masses: classification and differential diagnosis. *Insights into imaging*, 7(1), 21-41.
- **Imaoka I, Wada A, Kaji Y, Hayashi T, Hayashi M, Matsuo M, et al. (2006).** Developing an MR imaging strategy for diagnosis of ovarian masses. *Radiographics*, 26(5), 1431-1448.
- **Kyriazi S, Kaye SB, Desouza NM (2010).** Imaging ovarian cancer and peritoneal metastases—current and emerging techniques. *Nature reviews Clinical oncology*, 7(7): 381-393.
- **Li W, Chu C, Cui Y, Zhang P, Zhu M (2012).** Diffusion-weighted MRI: a useful technique to discriminate benign versus malignant ovarian surface epithelial tumors with solid and cystic components. *Abdominal Radiology*, 37(5): 897-903.
- **Mansour S, Wessam R, Raafat M (2015).** Diffusion-weighted magnetic resonance imaging in the assessment of ovarian masses with suspicious features: strengths and challenges. *The Egyptian Journal of Radiology and Nuclear Medicine*, 46(4): 1279-1289.
- **Mohaghegh P, Rockall AG (2012).** Imaging strategy for early ovarian cancer: characterization of adnexal masses with conventional and advanced imaging techniques. *Radiographics*, 32(6): 1751-1773.
- **Tamai K, Koyama T, Saga T, Morisawa N, Fujimoto K, Mikami Y, et al. (2008).** The utility of diffusion-weighted MR imaging for differentiating uterine sarcomas from benign leiomyomas. *European radiology*, 18(4), 723-730.
- **Tantawy MSI, Elrakhawy MM, El-Morsy A, Saleh GA (2018).** DWI in characterization of complex ovarian masses, would it help?. *The Egyptian Journal of Radiology and Nuclear Medicine*, 49(3): 878-883.
- **Thomassin-Naggara I, Toussaint I, Perrot N, Rouzier R, Cuenod CA,**

- Bazot M, et al. (2011).** Characterization of complex adnexal masses: value of adding perfusion-and diffusion-weighted MR imaging to conventional MR imaging. *Radiology*, 258(3), 793-803.
- **Van Nimwegen LW, Mavinkurve-Groothuis AM, de Krijger RR, Hulsker CC, Goverde AJ, Zsiros J, et al. (2020).** MR imaging in discriminating between benign and malignant paediatric ovarian masses: a systematic review. *European radiology*, 30(2), 1166-1181.
 - **Zhang P, Cui Y, Li W, Ren G, Chu C, Wu X (2012).** Diagnostic accuracy of diffusion-weighted imaging with conventional MR imaging for differentiating complex solid and cystic ovarian tumors at 1.5 T. *World Journal of Surgical Oncology*, 10(1): 1-8.