

SEXUAL DIMORPHISM OF THE PALATAL VAULT MORPHOMETRY AND RUGOSCOPY IN A SAMPLE OF EGYPTIAN CHILDREN POPULATION

Fatma M. Elgazzar^{a*}, Ahmed Ibrahim El Dosoky^b, Sara Abdel Aziz Gonna^c

^{a*} Forensic Medicine and Clinical Toxicology Department, Faculty of Medicine, Tanta University, ^b Pediatric Dentistry, Oral Health and Preventive Department, Faculty of Dentistry, Tanta University, ^c Pediatric Dentistry Department, Faculty of Dentistry, Tanta University, Tanta, Egypt

*Corresponding author: Fatma M. Elgazzar, Forensic Medicine and Clinical Toxicology Department – 6th floor – Faculty of Medicine – Tanta University – Medical Campus – El-Gaish Street – Tanta – El-Gharbia Govenorate – Egypt. Email: fatma.elgazar@med.tanta.edu.eg

Telephone number: 00201004568919

Submit Date 2020-12-16 20:01:26

Revise Date 2021-02-21 18:25:01

Accept Date 2021-02-28 17:50:37

ABSTRACT

Introduction: Sex determination of the juvenile skeleton before puberty time is a difficult task. **Objectives:** The objective of this study was to determine the accuracy of the hard palate measurements and the rugae patterns in determining the sex of the Egyptian children. **Patients and Methodology:** The study included 210 children of either sex aged 6-12 years old. Alginate impressions from the maxillary arches have been taken. We measured the hard palate length, width, and height by using a digital caliper. We also obtained palatal rugae patterns from the maxillary casts. The patterns included the rugae length, shape, direction, and unification. **Results:** The mean palatal length, width, and height were significantly higher in males than females ($p < 0.001$), and they displayed a significant-good power in predicting male sex (area under the curves (AUCs) were 0.85, 0.87, and 0.80 respectively). The median number of curved rugae was significantly lower in males ($p = 0.002$), while the straight shape rugae exhibited a significantly higher number in males than females ($p = 0.004$). Binary logistic regression revealed a model with excellent (AUC=0.968) power and overall accuracy of 91.43% for sex identification. **Conclusion:** These findings indicate that the hard palate dimensions and the rugae shape could be used as complementary tools to determine the sex of the Egyptian children.

Keywords: Sex determination; hard palate; rugae patterns; rugoscopy; children; Egypt

INTRODUCTION

Sex determination is a crucial preliminary step in the process of unknown body identification (Kandeel and habib, 2019). Sex identification is necessary for accurate age and stature assessment as well as in personal identification. However, certain circumstances like mutilated and putrefied bodies constitute a tremendous challenge in this context (Nagare et al., 2018).

There are various methods of sex determination. These include osteometry, odontometry, and DNA analysis. However, skeletal and dental metric studies are preferred for being accurate, simple, repeatable, and not costly (Oner et al., 2019).

The palatal vault is a crucial fragment of the human skull. The palatal processes of the maxilla form its anterior part, while the horizontal plates of palatine bones form the posterior part (Gujar and Oza, 2018). The

hard palate has the advantage of resisting severe damages to the skull like burns and explosions. So, it has a great value in cranial sexing (Kamath et al., 2016). Despite this, few studies have investigated the accuracy of the juvenile hard palate in sex determination (Mustafa et al., 2019).

The Palatal rugae are transverse mucosal elevations that lie in the anterior one-third of the palate behind the incisive papilla. They spread unevenly on the two sides of the midpalatal raphe. These unique structures develop during the third month of intrauterine life (Kesri et al., 2014). Rugae characters as their number, length, direction, and shape have helped in the personal identification of fresh cadavers as well as charred and amputated bodies (Syed et al., 2016). However, their role in sex identification is still inconclusive (Andrade et al., 2019).

Sexual dimorphism of the morphological and metric traits of the juvenile skeleton starts from the moment of birth, but it becomes more pronounced at puberty time. Furthermore, the accuracy of sexual dimorphism from morphometric studies differs according to the studied population (Elgazzar et al., 2016; Oikonomopoulou et al., 2017). Hence, the sex determination of young individuals needs population-specific studies (Przystańska et al., 2020).

Therefore, the objective of this work was to determine the accuracy of the palatal vault measurements as well as the palatal rugae patterns in the sex determination of Egyptian children. Further, to develop a population-specific model for sex identification.

MATERIAL & METHODS

The present cross-sectional study included a random sample of pediatric patients. They were recruited from the outpatient clinic of Pedodontics Departments, Faculty of Dentistry, Tanta University after approval from the local

research ethics committee. The study followed the Ethics Code of the World Medical Association (Declaration of Helsinki). Before inclusion, written informed consent was taken from the guardians of the children. Confidentiality of personal and clinical data was maintained by making a code number for each participant.

We recruited children of either sex aged 6-12 years old with a healthy state of the periodontium. However, children who had congenital anomalies, a history of previous orthodontic treatment, skeletal or soft tissue swelling, active lesions, scars, or deformity were excluded.

The study included 210 subjects. We calculated the sample size with the G Power software program version 3.1. assuming a Cohen effect size of 0.5, an alpha error of 5.0%, a target power of 95%, and allocation ratio =1.

For each participant, alginate impressions from maxillary arches were taken in proper perforated trays and immediately poured with dental plaster stone to maintain accurate dimensions. We allowed the casts to dry for one hour on a table. The presence of air bubbles or cavities dictated remaking the impressions. We numbered the casts to allow their easy recognition (Ashley et al., 2005).

The following measurements in millimeter (mm) were obtained from the maxillary casts using a digital caliper which has an accuracy of 0.01 m.

Hard Palate Measurements (Mustafa et al., 2019).

Palatal length: It indicates the distance between the orale, which is the point at the frontal end of the incisive suture situated between the sockets of the two medial upper incisors, to the middle point of the linear distance between the mesial surfaces of the upper permanent first molar (Fig. 1).

Palatal Width: It is the distance between the internal borders of the upper permanent

first molars' sockets (Fig. 2)

Palatal Height: It is the distance of the maximum arching of the palate from the line joining the two upper permanent first molar, and the uppermost point of the palatine arch.

Palatal rugae patterns (Azab et al., 2016).

We also obtained palatal rugae patterns from the maxillary casts. After demarcation of the rugae by means of a graphite pencil under a suitable light, they were analyzed macroscopically after magnification with a hand lens. The palatal rugoscopy was analyzed as stated by **Kapali et al. (1997)**, and it included the rugae length, shape, direction, and unification (Fig.3).

Rugae Length: We measured it directly from the cast, from the origin near the mid-palatine raphe to the terminal end transversely. Three categories were recognized: primary, secondary, and fragmentary rugae having more than 5, 3–5, and less than 3 mm, respectively. Fragmentary ones were omitted in our study.

Rugae Shapes: There were four major types: Straight shape that had a direct course from their origin till the termination, curved rugae that had a crescent shape, wavy rugae that had a slight curve at the start or the end of the curved rugae, and circular rugae that form a definite continuous ring.

The direction of Rugae: It was determined by measuring the angle formed by two lines; the line joining the rugae origin to its termination and the perpendicular line to the median raphe. We identified three categories: Forwardly directed rugae that were associated with positive angles, backwardly directed rugae that were associated with negative angles, and the perpendicular rugae that were associated with angles of zero degrees.

Unification: this describes the joining of two rugae either at their origin or termination. It includes a diverging type that identifies any two rugae having the same origin from the

midline, but they immediately branched. Alternatively, the converging type describes rugae having different origins from the midline, but they further joined on their lateral portions.

Hard palate measurements and rugae patterns were made twice in a random sample of thirty casts at an interval of 10 days by the same observer to calculate intra-observer consistency. Additionally, to assess the inter-observer reliability, another examiner repeated the examination of the thirty casts.

Statistical Analysis

We tabulated and analyzed the data using SPSS (Statistical Package for the Social Sciences), version 22.0. Continuous data were tested for normality with the Shapiro-Wilk test. The normally distributed data were presented as mean \pm standard deviation and were compared with the independent-samples T-test, while the non-normal distributed data were presented as median and interquartile range and were analyzed with the Mann-Whitney U test. Additionally, the receiver operating characteristics (ROC) curve analysis was performed to demonstrate the performance of the studied measurements in predicting male sex. Finally, a stepwise multivariable binary logistic regression analysis was performed to determine a prediction model for the male sex. Intra rater and inter-rater reliability were assessed by intraclass correlation and percent agreement method. The level of statistical significance was set at $P < 0.05$.

RESULTS

Both Intra rater and inter-rater reliability were excellent (correlation coefficients were 0.96 and 0.93 respectively, $p < 0.001$). Additionally, intra rater and inter-rater agreement was 96.7% and 93.4%. Both sexes were equally distributed (105 each), with the absence of significant differences in the mean age of males and females (9.4 ± 0.6 and 9.7 ± 0.6 respectively, $p > 0.05$).

Hard Palate Measurements

The palatal length, width, and height showed significantly higher means in males than females ($p < 0.001$) (Table 1). Additionally, the three palatal dimensions displayed a significant-good power in predicting male sex (AUCs were 0.85, 0.87, and 0.80, respectively). The width of the palatal arch revealed the highest accuracy (80.50%), whereas the length explored the highest specificity (98.10%) and PPV (96.72%), as shown in Table 2 and Fig. 4.

Palatal Rugae patterns

Table 3 shows the rugae pattern and its relation to sex. In both males and females, wavy rugae represented the most frequent shape, followed by curved, straight, and circular ones. Further, the median number of curved rugae was significantly lower in males than females (3.0 versus 4.0, $p = 0.002$), while the straight shape was more significantly higher in males ($p = 0.004$). The forward direction was more predominant than the backward and perpendicular ones in both males and females, with no significant differences ($p > 0.05$). The distribution of rugae unification was homogenous between convergence and divergence with no significant differences between males and females ($p > 0.05$). Concerning rugae length, the primary type was more frequent than the secondary category, and the comparison of the rugae length between both sexes showed no significant differences ($p > 0.05$).

Table 4 and Fig. 5 illustrate a significant poor power of discrimination for both curved and straight rugae ($p < 0.05$). The number of curved palatal rugae at a cut off of 2 or less significantly discriminated male sex with an accuracy of 62.0% and poor AUC of 62.0.

A stepwise multivariable binary logistic regression analysis selected only the variables that significantly contribute to the diagnostic power of the prediction model. The model consisting of the palatal length, width, and height, as well as the number of

curved rugae. The model significantly predicted male sex ($X^2 = 196.98$, $p < 0.001$) and explained 81.15% (R^2) of variance in sex. The model showed excellent power in discriminating male sex (AUC=0.968), with an overall accuracy of 91.43%. The palatal width (odds ratio =2.77) displayed the greatest contribution in this model (Table 5).

DISCUSSION

The present study investigated the accuracy of the hard palate morphometry and rugoscopy for establishing the sex of Egyptian children aged 6-12 years. Dimensions of the hard palate represented by length, width, and height were significantly valid in discriminating sex, with the highest accuracy (80.50%) for the palatal width. The shape of the rugae was the only trait that showed a significant sexual dimorphism. However, its diagnostic accuracy was poor. Furthermore, the combined use of these sexually dimorphic features in a stepwise regression analysis revealed a model with excellent diagnostic power (AUC=0.968) in discriminating male sex, with an overall accuracy of 91.43%.

Hard Palate Measurements

In the process of human identification, analysis of bones of the cranium provides a useful tool for sex diagnosis. The hard palate is an essential sex indicator in certain circumstances where the only accessible evidence for establishing sex is only bony fragments (Mustafa et al., 2019).

The mean values of length and width of the hard palate in the studied Egyptian children were comparable to those reported in Jordanian children of the same age group. Alternatively, the mean palatal height in our study was higher (12.22 ± 1.96 mm for males and 11.77 ± 1.65 mm for females) than was found in Jordanian children (Mustafa et al., 2019).

The present study detected sexual

dimorphism of the palatal length, width, and height, with significantly higher means in males than females. These findings are in line with **Mustafa et al. (2019)** who reported significantly greater means of the palatal length and width in Jordanian boys than girls. Likewise, an earlier study involved 150 Taiwanese children aged 4-5 years revealed larger palatal dimensions in boys (**Tsai and Tan, 2004**). Thus, it seems that the palatal size shows sexual dimorphism from early childhood and not dependent on puberty.

The studied palatal dimensions were significantly valid in discriminating male sex where they displayed good power of discrimination (AUCs were 0.85, 0.87, and 0.80, respectively). The palatal width exhibited the highest accuracy (80.50%) and the best balance between sensitivity and specificity. These results favor palatal width as a tool for sex prediction. Alternatively, the length and height showed a lower accuracy of 78.50% and 77.0%, respectively. Therefore, the palatal dimensions can supplement other pieces of evidence for more accurate sex determination.

Comparable results have been reported for the palatal dimensions directly obtained from the adult dry skulls. A recent study of the palatal length and width in 43 skulls in France revealed sexual dimorphism with an overall precision of 84.0% (**Escalante-Flórez et al., 2020**). Additionally, **Alves et al. (2019)** have highlighted sexual dimorphism of 5 hard palate measurements with greater values in males than females, but they have reported a lower diagnostic performance with an accuracy ranged approximately from 54% to 67%. Another study in India has identified palatal length from the incisive foramen to posterior nasal spine as a definite sex marker with an accuracy of 87.2% (**Kamath et al., 2016**).

In agreement with our findings, **Manjunath et al. (2014)** have concluded that palatal breadth showed better performance in

predicting Indian males while the palatal length was a better predictor for Indian females. Furthermore, an earlier Greek study using three-dimensional geometric morphometry of dry skulls detected a significantly deeper and more elongated palate in males. They also reported that palatal size and shape correctly classified sex with an accuracy of 74.8% (**Chovalopoulou et al., 2013**). Thus, it seems that dental casts reflect well the anatomical features of the palate as exactly as the directly obtained metrics from the dry skulls. This observation has been previously shown by (**Mustafa et al. (2019)**).

Palatal Rugae patterns

The pattern of palatal rugae has shown racial differences (**Azab et al., 2016**). There is an observed lack of data about rugae traits in Egyptian children and their possible role in sex identification in this particular age group.

The study of palatal rugae for purposes of human identification is essential if alternative methods are not available or difficult. Because of their fibrous origin, rugae can remain intact and resist postmortem changes for up to one week after death. Furthermore, their internal location inside the oral cavity enables them to withstand conditions of trauma and burns (**Fatima and Fida, 2019**).

The palatal rugae show consistency in their number, length, shape, direction, and unification throughout life except for the change of the length due to their normal growth (**Poojya et al., 2015**).

There are numerous ways to analyze the palatal rugae patterns. However, oral impressions have been commonly used because of their reported accuracy besides their simplicity, reliability, and low cost (**Poojya et al., 2015**).

Analysis of the maxillary arch casts of the studied children revealed a characteristic rugae pattern. Wavy rugae represented the most frequent shape, followed by curved,

straight, and circular ones. The forward direction was more predominant than the backward and perpendicular ones, whereas the distribution of rugae unification was homogenous between convergence and divergence. Concerning rugae length, the primary type was more frequent than the secondary category. Similarly, various studies from different populations reported wavy rugae as the most prevalent shape followed by either curved or straight configurations (**Rath and Reginald, 2014; Dwivedi and Nagarajappa, 2016; Selvamani et al., 2019**).

One of the objectives of this study was to show sexual dimorphism of the rugae pattern in the children to develop an alternative or supplementary method for sex identification. Metric analysis of the rugae pattern in this study revealed sexual dimorphism only in the shape trait. The studied males displayed a significantly higher median number of the straight shape and a lower median number of the curved shape. However, the diagnostic accuracy of the rugae shape was poor; it ranged from 58.50% for the straight shape to 62.0% for the curved ones.

A study of the palatal rugae in Egyptian adults showed similar findings, with a significantly higher number of curved rugae in females than males. Otherwise, different rugae characters showed an absence of significant differences between males and females (**Azab et al., 2016**). A recent study that included Egyptian adults revealed sexual dimorphism in the rugae shape as well as the total and primary rugae numbers (**Elrewieny et al., 2020**). Alternatively, an earlier study of palatal morphology of the Egyptian children aged 6-8 years showed no significant sex-related differences (**Abdellatif et al., 2011**).

In comparison with other populations, our findings agree with **Pakshir et al. (2019)**, who described a significant sexual dimorphism only in the number of curved

rugae in Iranian children aged 6-12 years, with a sex differentiation accuracy of 60.8%. Turkish population have also shown sexual dimorphism in the rugae shape only (**Buyuk et al., 2019**).

Furthermore, both rugae shape and length showed 78.0% accuracy in establishing the sex of the Andhra population (**Bharath et al., 2011**). On the other hand, **Gadicherla et al. (2017)** have reported a significant difference in the unification pattern of Bengaluru children aged 4-16 years, which enabled sex diagnosis with 80% accuracy. A study of the Navi Mumbai population has identified high (90.0%) accuracy for the various rugae traits (**Pereira et al., 2018**). Further sexual dimorphism of the curved and wavy rugae, in addition to the number of primary rugae (5-10 mm), with higher values in males were reported in Bhopal, Ranchi, and Patna regions of India (**Jain and Jain, 2015; Chandra et al., 2016**) and Saudi subjects (**Fawzi et al., 2016**).

On the other hand, all palatal rugae traits did not show significant sexual dimorphism in some adult Indian populations (**Sharma et al., 2009; Nagalaxmi et al., 2015**). A recent study in Brazil has also revealed similar computed images of the area and density of the palatal rugae of both sexes (**Rosa et al., 2020**).

The racial differences, the possible influence of the examiner's subjectivity in evaluating some rugae traits, and the variations in sample size and statistical methods among different studies might explain the observed conflicting results regarding sex differences and the accuracy of sex prediction by using palatal morphometry and rugoscopy (**Hunnargi et al., 2009**).

There are different levels of sexual expression in the sexually dimorphic traits of the human body. Therefore, forensic experts

usually combine two or more sex indicators to obtain a conclusive biological sex determination (Best et al., 2018).

In this regard, the present study revealed a model consisting of palatal length, width, and height, and the number of curved rugae. The model showed excellent (AUC=0.968) power in discriminating male sex, and its accuracy in classifying sex was 91.43%.

The addition of rugae traits, when circumstances allow, seems to produce compelling evidence for sex determination, thereby narrowing down the outcome of forensic investigations.

We thought that this study filled a gap in the context of sex determination of Egyptian children. The random allocation of the participants favors the validity of our results. However, recruiting the participants from a single governorate is considered a limitation that should be further considered.

CONCLUSION & RECOMMENDATION

Evaluation of the palatal vault dimensions and rugae characters could be used as complementary tools to determine the sex of Egyptian children aged 6-12 years. However, to validate our findings, further studies involving a larger sample size from different Governorates of Egypt are needed.

REFERENCES

Abdellatif, A.M.; Awad, S. and Hammad, S. (2011):Comparative study of palatal rugae shape in two samples of egyptian and saudi children. *Pediatric dental journal*,21:123-128.

Alves, N.; Deana, N.F.; Ceballos, F.; Hernandez, P. and Gonzalez, J. (2019):Sex prediction by metric and non-metric analysis of the hard palate and the pyriform aperture. *Folia Morphol (Warsz)*,78:137-144.

Andrade, R.N.M.; Vieira, W.A.; Bernardino, M.Í.; Franco, A. and

Paranhos, L.R. (2019):Reliability of palatal rugoscopy for sexual dimorphism in forensic dentistry: A systematic literature review and meta-analysis. *Arch Oral Biol*,97: 25-34.

Ashley, M.; Mccullagh, A. and SWEET, C. J. D. U. (2005): Making a good impression:(how to'paper on dental alginate). *Dental update*, 32: 169-70.

Azab, S.M.S.; Magdy, R. and Sharaf El Deen, M.A. (2016):Patterns of palatal rugae in the adult egyptian population. *Egyptian Journal of Forensic Sciences*,6: 78-83.

Best, K.C.; Garvin, H.M. and Cabo, L.L. (2018):An investigation into the relationship between human cranial and pelvic sexual dimorphism. *J Forensic Sci*,63: 990-1000.

Bharath, S.T.; Kumar, G.R.; Dhanapal, R. and Saraswathi, T. (2011):Sex determination by discriminant function analysis of palatal rugae from a population of coastal andhra. *J Forensic Dent Sci*,3: 58-62.

Buyuk, S.K.; Simsek, H.; Yasa, Y.; Genc, E. and Turken, R. (2019):Morphological assessment of palatal rugae pattern in a turkish subpopulation. *Australian Journal of Forensic Sciences*,51:40-48.

Chandra, S.; Pandey, V.; Wasti, A.; Mangat, S.S.; K. Bhagat, J.;Singh; et al. (2016):Analysis of rugae pattern in ranchi and patna population. *Journal of International Oral Health*,8:362-366.

Chovalopoulou, M.E.; Valakos, E.D. and Manolis, S.K. (2013):Sex determination by three-dimensional geometric morphometrics of the palate and cranial base. *Anthropol Anz*,70: 407-425.

Dwivedi, N. and Nagarajappa, A. K. (2016):Morphological analysis of palatal rugae pattern in central indian population. *J Int Soc Prev Community Dent*,6:417-422.

- Elgazzar, F., El-Sernagawy, G. and El-Gendy, A. (2016):** Sexual dimorphism of mandible in egyptian population sample: a panoramic radiographic study, *The Egyptian Journal of Forensic Sciences and Applied Toxicology*, 16: 127-137.
- Elrewny, N.M.; Ismail, M.M.E.; Zaghloul, H.S.; Abielhassan, M.H. and Ali, M.M. (2020):** Palatoscopy and odontometrics' potential role in sex determination among an adult egyptian population sample: A pilot study. *Homo*, 71: 19-28.
- Escalante-Flórez, K.J.; Suárez-Ponce, D.G. and Velezmoro-Montes, W. (2020):** Sexual dimorphism via palatal vault morphometric analysis on a sample peruvian population. *Odovtos-International Journal of Dental Sciences*, 22: 217-225.
- Fatima, F. and Fida, M. (2019):** The association between morphological characteristics of palatal rugae and sagittal skeletal patterns. *J Pak Med Assoc*, 69: 939-945.
- Fawzi, M.; Eldomyaty, M.; Desouky, M. and Algaidi, S. (2016):** Evaluation of the role of palatal rugae application as a tool for sex identification in the saudi population. *WIMJ Open*, 3: 28-31.
- Gadicherla, P.; Saini, D. and Bhaskar, M. (2017):** Palatal rugae pattern: An aid for sex identification. *J Forensic Dent Sci*, 9: 48-53.
- Gujar, S.M. and Oza, S.G. (2018):** Morphometric analysis of hard palate and its clinical importance. *National Journal of Clinical Anatomy*, 7: 036-040.
- Hunnargi, S.A.; Menezes, R.G.; Kanchan, T.; Lobo, S.W.; Uysal, S.; Herekar, N.G.; et al. (2009):** Sternal index: Is it a reliable indicator of sex in the maharashtrian population of india? *J Forensic Leg Med*, 16: 56-58.
- Jain, S. and Jain, A. (2015):** Rugoscopy as an adjunct to sex differentiation in forensic odontology. *Journal Of Applied Dental and Medical Sciences*, 1: 1-6.
- Kamath, V.; Asif, M.; Shetty, R. and Avadhani, R. (2016):** Binary logistic regression analysis of hard palate dimensions for sexing human crania. *Anat Cell Biol*, 49: 151-159.
- Kandeel, F. and Habib, R. (2019):** SEX ESTIMATION FROM TRANSVERSE BREADTH OF TALUS BONE IN EGYPTIAN POPULATION. *The Egyptian Journal of Forensic Sciences and Applied Toxicology*, 19: 65-76.
- Kapali, S.; Townsend, G.; Richards, L. and Parish, T.J. (1997):** Palatal rugae patterns in australian aborigines and caucasians. 42: 129-133.
- Kesri, R.; Das, G.; Tote, J. and Thakur, P. (2014):** Rugoscopy-science of palatal rugae: A. *Int J Dent Med Res*, 1: 103-107.
- Manjunath, T.; Kuppast, N.C.; Umesh, S. and Iddalgave, S. (2014):** Identification of gender from dimensions of palate. *Medico-Legal Update*, 14: 132-134.
- Mustafa A.G.; Tashtoush, A.A.; Alshboul, O.A.; Allouh, M.Z. and Altarifi, A.A. (2019):** Morphometric study of the hard palate and its relevance to dental and forensic sciences. *International journal of dentistry*, 1687345.
- Nagalaxmi, V.; Ugrappa, S.; Ch, N.J.M.; L.; Maloth, K.N. and Kodangal, S. (2015):** Cheiloscopy, palatoscopy and odontometrics in sex prediction and discrimination - a comparative study. *The open dentistry journal*, 8: 269-279.
- Nagare, S.P.; Chaudhari, R.S.; Birangane, R.S. and Parkarwar, P.C. (2018):** Sex determination in forensic identification, a review. *Journal of forensic dental sciences*, 10: 61-66.
- Oikonomopoulou, E.K.; Valakos, E. and**

- Nikita, E. (2017):**Population-specificity of sexual dimorphism in cranial and pelvic traits: Evaluation of existing and proposal of new functions for sex assessment in a greek assemblage. *Int J Legal Med*,131: 1731-1738.
- Oner, Z.; Oner, S.; Kurtul, I. and Sahin, B. (2019):**Usage length of sternum components and sternal angle through images obtained by computerized tomography image reconstruction in gender determination. *Annals of Medical Research*,26:217-221
- Pakshir, F.; Ajami, S.; Pakshir, H.R. and Malekzadeh, A.R. (2019):**Characteristics of palatal rugae patterns as a potential tool for sex discrimination in a sample of iranian children. *Journal of dentistry (Shiraz, Iran)*,20:1-9.
- Pereira, T.; Shetty, S.; Surve, R.; Gotmare, S.; Kamath, P. and Kumar, S. (2018):**Palatoscopy and odontometrics for sex identification and hereditary pattern analysis in a navi mumbai population: A cross-sectional study. *Journal of oral and maxillofacial pathology. JOMFP*,22: 271-278.
- Poojya, R.; Shruthi, C.S.; Rajashekar, V.M. and Kaimal, A. (2015):**Palatal rugae patterns in edentulous cases, are they a reliable forensic marker? *Int J Biomed Sci*,11: 109-112.
- Przystańska, A.; Rewekant, A.; Sroka, A.; Gedrange, T.; Ekkert, M.; Jończyk-Potoczna, K. ; et al. (2020):**Sexual dimorphism of maxillary sinuses in children and adolescents - a retrospective CT study. *Ann Anat*,229: 1-6.
- Rath, R. and Reginald, B.A. (2014):**Palatal rugae: An effective marker in population differentiation. *J Forensic Dent Sci*,6: 46-50.
- Rosa, G.A.A.; De Araújo, M.F.; Aguiar, L.S.; Beghini, M.; Juliano, G.R.; Da Fonseca, M. L.; et al. (2020):**Computerized morphometry of the area of the hard palate and of palatal rugae: A cross-sectional study. *Medicina Legal de Costa Rica*,37:154-161.
- Selvamani, M.; Bindiya, P.K.; Bhojaraju, N.; Bastian, T.S.; Suhana, H.S. and Mathew, M. (2019):**Morphological analysis of various rugae patterns among dravidian population. *Journal of oral and maxillofacial pathology. JOMFP*,23:295-299.
- Sharma, P.; Saxena, S. and Rathod, V. (2009):**Comparative reliability of cheiloscopy and palatoscopy in human identification. *Indian J Dent Res*,20: 453-457.
- Syed, S.; Alshahrani, I.; Alshahrani, A.; Togoo, R.A.; Luqman, M. and Dawasaz, A. A. (2016):**Conversion of palatal rugae pattern to scanable quick response code in an arabian population. *Journal of dental sciences*,11:253-260.
- Tsai, H.H. and Tan, C.T. (2004):**Morphology of the palatal vault of primary dentition in transverse view. *Angle Orthod*,74:774-779.

LEGENDS OF TABLES AND FIGURES**TABLE (1):** Comparison between the studied males and females as regards the studied palatal dimensions (N=210).

	Groups		Independent T-test	
	Males N=105	Females N=105	t	P value
Palatal length (mm)	37.02±4.44	31.62±2.07	11.30	<0.001*
Palatal width(mm)	38.67±2.14	35.15±2.48	11.03	<0.001*
Palatal height(mm)	24.65±2.05	22.07±1.93	9.39	<0.001*

*Significant at p <0.05, values are expressed as mean± SD

TABLE (2): Receiver operating characteristics curve analysis for predicting male sex by the studied palatal dimensions.

	Cut off	Sensitivity %	Specificity %	PPV %	NPV %	AUC	95% CI	Accuracy %	P value
Palatal length(mm)	>35.76	59.05	98.10	96.72	70.50	0.85	0.792 to 0.894	78.50	<0.001*
Palatal width(mm)	>36.9	82.86	78.10	79.05	82.11	0.87	0.812 to 0.909	80.50	<0.001*
Palatal height(mm)	>23.96	61.90	92.38	88.57	70.77	0.80	0.744 to 0.855	77.0	<0.001*

Pairwise comparison of AUCs of the palatal length, width, and height revealed nonsignificant differences (p>0.05)

*Significant at p <0.05, AUC: area under the curve, PPV: positive predictive value, NPV: negative predictive value, CI: confidence interval

TABLE (3): The sex-related differences of the studied palatal rugae characters (N=210)

			Groups		Test statistic	P value
			Males N=105	Females N=105		
Shape	Wavy	Range	0.0-6.0	0.0-8.0	0.775	0.439
		Median	4.0	4.0		
	Curved	Range	0.0-8.0	0.0-7.0	3.13	0.002*
		Median	3.0	4.0		
	Straight	Range	0.0-7.0	0.0-4.0	2.89	0.004*
		Median	1.0	1.0		
Circular	Range	0.0-2.0	0.0-2.0	1.83	0.066	
	Median	0.0	0.0			
Direction	Forward	Range	0.0-8.0	0.0-10.0	1.40	0.161
		Median	5.0	4.0		
	Backward	Range	0.0-7.0	0.0-8.0	1.55	0.1201
		Median	3.0	3.0		
	Perpendicular	Range	0.0-6.0	0.0-3.0	0.322	0.748
		Median	1.0	1.0		
Unification	Convergence	Range	1.0-8.0	1.0-7.0	0.141	0.888
		Median	4.0	4.0		
	Divergence	Range	1.0-8.0	1.0-8.0	0.171	0.864
		Median	5.0	4.0		
Length (mm)	Primary	Range	3.0-10.0	3.0-10.0	0.934	0.350

	Secondary	Median	7.0	6.0	1.41	0.157
		Range	0.0-4.0	0.0-4.0		
	Total number	Median	2.0	2.0	0.572	0.568
		Range	7.0-11.0	5.0-12.0		
		Mean± SD	8.4±0.9	8.5±1.2		

*Significant at p <0.05

TABLE (4): Receiver operating characteristics curve analysis for male sex discrimination by the number of curved and straight rugae.

	Cut off	Sensitivity %	Specificity %	PPV %	NPV %	AUC	95% CI	Accuracy %	P value
Curved rugae	≤2	44.76	79.05	68.18	58.96	0.62	0.55 to 0.69	62.0	0.001*
Straight rugae	>1	39.05	78.10	63.93	56.12	0.61	0.54 to 0.68	58.50	0.003*

Pairwise comparison of AUCs of palatal length, width, and height revealed nonsignificant differences (p>0.05)

*Significant at p <0.05, AUC: area under the curve, PPV: positive predictive value, NPV: negative predictive value, CI: confidence interval

TABLE (5): Stepwise multivariable binary logistic regression analysis for prediction of the male sex from palatal dimensions and rugae shape.

variables	Coefficient	Odds ratio	95% CI of odds	P value	Accuracy %	R² %	X²	P value	AUC	95%CI of AUC
Palatal length (mm)	0.36	1.44	1.21-1.70	<0.001*	91.43	81.15	196.98	<0.001*	0.968	0.9385 to 0.987
Palatal width (mm)	1.02	2.77	1.93-4.0	<0.001*						
Palatal height (mm)	0.77	2.16	1.54-2.99	<0.001*						
Number of curved rugae	-0.57	0.56	0.40-0.80	0.001*						

*Significant at p <0.05, AUC: area under the curve, CI: confidence interval



FIGURE (1): Measurement of palatal length (mm) by using a digital caliper.



FIGURE (2): Measurement of palatal width (mm) by using a digital caliper.

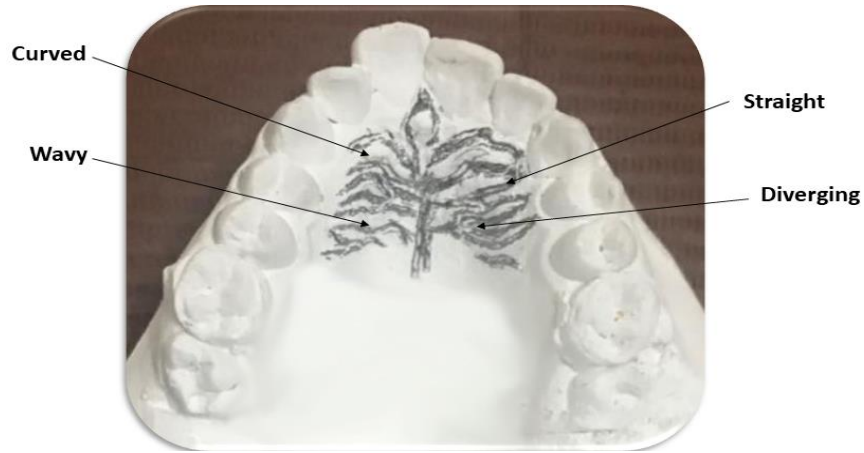

FIGURE (3): Pattern of palatal rugae as marked on maxillary cast.

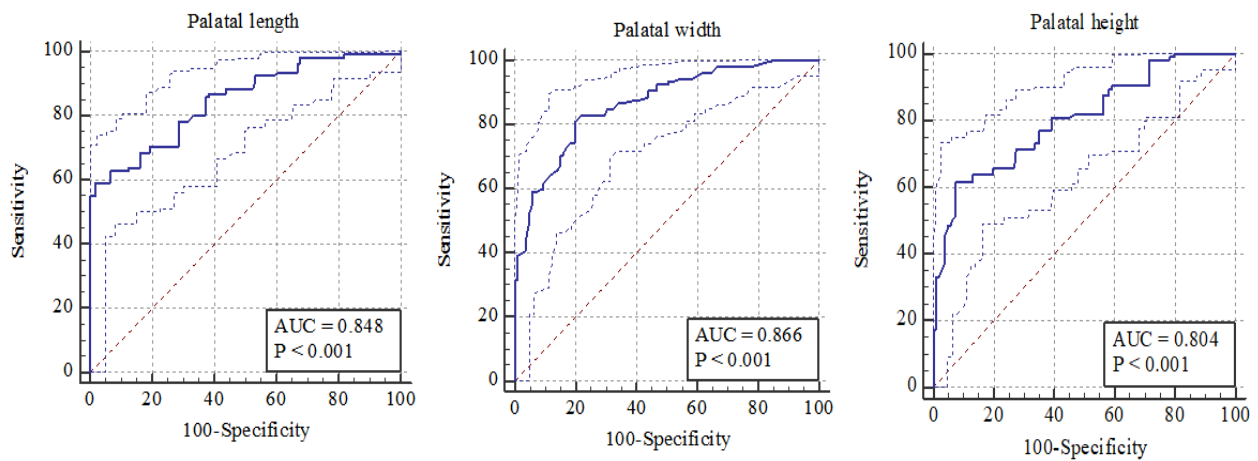


FIGURE (4): Receiver operating characteristics (ROC) curve analysis for predicting male sex by palatal dimensions.

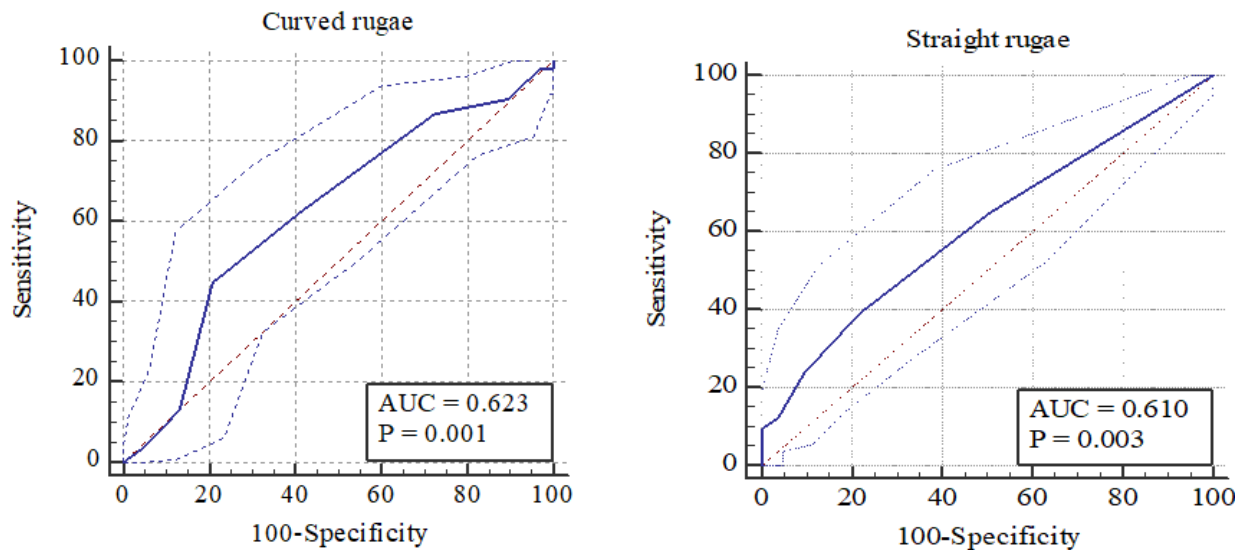


FIGURE (5): Receiver operating characteristics (ROC) curve analysis for predicting male sex by curved and straight rugae.

الملخص العربي

إزدواج الشكل الجنسي لقياسات ونمط القبو الحنكي في عينة من الأطفال المصريين

د. فاطمة محمد الجزار*، د. أحمد إبراهيم الدسوقي#، د. سارة عبدالعزيز جونه##
 * قسم الطب الشرعي والسموم الإكلينيكية، كلية الطب، جامعة طنطا، مصر
 # قسم طب أسنان الأطفال وصحة الفم والوقاية، كلية طب الأسنان، جامعة طنطا، مصر
 ## قسم طب أسنان الأطفال، كلية طب الأسنان، جامعة طنطا، مصر

المقدمة: يعد تحديد جنس الهيكل العظمي قبل سن البلوغ مهمة صعبة. الهدف من الدراسة: هدفت هذه الدراسة إلى تحديد دقة قياسات وأنماط الحنك الصلب في تحديد جنس الأطفال المصريين. **المرضى وطرق البحث:** إشمطت الدراسة علي ٢١٠ طفل من كلا الجنسين تتراوح أعمارهم بين ٦-١٢ سنة، تم أخذ طبقات من الفك العلوي، تم قياس الطول والعرض والارتفاع للحنك الصلب وكذلك عدد، شكل، إتجاه، وتوحيد الركائز الحنكية باستخدام الفرجار الرقمي. **النتائج:** كان متوسط الطول والعرض والارتفاع في الحنك أعلى بدلالة إحصائية في الذكور عن الإناث ($p < 0.001$) وقد أظهروا جميعاً قوة جيدة في التنبؤ بجنس الذكور (كانت المنطقة الواقعة تحت منحنيات روك (0.85 و 0.87 و 0.80 علي التوالي). كان الوسيط لعدد الركائز المنحنية أقل، بينما أظهرت الأشكال المستقيمة عدداً أعلى في الذكور من الإناث بفرق ذو دلالة إحصائية ($p < 0.05$)، وكشف الانحدار اللوجستي الثنائي عن نموذج ذو قوة ممتازة ($AUC = 0.968$) ودقة كلية ٩١,٤٣٪ لتحديد الجنس. **الخلاصة:** يمكن أن نخلص إلي أنه يمكن استخدام أبعاد الحنك الصلب بالإضافة إلى شكل الركائز الحنكية كأدوات مكملة لتحديد جنس الأطفال المصريين.