



## The Effect of Xylitol on Osteoclastogenesis in Experimentally Induced Bone Defect in Rabbits

Ahmed, H. Naji<sup>1\*</sup>; Ghada, A. Taqa<sup>2</sup> and Wael, T. Al-Watter<sup>3</sup>

<sup>1</sup>Ministry Of Health, Nineveh Health Directorate, Diyala, Iraq.

<sup>2</sup>Department of Dental Basic Sciences, College of Dentistry, University of Mosul, Mosul, Iraq.

<sup>3</sup>Department of Oral and Maxillofacial Surgery, College of Dentistry, University of Mosul, Mosul, Iraq.

\*Corresponding Author: Ahmed, H. Naji, E-Mail: [ahmed.hatif.1990@gmail.com](mailto:ahmed.hatif.1990@gmail.com)

### ABSTRACT

This study aimed to investigate the effect of topical and systemic xylitol on osteoblast and osteoclast in the femoral bone of rabbits. Twenty-four healthy white male New Zealand rabbits were used in this study. The groove of 2mm diameter will be made on proximal to the femur bone was drilled by the heavy-duty dental engine. The rabbits were divided into three groups based on how the xylitol substance was applied; each group was then subdivided into two experimental periods (14,28 days), with four rabbits in each subgroup. Control groups received no xylitol therapy; locally treated groups received xylitol powder that was well condensed in the hole. Systemically treated groups received 1mg/kg of xylitol orally. After 14 days and 28 days, a histological investigation was performed to identify the number of osteoblasts and osteoclasts at the defect bone. Statistical analysis showed significant differences between all groups (control and treated). Histological analysis for osteoblast and osteoclast showed a significant increase in osteoblast and osteoclast in the treated groups compared to the control group. The systemically treated group shows better results than the local treated and control group. This study concluded that xylitol improved bone healing when used topically and systemically, evidenced by an increase in the number of osteoblast and osteoclast at the site of the femoral bone defect.

**Keywords:** Bone healing, bone defect, osteoblast, osteoclast, xylitol.

### Original Article:

DOI: [HTTPS://DX.DOI.ORG/10.21608/JAVS.2021.104726.1114](https://dx.doi.org/10.21608/JAVS.2021.104726.1114)

**Received :09 November, 2021.**

**Accepted :27 December, 2021.**

**Published in January, 2022.**

This is an open access article under the term of the Creative Commons Attribution 4.0 (CC-BY) International License . To view a copy of this license, visit: <http://creativecommons.org/licenses/by/4.0/>

*J. Appl. Vet. Sci., 7 (1) : 58-63.*

### INTRODUCTION

The bone defect could take a long time to be fully regenerated; even then, some individuals still experience a delay in bone healing (Marsell, *et al.*, 2011). The treatment strategy of bone healing has been developed by advances in better protocols, hardware, surgical techniques, etc. (Christine, *et al.*, 2018). Among them, pharmacological treatment would reduce physical and mental burdens for patients, although a substantial amount of research is required for a clinical application at this stage (Brandt, 2012).

Xylitol was first isolated from the bark of beech trees in 1890. The application of xylitol varied widely from food, nutraceuticals, beverage to pharma industries, making it one of the top 12 global bio-products (Vishal, *et al.*, 2020). Xylitol is a polyol of the pentitol type, also called sugar alcohol or polyalcohol. It is a white crystalline, amorphous sugar

alcohol and low-calorie sweetener. Xylitol prevents demineralization of teeth and bones, otitis media infection, respiratory tract infections, inflammation and cancer progression (Arcaño, *et al.*, 2020). Xylitol is considered as a “Generally Recognized as Safe” (GRAS) additive by the Food and Drug Administration (FDA) and 70% of the market share globally accounts for the manufacturing of chewing gums and confectionery products (Dasgupta, *et al.*, 2017).

The European Food Safety Agency has also claimed that xylitol chewing gum reduces the risk of caries in children (Salli, *et al.*, 2019). Several reviews have been published in recent years with xylitol application in pharmaceuticals (especially dental care) and its production prospects. Herein, we aim to review the development of production methods with time, including chemical and biological routes and their

application in the pharmaceutical industry for the treatment of defective bone or as bone substitutes. This study aims to see how topical and systemic xylitol affects femoral bone healing in rabbits by examining how it affects osteoblasts and osteoclasts in the defect site.

## MATERIALS AND METHODS

### Animals:

The present study was carried out on white New Zealand healthy male rabbits weighing from (mean=2Kg). The enrolled rabbits were provided with an appropriate, balanced dry diet and water ad libitum and caged individually in standard rabbit cages in the animal house of the College of Dentistry, University of Mosul, under veterinary supervision.

The animal's condition and general health were checked before enrollment in the current study and during the designed follow-up period. Animals were divided into 3 groups (eight animals in each group) assigned as A; control group, B; topically treated group and C; systemically treated group. The material used in this study (xylitol) was manufactured by the World Organic Company, Canada.

### Anesthesia:

Animals were divided into 3 groups, and each group consisted of 8 rabbits. Prior to anesthesia, the food was withheld for 8 hours. All rabbits were anesthetized with a mixture of IM injection of general anesthesia Ketamine hydrochloride (Ketalar.50 mg/kg) and xylazine (5mg/kg) as a sedative, analgesic, and muscle relaxant drug.

### Procedure induction of a femoral bone defect:

The surgery was performed under a complete aseptic condition with the rabbits positioned in dorsal recumbency. The limb was clipped circumferentially from the dorsal midline to mid tibia and draped from a hanging position to allow maximal manipulation during surgery. A 1.5 cm skin incision was made from the greater trochanter and extended ventrally over the proximal femur. The Fascia and underlying muscles were bluntly dissected and the femoral shaft was exposed. The periosteum was elevated by blunt dissection using Hawarth periosteal elevator. They used round carbide bur (2mm) attached to the dental engine's low-speed straight surgical handpiece. The femoral bone shaft created 2 mm of both diameter and depth hole (defect). The defect was then rinsed using distilled water and dried using gauze. In group B (topically treated group) and left without adding any

material in group A (control group) and group C (systemically treated group).

The rabbits enrolled in group C received 1mg/kg of xylitol through the oral cavity throughout the treatment period day. The wound was closed by suturing the muscles and approximation of the skin edges using a simple interrupted suturing technique. The wound was daily dressed with povidene iodine. The operated rabbits were immediately isolated after the surgical procedure until they completely regained consciousness. They were monitored closely, especially during the first twenty hours after the surgical procedure, including feeding and physical activity. Each experimental animal received Oxytetracycline 0.5 ml/kg once daily for three days following the surgical procedure every 24 h. Overdosage of Ketalar (100mg) was used to euthanize animals after a 14 and 28 days healing period. All rabbits groups were sacrificed after 14<sup>th</sup> and 28<sup>th</sup> days after the operation.

### Histological and histochemical work:

#### Decalcification:

A routine histological processing method was initiated by removing the fixative using running tap water for 30 minutes. Dehydration was then carried out by running the tissues through a graded series of alcohol (70%, 90%, and 100%). The tissues were initially exposed to 70% alcohol for 24 hrs. followed by 90% alcohol for 4 hours and then two changes of absolute alcohol, each for 2 hrs. Dehydration was then followed by clearing the samples in two changes of xylene; it consisted of tissue immersion for an hour in a mixture comprising 50% alcohol and 50% xylene, followed by pure xylene for one hr. with monitoring. Samples were then impregnated with molten paraffin wax two changes 2hrs. for each, then embedded and blocked out. Paraffin sections (5-6  $\mu$ m) were obtained by using a rotary microtome and mounted and affixed to histological slides.

#### Micromorphometric measurements:

- Newly formed trabecular bone area/ $\mu$ m<sup>2</sup>
- Osteoblast No./40x field
- Osteocyte No./40x field

All parameters were measured using the color USB 2.0 digital image camera Scope.Image 9.0-China), which was provided with image processing software. The camera software was calibrated to all lenses of Microscope-Olympus-CX31 with a 0.01mm stage micrometer(ESM-11 / Japan). Heat to dissolve. Add 25 ml of 10% alcoholic hematoxylin solution and heat to boiling for 1 minute. Remove from heat and slowly add 1.25 g of mercuric oxide (red). Heat to the solution and until it becomes dark purple color. Cool

the solution in a cold water bath and add 10 ml of glacial acetic acid (concentrated). Filter before use.

Eosin Y Stock Solution (1%):

Eosin Y ..... 1 g  
Distilled water ..... 20

**Procedure:**

1. Deparaffinize sections, 2 changes of xylene, 10 minutes each.
  2. Re-hydrate in 2 changes of absolute alcohol, 5 minutes each.
  3. 95% alcohol for 2 minutes and 70% alcohol for 2 minutes.
  4. Wash briefly in distilled water.
  5. Stain in Harris hematoxylin solution for 8-10 minutes.
  6. Wash in running tap water for 15 minutes.
  7. Differentiate in 1% acid alcohol for 30 seconds.
  8. Wash running tap water for 1 minute.
  9. Rinse in 95% alcohol, 10 dips.
  10. Counterstain in eosin Y solution for 30 seconds to 1 minute.
  11. Dehydrate through 95% alcohol, 2 changes of absolute alcohol, 5 minutes each.
  12. Clear in 2 changes of xylene, 5 minutes each.
  13. Mount with xylene-based mounting medium.
- Results: nuclei ....blue, Cytoplasm ....pink.

**Statistical analysis:**

The histomorphometric study was carried out using Sigma plot V12.0 / systat software. The data were presented as means + standard error (SE) and evaluated using Duncan's test with a significance level of P0.05 (Systat Software Inc 2020).

**RESULTS**

**Histological Results:**

**1. On day 14 of the experiment:**

In the control group, the femoral bone defect shows infiltration of many inflammatory cells (++++). Scanty granulation tissue formed at the defect area's periphery, with new trabecular bone formation (bonnie spicules) and a scanty amount of woven bone as in Fig. 1-A. In the local treated group, the femur bone of the local treated group at 14 days shows the hole site with the presence of new trabecular bone; it was better than that in the non-treated group as in Fig. 1-B.

The femur bone of the systemic treated group at 14 days shows the hole site with new trabecular bone formation (bonnie spicules), woven bone, connective tissue formation, and inflammatory cells as in Fig. 1-C.

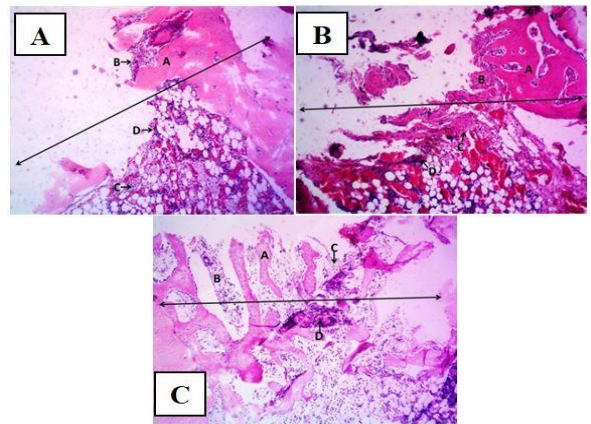


Fig.1: A: Photomicrograph of femur bone of control group (14 days) shows the site of the hole (↔) with the presence of new trabecular bone formation , scanty amount of woven bone, connective tissue formation and inflammation (score 2). B: Photomicrograph of femur bone of local treated group (14 days) shows the site of the hole (↔) with the presence of new trabecular bone. C: Photomicrograph of femur bone of systemic treated group (14 days) shows the site of the hole (↔) with the presence of new trabecular bone formation , woven bone , connective tissue formation , and inflammation (score 2).

**2. On day 28 of the experiment:**

At 28 days femur bone of the control group shows the site of the hole with the presence of well-developed new trabecular bone formation (bonnie spicules), scanty amount of woven bone, connective tissue formation and inflammatory cell (Fig 2-A). The femur bone of the local treated group (28 days) shows the hole site with the presence of well-developed new trabecular bone formation filling the hole area, woven bone, and connective tissue formation (Fig 2-B). While in the femur bone of the systemic treated group (28 days) shows the hole site with the presence of well-developed new trabecular bone formation not fill the hole area, woven bone, inflammation and connective tissue formation (Fig 2-C).

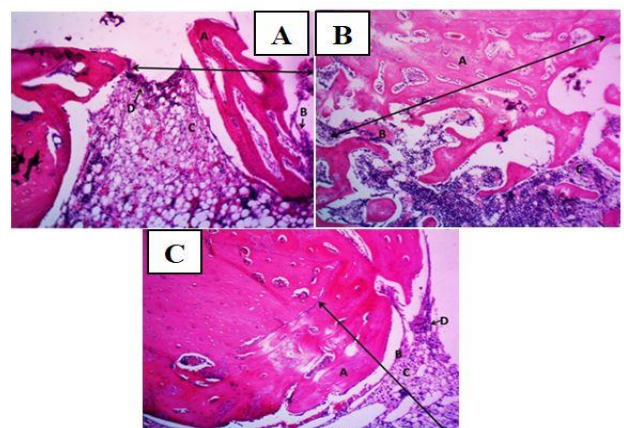


Fig. 2: Photomicrograph of femur bone of control (A); local treated (B) and systemic treated group (C) at 28 days shows the site of the hole (↔) with the presence of well-developed new trabecular bone formation not fill the hole area, woven bone , connective tissue formation and inflammation (score 1). H&E stain, 100X.

**Histomorphometric Results:**

**1. Statistical analysis of the number of osteoblasts founded:**

ANOVA -Test showed at 14 days period, there was a significant increase in the number of osteoblasts found on both local and systemically treated groups compared to the control group. There was a significant increase in the number of osteoblasts found in the systemically treated group over the locally treated group. At 28 days, there was a significant increase in the number of osteoblasts in locally treated groups and a decrease in the systemic treated group. Both systemically and locally are larger than the control group as shown in table 1 and Fig. 3.

Table I: Statistical analysis of the number of osteoblasts:

Osteoblast No./40x field		
Methods of treatment	14 d	28d
	MS ± DS	MS ± DS
Control	17.2± 2.1	23.2±2.5
Local	43.6± 4.7	43.8±5.2
Systemic	48.6±2.7	37.4±3.0

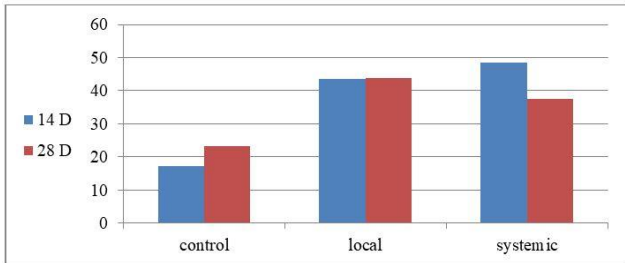


Fig.3: The histogram of statistical analysis of the number of osteoblasts founded.

**2. Statistical analysis of the number of osteocytes found:**

ANOVA –Test shows a slight difference in the number of osteocytes between groups at different healing periods with the systemically and locally treated superiority than the control group as shown in table 2 and Fig. 4.

Table 2: Statistical analysis of the number of osteocytes:

Osteocyte No./40x field		
Methods of treatment	14 d	28d
	MS ± DS	MS ± DS
Control	7.8±2.3	25.8±5.0
Local	39.0±2.5	46.8±6.6
Systemic	33.4±4.3	34.8±4.1

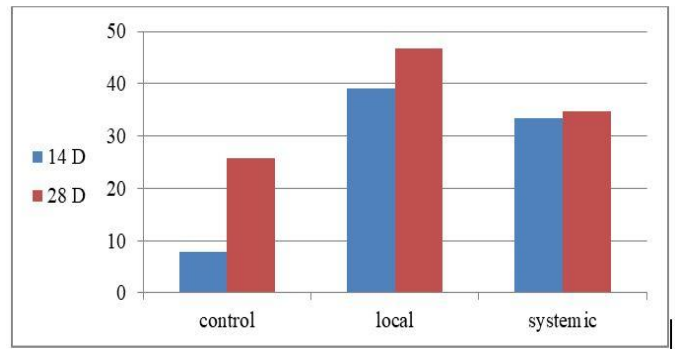


Fig. 4: The histogram of statistical analysis of the number of osteocytes founded.

**2. Statistical analysis of the number of osteoclasts found:**

ANOVA test shows a difference in the number of osteoclast between groups at different healing periods with the superiority of the locally treated group than the systemically treated group ( table 3 and Fig. 5).

Table 3: Statistical analysis of the number of osteoclasts:

osteoclast No./40x field		
	14 Days	28 Days
Control	0.83±0.4	1.83±0.7
Local	3.83±0.7	4.83±0.7
Systemic	2.83±0.7	3.83±0.7

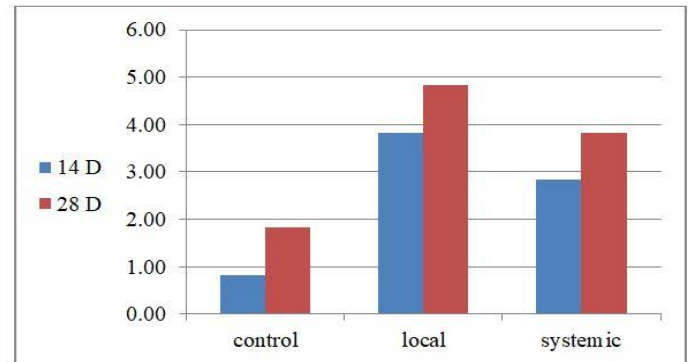


Fig. 5: The histogram of statistical analysis of osteoclasts.

**3. Statistical analysis of the thickness of bone trabeculae:**

ANOVA Test shows a significant difference in the thickness of bone trabeculae between groups at different healing periods with the superiority of the locally treated then systemically treated group over the control group as shown in table 4 and Fig. 6.



Tale 4: Statistical analysis of the thickness of bone trabeculae:

The newly formed trabecular bone area		
Methods of treatment	14 d	28d
	MS	MS
Control	10421.4	139600.6
Local	178609.7	616812.2
Systemic	276471.7	377942.8

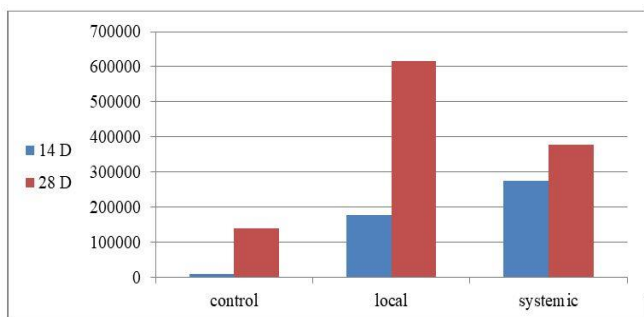


Fig. 6: The histogram of statistical analysis of the thickness of bone trabeculae.

## DISCUSSION

Fracture is one of the most common body injuries in our daily life. Following the fracture, the bone healing system restores the damaged area of the bone qualitatively, structurally, and functionally (Juri, et al., 2020). Fracture healing is a well-orchestrated process involving the interplay of multiple cell types, various cytokines, chemokines, and growth factors which can result in reconstituted bone without any scar tissue (Schell, et al., 2017).

This study found that applying xylitol as locally or systemic enhanced bone healing bone, which is indicated by increasing the number of osteoblast and osteocyte, which is one of the most commonly utilized bone biomarkers in clinical studies. This result agrees with the previous study that suggested that bone remodeling is tightly regulated by a cross-talk between bone-forming osteoblasts and resorbing bone osteoclasts. Osteoblasts and osteoclasts communicate with each other to regulate cellular behavior, survival and differentiation through direct cell-to-cell contact or secretory proteins (Jung, et al., 2020). The function and activity of osteoclasts and osteoblasts in bone resorption and formation, respectively, are orchestrated through osteocytes which are critical sensors of mechanical stimuli on the bone (Juri, et al., 2020).

In general, bone healing progresses different temporal phases following an injury such as inflammatory, reparative, and bone remodeling phases (Florence, et al., 2016). Osteoblasts and osteoclasts have important roles especially in the latter two phases (Schell, et al., 2017). In the reparative phase, a non-calcified cartilaginous callus is formed to connect the two ends of the fractured bone. Then, osteoblasts contribute to replacing the soft callus with calcified hard callus, known as woven bone. In the remodeling phase, the hard callus is resorbed by osteoclasts, and lamellar bone is formed by osteoblasts (Marsell, et al., 2010). Increased activity of the osteoclasts could accelerate the cartilaginous callus resorption and the replacement by hard callus. Also, enhanced activity of the osteoblasts is essential for the proper bone repair process (Thomas, et al., 2015).

Osteoclasts differentiate from hematopoietic progenitor cells of the monocyte/macrophage lineage. It is hypothesized that they recognize and target skeletal sites of compromised mechanical integrity and initiate the bone remodeling process. However, the exact signals and underlying mechanisms that target osteoclasts to specific sites remain unknown (Ramin, et al., 2015). Osteoclastic bone resorption is followed by the recruitment of osteoblasts derived from mesenchymal stem cells. Osteoblasts actively synthesize extracellular matrix on bone surfaces, which are subsequently mineralized (Barragan, et al., 2006). Osteoblasts entrapped in matrix differentiate into osteocytes and compose 90-95% of the cells embedded in the mineralized matrix of bone (Canalis, 2005). Osteoblasts actively synthesize extracellular matrix on bone surfaces, which are subsequently mineralized. Osteoblasts entrapped in matrix differentiate into osteocytes and compose 90-95% of the cells embedded in the mineralized matrix of bone (Ramin, et al., 2015).

The histological processes findings in this study showed significant differences in healing processes of the defect bone between the control group and treated group (systemic and local) and that proved by the increased amount of the osteoblast and decreased osteoclast in the defect site and improvement in the ossification process comparing with the control group as the amount of new bone formation was higher, this result in agreement with other study explained that osteoblasts are mature bone-forming cells responsible for bone formation by producing bone matrix proteins and play an essential role in bone remodeling (Lerner et al., 2019).

## CONCLUSION

Xylitol application increases the number of osteoblasts found on both local and systemically treated groups compared to the control group and we also found an increase in the number of osteoblasts in the systemically treated group over the locally treated group, which may be related to the absorption pathway of xylitol in the body.

## Declaration of Conflicting Interests

The authors revealed that there is no potential conflicts of interest.

## REFERENCES

- AHUJA,V., MACHO, M., EWE, D., SINGH, M., SAHA, S., and SAURAV, K., 2020. Biological and pharmacological potential of xylitol: a molecular insight of unique metabolism. *Foods*, 9(11), 1592. <https://doi.org/10.3390/foods9111592>
- ARCAÑO, Y.D., GARCÍA, O.D.V., MANDELLIB ,W.A., CARVALHO,W. A., and PONTES, L.A.M., 2020. Xylitol: A review on the progress and challenges of its production by chemical route. *Catalysis Today*, 344, 2-14. <https://doi.org/10.1016/j.cattod.2018.07.060>
- BRANDI, M. L. 2012. Drugs for bone healing. *Expert Opinion on Investigational Drugs*, 21(8), 1169-1176. <https://doi.org/10.1517/13543784.2012.696610>
- BARRAGAN, A. C., NICOLELLA, D., DUSEVICH, V., DALLAS, M.R., EICK, J.D., and BONEWALD, L.F., 2006. Mechanism by which MLO-A5 late osteoblasts/early osteocytes mineralize in culture: similarities with mineralization of lamellar bone. *Calcif Tissue Int.* 79 (5):340-353. <https://doi.org/10.1007/s00223-006-0107-2>.
- CANALIS, E. 2005. The Fate of Circulating Osteoblasts. *N. Engl. J. Med.* 352(19), pp. 2014-2016. <https://doi.org/10.1056/nejme058080>.
- DASGUPTA, D., BANDHU, S., ADHIKARI, D.K., and GHOSH, D., 2017. Challenges and prospects of xylitol production with whole-cell bio-catalysis: A review. *Microbiological Research*, 197, 9-21. <https://doi.org/10.1016/j.micres.2016.12.012>.
- EINHORN,T.A., and GERSTENFELD,L.C., 2015. Fracture healing: mechanisms and interventions. *Nature Reviews Rheumatology*, 11(1), 45-54. <https://doi.org/10.1038/nrrheum.2014.164>
- KIM, J.M., LIN, C., STAVRE, Z., GREENBLATT, M.B., and SHIM, J.H. 2020. Osteoblast-Osteoclast Communication and Bone Homeostasis. *Cells*, 9(9), 2073. <https://doi.org/10.3390/cells9092073>
- KOWALCZEWSKI, C. J., and SAUL, J. M., 2018. Biomaterials for the delivery of growth factors and other therapeutic agents in tissue engineering approach to bone regeneration, *Front. Pharmacol.* 9, 513. <https://doi.org/10.3389/fphar.2018.00513>.
- LERNER, U. H., KINDSTEDT, E., and LUNDBERG, P., 2019. The critical interplay between bone-resorbing and bone-forming cells. *Journal of clinical periodontology*, 46, 33-51. <https://doi.org/10.1111/jcpe.13051>

- LISOWSKA, B., KOSSON, D., and DOMARACK, K., 2018. Lights and shadows of NSAIDs in bone healing: the role of prostaglandins in bone metabolism. *Drug design, development and therapy*, 12, 1753. <https://dx.doi.org/10.2147%2FDDDT.S164562>
- LOI F., CORDOVA, L.A. , PAJARINEN, J., LIN,T.H , YAO, Z., and GOODMAN,S.B., 2016 . Inflammation, fracture and bone repair. *Bone.* , 86, 119-130. <https://doi.org/10.1016/j.bone.2016.02.020>.
- MARSELL, R., and EINHORN, T. A., 2010. Emerging bone healing therapies. *Journal of orthopaedic trauma*, 24, S4-S8. <https://doi.org/10.1097/bot.0b013e3181ca3fab>.
- NAKATA,J., AKIBA,Y., NIHARA, J., THANT, L., EGUCHI, K., KATO, H., IZUMI, K., OHKURA, M., OTAKE, M., KAKIHARA, Y., and SAITO, I., SAEKI, M., 2020. ROCK inhibitors enhance bone healing by promoting osteoclastic and osteoblastic differentiation, *Biochemical and Biophysical Research Communications*, 526 (3), 547-552. <https://doi.org/10.1016/j.bbrc.2020.03.033>.
- OFTADEH,R., PEREZ-VILORIA, M., VILLACAMACHO,J.C., VAZIRI, A., and NAZARIAN, A., 2015. Biomechanics and mechanobiology of trabecular bone: a review. *Journal of biomechanical engineering*, 137(1), 010802. <https://doi.org/10.1115/1.4029176>.
- SALLI, K., LEHTINEN, M.J., TIHONEN, K., and OUWEHAND, A.C., 2019. Xylitol's health benefits beyond dental health: a comprehensive review. *Nutrients*, 11(8), 1813. <https://doi.org/10.3390/nu11081813>.
- SCHELL, H., DUDA, G.N., PETERS, A., TSITSILONIS, S., JOHNSON, K.A., and SCHMIDT-BLEEK, K., 2017. The haematoma and its role in bone healing. *Journal of experimental orthopaedics*, 4(1), 1-11. <https://doi.org/10.1186/s40634-017-0079-3>.

### How to cite this article:

Ahmed, H. Naji; Ghada, A. Taqa and Wael, T. Al-Watter, 2022. The Effect of Xylitol on Osteoclastogenesis in Experimentally Induced Bone Defect in Rabbits. *Journal of Applied Veterinary Sciences*, 7 (1): 58 – 63.  
DOI: [HTTPS://DX.DOI.ORG/10.21608/JAVS.2021.104726.1114](https://dx.doi.org/10.21608/JAVS.2021.104726.1114)

