



## Research Article

# EZH2 is a specific marker for granulomatous WT

Ebraheme Boceila<sup>1</sup>, and Mariz Faltas<sup>2</sup>

### Abstract

**Background** Warthin's tumor (WT) is the second commonest benign neoplasm of the parotid gland and constitutes about 14% of all epithelial tumors of the parotid gland. The coexistence of Warthin's tumor with granulomas is under-investigated. The pathogenesis of the granulomatous changes in WT, especially sarcoid-like granulomas remains unclear.

**Objective** We investigate the specificity of EZH2 in metaplastic WT and classic WT.

**Method** The annual bulletins and detailed reports of Health Services published by Central Agency of Public Mobilization and Statistics and the pathology departments of major public health institutes in Cairo were examined. The Kaplan-Meier method with confidence interval and Log-Rank test are used to calculate the survival analysis for the five studied groups

**Results** Cases of conventional WT did not show a granulomatous reaction. Twelve cases out of 48 metaplastic WT revealed mild to severe granulomatous reactions in the lymphocytic stroma. Of these, a case showed a tuberculous reaction, and two cases revealed sarcoid-type granulomas composed of dense aggregates of epithelioid histiocytes and occasional Langhan's giant cells.

**Advances in Knowledge** This is the first study to report EZH2 as a specific marker for granulomatous WT. Strong expression of EZH2 was clinically correlated to a past history of either pulmonary tuberculosis or sarcoidosis.

**Keywords:** Epidemiology, Orofacial malignancies, Survival rate

## Introduction

Warthin's tumor (WT) is the second commonest benign neoplasm of the parotid gland and constitutes about 14% of all epithelial tumors of the parotid gland[1]. The coexistence of Warthin's tumor with granulomas is under-investigated. The pathogenesis of these sarcoid-like granulomas remains unclear[2]. WT containing oncocytes are more susceptible to FNA-induced histologic changes. The high-energy requirements of these mitochondrion-rich tumors perhaps contribute to their tendency to undergo infarction after FNA injury.

The histologic features of Warthin's tumor are distinct and make it easily recognizable among the other salivary gland tumors. The columnar oncocytic epithelial cells, papillary and cystic growth pattern, and lymphocytic component characterize WT with a distinctive histomorphology[3]. Although secondary changes in this tumor are rare, features such as necrosis, fibrosis, squamous metaplasia, and malignant transformation are well recognized[4-7]. Metaplastic changes of the epithelial component include focal squamous or mucinous metaplasia, focal ciliated epithelium, and snout-like apical cytoplasmic projections suggestive of apocrine differentiation. Variability in the overall amount of lymphocytic component can also occur. However, no molecular profile is found characteristic of this tumor[8, 9].

Enhancer of zeste homologue 2 (EZH2) is a widely studied histone methyl transferase. Recently, EZH2 was reported to be sufficient for distinguishing benign and malignant salivary tumors [10], and hepatic tumors[11]. This study investigates the specificity of EZH2 in metaplastic WT and classic WT.

## Method

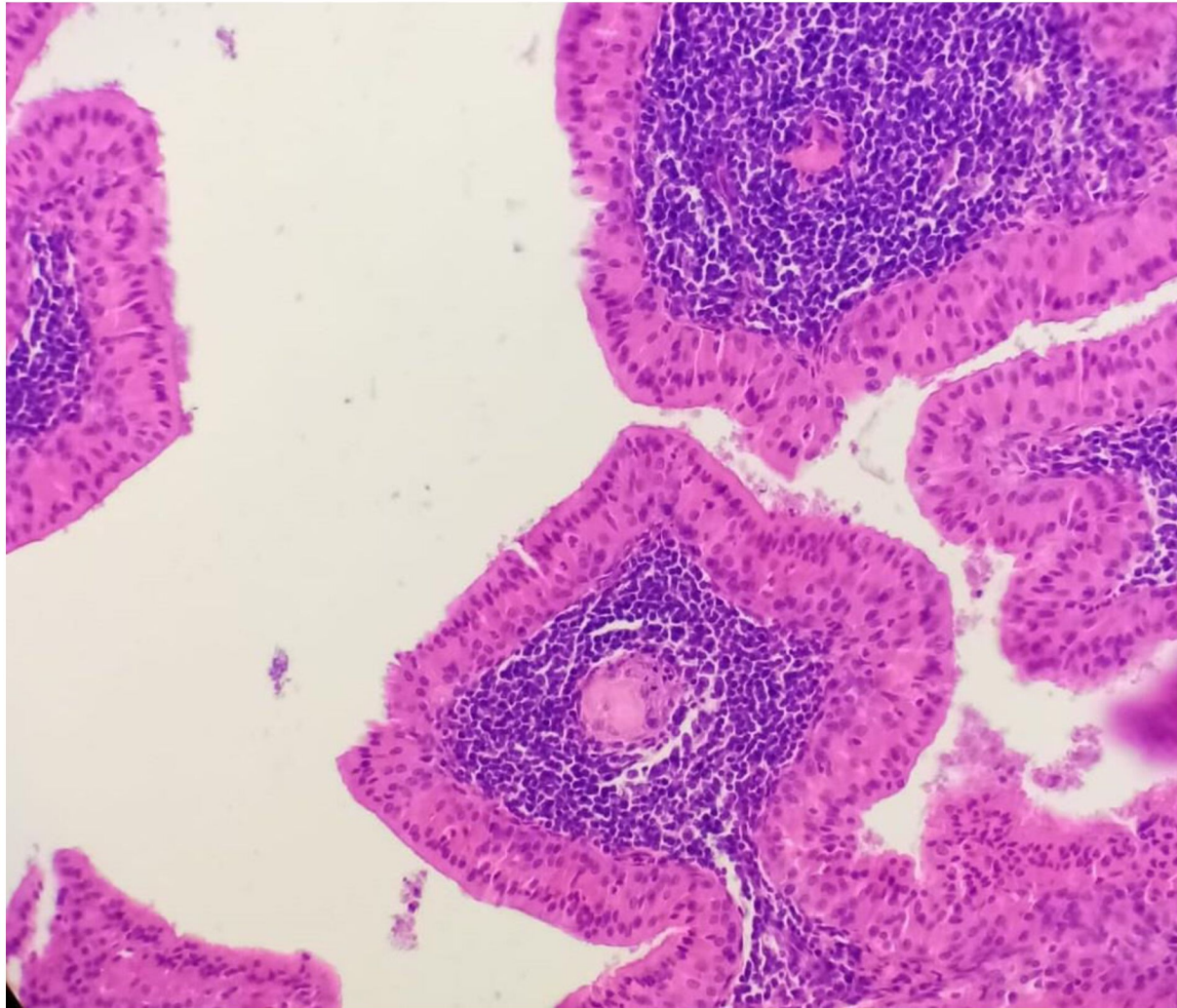
We retrospectively evaluated 48 patients with metaplastic WT and 60 patients with conventional WT who had undergone curative surgery between November 2016 and December 2021. Patients with WT were informed about the study and consented to participate. Malignant transformation and collision lesions were excluded from all 108 cases. That is to say, Warthin-like mucoepidermoid carcinoma or salivary malignancy arising in WT were beyond the scope of this study.

The paraffin-embedded specimens were cut into 4- $\mu$ m histological sections and mounted on glass slides prepared with organosilane adhesive. The sections were submitted to immunoperoxidase staining a primary antibody of anti-EZH2, clone 11/EZH2, from BD Biosciences (San Jose CA, USA) (dilution 1:100). The reaction resulted in nuclear staining. Scores were assigned based on the density of positivity by using negative (score =0, < 5 % of nuclei staining); weak (score = 1, 5-10 % of nuclei staining); moderate (score = 2, 11-50 % of nuclei staining); and strong (score = 3; >50% of nuclei staining).

## Results

The cases of conventional WT did not show a granulomatous reaction. 12 cases out of 48 metaplastic WT revealed mild to severe granulomatous reaction (Figure 1). Of these, two cases

revealed sarcoid-type granulomas composed of dense aggregates of epithelioid histiocytes and occasional Langhan's giant cells. These lesions were generally composed of broad papillae covered with a double layer of oxyphilic cells with granular eosinophilic cytoplasm. The papillary cores showed abundant mixed lymphoid cells and hyperplastic lymphoid follicles. These noncaseating granulomas were distributed within the lymphoid cores of the papillae as well as extending into the adjacent non-neoplastic salivary lobules.



**Figure 1.** Micrograph showing granuloma development in WT

EZH2 immunohistochemical staining resulted in a clear nuclear reaction. The non-tumorous portion of WT was immunonegative. The granulomatous reactions seen in metaplastic WT was strongly positive (Figure 2). All case of conventional WT did not express EZH2.



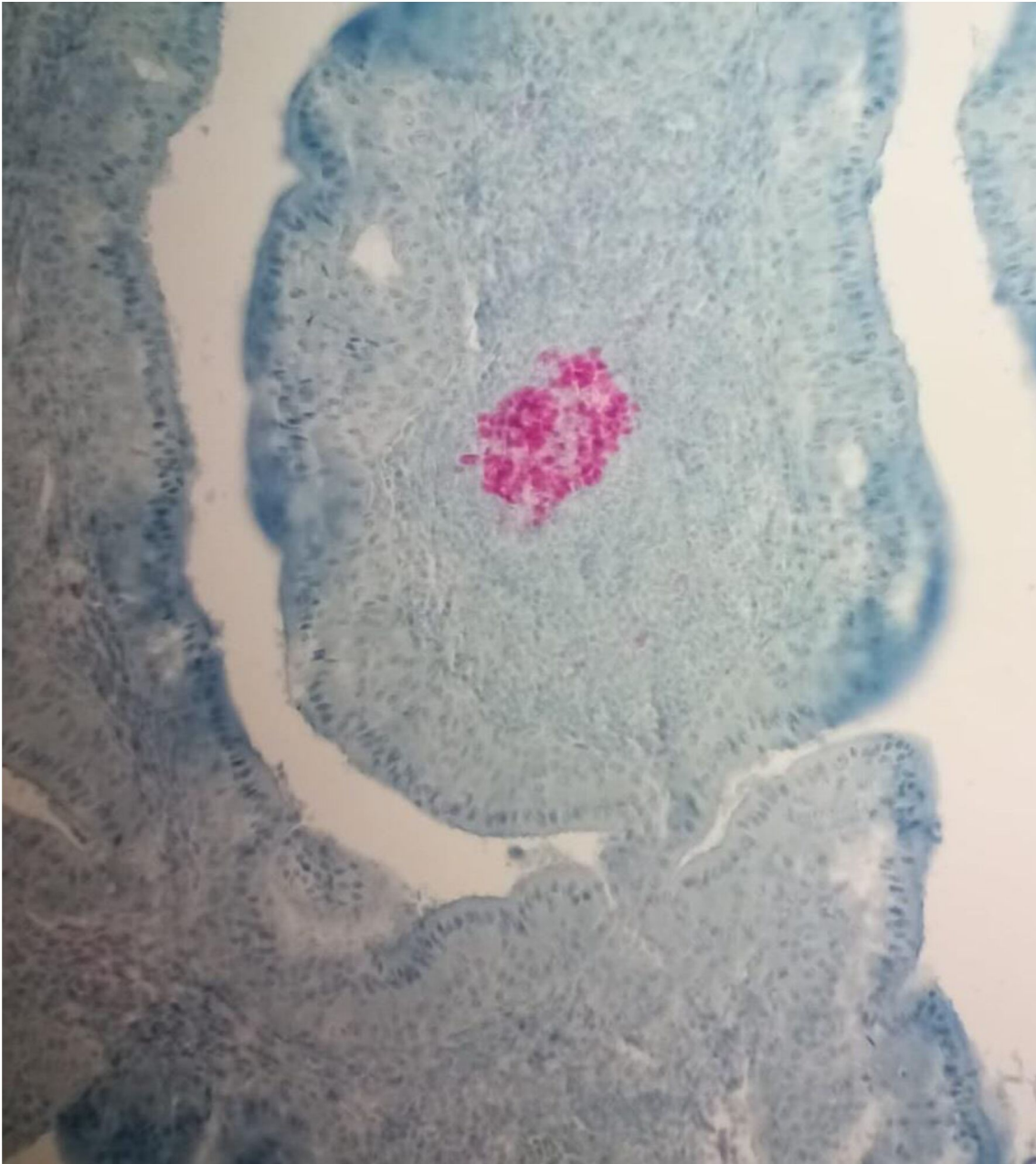


Figure 2. EZH2 strong expression in granulomatous WT

## Discussion

Post-aspiration disruptions were reported to cause oncocytic changes and infarcts formation. However, neither of these is specific to WT[12]. Although oncocytes are one of the characteristics of Warthin's tumor, they can also be found in aspirates in a variety of conditions affecting the salivary gland, ranging from normal glands in elderly individuals, reactive lesions, and oncocytic hyperplasia, to such tumors as pleomorphic adenomas and

oncocytomas[13]. The nuclei of Warthin's tumor oncocytes contain prominent nucleoli, and the cells can be binucleated. Nuclear pyknosis and nuclear ghosts (karyolysis) may also occur. Therefore, Warthin's tumor may be mistaken for oncocyctic carcinoma, or oncocyctic acinic cell carcinoma.

A granulomatous reaction can result from infection such as tuberculosis, actinomycosis, histoplasmosis, cat scratch fever, toxoplasmosis, and sarcoidosis. Mycobacterial tuberculosis, fungal infection, and cat scratch disease have to be excluded histologically. Granuloma development in WT was reported since 1990s, but connection to underlying connective tissue granulomatous disease could not established[2, 14–18]. Granulomas within salivary glands can be generally classified into four categories (a) foreign body type (containing cholesterol crystals or keratin masses; rarely as a consequence of sialography reaction to the escaped X-ray contrast material); (b) muciphagic type (with numerous foamy cells - the appearance similar to that seen in the wall of a ruptured retention cyst); (c) tuberculous granulomas (with central caseous necrosis; positive staining for acid fast bacilli); (d) sarcoid-like type (in sarcoidosis, Heerfordt's syndrome, Wegener's granulomatosis, toxoplasmosis, other infections, or idiopathic). The sarcoid-like granuloma could have been caused by a toxic effect of the cyst contents, inducing a foreign body giant cell reaction[19].

The detection of EZH2 in granulomatous changes in WT was previously detected [10]. However, it was misinterpreted as a stromal epithelial component of WT in which lymphocytes were aggregations were positive for EZH2.

Malignant transformation of WT, mostly as Warthin-like mucoepidermoid carcinoma, is recently reported and has been described in case series[20]. The carcinoma infiltrating into WT are either completely confined to the WT or feature a very focal infiltration of the adjacent salivary gland parenchyma[21]. Even more, extra-salivary Warthin adenocarcinoma was mistakenly reported[22]. However, this controversy is beyond the scope of this study because most malignant tumors show tumor-infiltrating lymphocytes that are not specifically native of WT. This is the first study to report EZH2 as a specific marker for granulomatous WT.

## Conclusion

This is the first study to report EZH2 as a specific marker for granulomatous WT. Strong expression of EZH2 was clinically correlated to a history of either pulmonary tuberculosis or sarcoidosis.

**Notes:** None

**Acknowledgements:** None

**Funding resources:** None

**Conflict of interest:** The authors declare that there is no conflict of interest.

## References

- [1] Kuzenko Y V., Romanuk AM, Dyachenko OO, et al. Pathogenesis of Warthin's tumors. *Interv Med Appl Sci* 2016; 8: 41–48.
- [2] To EWH, Tsang WM, Leung CY, et al. Warthin's tumor with multiple sarcoid-like granulomas: A case report. *J Oral Maxillofac Surg*; 60. Epub ahead of print 2002. DOI: 10.1053/joms.2002.31860.
- [3] Skálová A, Vanecek T, Simpson RHW, et al. CRTC1-MAML2 and CRTC3-MAML2 fusions were not detected in Metaplastic Warthin tumor and Metaplastic Pleomorphic adenoma of salivary glands. *Am J Surg Pathol* 2013; 37: 1743–1750.
- [4] Yorita K, Nakagawa H, Miyazaki K, et al. Infarcted Warthin tumor with mucoepidermoid carcinoma-like metaplasia: a case report and review of the literature. *J Med Case Rep*; 13. Epub ahead of print 2019. DOI: 10.1186/s13256-018-1941-3.
- [5] Seifert G. Karzinome in vorbestehenden Warthin-Tumoren (zystadenolymphomen) der Parotis. Klassifikation, Pathogenese und Differentialdiagnose. *Pathologe* 1997; 18: 359–367.
- [6] Nagao T, Sugano I, Ishida Y, et al. Mucoepidermoid carcinoma arising in Warthin's tumour of the parotid gland: Report of two cases with histopathological, ultrastructural and immunohistochemical studies. *Histopathology* 1998; 33: 379–386.
- [7] Zhang X, Baloch ZW, Cooper K, et al. The significance of mucinous metaplasia in Warthin tumor: a frequent occurrence and potential pitfall. *Hum Pathol*; 99. Epub ahead of print 2020. DOI: 10.1016/j.humpath.2020.03.008.
- [8] Hellquist H, Paiva-Correia A, Vander Poorten V, et al. Analysis of the Clinical Relevance of Histological Classification of Benign Epithelial Salivary Gland Tumours. *Adv Ther* 2019; 36: 1950–1974.
- [9] Stárek I, Tichý T, Skýpalová P, et al. Ulcerating Warthin's tumour. *Acta Otolaryngol* 2004; 124: 744–746.
- [10] Hajósi-Kalcakosz S, Vincze E, Dezso K, et al. EZH2 is a sensitive marker of malignancy in salivary gland tumors. *Diagn Pathol*; 10. Epub ahead of print 2015. DOI: 10.1186/s13000-015-0392-z.
- [11] Hajósi-Kalcakosz S, Dezso K, Bugyik E, et al. Enhancer of zeste homologue 2 (EZH2) is a reliable immunohistochemical marker to differentiate malignant and benign hepatic tumors. *Diagn Pathol*; 7. Epub ahead of print 2012. DOI: 10.1186/1746-1596-7-86.
- [12] Schmitt AC, Cohen C, Siddiqui MT. Expression of SOX10 in Salivary Gland Oncocytic Neoplasms: A Review and a Comparative Analysis with Other Immunohistochemical Markers. *Acta Cytol* 2015; 59: 384–390.
- [13] Liu H, Ljungren C, Lin F, et al. Analysis of Histologic Follow-Up and Risk of Malignancy for Salivary Gland Neoplasm of Uncertain Malignant Potential Proposed by the Milan System for Reporting Salivary Gland Cytopathology. *Cancer Cytopathol*; 126. Epub ahead of print 2018. DOI: 10.1002/cncy.22002.
- [14] Watanabe M, Nakayama T, Koduka Y, et al. Mycobacterium tuberculosis infection within Warthin's tumor: Report of two cases. *Pathol Int*; 51. Epub ahead of print 2001. DOI: 10.1046/j.1440-1827.2001.01281.x.

- [15] Udoji WC. Coexistence of histoplasma granulomas and Warthin's tumor in the submaxillary salivary gland. *Tenn Med*; 92.
- [16] Galed-Placed I. Granulomas with toxoplasmic features in a Warthin's tumor of the parotid gland. *Acta Cytologica*; 53. Epub ahead of print 2009. DOI: 10.1159/000325357.
- [17] Brown S, Conn B, Wallace W, et al. GRANULOMAS IN WARTHIN TUMORS OF THE PAROTID: REPORT OF TWO NOVEL CASES AND REVIEW OF THE LITERATURE. *Oral Surg Oral Med Oral Pathol Oral Radiol* 2021; 132: e12.
- [18] Chen SL, Hwang CC, Liu YC, et al. Warthin's tumor with necrotizing tuberculous granulomatous inflammation causing severe facial nerve adhesion in parotid gland: A case report and literature review. *Medicine (United States)*; 99. Epub ahead of print 2020. DOI: 10.1097/MD.00000000000018763.
- [19] Ryška A, Seifert G. Adenolymphoma (Warthin's tumor) with multiple sarcoid-like granulomas. *Pathol Res Pract*; 195. Epub ahead of print 1999. DOI: 10.1016/S0344-0338(99)80106-X.
- [20] García JJ, Hunt JL, Weinreb I, et al. Fluorescence in situ hybridization for detection of MAML2 rearrangements in oncocytic mucoepidermoid carcinomas: Utility as a diagnostic test. *Hum Pathol*; 42. Epub ahead of print 2011. DOI: 10.1016/j.humpath.2011.02.028.
- [21] Matsui M, Hironaka S, Tameno H, et al. A case of parotid gland warthin adenocarcinoma. *Pract Otorhinolaryngol (Basel)*; 105. Epub ahead of print 2012. DOI: 10.5631/jibirin.105.141.
- [22] Bell D, Luna MA. Warthin adenocarcinoma: analysis of 2 cases of a distinct salivary neoplasm. *Ann Diagn Pathol* 2009; 13: 201–207.