

RESEARCH ARTICLE

Comparative Study on the Effect of A probiotic and Toltrazuril for Controlling Coccidiosis in Japanese Quails (*Coturnix Japonica*)

Nasr A. M. Nasr El Deen¹, Shima A. A. Ismail¹, Sahar S. Abd El Hamied² and Asmaa N. S. Kaser^{3*}

¹ Clinical Pathology Department, Faculty of Veterinary Medicine, Zagazig, University, Egypt

² Clinical Pathology Department, Animal Health Research Institute, Zagazig

^{1,3} Reference Laboratory for Quality Control on Poultry Production, Animal Health Research Institute, Zagazig

* Corresponding author: asmaanabil248@gmail.com

Article History: Received: 14/10/2021 Received in revised form: 25/10/2021 Accepted: 17/11/2021

Abstract

This study was carried out to compare between the effect of probiotic (Gro-2-max) and anticoccidial toltrazuril in prevention of coccidiosis in quails and also examine their effects on some blood biochemical, antioxidant and immunological parameters. One hundred and twenty six apparently healthy, one day old quails were divided into 6 equal groups. Group (Gp 1) was kept as control. Gp 2 was treated with a probiotic preparation (1 gm/L drinking water) from a day till 28 days old. Gp 3 was treated with toltrazuril at 16 days old at a dose of 25 ppm (1 ml/L drinking water) for 2 consecutive days. Gp 4 was inoculated with 4.1×10^4 sporulated oocysts of *Eimeria spp.* intracrop at 14 days old. Gp 5 was treated with a probiotic (1 gm/L drinking water) from a day till 28 days old and experimentally inoculated with 4.1×10^4 sporulated oocysts of *Eimeria spp.* at 14 days old using intracrop route. Gp 6 was experimentally inoculated with 4.1×10^4 sporulated oocysts of *Eimeria spp.* at 14 days old and treated with toltrazuril at 16 days old at a dose of 25 ppm (1ml/L drinking water) for 2 consecutive days. Probiotic relatively minimize the infestation and oocysts shedding. Moreover, an improvement in the cecal IFN- γ & IL-2 and antioxidant enzymes with variable effects on the serum cholesterol, triglycerides, HDL, ALT, AST and ALP activities were resulted. It could be concluded that the addition of the used probiotic (1 gm/L drinking water) was found to have a positive effect on coccidiosis and reduce the number of *Eimeria* oocysts and reduces the damage caused by free radicals and raise immunity.

Keywords: Coccidiosis, Probiotic, Toltrazuril, Immune response, *Eimeria*, Quails

Introduction

Among the most pathogenic diseases affecting quails is coccidiosis, which considered as one of the limiting factors for the development of this industry [1] Three *Eimeria* species have been recognized in Japanese quails including *Eimeria (E.) bateri*, *E. uzura* and *E. tsunodai* [2]. Coccidiosis is regarded as subclinical disease of quails; however, it causes severe economic losses via increasing mortality; decreasing productivity

and increasing the susceptibility for other bacterial diseases such as necrotic enteritis [3].

Toltrazuril is a symmetrical triazinetrione component and has been reported to be effective against all species of *Eimeria* infecting chickens [4]. It is effective against all intracellular developmental stages of the parasite including schizogony and gametogony stages [5]. Chemoprophylaxis with toltrazuril enhances immunity against poultry coccidiosis [6]. It has been proved that therapeutic

medication with toltrazuril protected chickens from clinical coccidiosis [7].

The development of resistance or decreasing the sensitivity of *Eimeria* species to chemotherapeutic agents in poultry was reported world-wide few years ago [8-10]. The major plan to decrease the development of such resistance is using less intensive shuttle and rotation programs and incorporating other methods in controlling the disease [11].

Probiotics have become more popular in the world of dietary supplements and feed additives within the poultry industry, acting as antibiotic substitutes. Above all, probiotics are universal feed additives that can be used in conjunction with other additives to promote improved performance and health. Their positive effects can be observed directly in the gastrointestinal tract and indirectly in immunomodulation of the poultry immune system [12]. However, there is still a little of literature discussing its use in controlling parasitic diseases like coccidiosis [13, 14].

Material and Methods

Quails

One hundred and twenty six one day old quails were obtained from Animal's Production Institute – Anshas, Al-sharkia, Egypt. All quails were kept under hygienic conditions and were fed on well balanced ration free from medication and water *add libitum*.

Probiotic (Gro-2-max®)

It is a product of Bio Natural America Institute (BNA), USA. It is a powder contains *Bacillus subtilis* [10^6 Colony Forming Unit (CFU)/gm], *Pediococcus pentosaceus* (2×10^4 CFU/gm), *Pediococcus acidilactici* (2×10^4 CFU/gm), *Lactobacillus acidophilus* (3×10^6 CFU/gm) and *Saccharomyces cerevisiae* (1×10^6 CFU/gm). It was given at a dose of 1 gm/L from a day till 28 days old [15].

Toltrazuril (Eimeriacox 2.5 %)®

It is a product of Royal Link Pharma-Belkas El-Dakahlia- Egypt. It was obtained in the form of watery solution. Each 100 ml contains 2.5 gm toltrazuril.

Eimeria spp.

Sporulated oocysts of *Eimeria* spp. were kindly obtained from the Parasitology Department, Faculty of Veterinary Medicine, Zagazig University to be used for experimental infestation.

Experimental design

One hundred and twenty six apparently healthy, one day old quails were divided into 6 equal groups. Gp 1 was kept as control. Gp 2 was treated with a probiotic preparation (1 gm/L drinking water) from a day till 28 days old. Gp 3 was treated with toltrazuril at 16 days old at a dose of 25 ppm (1 ml/L drinking water) for 2 consecutive days [16]. Gp 4 was inoculated with (4.1×10^4) sporulated oocysts of *Eimeria* spp. intracrop at 14 days old [16]. Gp 5 was treated with a probiotic (1 gm/L drinking water) from a day till 28 days old and experimentally inoculated with 4.1×10^4 sporulated oocysts of *Eimeria* spp. at 14 days old using intracrop route. Gp 6 was experimentally inoculated with 4.1×10^4 sporulated oocysts of *Eimeria* spp. at 14 days old and treated with toltrazuril at 16 days old at a dose of 25 ppm (1ml/L drinking water) for 2 consecutive days.

Sampling

Five birds, from each group, were sacrificed for collecting blood samples at age of 21 and 28 days. The first blood sample was taken without anticoagulant, left to clot, centrifuged at 3000 rpm for 15 minutes and the sera were separated for biochemical analysis. The second blood sample was collected on dipotassium salt of EDTA (1mg/1 ml blood), then centrifuged for 10 minutes at 3500 rpm, and the plasma was separated. The red cells were washed twice with cold saline solution and lysed with 20% parts of cold redistilled water. The lysate was divided into three parts in sterile epindorff tubes for determining the activities of catalase, superoxide dismutase, and the concentration of malondialdehyde.

Tissue specimens from small intestine and caecum were collected at the same time of blood samples for histopathological examination. Tissue specimens from the 36caecum were taken for immunological parameters, rinsed in phosphate buffer saline (PBS) to remove excess blood, minced and homogenized in PBS (pH 7.4) with a glass

homogenizer ice, centrifuged at 3000 rpm for approximately 20 minutes, and then the supernatant was kept at -20°C until using.

Daily collection of fresh dropping from each experimental group was done. *Eimeria* oocysts counting started from the 5th day till the end of the 14th day post infestation. Oocysts were counted in one gram of fecal matter using McMaster-chamber method [17].

Biochemical analysis

Serum samples were analyzed for the alanine aminotransferase (ALT) and aspartate aminotransferase (AST) [18], alkaline phosphatase (ALP) [19], cholesterol, triglycerides and high density lipoprotein (HDL-C) [20].

Antioxidant enzymes activities

Plasma catalase activity and malondialdehyde concentration were detected by commercial Enzyme Linked Immuno Sorbent Assay (ELISA) kits of Mybiosource according to the manufacturer's instructions with Cat. No. MBS2600683 and Cat. No. MBS738685, respectively.

Plasma superoxide dismutase activity was detected by commercial ELISA kits of Cusabio according to the manufacturer's instructions with Cat. No. CSB-E08555r.

Inflammatory markers

Cecal interferon- gamma (IFN- γ) and interleukin-2 (IL-2) were detected by commercial ELISA kits of Mybiosource for birds according to the manufacturer's

instructions with Cat. No. MBS779133 and MBS1602755 respectively.

Pathological examination

Specimens from the small intestine and caecum were collected and fixed in 10% buffered neutral formalin solution, dehydrated in gradual ethanol (70-100%), cleared in xylene, and embedded in paraffin. Five-micron thick paraffin sections were prepared, routinely stained with hematoxylin and eosin (H&E) dyes [21], and then examined microscopically.

Statistical analysis:

The data obtained were expressed as mean \pm SE. Statistical comparison were analyzed by One Way ANOVA F-test to compare mean values between the experimental groups, using the SPSS 16.0 computer program. P value \leq 0.05 was considered as statistically significant [22].

Results and Discussion

Coccidiosis is recognized as the main parasitic disease of poultry and it is caused by protozoan parasites of genus *Eimeria* [17]. Shedding of *Eimeria* oocysts in the excreta of birds is generally considered as the major parameter for the assessment of coccidial infestation. The obtained data here revealed that quails in groups (5 & 6) showed a significant decrease in the fecal oocysts count from the 5th day to the 14th day post-infestation compared with *Eimeria* spp. infested group (Gp 4) (Table 1).

Table (1): Daily output of oocysts in experimentally infested quails (mean values \pm S.E) with sporulated oocysts of *Eimeria* spp. from the 5th to the 14th day post-infestation.

Day of infestation	Gp 4	Gp 5	Gp 6
5 th	1126.33 \pm 14.43 ^a	744.00 \pm 15.37 ^b	435.00 \pm 3.75 ^c
6 th	1303.66 \pm 10.49 ^a	856.33 \pm 10.17 ^b	494.33 \pm 16.22 ^c
7 th	756.80 \pm 9.40 ^a	543.00 \pm 10.81 ^b	348.66 \pm 12.34 ^c
8 th	552.00 \pm 9.53 ^a	315.66 \pm 5.23 ^b	267.20 \pm 11.12 ^c
9 th	326.00 \pm 3.78 ^a	207.50 \pm 3.32 ^b	175.50 \pm 5.26 ^c
10 th	193.50 \pm 9.35 ^a	135.66 \pm 3.84 ^b	91.00 \pm 3.21 ^c
11 th	136.16 \pm 2.77 ^a	97.66 \pm 1.45 ^b	73.66 \pm 1.52 ^c
12 th	87.66 \pm 1.45 ^a	62.80 \pm 1.74 ^b	45.50 \pm 1.60 ^c
13 th	60.00 \pm 1.15 ^a	48.50 \pm 1.32 ^b	37.20 \pm 2.04 ^c
14 th	34.50 \pm 1.04 ^a	29.50 \pm 1.04 ^b	24.50 \pm 1.44 ^c

Mean within the same raw carrying different letters are significant at $P \leq 0.05$.

Means: Mean of 3 replicate (7 birds/ replicate)

(Mean \pm SE) \times 100

The probiotic usage (Gp 5) might decrease the ability of the parasite invasion into the enterocytes. Probiotic's organisms in the intestine can release products such as free radicals, hydrogen peroxide, short-chain fatty acids and other oxygen metabolites that adversely affect the intracellular stages thereby reducing their numbers [23]. These results coincides with the previously cited by author [24] who mentioned that *Pediococcus* and *Saccharomyces*-based probiotic given to birds challenged with *E. acervuline* or *E. tenella*, led to less oocyst excretion compared to non-treated controls.

The significant decreases in the oocysts count in toltrazuril treated group (Gp 6) from the 5th to the 14th day post-infestation can be explained as toltrazuril could pass through the host cell membrane and the cytoplasm causing destruction of intracellular stages (shizonts and gamonts) ensuring its use as a therapeutic coccidiocidal drug [4]. Similar results were previously reported by Roy *et al.* [25] who noticed a significant decrease in the fecal oocysts count in chickens infested orally with *E. tenella* sporulated oocysts and treated 24 hrs post-infestation with toltrazuril (1 ml/liter) for 2 days compared with infested non treated control.

Our result revealed that the probiotic or toltrazuril supplemented groups (Gps 2& 3) showed insignificant changes in the activities of serum ALT, AST and ALP compared with the normal control all over the experimental period (Tables 2 & 3). Similar results were previously obtained [26]. Hence, supplementation with the probiotic or toltrazuril in broiler's diet had no harmful effect on liver functions. Our results disagreed with Mondal *et al.* [27]. This discrepancy might be due to the variation in the species, dose, and route of administration.

The present study showed significant increase in the serum ALT, AST, and ALP activities in groups (4-6) at the end of the 3rd and 4th weeks compared with the normal control. Similarly, other reports indicated that

the liver function test of the infested broiler chickens with *Eimeria* spp. showed significant increase in the serum ALT and AST activities [28, 29]. They suggested that the significant damage of cell lining of the caecal wall along with their inflammation and severe blood loss causing tissue loss from the body may be attributed to the increase in AST activity. The elevated serum activities of ALP in the present study might be associated with the metabolic alteration and damage of the bone marrow for compensation of blood losses [30]. The bone marrow might be forced to produce excessive blood cellular components as previously reported [31].

The probiotic supplemented and *Eimeria* spp. infested group (Gp 5) showed significant decrease in the serum ALT, AST and ALP activities compared with infested non treated group (Gp 4). Similar results mentioned that broiler chicks infested with 1×10^5 sporulated oocysts of field strain *Eimeria* spp. at 8 days old and supplemented with a probiotic 1gm/L from one day old to 35 days old resulted in significant decrease in the serum ALT and AST activities at 35 days old compared with the infested non treated group [15]. These results may be attributed to probiotic appeared to help protect birds against the deleterious effect of coccidia [23].

Eimeria spp. infested quails and treated with toltrazuril (Gp 6) showed significant decrease in the serum ALT and AST activities compared with infested non treated group (Gp 4). Earlier studies recorded that 20 days old broiler chicks infested orally with 1×10^4 sporulated oocysts of *E. tenella* and treated with toltrazuril 1ml/L for 2 days resulted in a significant decrease in the serum ALT, AST and ALP activities compared with infested non treated group [32]. This indicated that toltrazuril induced elimination of coccidia contributed to the regeneration of mucosal membraned without causing hepatotoxic effects [33] and reflect the anticoccidial effect of toltrazuril.

Table (2): Impact on biochemical parameters (mean values \pm S.E) of quails in different groups at the end of the 3rd week (N=5).

Parameter	Gp 1	Gp 2	Gp 3	Gp 4	Gp 5	Gp 6
CHO(mg/dl)	191.01 \pm 1.70 ^a	162.03 \pm 1.26 ^c	190.85 \pm 1.26 ^a	156.25 \pm 1.00 ^d	158.44 \pm 1.91 ^d	170.24 \pm 1.09 ^b
TG(mg/dl)	130.13 \pm 1.91 ^a	103.12 \pm 1.11 ^c	129.64 \pm 1.75 ^a	99.89 \pm 1.70 ^d	101.05 \pm 1.01 ^{cd}	119.78 \pm 1.81 ^b
HDL(mg/dl)	75.69 \pm 1.02 ^a	76.52 \pm 1.60 ^a	74.71 \pm 1.52 ^a	51.48 \pm 1.64 ^d	53.83 \pm 1.57 ^c	67.29 \pm 1.65 ^b
ALT(U/L)	8.47 \pm 0.14 ^d	8.66 \pm 0.11 ^d	8.92 \pm 0.09 ^d	12.98 \pm 0.17 ^a	10.94 \pm 0.09 ^b	9.90 \pm 0.19 ^c
AST(U/L)	124.61 \pm 1.33 ^c	126.36 \pm 1.48 ^c	125.69 \pm 2.00 ^c	158.08 \pm 2.48 ^a	148.42 \pm 2.02 ^b	143.01 \pm 1.85 ^b
ALP(U/L)	49.38 \pm 0.61 ^d	48.52 \pm 0.56 ^d	48.73 \pm 0.47 ^d	95.48 \pm 1.12 ^a	81.35 \pm 1.09 ^b	75.94 \pm 0.95 ^c

Mean within the same raw carrying different letters are significant at $P \leq 0.05$. Gp1: apparently healthy quails as control group. Gp2: Probiotic supplemented quails. Gp3: Toltrazuril treated quails. Gp4: Eimeria spp. infested quails. Gp5: Probiotic supplemented and Eimeria spp infested quails. Gp6: Eimeria spp. infested and toltrazuril treated group. CHO: cholesterol, TG: triglycerides, HDL: high density lipoprotein, ALT: alanine aminotrasferase, AST: aspartate aminotransferase, ALP: alkaline phosphatase.

Table (3): Outcomes of biochemical parameters (mean values \pm S.E) of quails in different groups at the end of the 4th week (N=5)

Parameter	Gp 1	Gp 2	Gp 3	Gp 4	Gp 5	Gp 6
CHO(mg/dl)	206.76 \pm 0.80 ^a	158.95 \pm 3.03 ^c	204.46 \pm 1.44 ^a	162.77 \pm 1.84 ^c	160.43 \pm 1.17 ^c	176.36 \pm 1.13 ^b
TG(mg/dl)	140.12 \pm 1.05 ^a	106.57 \pm 1.54 ^c	137.73 \pm 1.00 ^a	104.80 \pm 0.98 ^c	105.11 \pm 1.95 ^c	130.42 \pm 1.46 ^b
HDL(mg/dl)	78.56 \pm 0.75 ^a	77.29 \pm 0.49 ^a	77.47 \pm 0.36 ^a	55.91 \pm 0.89 ^c	56.31 \pm 0.68 ^c	71.09 \pm 0.97 ^b
ALT(U/L)	10.00 \pm 0.15 ^d	9.95 \pm 0.21 ^d	10.21 \pm 0.10 ^d	14.41 \pm 0.52 ^a	12.34 \pm 0.53 ^b	11.30 \pm 0.08 ^c
AST(U/L)	112.46 \pm 2.16 ^d	111.84 \pm 1.98 ^d	115.46 \pm 1.91 ^d	146.98 \pm 1.37 ^a	133.28 \pm 1.25 ^b	124.07 \pm 1.44 ^c
ALP(U/L)	60.39 \pm 1.22 ^d	63.12 \pm 1.92 ^d	61.38 \pm 0.74 ^d	92.86 \pm 1.21 ^a	78.09 \pm 1.06 ^b	72.08 \pm 0.98 ^c

Mean within the same raw carrying different letters are significant at $P \leq 0.05$. Gp1: apparently healthy quails as control group. Gp2: Probiotic supplemented quails. Gp3: Toltrazuril treated quails. Gp4: Eimeria spp. infested quails. Gp5: Probiotic supplemented and Eimeria spp infested quails. Gp6: Eimeria spp. infested and toltrazuril treated group. CHO: cholesterol, TG: triglycerides, HDL: high density lipoprotein, ALT: alanine aminotrasferase, AST: aspartate aminotransferase, ALP: alkaline phosphatase.

Regarding the lipogram, quails in groups (2 & 5) showed significant decrease in the serum cholesterol and triglycerides compared with the control at the 3rd and 4th weeks of age (Tables 2 & 3). Our results supported some previous results [34]. The mechanism by which the probiotic decrease the total cholesterol and triglyceride may be attributed to its ability to deconjugate bile acids enzymatically using bile-salt hydrolase [35]. Probiotic's microorganisms suppress hydroxymethyl-glutaryl-coenzyme A, which is an enzyme necessary for cholesterol synthesis pathway thereby inhibit cholesterol synthesis [36].

Eimeria spp. infested quails (Gp 4) revealed significant decrease in the serum cholesterol, triglycerides and high-density lipoprotein all over the experimental periods (Table 4). These results were previously mentioned by several investigators [37, 38]. They concluded that the decreased parameters of lipid profile may be

attributed to anorexia and malabsorption of nutrients in broilers. Anorexia may be a major reason for decreased triglycerides level in coccidiosis infested birds. Another factor that may contribute the lipid metabolism disorder was the clinical anemia presented by the infested birds during the first two weeks post-infestation [39]. Addition of toltrazuril to healthy quails (Gp 3) had no significant effect on the serum cholesterol, triglycerides, and HDL compared with the control group (Gp 1). However, quails infested with Eimeria spp. and treated with toltrazuril 1ml/L for 2 successive days (Gp 6) showed significant increase in the serum cholesterol, triglycerides, and HDL compared with infested non treated group. Our results partially agreed with others who mentioned that intracrop inoculation of 8 days old broiler chicks with 1×10^5 sporulated oocysts of field strain of Eimeria spp. then treated with toltrazuril (7 mg/kg body weight in the drinking water) on the 14th and 15th days

post-infestation resulted in a significant increase in the serum cholesterol level compared with infested non treated group [15]. This reflects the anticoccidial effect of the drug. Our results showed that administration of the probiotic or toltrazuril to healthy quails (Gps 2 & 3) had no significant changes in the plasma catalase (CAT) and superoxide dismutase (SOD) activities all over the experimental period compared with the control. Our results agreed with Khodary [26]. Infested quails with *Eimeria* spp. (Gp 4) showed a significant increase in CAT activity with a significant decrease in SOD activity at the end of the 3rd and 4th weeks of the experiment compared with the normal control. Oxidative stress following the infection increased the use and weakened the protective effect of the antioxidant enzymatic system in chickens [26]. Similar results were also reported [40]. The reduced SOD activity may be due to the inactivation by interaction with oxygen radicals. Increased CAT activity may be a compensative mechanism to get rid of excess peroxides [41]. The compensatory elevation of CAT was due to impaired ecological oxidative balance following the oxidative stress [42] that probably occurred after the infestation of birds with *Eimeria* spp.

Eimeria spp. infested quails and supplemented with probiotic or treated with toltrazuril (Gps 5 & 6) showed a significant decrease in the plasma CAT activity with a significant increase in the plasma SOD activity at the 3rd and 4th week of the experiment compared with infested non treated group. These results reflect the antioxidant and anticoccidial effect of probiotic and toltrazuril. It is assumed that the anticoccidials prevented the activation of SOD by H₂O₂ which results from the dismutation of superoxide anion [43].

Similar results were found in the study of Mengistu *et al.* [44], who declared that the antioxidant capacity of chickens with coccidiosis was effectively elevated by probiotics. Also, this results coincides with that previously cited by Wang *et al.* [45] who found that 14 days old broiler chicks infested with 4 x 10⁴ sporulated oocysts of mixed *Eimeria* spp. and fed on diet supplemented with either probiotic 1 x 10⁸ CFU/g or diclazuril 5% (0.2 g/kg diet) resulted in a significant increase in the jejunum SOD activity at the end of the 1st and 4th week post-infestation compared with the infested non treated group.

Healthy quails supplemented with probiotic or treated with toltrazuril (Gps 2& 3) showed no significant changes on the plasma malondialdehyde (MDA) concentration compared with the normal control. This result agreed with the previous ones [46, 47]. However, administration of probiotic or toltrazuril to *Eimeria* spp. infested quails (Gps 5& 6) resulted in a significant decrease in the plasma MDA concentration compared with infested non treated group. Similar results were showed by author [45]. These results reflect the antioxidant and anticoccidial effects of probiotic and toltrazuril [15, 48].

Eimeriosis lead to oxidative stress in the infested quails which expressed by alterations in the antioxidant enzymes and increasing in the MDA concentration. The elevated MDA blood concentrations in infested quails (Gp 4) when compared with the control (Table 4) could be owing to the increased ROS production, which resulting in lipid peroxidation. The higher blood MDA concentration in infested birds is probably due to the oxidative stress occurring after infestation [40, 47, 49].

Table (4): Findings of serum antioxidant enzymes and lipid peroxidation (mean values ±S.E) of quails in different groups at different experimental periods (N=5).

	Parameter	Gp 1	Gp 2	Gp 3	Gp 4	Gp 5	Gp 6
3W	CAT(ng/ml)	5.68 ±0.47 ^c	5.55 ±0.65 ^c	6.00 ±0.53 ^c	14.30 ±0.40 ^a	9.58 ±0.54 ^b	10.20 ±0.47 ^b
	SOD(u/ml)	93.25 ±1.67 ^a	92.87 ±1.60 ^a	92.80 ±1.85 ^a	70.80 ±1.23 ^c	84.30 ±1.22 ^b	83.18 ±0.74 ^b
	MDA(ng/ml)	9.29 ±0.54 ^c	9.55 ±0.32 ^c	9.16 ±0.34 ^c	15.66 ±0.37 ^a	11.93 ±0.26 ^b	13.22 ±0.66 ^b
4W	CAT(ng/ml)	4.94 ±0.28 ^d	5.22 ±0.66 ^d	5.28 ±0.53 ^d	12.29 ±0.63 ^a	7.26 ±0.34 ^c	9.81 ±0.19 ^b
	SOD(u/ml)	80.81 ±1.23 ^a	81.38 ±0.48 ^a	81.54 ±0.89 ^a	63.38 ±0.87 ^c	76.17 ±0.78 ^b	76.36 ±0.68 ^b
	MDA(ng/ml)	7.39 ±0.65 ^d	7.54 ±0.35 ^d	7.27 ±0.26 ^d	13.52 ±0.65 ^a	9.20 ±0.20 ^c	10.93 ±0.77 ^b

Mean within the same raw carrying different letters are significant at $P \leq 0.05$. Gp1: apparently healthy quails as control group. Gp2: Probiotic supplemented quails. Gp3: Toltrazuril treated quails. Gp4: Eimeria spp. infested quails. Gp5: Probiotic supplemented and Eimeria spp infested quails. Gp6: Eimeria spp. infested and toltrazuril treated group. CAT: Catalase, SOD: Superoxide dismutase, MDA: Malondialdehyde.

Probiotic supplemented quails (Gp 2) showed insignificant changes in the cecal IFN- γ and IL-2 levels compared with the normal control (Table 5). This result partially disagreed with a pervious study [50], who mentioned that supplementation of one day old male arbor acres broiler chicks with 2gm/kg feed microencapsulated probiotic containing (*Enterococcus faecium* 1×10^8 CFU/g, *Lactobacillus palntarum* 1×10^9 CFU/g, *Bacillus subtilis* 1×10^9 CFU/g, β -mannose 250 u/g and fructo-oligosaccharide 250 mg/g) for 42 days resulted in a significant increase in the serum IL-2 at 21 and 42 days old compared with control. This discrepancy might be due to the differences in species, dose or strains of the used probiotic. However, quails supplemented with the probiotic and infested with Eimeria spp. (Gp 5) showed significant decrease in the cecal IFN- γ and IL-2 levels at the end of the 3rd and 4th weeks of the experiment compared with infested non treated group. Our results supported by Dalloul and Lillehoj [51] who reported that feeding of broilers with Lactobacillus containing diet and infection with *E. acervulina* resulted in immune-regulatory effect on the local immune system and improving in the broilers' resistance to *E. acervulina* infection.

Administration of toltrazuril (1ml/L) for 2 successive days to apparently healthy quails (Gp 3) had no significant changes in the cecal IFN- γ and IL-2 levels when compared with control. However, quails infested with Eimeria spp. and treated with toltrazuril (Gp 6) showed significant decrease in the cecal IFN- γ and IL-2 at the end of the 3rd and 4th week of the experiment compared with the infested non treated group (reach to the normal level at the end of the 4th week). This result reflected the effectiveness of the drug in controlling *Eimeria* infestation.

The obtained data revealed significant increase in the cecal INF- γ and IL-2 in Eimeria spp. infested quails (Gp 4) compared with control. These results provide the first direct evidence that chicken IFN- γ exerts an inhibitory effect against *Eimeria* and provides a rational basis for the use of this cytokine as a vaccine adjuvant against coccidiosis [52]. Interleukin-2 plays an important role in the function of the immune system. It is a powerful growth factor for a variety of cell types including T cell differentiation, B cell development and natural killer cell activation [53]. Our results agreed with these reported by many authors [54, 55].

Table (5): Results of immunological parameters (mean values \pm S.E) of quails in different groups at different experimental periods (N=5).

Parameter	Gp 1	Gp 2	Gp 3	Gp 4	Gp 5	Gp 6
3W INF- γ (pg/g tissue)	140.0 \pm 2.64 ^c	139.66 \pm 4.4 ^c	144.0 \pm 4.58 ^c	215.0 \pm 5.50 ^a	179.66 \pm 2.96 ^b	176.66 \pm 5.23 ^b
3W IL-2 (ng/g tissue)	3.47 \pm 0.52 ^c	3.07 \pm 0.46 ^c	3.54 \pm 1.00 ^c	15.91 \pm 1.18 ^a	9.03 \pm 1.13 ^b	9.22 \pm 0.39 ^b
4W INF- γ (pg/g tissue)	145.33 \pm 4.17 ^{cd}	140.33 \pm 2.33 ^d	143.0 \pm 4.04 ^d	179.33 \pm 4.70 ^a	163.33 \pm 2.33 ^b	154.66 \pm 3.17 ^{bc}
4W IL-2 (ng/g tissue)	3.11 \pm 0.90 ^c	3.42 \pm 0.36 ^c	3.75 \pm 0.88 ^c	11.09 \pm 1.37 ^a	6.98 \pm 0.51 ^b	5.16 \pm 0.13 ^{bc}

Mean within the same raw carrying different letters are significant at $P \leq 0.05$. Gp1: apparently healthy quails as control group. Gp2: Probiotic supplemented quails. Gp3: Toltrazuril treated quails. Gp4: Eimeria spp. infested quails. Gp5: Probiotic supplemented and Eimeria spp infested quails. Gp6: Eimeria spp. infested and toltrazuril treated group. INF- γ : interferon gamma, IL-2: Interleukin 2.

The microscopical lesions found by some researchers were in partial accordance with our findings, they found that parasitic infestation caused by *E. tsunodai* led to villus erosion, hyperplasia of the crypts of Lieberkuhn, granulocyte and mononuclear cell infiltration, as well as edema [56]. Also, earlier researchers studied infestations caused by three *Eimeria* species and reported hyperplasia of epithelial

cells, constriction of intestinal gland cavities in the small intestine and caecum, edema between muscle fibers, and inflammatory cell infiltration [57]. In our study, healthy quails treated with toltrazuril (Gp 3) showed partial desquamation of some intestinal villus tips with normal mucosal and sub mucosal tissue of the caecum and cecal tonsil (Figs. 1, 2 & 3). The gross lesions associated with *Eimeria* spp.

infestation in Japanese quails in our study were ballooning of the caeca with softening of the intestinal contents. Also, petechial hemorrhage on the intestinal serosa was noticed as shown in (Fig. 4). Microscopically, *Eimeria* spp. infested quails (Gp 4) showed severe intestinal inflammatory reaction with eosinophilic infiltration and denuded villi with heavy proliferation of *Eimeria* spp. at the end of the 3rd week of the experiment with few proliferative stages at the end of the 4th week (Figures 5, 6 & 7). Moreover, there was severe damage of the cecal mucosa caused by the proliferation of the parasites, meronts growth, and release of the merozoites with cystic dilation of the cecal tonsil submucosal gland (Figs. 8 & 9). Our results had a great

accordance with those reported in other previous studies [2, 58, 59].

As shown in Figs. (10, 11 & 12), supplementation of *Eimeria* spp. infested quails with probiotic (Gp 5) resulted in reduction of the lesion compared with infested non treated group (Gp 4). This result was attributed to the adverse effect of probiotic on the developmental stages of *Eimeria* spp. [15].

Quails of group (6) showed mild enteritis with minimal proliferative stages at the 3rd week which was disappeared completely at the 4th week of the experiment in some birds (Figs. 13, 14 & 15). Similar results were previously recorded and attributed these changes to the toltrazuril treatment effect [59].

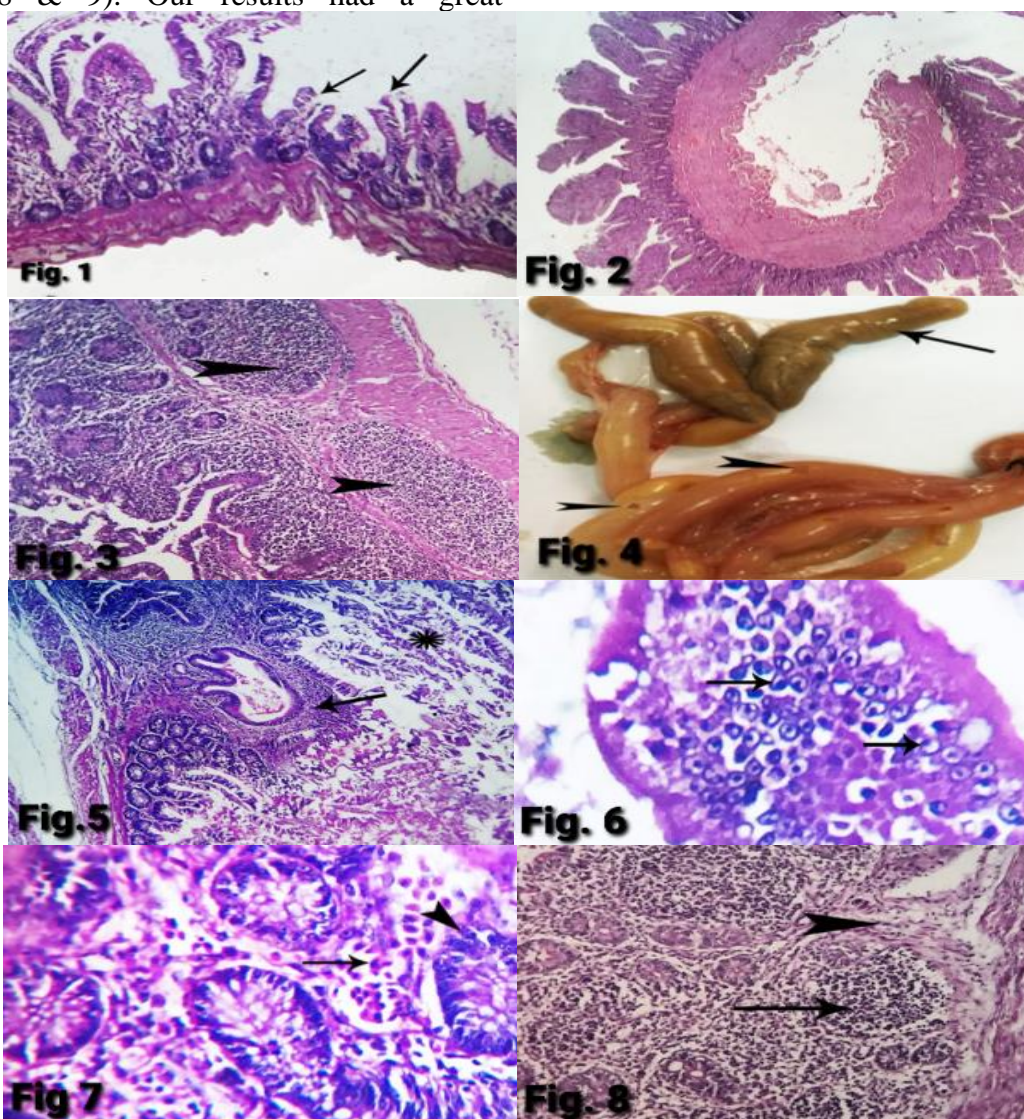


Plate 1: Photomicrograph of (Figure 1) small intestine of Gp (3) at the 4th week of experiment showing partial desquamation of some villus tips (arrows). (H&E x 400). (Fig. 2) caecum of Gp (3) at the 3rd week of experiment showing normal mucosal and submucosal tissues. (H&E x 200). (Fig. 3) cecal tonsil of Gp (3) at the 4th week of experiment showing normal mucosal and submucosal tissues with lymphoid nodules (arrow head). (Fig. 4) Enlarged ballooned caecum and cecal tonsil (arrow) with areas of petechial hemorrhages on the intestinal serosa of Gp (4) at the 4th week of experiment. (Fig. 5) small intestine of Gp (4) at the 3rd week of experiment showing perivascular inflammatory reaction with perivascular fibrosis and few eosinophils infiltration (arrow) in addition to denuded epithelium (star). (H&E x 400). (Fig. 6) small intestine of Gp (4) at 4th week of experiment

showing denuded villi with heavy proliferative stages of *Eimeria spp.* (arrows). (H&E x 1200). (Fig. 7) small intestine of Gp (4) at the 4th week of experiment showing submucosal extravasated erythrocytes (arrow) with few proliferative stages of *Eimeria spp.* (arrowhead). (H&E x 1200). (Fig. 8) caecum of Gp (4) at the 4th week of experiment showing focal fibrosis of submucosa (arrowhead) with lymphoid depletion from submucosal lymphatic tissue (arrow). (H&E x 400).

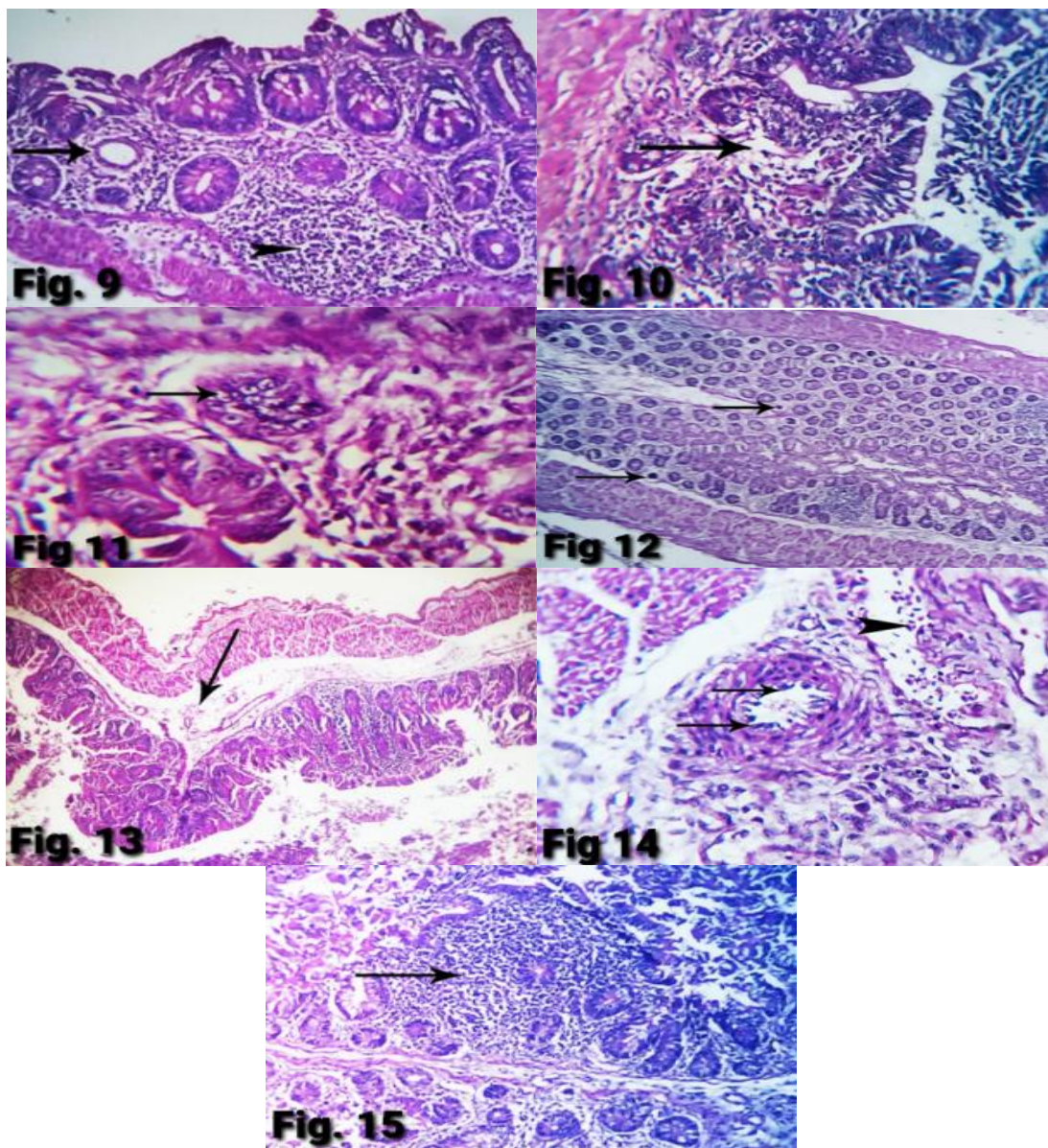


Plate 2: Photomicrograph of (Fig. 9) cecal tonsil of Gp (4) at the 4th week of experiment showing cystic dilation of submucosal gland (arrow) with lymphoid depletion from submucosal lymphatic tissue (arrowhead). (H&E x 400). (Fig. 10) small intestine of Gp (5) at the 4th week of experiment showing partial destruction of submucosa (arrow) with presence of minimal proliferative stages of *Eimeria spp.* (H&E x 400). (Fig. 11) caecum of Gp (5) at the 4th week of experiment showing focal area of proliferative stages of *Eimeria spp.* (arrow). (H&E x 1200). (Fig. 12) cecal tonsil of Gp (5) at the 4th week of experiment showing atrophy of some submucosal glands. (H&E x 200). (Fig. 13) small intestine of Gp (6) at the 3rd week of experiment showing edema under submucosa (arrow). (H&E x 400). (Fig. 14) caecum of Gp (6) at the 4th week of experiment showing endotheliosis of submucosal blood vessels (arrows) with mild extravasated erythrocytes (arrow head). (H&E x 1200). (Fig. 15) cecal tonsil of Gp (6) at the 4th week of experiment showing focal interglandular lymphocytic cells infiltration (arrow). (H&E x 400).

Conclusion

Probiotic can be used as a potential alternative anticoccidials in poultry to avoid

side effects of chemical and anticoccidial drugs such as anticoccidial residues and resistance. Moreover the addition of the used

probiotic (1 gm/L drinking water) was found to have a positive effect on coccidiosis and reduce the number of *Eimeria* oocysts and reduces the damage caused by free radicals and raise immunity.

Conflict of interest

All the authors declare that they have no competing interests.

Acknowledgment

The authors are happy to acknowledge Prof. Dr. Rehab Mowafy Chief. Researcher of pathology, Animal Health Research Institute, Zagazig for her great help in performing the histopathological study

References

- [1] Bashtar, A. R.; Abdel-ghaffar, F.; Al-Rasheid, K. A.; Mehlhorn, H. A. and Nasr, I. (2010): Light microscopic study on *Eimeria* species infecting Japanese quails reared in Saudi Arabian farms. *Parasitology Research*, 107(2): 409- 416.
- [2] Elmorsy, M. A.; Jena, G. R.; Panda, S. K.; Kundo, A. K.; Kumar, D.; Mishra, S. K.; Senapati, S. K.; Majhi, C.; Panda, S. K. and Das, M. R. (2020): Isolation, identification, and clinical impact of coccidiosis in Japanese quail farms in and around Bhubaneswar, Odisha, India. *Journal of Entomology and Zoology Studies*, 8(6): 302-307.
- [3] Simiyoon, L.; Arulmozhi, A. and Balasubramaniam, G. A. (2018): Pathology of caecal coccidiosis in Japanese quails. *International Journal of Science, Environment and Technology*, 7(1): 299- 302.
- [4] Mehlhorn, H.; Schmahl, G. and Haberkorn, A. (1988): Toltrazuril effective against a broad spectrum of protozoan parasites. *Parasitology Research*, 75 (1): 64-66.
- [5] Mehlhorn, H.; Ortmann-Falkenstein, G. and Haberkorn, A. (1984): The effects of sym. triazinones on developmental stages of *Eimeria tenella*, *E. maxima* and *E. acervulina*: a light and electron microscopical study. *Z. Parasitenkd*, 70(2):173–182.
- [6] Grief, G. (2000): Immunity to coccidiosis after treatment with toltrazuril. *Parasitology Research*, 86(10): 787-790.
- [7] Ramadan, A.; Abo El-Sooud, K. and El-Bahy, M. M. (1997): Anticoccidial efficacy of toltrazuril and halofuginone against *Eimeria tenella* infections in broiler chickens in Egypt. *Research in Veterinary Science*, 62(2): 175- 178.
- [8] [Sundar](#), S.; [Harikrishnan](#), T. J. and [Senthilkumar](#), T. (2017): Anticoccidial drug resistance in chicken coccidiosis and promising solution: A review. *Journal of Entomology and Zoology Studies*, 5(4): 1526-1529.
- [9] Odden, A.; Enemark, H. L.; Ruiz, A.; Robertson, L. J.; Ersdal, C.; Nes, S. K.; Tømmerberg, V. and Stuen S. (2018): Controlled efficacy trial confirming toltrazuril resistance in a field isolate of ovine *Eimeria* spp. *Parasites & Vectors*, 11(1): 1-11.
- [10] Noack, S.; Chapman, H. D. and Selzer, P. M. (2019): Anticoccidial drugs of the livestock industry. *Parasitology Research*, 118(7): 2009-2026.
- [11] Abdel-Rahman, W.; Mohnal, M.; Teichmann, K.; Doupovec, B.; Schatzmayr, G.; Lumpkins, B. and Mathis, G. (2014): Comparative evaluation of probiotic and salinomycin effects on performance and coccidiosis control in broiler chickens. *Poultry Science*, 93(12): 3002–3008.
- [12] Krysiak, K.; Konkol, D. and Korczyński, M. (2021): Overview of the use of probiotics in poultry production. *Animals (Basel)*, 11(6):1-24.
- [13] Hume, M. E.; Barbosa, N. A.; Dowd, S. E.; Sakomura, N. K.; Nalian, A. G.; Martynova-Van, K. A. and Oviedo-Rondon, E. O. (2011): Use of pyrosequencing and denaturing gradient gel electrophoresis to examine the effects of probiotics and

- essential oil blends on digestive microflora in broilers under mixed *Eimeria* infection. Foodborne Pathogens and Disease, 8(11):1159–1167.
- [14] Ritzi, M.; Abdelrahman, W.; Mohnl, M. and Dalloul, R. (2014): Effects of probiotics and application methods on performance and response of broiler chickens to an *Eimeria* challenge. Poultry Science, 93(11): 2772- 2778.
- [15] El-Khouly, M. A.; Khairy, M. H.; Abd-El Alim, A. F. and Ali, A. M. (2016): Effect of phytobiotics, probiotics and toltrazuril on chicken coccidiosis. Zagazig Veterinary Journal, 44(3): 214-223
- [16] El-Morsy, M. A.; Abou El-Azm, K. I. and Awad, S. S. (2016): Efficacy of some anticoccidial drugs on experimentally induced cecal coccidiosis (*E.tsunodai*) in Japanese quails. Egypt Journal of Veterinary Science, 47(2): 165-177.
- [17] Conway, D. P. and McKenzie, M. E. (1991): Poultry Coccidiosis: Diagnostic and testing procedure. 2nd ed. Chapter 2, 17-36.
- [18] Pappas, N. (1989): Enhanced cardiac enzyme profile. Clinics in Laboratory Medicine. 9(4): 689-716.
- [19] Tietz, N. (1995): Clinical guide to laboratory tests 3rd edition. WB Saunders, Philadelphia, 306-309.
- [20] Lee, S.; Kim, C.; Kim, J.; Shin, H. and Baik, J. (2008): Gallocatechin gallate rich tea catechins are effective in lowering cholesterol and triglycerides concentrations in hyperlipimic rats. Lipids, 43(5): 419-429.
- [21] Bancroft, J. D. and Gamble, M. (2008): Theory and Practice of Histological Techniques. 5th Ed., Churchill Livingstone. New York, London, Philadelphia.
- [22] Norusis M (2008): SPSS 16.0 Statistical Procedure Comparison Prentice Hall Press Upper Saddle River, NJ, USA, 648.
- [23] Abd alla, A. M.; Abd Alla, O. A.; Emad, W. G.; Abdo, W. and Fatma, F. M. (2013): Efficacy of probiotic on intestinal coccidiosis in infected broilers: hematological, biochemical and pathological studies. Kafrelsheikh Veterinary Medicine Journal, 11(2): 175-202.
- [24] Lee, S. H.; Lillehoj, H. S.; Dalloul, R. A.; Park, D. W. and Hong, Y. H. (2007): Influence of *Pediococcus* based probiotic on coccidiosis in broiler chickens. Poultry Science, 86(1): 63-66.
- [25] Roy, R.; Hasan, M. M.; Aziz, F. B.; Islam. R. and Sarkar, S. (2020): Comparative study of neem leaf (*Azadirachta indica*) suspension and toltrazuril against coccidiosis in Sonali chicken. Bangladesh Journal of Veterinary Medicine, 17(2): 79-105.
- [26] Khodary, M. R. (2011): Clinicopathological studies on the effect marbofloxacin in quails. M.V.Sc. Thesis (Clinical Pathology), Faculty of Veterinary Medicine Zagazig University.
- [27] Abdallah, R. A. (2017): Evaluation of toltrazuril as anticoccidial drug in broilers. Master Thesis (Department of pharmacology), Faculty of Veterinary Medicine Zagazig University.
- [28] Patra, G.; Khan, M. d.; Ayub, A.; Chanu, V.; Jonathan, L.; Joy, L. K.; Prava, M.; Ravindran, R.; Das, G. and Inaotombi, D. L. (2010): PCR based diagnosis of *Eimeria tenella* infection in broiler chicken. International Journal of Poultry Science, 9(8): 813-818.
- [29] Mondal, D. K.; Chattopadhyay, S.; Batabyal, S.; Bera, A. K. and Bhattacharya, D. (2011): Plasma biochemical indices at various stages of infection with a field isolate of *Eimera tenella* in broiler chicken. Veterinary World, 4(9): 404- 409.
- [30] Hirani, N. D.; Hasnani, J. J.; Pandya, S. S. and Madhira, S. P. (2018): Biochemical changes in induced cecal

- coccidiosis in broiler birds given different feed anticoccidial at Anand, Gujarat, India. *International Journal of Current Microbiology and Applied Science*, 7(7): 1044-1051.
- [31] Adamu, M.; Boonkaewwan, C.; Gongruttananun, N. and Vongpakorn, M. (2013): Hematological, biochemical and histopathological changes caused by coccidiosis in chickens. *Kasetsart Journal (Natural Science)*, 47(2): 238-246.
- [32] Youssef, F. M.; Abd El Hamid, H. A. and El-sheshtawy, A. F. (2015): Clinicopathological studies on the effect of *Artemisia cina* (Sheih Baladi) on coccidiosis in chickens. *The Egyptian Journal of Veterinary Sciences*, 46 (1): 11-24.
- [33] Soliman, E. A. (2016): Effect of propolis and toltrazuril on coccidiosis in broilers. Master Thesis (Department of pharmacology), Faculty of Veterinary Medicine Zagazig University.
- [34] Haque, M. I.; Ahmad, N. and Miah, M. A. (2017): Comparative analysis of body weight and serum biochemistry in broilers supplemented with some selected probiotics and antibiotic growth promoters. *Journal of Advanced Veterinary and Animal Research*, 4(3):288- 294.
- [35] Surono, I. S. (2003): In vitro probiotic properties of indigenous Dadhi lactic acid bacteria. *Asian-Australian Journal of Animal Science*, 16(5): 726-731.
- [36] Fukushima, M. and Nakano, M. (1995): The effect of probiotic on faecal and liver lipid classes in rats. *British Journal of Nutrition*, 73(5): 701-710.
- [37] Abd El-Maksoud, H. A.; Afaf, D. A. and El-Badry, M. A. (2014): Biochemical effect of coccidian infestation in laying hen. *Benha Veterinary Medical Journal*, 26(1): 127- 133.
- [38] Ali, M. A.; Hanem, F. K.; Shaker, A. S. and Mai, O. N. (2015): Comparative efficacy of symbiotic and diclazuril on broilers experimentally infected with *Eimeria acervulina*. *Assuit Veterinary Medical Journal*, 61(146): 24- 33.
- [39] Freitas, F. L.; Almeida, K. S.; Machado, R. Z. and Machado, C. R. (2008): Lipid and glucose metabolism of broilers (*Gallus gallus domesticus*) experiment infected with *Eimeria acervulina*. *Brazilian Journal of Poultry Science*, 10(3): 157-162.
- [40] Pajic, M.; Aleksic, N.; Vejnovic, B.; Polacek, V.; Novakov, N.; Andric, D. O. and Stanimirovic, Z. (2019): Influence of anticoccidials on oxidative stress, production performance and faecal oocyst counts in broiler chickens infected with *Eimeria* species. *Kafkas Universitesi Veteriner Fakultesi Dergisi*, 25(3): 379-385.
- [41] Abuja, P. M. and Albertini, R. (2001): Methods for monitoring oxidative stress, lipid peroxidation and oxidation resistance of lipoproteins. *Clinica Chimica Acta*, 306(1-2): 1-17.
- [42] Georgieva, N. V. (2005): Oxidative stress as a factor of disruption of the ecological oxidative balance in biological systems-a review *Bulgarian Journal of veterinary medicine*, 8(1): 1-11.
- [43] Nikolić-Kokić, A.; Blagojević, D. and Spasić, M. B. (2010): Complexity of free radical metabolism in human erythrocytes. *Journal of Medical Biochemistry*, 29 (3): 189-195.
- [44] Mengistu, B. M.; Bitsue, H. K. and Huang, K. (2021): The effects of selenium enriched probiotics on growth performance, oocysts shedding, intestinal cecal lesion scores, antioxidant capacity, and mRNA gene expression in chickens infected with *Eimeria tenella*. *Biological Trace Element Research*, 199(1): 278- 291.
- [45] Wang, Y.; Lv, X.; Li, X.; Zhao, J.; Zhang, K.; Hao, X.; Liu, K. and Liu, H. (2021): Protective effect of *Lactobacillus plantarum* (P8) on growth performance, intestinal health

- and microbiota in *Eimeria* infected broiler. *Frontiers in Microbiology*, 12:1-15
- [46] Aluwong, T.; Kawu, M.; Raji, M.; Dzenda, T.; Govwang, F.; Sinkalu, V. and Ayo, J. (2013): Effect of yeast probiotic on growth, antioxidant enzyme activities and malondialdehyde concentration of broiler chicks. *Antioxidants (Basal)*, 2(4): 326- 339.
- [47] Eraslan, G.; Cam, Y.; Eren, M. and Liman, B. C. (2004): Changes in malondialdehyde level and catalase activity and effect of toltrazuril on these parameters in chicks infected with *Eimeria tenella*. *Bullten Veterinary Instiute in Pulawy*, 48(3): 251-254.
- [48] Mathis, G. F.; Froyman, R. and Kennedy, T. (2004): Coccidiosis control by administering toltrazuril in the drinking water for a 2-day period. *Veterinary Parasitology*, 121(1-2): 1-9.
- [49] Koinarski, V.; Georgieva, N.; Gadjeva, V. and Petkov, P. (2005): Antioxidant status of broiler chickens infected with *Eimeria acervulina*. *Revue de Medicine Veterinaire*, 156(10): 498-502.
- [50] Wang, Y.; Dong, Z.; Song, D.; Zhou, H.; Wang, W.; Miao, H.; Wang, L. and Li, A. (2018): Effects of microencapsulated probiotics and prebiotics on growth performance, antioxidative abilities, immune functions, and caecal microflora in broiler chickens. *Food and Agriculture Immunology*, 29(1): 859-869.
- [51] Dalloul, R. A. and Lillehoj, H. S. (2005): Recent advances in immunomodulation and vaccination strategies against coccidiosis. *Avian Diseases*, 49(1): 1-8.
- [52] Lillehoj, H. S.; Min, W. and Dalloul, R. A. (2004): Recent progress on the cytokine regulation of intestinal immune responses to *Eimeria*. *Poultry Science*, 38(4): 611-623.
- [53] Lillehoj, H. S.; Kaspers, B.; Jenkins, M. C. and Lillehoj, E. P. (1992): Avian interferon and interleukin-2. A review by comparison with mammalian homologues. *Poultry Science*, 4(2):67-85.
- [54] Hong, Y. H.; Lillehoj, H. S.; Lee, S. H.; Dalloul, R. A. and Lillehoj, E. P. (2006): Analysis of chicken cytokine and chemokine gene expression following *Eimeria acervulina* and *Eimeria tenella* infections. *Veterinary Immunology and Immunopathology*, 114(3-4): 209 -223.
- [55] Davou, K. P.; Lawal, I.; Joseph, A.; Lawal, S.; Karaye, G.; Patrobas, M.; Markus, B.; Ayinzat, F. S.; Christopher, D. and Karaye, K. (2018): T- lymphocytes response to caecal coccidiosis in broilers infected with exo and endogenous stages of *Eimeria tenella*. *SOJ Immunology*, 6(1): 1-6.
- [56] Teixeira, M.; Teixeira, F. W. and Lopes, C. W. (2004): Coccidiosis in Japanese quails (*Coturnix Japonica*): Characterization of a naturally occurring infection in a commercial rearing farm. *Brazilian Journal of Poultry Science*, 6(2): 129- 134.
- [57] Mohammad, N. H. (2012): A study of the pathological and diagnosis of *Eimeria* species infection in Japanese quails. *Basrah Journal of Veterinary Research*, 11(1): 318- 333.
- [58] Umar, H. A.; Lawal, I. A.; Okubanjo, O. O. and Wakawa, A. (2014): Morphometric identification, gross and histopathological lesions of *Eimeria* species in Japanese quails (*Coturnix japonica*) in Zaria. *Nigeria Journal of Veterinary Medicine*, 1-6.
- [59] Hussein, S. H.; Soad, M.; Mervat, A. A.; Gehan, N. A. and Rania, A. A. (2021): Comparative biochemical and pathological studies between toltrazuril and garlic supplementation in chickens experimentally infected with coccidiosis. *Egyptian Journal of Animal Health*, 1(1): 65-80.

الملخص العربي

دراسات مقارنة على تأثير البروبيوتيك والتولترازوريل في مقاومة الكوكسيديا في السمان
نصر عبد الوهاب محمد نصر الدين¹، شيماء أحمد عبد الفتاح اسماعيل¹ ، سحر سمير عبد الحميد²
أسماء نبيل سليم كاسر³

1 قسم الباثولوجيا الاكلينيكية- كلية الطب البيطري- جامعة الزقازيق-مصر
2 قسم الباثولوجيا الاكلينيكية- معهد بحوث الصحة الحيوانية- الزقازيق-مصر
3 المعمل الرجعي للرقابة البيطرية على الإنتاج الداجنى- معهد بحوث الصحة الحيوانية- الزقازيق-مصر

اجريت هذه الدراسة للمقارنة بين تأثير البروبيوتيك (جرو-2-ماكس) و مضاد الكوكسيديا التولترازوريل فى الوقاية من الكوكسيديا وكذلك لفحص تأثيرهما على بعض العوامل الكيميائية بالدم والإنزيمات المضادة للأكسدة وبعض المعاملات المناعية فى السمان. أجريت التجربة على 126 فرخ سمان عمر يوم واحد حيث قسمت الى ست مجموعات متساوية تم معاملتها كالتالى: المجموعة الأولى : تركت بدون معالجة كمجموعة ضابطة للتجربة. المجموعة الثانية: تم اضافة البروبيوتك الى ماء الشرب (1 جم/ لتر ماء شرب) من عمر يوم وحتى 28 يوم. المجموعة الثالثة: تم اضافة التولترازوريل عند عمر 16 يوم بمعدل 25 جزء من المليون (1 جم/لتر ماء شرب). المجموعة الرابعة : تم إجراء عدوى تجريبية لها داخل الحوصلة بجرعة 4.1×10⁴ حويصلة متجرثمة من الأيميريا الحقلية عند عمر 14 يوم. المجموعة الخامسة : تم اضافة البروبيوتك الى ماء الشرب (1 جم/ لتر ماء شرب) من عمر يوم وحتى 28 يوم و تم إجراء عدوى تجريبية لها داخل الحوصلة بجرعة 4.1×10⁴ حويصلة متجرثمة من الأيميريا الحقلية عند عمر 14 يوم. المجموعة السادسة : تم إجراء عدوى تجريبية لها داخل الحوصلة بجرعة 4.1×10⁴ حويصلة متجرثمة من الأيميريا الحقلية عند عمر 14 يوم ثم عولجت بالتولترازوريل عند عمر 16 يوم بمعدل 25 جزء من المليون (1 جم/لتر ماء شرب) لمدة يومين متتاليين. قلل استخدام البروبيوتيك نسبيا من معدل الإصابة وعدد حويصلات الكوكسيديا. بالاضافة الى ذلك هناك تحسن فى المناعة الخلوية والانزيمات المضادة للاكسدة. نستخلص من ذلك ان البروبيوتيك له تأثير إيجابى على الكوكسيديا وقلل عدد حويصلات الكوكسيديا وقلل الضرر الناتج عن الجذور الحرة ورافعا للمناعة.