

EVALUATION OF BREAST CANCER RISK WITH SUPPLEMENTARY ULTRASONOGRAPHY TO CHARACTERIZE PALPABLE LUMPS IN MAMMOGRAPHICALLY DENSE BREASTS

By

**Mostafa Rabei Kamel, Ahmed Abd Al-Fattah Ahmed Mostafa and
Mohammed Nader Hashim Taweela**

Department of General Surgery, Faculty of Medicine, Al-Azhar University, Cairo, Egypt

Corresponding author: Mostafa Rabei Kamel,

Phone: (+20)1119564501, (+20)1090600115, **E-mail:** mostafarabei2016@gmail.com

ABSTRACT

Background: Breast lumps are one of the common problems encountered in women. These lumps are frequently seen in younger to middle aged women and often they go undetected for various reasons. These lumps have different etiologic causes and can be either benign or malignant.

Objective: To evaluate prediction of pathological type of different breast lesions, and the sensitivity and specificity of BI-RADS Scoring system using a modified triple test.

Patients and methods: This prospective observational study included fifty patients complaining of palpable breast masses came to Department of Surgery Al-Azhar University Hospitals (Al-Hussein and Bab Al-Sha'reia University Hospitals), Each patient underwent a modified triple test which included a complete clinical examination, next was the mammography and ultrasound examination of the breast mass, and finally fine needle aspiration of the breast lump was made. Based on each test, the palpable breast lumps were classified as benign, malignant or inconclusive. Then investigate, how accurately using the BI-RADS assessment categories for diagnosing breast cancer, Data of the study were collected during the period from July 2018 to June 2019 for analysis by statistical program SPSS, then Microsoft Excel sheets were used to graph the results and integrated into Microsoft Word.

Results: Clinical examination had sensitivity of 86.34 % and specificity of 91% for the detection of malignancy. Positive predictive value of clinical examination was 85%, and negative predictive value was 84.42%. Ultrasound findings suggestive of malignancy had biopsy proven malignancy. Ultrasound had a sensitivity of 86.84% and specificity of 100% for the detection of malignancy, Positive predictive value for detection of malignancy was 100%, Negative predictive value to rule out malignancy was 92.86%. By Using modified triple test, 18 patients (36%) had features suggestive of malignant disease, and 32 patients (64%) were suspected to have benign breast disease. All of the 18 patients suspected to have malignancy on Modified Triple Test were biopsy proven to have malignant breast disease.

Conclusion: Modified Triple Test had a sensitivity, specificity, positive predictive value and negative predictive value of 97.36%, 100%, 100% and 98.48% .respectively. Benign cases can be safely followed up without further procedure (open biopsy) that avoiding the surgical morbidity and scar, and also those found to be malignant on Modified Triple Test can directly proceed to definitive surgical management.

Keywords: Breast Imaging Reporting and Data System (BI-RADS), Modified Triple Test (MTT), dense breast, Ultrasound, Breast cancer.

INTRODUCTION

Breast cancer is the most common cancer among women in the world; 1.7 million new cases were diagnosed in 2012 (*Beagle et al., 2015*).

There are more awareness campaigns, screening programmes and imaging tools available to the public to detect breast cancer in its early stages. Mammography is the 'gold standard' for detecting breast cancer in its early stages. It has been proved that mammography reduces the breast cancer mortality rate (*Copeland et al., 2015*).

The American College of Radiology (ACR) developed the Breast Imaging Reporting and Data system (BI-RADS). It is an internationally accepted method of assessing and reporting on mammogram and breast ultrasound images. The BI-RADS consists of final assessment categories according to the mammographic and ultrasound findings. The BI-RADS includes various descriptors for mammographic and breast ultrasound images as well as a reporting structure that involves assessment categories. These descriptors are also known as the mammography and ultrasound lexicon. BI-RADS standardizes breast imaging reporting and helps to predict the likelihood of malignancy (*Shetty et al., 2013*).

The present work aimed to evaluate prediction of pathological type of different breast lesions, and the sensitivity and specificity of BI-RADS Scoring system using a modified triple test.

PATIENTS AND METHODS

This prospective observational study included fifty patients complaining of palpable breast masses came to Department of Surgery Al-Azhar University Hospitals (Al-Husseen and Bab Al-Sha'reia University Hospitals), during the period From July 2018 to June 2019, Each patient underwent a modified triple test which included a complete clinical examination, the mammography and ultrasound examination of the breast mass and finally fine needle aspiration of the breast lump was made. Based on each test, the palpable breast lumps were classified as benign, malignant or inconclusive.

Inclusion criteria: Female patients with age of > 20 years with palpable breast lump and patient willing for lump excision.

Exclusion criteria: Patients who were below 20 years, female patients with advanced disease which made the diagnosis obvious, male patients, patients not willing for lump excision.

Statistical Analysis: The results of the modified triple test were analyzed individually and collectively, a computer statistical package SPSS version 20, finally the result was compared to Histopathological diagnosis. The statistical program SPSS was used to analyze the data of this study, then Microsoft Excel sheets used to graph the results and integrated into Microsoft Word, p-value ≤ 0.05 was considered significant, chi square test, predictive values, sensitivity, and specificity were calculated.

RESULTS

Clinical examination alone has a sensitivity of 86%, but when combined with USG and FNAC the overall sensitivity rose to 100%. Ultrasound examination has a high sensitivity of 100%, and hence was a reliable method

that can be used for screening of breast lump. Among the three components fine needle aspiration cytology was highly accurate with a specificity and positive predictive value of 100% (**Figure 1** and **Table 1**).

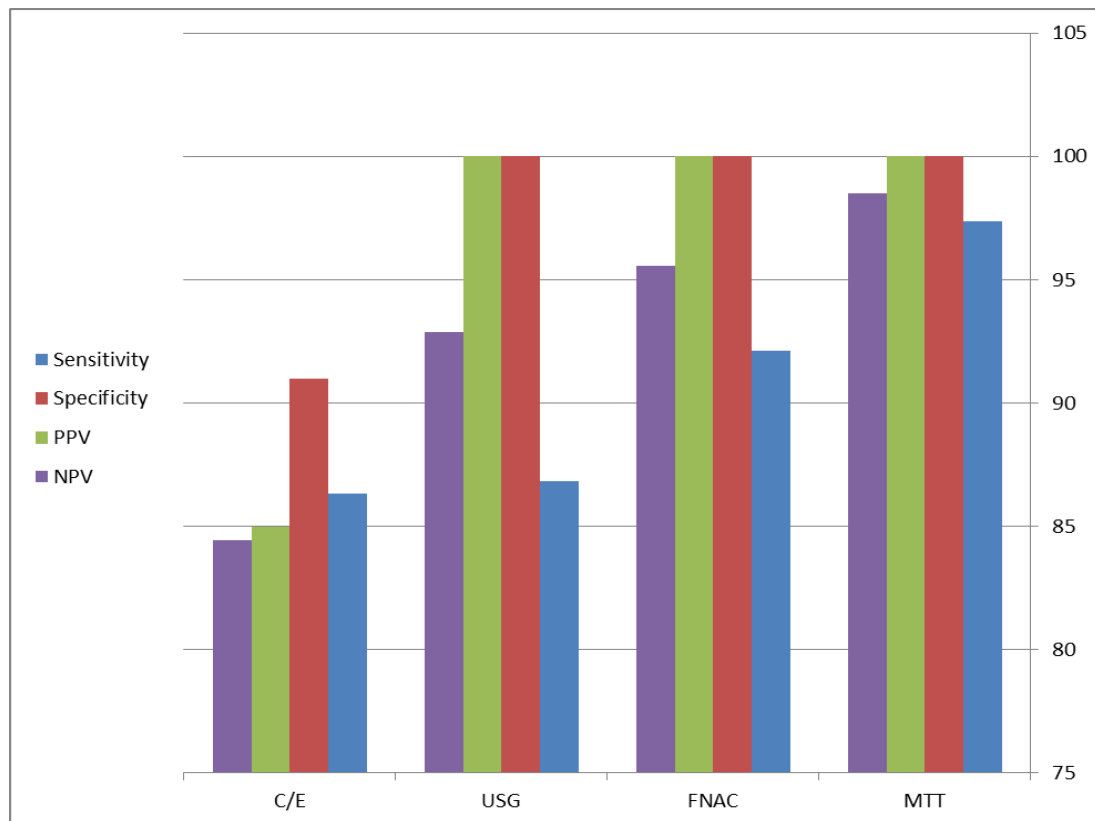


Figure (1): Individual component and combined results of Modified Triple test

PPV: positive predictive value
 NPV: negative predictive value

Table(1): Individual component and Combined Results of Modified Triple Test

Parameters \ Test	C/E	USG	FNAC	MTT
Sensitivity	86.34	86.84	92.10	97.36
Specificity	91	100	100	100
PPV	85	100	100	100
NPV	84.42	92.86	95.58	98.48

In the present study, 30 patients out of 50 (60%) had ultrasound features suggestive of benign breast lumps, and 16 out of 50 (32%) had features of malignancy, Four (8%) patients out of 50 had inconclusive features. Of the ultrasonographically suggested benign disease, all of them had benign disease by histopathology, and all the ultrasonographically suspected malignant lesions were proven by biopsy to be

malignant, of the remaining 4 inconclusive lesions by ultrasound 50% were found to have malignant disease. Sensitivity and specificity of ultrasonogram for the detection of malignancy was 86.84 %, and 100 % respectively. Positive predictive value for detection of malignancy was 100%, Negative predictive value to rule out malignancy was 92.86% (**Table 2**).

Table(2): Ultrasonogram test

USG Finding \ Test	Malignant	Benign
Malignant	16	0
Benign	0	30
Inconclusive	2	2
P VALUE - 0.001		
SIGNIFICANT		

DISCUSSION

When the clinical examination findings were examined as a whole clinical examination had sensitivity of 86.34 % and specificity of 91% for the detection of malignancy. Positive predictive value of Clinical examination was 85% and Negative predictive value was 92.19% (*Baykara et al., 2013*).

In the present study, (85%) of patients with hard lumps which were clinically suggested as malignant turned out to be malignant, whereas (15%) with hard lumps had benign disease (15%), sixty two of patients had lumps with firm consistency suggestive of benign lesions of them, (3.2%) had malignancy and (3.2%) patients had lumps with firm to hard in consistency of which all of them were malignant. Clinical examination had a sensitivity of 86.34 % and specificity of 91% for the detection of malignancy. Positive predictive value of Clinical

examination was 85% and negative predictive value was 92.19 %.

Pain over the lump was an important symptom and 60% of patients with painless lumps had malignancy on histopathological examination in contrast to 15 % of the patients with painful breast lumps. The usual mode of presentation of malignancy was a painless palpable lump (*Jin Young et al., 2016*).

In the present study, the upper outer quadrant was commonly involved with tumor (45.6%).It has been demonstrated that the upper outer quadrant of the breast has more amount of epithelial tissue compared to other quadrants leading to more incidence of tumors (*Jaykar et al., 2013*).

Of the clinical examination findings nipple discharge was also found to be an important finding. Of the patients with nipple discharge 77% (17 out of 22) were found to have malignancy on final

histopathological diagnosis, so nipple discharge might serve as an important clue to the diagnosis of malignancy, but many studies have shown that nipple discharge is usually benign and 10 to 15% of the patients with nipple discharge tend to have malignancy (*Van Zee et al., 2016*).

The application of the breast Imaging Reporting and Data System (BI-RADS) final assessment System in Sonography of palpable breast Lesions and reconsideration of the Modified Triple Test in this study they followed up 160 palpable breast lesions and subjected the lesions to guided FNAC, sonography, and then histopathologic confirmation. It was shown in this study that ultrasonography of breast was as accurate as guided fine needle aspiration for not missing the diagnosis of malignancy (*Kumar et al., 2017*).

CONCLUSION

Benign cases can be safely followed up without further Procedure (open biopsy) that avoiding the surgical morbidity and scar, and also those found to be malignant on Modified Triple Test can directly proceed to definitive surgical management.

REFERENCES

1. **Baykara M, Ozkan Zp, Gul Y, Aslan O and Gungo L. (2013):** Effectiveness of the Triple Test and Its Alternatives for Breast Mass Evaluation, *J Breast Health*, (87)41:252-256.
2. **Beagle G, Katherine M, Rodney F, Morris P, Alderemar W, Schmid T and Alexander P. (2015):** Usefulness of the triple test scores for palpable breast masses. *Archive of Surgery*, 13(6):1008-1013.
3. **Copeland E, Bland K and Beenken S. (2015):** The Breast Schwartz's Principles of Surgery Charles F. Brunnicardi, pbl. McGraw Hill, 4 (15): 485-489.
4. **Jin Young K, Eun K, Hai-Lin P and Ji-Young K. (2016):** Application of the Breast Imaging Reporting and Data System Final Assessment System in Sonography of Palpable Breast Lesions and Reconsideration of the Modified Triple Test, *J ultrasound Med*, 25(12):1255–1261.
5. **Jaykar R, Kasbe P and Pargaonkar R. (2013):** A Study of Modified Triple Test Score for Assessment of Palpable Breast Masses in Young Females. *International Journal of Recent Trends in Science And Technology*, 4(25):63-68.
6. **Kumar M, Fausto D and Mitchell R. (2017):** Basic pathology, 8th edition, Elsevier Saunders, 06(09):742-749.
7. **Shetty MK, Shah YP and Sharman RS. (2013):** Prospective evaluation of the value of combined mammographic and sonographic assessment in patients with palpable abnormalities of the breast, *J ultrasound Med*, 22(12):263-268.
8. **Van Zee, Pérez O and Einnard M. (2016):** Preoperative galactography increases the diagnostic yield of major duct excision for nipple discharge Cancer, 82(10):1874-1876.

تقييم خطر الإصابة بسرطان الثدي بالموجات فوق الصوتية التكميلية لوصف كتل محسوسة فى ماموجرام الثدي الكثيف

مصطفى ربيع كامل، أحمد عبد الفتاح أحمد مصطفى، محمد نادر هاشم طويلة

قسم الجراحة العامة، كلية الطب، جامعة الأزهر، القاهرة، مصر

E-mail: mostafarabei2016@gmail.com

خلفية البحث: تعد أورام الثدي من المشكلات الشائعة التي تواجه النساء. غالبًا ما تُرى هذه الكتل لدى النساء الأصغر سنًا إلى متوسطات العمر وغالبًا ما يتم اكتشافها لأسباب مختلفة. وهذه الكتل لها عدة أسباب مختلفة ويمكن أن تكون إما حميدة أو خبيثة.

الهدف من البحث: لتقييم التنبؤ بالنوع المرضي لآفات الثدي المختلفة وحساسية ونوعية نظام تصوير الثدي والبيانات باستخدام اختبار الثلاثي المعدل.

المريضات و طرق البحث: تم إجراء هذه الدراسة بمستشفيات جامعة الأزهر (مستشفى الحسين الجامعي و مستشفى باب الشعرية الجامعي) على خمسين مريضة تعانين من أورام بالثدي وذلك في الفترة من يوليو 2018 و حتى يونيو 2019 حيث خضعت كل مريض لإختبار ثلاثي معدل وقد شمل الفحص السريري الكامل ثم تم إجراء فحص بالموجات فوق الصوتية والماموجرام، وأخيراً تم أخذ عينة من أورام الثدي بالإبرة الدقيقة، وبناءً على كل اختبار تم تصنيف الكتل الظاهرة على أنها حميدة، خبيثة أو غير حاسمة. ثم تحقق من مدى دقة استخدام فئات تقييم نظام تصوير الثدي والبيانات لتشخيص سرطان الثدي.

نتائج البحث: عندما تم إحصاء نتائج الفحص الإكلينيكي إجمالاً كانت حساسية الفحص السريري 86.34% وبنسبة خصوصية 91% و القيمة التنبؤية الإيجابية للفحص السريري 85% والقيمة التنبؤية السلبية 84.42% للكشف عن الورم الخبيث. ومن بين جميع المرضى التي أثبتت الإبرة الدقيقة أنهم يعانون من ورم خبيث كانت حساسية الموجات فوق الصوتية لهؤلاء المرضى لإكتشاف الورم الخبيث 86.84% وبنسبة خصوصية 100% وكانت القيمة التنبؤية الإيجابية للكشف عن الأورام الخبيثة 100% والقيمة التنبؤية السلبية لإستبعاد الورم الخبيث

92.86% وبإستخدام الإختبار الثلاثى المعدل 18 مريضاً (36%) كان لديهم سمات توحى بمرض خبيث و 32 مريضاً (64%) يشتبه فى إصابتهم بأمراض الثدي الحميدة. وحينما تم أخذ عينة من هؤلاء المريضات المشتبه فى إصابتهم بورم خبيث بإستخدام الإختبار الثلاثى المعدل تبين أن هؤلاء المرضى يعانون بالفعل من أورام خبيثة بالثدى.

الاستنتاج: أشارت نتائج هذه الدراسة إلى أن حساسية الإختبار الثلاثى المعدل لإكتشاف الأورام الخبيثة بالثدى تصل إلى 97.36% وبنسبة تخصصية 100% وقيمة تنبؤية إيجابية بنسبة 100% وقيمة تنبؤية سلبية بنسبة 98.48%. من خلال نتائج الدراسة المتاحة، و يمكن متابعة حالات الأورام الحميدة بأمان دون الحاجة لأخذ عينة جراحية لتجنب مخاطر التدخل الجراحى والندبات. أما هؤلاء اللاتي أثبت الإختبار الثلاثى المعدل من أنهن يعانين من أورام خبيثة بالثدى يتم تحويلهم إلى إجراء التدخل الجراحى المناسب مباشرة.

الكلمات الدالة: نظام تصوير الثدي والبيانات، الإختبار الثلاثى المعدل، الثدي الكثيف، الموجات فوق الصوتية، سرطان الثدي.