

# Laparoscopic Sleeve Gastrectomy with Interrupted Sutures Omentopexy, Does a Simple Addition Change the Outcome?

**Abdelrahman M Elghandour, MD; Ahmed Osman, MD; Mohammed Shaaban Khalifa, MD; Mohammad Ahmad Abd-erRazik, MD**

Department of General Surgery, Faculty of Medicine, Ain-Shams University, Egypt

**Background:** Obesity is a major risk for mortality and morbidity. After failure of conservative management, the only way out is a bariatric procedure. The Laparoscopic Sleeve Gastrectomy (LSG) is the most frequently performed bariatric procedure worldwide. It is easier and has a shorter learning curve than other bariatric procedures. In this study we addressed a modified technique for omental reattachment to the staple line during LSG and its value in decreasing early postoperative complications.

**Patients and methods:** This was a concurrent cohort study, which involved 119 patients who underwent LSG for a valid indication in adDemerdash Hospital, Ain-Shams University. Patients were randomly allocated into 2 Groups, Group A (n=60), underwent a LSG followed by a modified omentopexy, while Group B (n=59), underwent LSG with no omentopexy.

**Results:** Males represented 27.7% of patients, the mean age was 38.7 years old. The mean BMI was 48.22 kg/m<sup>2</sup>. The sleep apnea was reported in 30.25% of patients, followed by hypertension in 24.3%, DM in 15.9%, and GERD in 5.8% of the patients. The mean intra-operative blood loss was 11.5±3.7 cc, the operative time was significantly longer in the MOP group, p<0.001. Leakage was detected in a single case and gastric sleeve twist was observed in 2 cases in Group B, while postoperative GERD was presented in 8.33% of Group A and 16.94% in Group B. Vomiting was reported in 16.8% of the patients at first day postoperative this number declined to 5.8% at both 1-week and 1-month follow-up visits. The median of number of attacks of vomiting per day in the first day postoperative was 0 with range of 0-5. There was significant decrease in vomiting in the MOP in the 1-week and 1-month follow-up visits.

**Conclusion:** The modified omentopexy (MOP) is a simple addition to the LSG, with the added value of reducing some postoperative complications and symptoms, mainly the postoperative nausea and vomiting attacks.

**Key words:** Laparoscopic sleeve gastrectomy, interrupted omentopexy, omental reattachment, twist, staple line fixation.

## Introduction

Increased body weight is a major risk for mortality and morbidity from other noncommunicable as well as communicable diseases.<sup>1</sup> Studies shown that the problem of obesity has expanded in the recent decades in numerous populations.<sup>2</sup> Obesity is defined by either the Body Mass Index (BMI), which is the weight in kilograms divided by the square of the height in meters, or by the waist circumference, the skinfold thickness or the bioimpedance.<sup>3</sup> Bariatric surgeries are the only long term management option.<sup>4</sup>

The Laparoscopic Sleeve Gastrectomy (LSG) was first thought to be a feasible standalone bariatric surgery, instead of being only a first step in a 2-staged laparoscopic Roux-en-Y gastric bypass in 2003, when Gagner and his team published the results of their study. There was a significant drop in the average BMI after the LSG from 63 to 50 in average of 11 month.<sup>5,6</sup> The LSG gained popularity till it became the most commonly performed bariatric procedure worldwide only after one decade of that study.<sup>7</sup>

The LSG is easier and has a shorter learning curve

than other bariatric procedures.<sup>8</sup> But it's not problem free, it may be accompanied by bleeding (< 5%), leakage (1% to 3.9%), stenosis (2% to 5%), twist of the sleeve and increase in gastroesophageal reflux disease (GERD) symptoms.<sup>6,7,9-12</sup> Many techniques were suggested to treat or reinforce the staple line, such as staple line suturing, buttressing.<sup>13</sup> or omentopexy (OP).<sup>14</sup> In this study we addressed a modified technique for omental reattachment to the staple line during LSG and its value in decreasing early postoperative complications.

## Patients and methods

This was a concurrent cohort study, which involved 119 patients who underwent LSG for a valid indication in adDemerdash Hospital, Ain-Shams University, in the period from June 2018 to June 2021.

All patients were adults, with BMI of 40 kg/m<sup>2</sup> or more, or BMI of 35 kg/m<sup>2</sup> or more with an associated comorbidity, fit for general anesthesia and accepting to participate in the study. Patients with history of previous gastric surgeries, patients needing concomitant procedure (like cholecystectomy, hiatal repair, etc....) or patients with history of severe

GERD symptoms were excluded from this study.

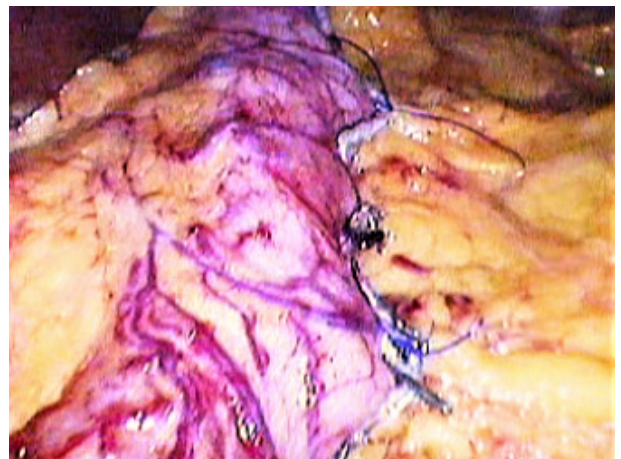
The study was approved from the Research Ethics Committee (REC), General Surgery Department, Ain-Shams University (IRB 00006379). All patients signed out an informed consent after a clear description of the procedure and the alternatives.

Patients were randomly allocated, by simple randomization into 2 groups. Group A was the MOP group (n=60), and it's the test group. While Group B was the control group (n=59), where no omental attachment was done. Full history and clinical examination were done for all the patients, preoperative preparation as per standard of our institute was performed.

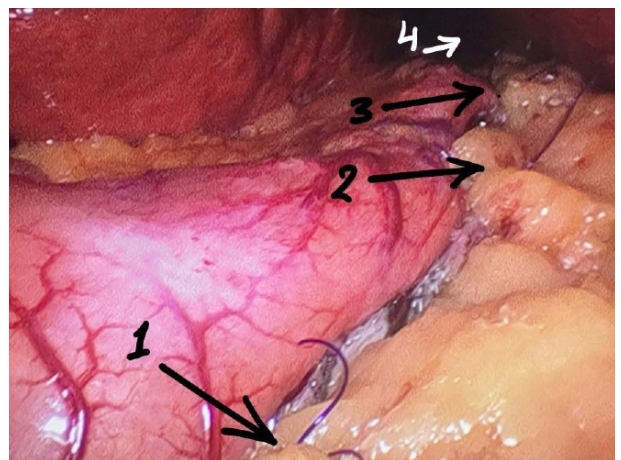
### Procedure

All the 119 patients received a prophylactic dose of Enoxaparin sodium (Clexane®) the night of surgery. All patients underwent LSG, in the French, anti-Trendelenburg position, where the patients were in the supine position with abducted lower limbs, and elevation of the table head. The pneumoperitoneum was achieved via a Veress needle inserted in the left hypochondrium, mid clavicular line, just below the costal margin. Patients underwent the LSG via 3 ports technique, an additional 4<sup>th</sup> port was sometimes used to retract the left lobe of the liver. The LigaSure™ Blunt Tip, Medtronic, Minnesota, USA, was used to divide the gastrocolic omentum starting at 4 cm from the pylorus till the gastroesophageal junction (GOJ). The gastric sleeve tube was created using the Endo GIA™ staplers, Medtronic, Minnesota, USA, starting with a green reload 60–4.8 mm, followed by another 3 to 5 blue reloads 60–3.5 mm, using a 36 Fr bougie. Special care was taken to avoid narrowing the sleeve at the level of the incisura angle and to achieve a uniform sleeved stomach tube without any kinks or twist by symmetrical stapling of the anterior and posterior walls. Staple-line hemostasis was completed with titanium clips in both groups.

In Group A patients, the MOP, (**Fig. 1**), was done by suturing the free edge of the dissected omentum to the sleeved stomach using 4 interrupted Polydioxanone 2-0 sutures, the sleeve was pulled down-wards and laterally, then the first suture was placed nearly at the beginning of staple line before the incisura, the second one was placed above the incisura to avoid possible narrowing of the gastric sleeve at this site, the third one was placed in the mid body while the fourth suture was located 2-3 cm below GOJ, (**Fig. 2**).



**Fig 1: Modified Omentopexy.**



**Fig 2: The 4 sutures of the MOP.**

The methylene blue dye test was used to examine the staple-line integrity, the resected stomach was removed via the right hypochondrial port site. An intra-abdominal tube drain was inserted through the left hypochondrial 5 mm port and wounds were closed.

### Postoperative care

Pain was controlled by intravenous acetaminophen, non-steroidal anti-inflammatory drugs, and opioids on demand. Postoperative nausea and vomiting were assessed during the 1<sup>st</sup> day by the number of attacks per day and were controlled by a single dose of IV 4 mg ondansetron (Zofran®). Precautions were taken to avoid deep venous thrombosis by wearing elastic stocking before the surgery, adequate intravenous fluids, early mobilization, and all patients were continued on venous thromboembolism (VTE) prophylaxis after making sure that there was no risk of bleeding. Patients started oral sips of clear fluids 6-12 hours after surgery and discharged on adequate oral fluids intake for two weeks and pureed diet for two more weeks. After that normal diet was restarted with special precautions.

All patients were discharged on daily dose of proton

pump inhibitor for three months, multivitamins for six months and treatment of hypertension and diabetes, if present, according to physician instructions.

### Postoperative follow-up

All patients underwent regular follow-up visits as follows, at one week, one month and then monthly for a year, for clinical examination and nutritional support. Postoperative nausea and vomiting were assessed at follow-up visits by asking the patient about number of attacks during the last day. The GERD severity was assessed by the need of prolonged use of proton pump inhibitors for more than three months. Only one patient in Group B was lost during the follow-up. The workflow of the recruited patients was shown in (Fig. 3).

Data were collected, tabulated, and coded using Excel 365, Microsoft Corporation, USA. Statistical analysis was done using SOFA statistics Version 1.5.4, Paton-Simpson & Associates Ltd, Auckland, New Zealand. Where the continuous variables were expressed as mean/median ± SD, while the categorical variables were presented as frequencies and percentages. The Student's t-test and Kruskal-Wallis H test were used with continuous variables, while the  $\chi^2$ -test was used with categorical variables. A p value less than 0.05 was reported to be a significant difference.

### Results

A total of 119 patients were recruited for this study.

**Table 1: Demographic data and comorbidities**

			All Cases n=119	LSG + MOP n=60	No MOP n=59	P Value
<b>Sex</b>	<b>Males</b>	n (%)	33 (27.7%)	20 (33.3%)	13 (22%)	§ 0.1686
	<b>Females</b>	n (%)	86 (72.3%)	40 (66.7%)	46 (78%)	
<b>Age</b> (years)		Mean ± SD	38.7 ± 11.5	39.71 ± 11.71	37.66 ± 11.28	× 0.3317
<b>BMI</b> (kg/m <sup>2</sup> )		Mean ± SD	45.91 ± 7.27	45.5 ± 7.58	46.32 ± 6.69	× 0.5323
<b>DM</b>		n (%)	19 (15.9%)	10 (16.6%)	9 (15.2%)	§ 0.8334
<b>HTN</b>		n (%)	29 (24.3%)	15 (25%)	14 (23.7%)	§ 0.8717
<b>Preoperative GERD</b>		n (%)	7 (5.8%)	4 (6.6%)	3 (5%)	§ 0.7138
<b>Sleep apnea</b>		n (%)	36 (30.25%)	14 (23.3%)	22 (37.2%)	§ 0.0975

BMI: Body mass index, DM: Diabetes mellites, HTN: Hypertension, GERD: Gastroesophageal reflux. §:  $\chi^2$ -test. ×: Student's t-test.

**Table 2: Intraoperative and postoperative data**

			All Cases n=119	LGS + MOP n=60	No MOP n=59	P Value
<b>Blood loss</b> (cc)		Mean ± SD	11.5 ± 3.7	11.66 ± 3.54	11.35 ± 3.88	×0.6491
<b>Operative Time</b> (minutes)		Mean ± SD	56.1 ± 7	58.85 ± 7.55	53.28 ± 5.21	× < 0.001*
<b>Leakage</b>		n (%)	1 (0.84%)	0 (0%)	1 (1.69%)	§0.3112
<b>Bleeding</b>		n (%)	3 (2.5%)	1 (1.6%)	2 (3.3%)	§0.5488
<b>Twist</b>		n (%)	2 (1.6%)	0 (0%)	2 (3.3%)	§0.1504
<b>Readmission</b>		n (%)	5 (4.2%)	1 (1.66%)	4 (6.77%)	§0.1645
<b>GERD</b>		n (%)	15 (12.6%)	5 (8.33%)	10 (16.94%)	§0.1568

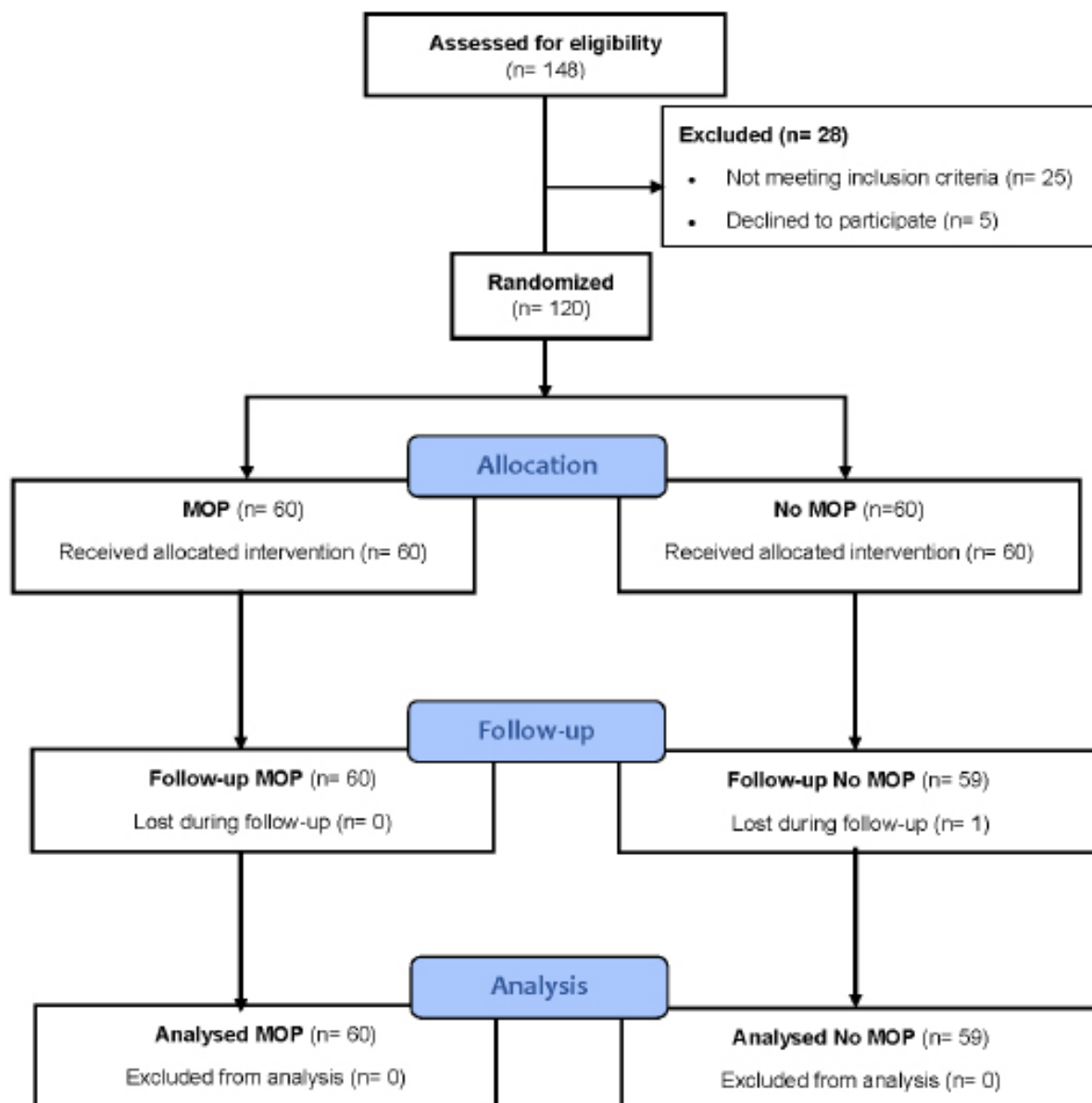
cc: Cubic centimeter. §:  $\chi^2$ -test. ×: Student's t-test. \*Significant.

Males represented only 27.7% of those patients and the mean age was 38.7 years old, it ranged from 18 to 63 years old. The mean BMI was 48.22 kg/m<sup>2</sup> it ranged from 35 to 70 kg/m<sup>2</sup>. The most commonly prevalent comorbidity was the sleep apnea which was present in 30.25% of the patients, followed by hypertension, which was present in 24.3% of the patients. The demographic data and the associated comorbidities were reported in (Table 1).

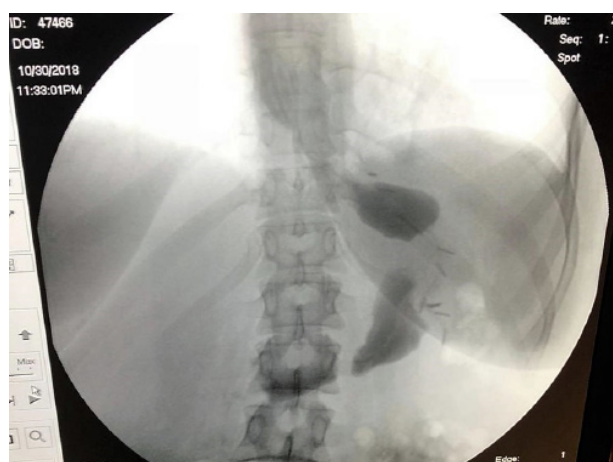The intra-operative blood losses in both groups were comparable, while the operative time was significantly longer in the MOP group, operative data were shown in (Table 2). Regarding postoperative data, one case of leakage was detected in Group B. Gastric sleeve twist was observed in 2 cases in Group B, (Figs. 4,5), the first one was after 24 hours post LSG, the second one was after 2 months. The postoperative data were presented in (Table 2).

The nausea and vomiting attacks were reported in 20 (16.8%) patients at first postoperative day this, number declined to 7 (5.8%) patients at both the 1-week and the 1-month follow-up visits. The of number of attacks of nausea and vomiting per day in both groups in the first postoperative day ranged from 0-5 attacks/day. The Kruskal-Wallis H statistical test was used to compare the total number of attacks per group between the 2 groups in each of the follow-up visits, (Table 3).

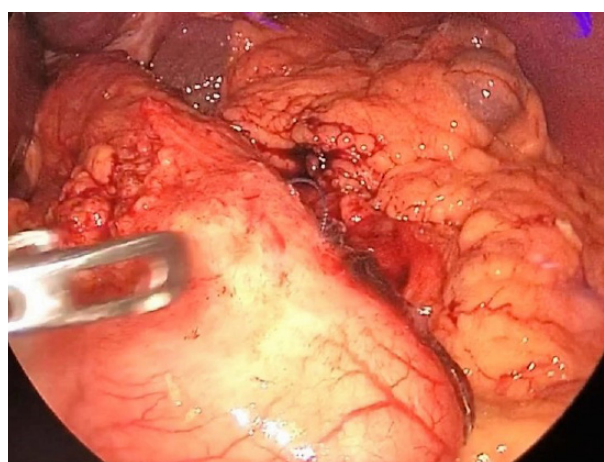




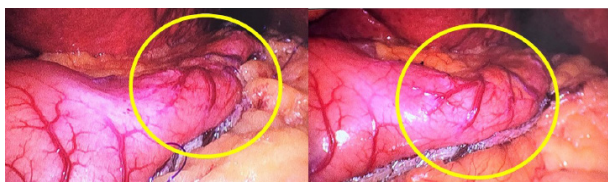
**Fig 3: Workflow of patients.**



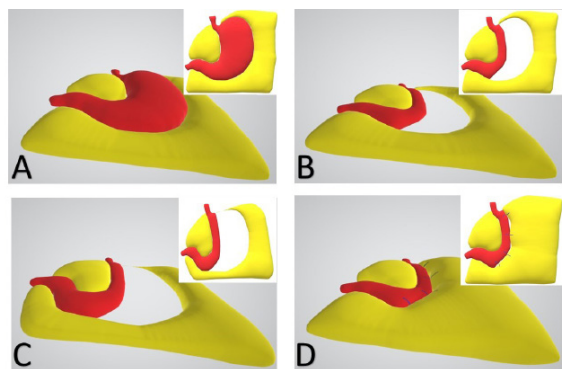
**Fig 4: Gastric sleeve twist.**



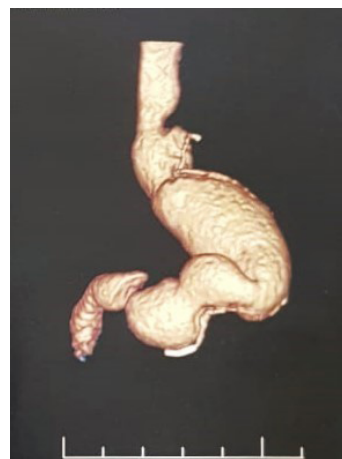**Fig 5: Laparoscopic exploration for the twist.**



**Fig 6: Before and after MOP, and the increase in the angle at the incisura.**



**Fig 7: A three-dimensional model for the LSG in 2 views, A before any intervention, B Just after the sleeve gastrectomy, C the changes of sleeve shape, D After MOP.**



**Fig 8: Virtual gastroscopy with acute angle at the incisura causing dilatation proximally.**

**Table 3: Postoperative nausea and vomiting attacks**

		All Cases n=119	LSG + MOP n=60	No MOP n=59	P Value
<b>First day</b>	n (%)	20 (16.8%)	8 (13.3%)	12 (20.3%)	§ 0.306
	Range per day	0-5	0-2	0-5	‡ 0.277
<b>1-week</b>	n (%)	7 (5.8%)	1 (1.6%)	6 (10.1%)	§ 0.0487*
	Range per day	0-2	0-1	0-2	‡ 0.0489*
<b>1-month</b>	n (%)	7 (5.8%)	1 (1.6%)	6 (10.1%)	§ 0.0487*
	Range per day	0-1	0-1	0-1	‡ 0.0496*

§:  $\chi^2$ -test. ‡: Kruskal-Wallis H test. \*Significant.

## Discussion

The omentopexy (OP) after LSG is a controversial topic,<sup>6</sup> and the procedure is done by different techniques. Usually, it is done by continuous sutures along the staple line. This study was designed to evaluate a modified technique for omentopexy, where only 4 stitches were used to perform the procedure.

In the study done by Sharma and his team, involving 737 patients, 370 of them underwent OP using non absorbable, braided, interrupted sutures.<sup>15</sup> Another study by AbdAlla and his colleagues presented another new technique for OP, they called it T-shaped OP.<sup>16</sup>

Females represented the main portion of the recruited patients, 72.3%, and the mean age of patients in this study was 38.7 years old, these figures were similar to that reported by other studies with similar purpose.<sup>4,17,18</sup> The mean BMI in this study was 45.91 kg/m<sup>2</sup>, similar to what was reported in similar studies.<sup>15,18</sup>

The type-two diabetes mellitus is highly connected to increased body weight, as for every one-kilogram increase in the body weight, the risk of developing type-2 DM increases by 4.5%.<sup>19</sup> In this study, 19% of the recruited patients were diabetics.

In a study involved 3942 patients, OP was done for 1574 patients using absorbable sutures (polydioxanone, size 3-0) along the staple line, the mean operative time in that study was 75 minutes. That study concluded that, the LSG surgery with OP was a promising method with an acceptable increase in the operative time, especially when applied by experienced hands.<sup>20</sup> In another study where OP was done by using continuous suture (3-0 V-Loc Wound Closure Device, Covidien) the mean operative time was 50 minutes.<sup>4</sup> In this study the mean operative time in the MOP group was 59 minutes, this was longer than the mean time in Group B by only 5 minutes, which is an acceptable variation, but this difference was a statistically significant difference at  $p < 0.001$ .

In a multicentric, retrospective study involved a total of 1906 patients, 1385 patients of them underwent LSG and OP, in the OP group the bleeding rate was 0.2%, the leakage/fistula rate was 0.07%, that study concluded that the LSG and OP can prevent the twists of the gastric tube, which is a cause of functional stenosis.<sup>4</sup> In another study the bleeding rate was 0.3% and the leakage rate was 0.06%.<sup>20</sup> In a prospective single-blind randomized trial involved 186 patients, 96 of them underwent LSG and OP using Glubran®2 spray, which is a modified cyanoacrylate, they reported a significant reduction in complication rates in the OP group.<sup>21</sup> Another study concluded that, the OP had a favorable effect on gastric leaks post LSG but had no effect on bleeding.<sup>15</sup> In our study, the bleeding rate in the MOP group was 1.6%, the patient was managed conservatively by close monitoring of vital data with blood and fresh frozen plasma transfusion. There were no reported cases of leakage or twist in the MOP group.

However, a case of leakage was detected in Group B in the 7<sup>th</sup> postoperative day. She was presented by fever, tachycardia, and abdominal pain, pelviabdominal ultrasound was done, it revealed a moderate abdominal collection. An endoscopic intra-luminal stent was inserted, and re-laparoscopy was done for abdominal lavage and drains insertion. Moreover, 2 cases of gastric twist were recorded, and again both were in Group B. The 1st one was presented 48 hours after surgery by recurrent attacks of vomiting and intolerance to oral intake. Oral gasrtograffin meal was done, (**Fig. 4**) which revealed mid-body twist. Urgent laparoscopic exploration was done to avoid development of leakage; as leakage is more likely to occur in patients presented with distal sleeve obstruction, which causes difficult gastric emptying.<sup>22</sup> Dissection of fibrinous adhesions and untwisting of the stomach tube were done, (**Fig. 5**) and then sleeve tube fixation to the free edge of omentum was done after making sure that there was no narrowing of the sleeved stomach. The second case was presented two months after surgery by repeated attacks of vomiting and intolerance to solid food, CT virtual gastroscopy was done and showed midbody twist, the patient was explored laparoscopically, extensive adhesions was found, laparoscopic adhesiolysis was done followed by proper fixation to the free edge of the omentum.

The LSG induces GERD in some patients who were previously asymptomatic.<sup>23</sup> Postoperative GERD symptoms were less in the MOP Group, it was present in 8.33% of the patients compared to 16.94% in the non-MOP group. A study involved 20 patients who underwent LSG and OP (with continuous sutures), concluded that LSG with OP improved the GERD score, but didn't determine significant change in the

lower esophageal sphincter pressure.<sup>10</sup>

There is a high burden of post LSG nausea and vomiting, it is the most common cause of readmission following the LSG.<sup>24</sup> It was reported that 30.4% of the readmissions of LSG patients were mainly for oral intake intolerance with nausea and vomiting.<sup>25</sup> A study reported that about 20% of the LSG patients had a "delayed than expected discharge" due to the postoperative nausea and vomiting.<sup>26</sup> Another study using what's called T-shaped OP, reported that their technique had lower incidence of significant postoperative nausea and vomiting, and GERD as well as less staple line bleeding.<sup>16</sup> In our study, the nausea and vomiting were less in the MOP group, especially in the 1-week and 1-moth follow-up visits, they had a significantly lower number of affected patients and lower number of attacks per group when compared to Group B. Also, the frequency of readmissions was lower in the MOP group.

The MOP is correcting the gastric sleeve angles and orientation, but it's not much appreciated during laparoscopy, (**Fig. 6**). This because of the distortion of the real image dimensions and angles, which normally happens during viewing objects from certain perspectives.<sup>27</sup>

A computer-generated 3D model, shown in (**Fig. 7**), demonstrated the difference in the perception of dimensions and angles in two visual perspectives. The first one, mimics the visual perspective during laparoscopy, in which the 30 degrees scope is placed below the target area and in an angled position, the other one is a perspective control, in which the images were rendered without any distortion. This model illustrated some perception problems that may face surgeons. For example, it's known that the antral division is started 2–5 cm from the pylorus, and a great care should be taken to avoid stenosing the sleeve at the angle made by the incisura,<sup>6,23</sup> the perspective control in (**Fig. 7B**) made it easier to imagine how frequent this error may happen if there is no such care to avoid the creation of this stenosis. Another example is the change and the narrowing of the angle at the incisura happening after formation of the gastric sleeve, this change is not much appreciated in the laparoscopic perspective, but in the perspective control the difference was very clear, (**Figs. 7B,C**). This narrowing of the angle at the incisura probably happens due to the loss of the lateral traction exerted by the previously attached greater omentum, this creates imbalanced forces on the gastric sleeve, changing its shape and orientation.<sup>15</sup> The virtual gastroscopy presented in (**Fig. 8**), emphasizes this idea. It belonged to a patient in Group B, was suffering of intermittent attacks of vomiting.



## Limitations

It was a single center study. The sample should have been larger, it was affected by COVID-19 pandemic restrictions.

## Conclusion

The modified omentopexy (MOP) is a simple addition to the LSG, with the added value of reducing some postoperative complications and symptoms, mainly the postoperative nausea and vomiting.

No conflict of interest to be declared.

No funds were received for this study.

## References

1. Klang E, Kassim G, Soffer S, et al: Severe obesity as an independent risk factor for COVID-19 mortality in hospitalized patients younger than 50. *Obesity*. 2020; 28(9): 1595–1599.
2. Finucane MM, Stevens GA, Cowan MJ, et al: National, regional, and global trends in body-mass index since 1980: systematic analysis of health examination surveys and epidemiological studies with 960 country-years and 9.1 million participants. *Lancet*. 2011; 12;377(9765): 557–567.
3. Kopelman PG: Obesity as a medical problem. *Nature*. 2021; 404(6778): 635–643.
4. Arslan E, Banli O, Sipahi M, et al: Effects and results of omentopexy during laparoscopic sleeve gastrectomy. *Surg Laparosc Endosc Percutan Tech*. 2018 Jun 2021; 28(3): 174–7.
5. Regan JP, Inabnet WB, Gagner M, et al: Early experience with two-stage laparoscopic roux-en-Y gastric bypass as an alternative in the super-super obese patient. *Obes Surg*. 2003; 13(6): 861–4.
6. Gagner M, Cardoso AR, Palermo M, et al: The Perfect Sleeve Gastrectomy: A Clinical Guide to Evaluation, Treatment, and Techniques [Internet]. Gagner M, Cardoso AR, Palermo M, Noel P, Nocca D, editors. *The Perfect Sleeve Gastrectomy*. Cham: Springer International Publishing. 2020.
7. Felsenreich DM, Ladinig LM, Beckerhinn P, et al: Update: 10 Years of sleeve gastrectomy-the first 103 patients. *Obes Surg*. 2018; 28(11): 3586–94.
8. Bohdjalian A, Langer FB, Shakeri-Leidenmühler S, et al: Sleeve gastrectomy as sole and definitive bariatric procedure: 5-year results for loss and ghrelin. *Obes Surg* [Internet]. 2021; 20(5): 535–40.
9. Zarzycki P, Kulawik J, Małczak P, et al: Laparoscopic sleeve gastrectomy with omentopexy: Is it Really a promising Method?—A Systematic Review with Meta-analysis. *Obes Surg*. 2021;31(6):2709-2716.
10. Filho AMM, Silva LB, Godoy ES, et al: De Quadros LG, Zotarelli Filho IJ, et al: Omentopexy in sleeve gastrectomy reduces early gastroesophageal reflux symptoms. *Surg Laparosc Endosc Percutan Tech*. 2019; 29(3): 155–61.
11. Lalor PF, Tucker ON, Szomstein S, et al: Complications after laparoscopic sleeve gastrectomy. *Surg Obes Relat Dis*. 2021; 4(1): 33–8.
12. Abd Ellatif ME, Abbas A, El Nakeeb A, et al: Management options for twisted gastric tube after laparoscopic sleeve gastrectomy. *Obes Surg*. 2017; 27(9): 2404–9.
13. Dapri G, Cadière GB, Himpens J: Reinforcing the staple line during laparoscopic sleeve gastrectomy: Prospective randomized clinical study comparing three different techniques. *Obes Surg*. 2021; 20(4): 462–7.
14. Sabry K, Qassem M. The impact of routine omentopexy to staple line on the incidence of early postoperative complications after laparoscopic sleeve gastrectomy: Is it worth? *Egypt J Surg*. 2018;37(4):479.
15. Sharma N, Chau WY: Remodifying omentopexy technique used with laparoscopic sleeve gastrectomy: Does it change any outcomes? *Obes Surg*. 2021; 30(4): 1527–35.
16. Abdallah E, Zakaria M, Fikry M, et al: Laparoscopic sleeve gastrectomy with T-shaped omentoplasty: Impact on the early postoperative outcomes. *Obes Surg*. 2021; 30(10): 3735–41.
17. Nosrati SS, Pazouki A, Sabzikarian M, et al: Can omentopexy reduce the incidence of gastroesophageal reflux disease after laparoscopic sleeve gastrectomy. *Obes Surg*. 2021; 31(1): 274–81.
18. AlHaddad M, AlAtwan AA, AlKhadher T, et al: Omentopexy during laparoscopic sleeve gastrectomy: Is it effective in reducing postoperative gastrointestinal symptoms. A retrospective cohort study. *Ann Med Surg*. 2021; 65: 102369.
19. Ford ES, Williamson DF, Liu S: Weight change and diabetes incidence: findings from a national cohort of US adults. *Am J Epidemiol*. 1997; 146(3): 214–22.

20. Lale A, Aygen E, Kirkil C, et al: Efficacy of staple Line reinforcement with Omentopexy During Laparoscopic Sleeve Gastrectomy on postoperative complications: experience of a single center. *Surg Laparosc Endosc Percutan Tech.* 2021; 31(2): 181–7.
21. Pilone V, Tramontano S, Renzulli M, et al: Omentopexy with Glubran®2 for reducing complications after laparoscopic sleeve gastrectomy: Results of a randomized controlled study. *BMC Surg.* 2019; 19(S1): 56.
22. Márquez MF, Ayza MF, Lozano RB, et al: Gastric leak after laparoscopic sleeve gastrectomy. *Obes Surg.* 2010; 20(9): 1306–11.
23. DuPree CE, Blair K, Steele SR, et al: Laparoscopic sleeve gastrectomy in patients with preexisting gastroesophageal reflux disease: A national analysis. *JAMA Surg.* 2021; 149(4): 328–34.
24. Spaniolas K, Nie L, Moller D, et al: A comprehensive approach for the prevention of nausea and vomiting following sleeve gastrectomy: A randomized controlled trial. *Obes Surg.* 2021; 30(11): 4250–7.
25. Sippey M, Kasten KR, Chapman WHH, et al: 30-day readmissions after sleeve gastrectomy versus Roux-en-Y gastric bypass. *Surg Obes Relat Dis.* 2016; 12(5): 991-996. doi:10.1016/j.soard.2016.01.036.
26. Celio A, Bayouth L, Burruss MB, et al: Prospective assessment of postoperative nausea early after bariatric surgery. *Obes Surg.* [Internet]. 2021; 29(3): 858–61.
27. Stefansic JD, Herline AJ, Yu Shyr, et al. Registration of physical space to laparoscopic image space for use in minimally invasive hepatic surgery. *IEEE Transactions on Medical Imaging.* 2005;VII\_4\_1-VII\_4\_12. doi:10.1109/SSBI. 2002.1233999.