

1 **Original research paper**

2 **Surgery**

3 **Title: Efficacy of Adipose and Bone Marrow Derived Mesenchymal Stem Cells for**
4 **Treatment of Surgically Induced Knee Osteoarthritis in Rats**

5 **Running title: Stem cell therapy for Knee Osteoarthritis in Rats**

6 **Authors: AmlAwad¹, Mohamed Salama², AwadRizk³, Mohamed F.Hamed⁴, Esam Mosbah³**

7 **Affiliations:** ¹Medical Experimental Research Center, Faculty of Medicine, Mansoura University,
8 Egypt.

9 ²Department of Toxicology, Faculty of Medicine, Mansoura University, Egypt.

10 ³Department of Surgery, Anesthesiology and Radiology, Faculty of Veterinary Medicine,
11 Mansoura University, Egypt.

12 ⁴Department of Pathology, Faculty of Veterinary Medicine, Mansoura University, Egypt.

13 Correspondence to:

14

15 **AmlAwad**

16 Medical Experimental Research Center, Faculty of Medicine, Mansoura University, Egypt. PO

17 35516 Mansoura, Egypt

18 E-mail: dramlawad.merc@yahoo.com

19 Tel: 002001001222595

20

21

22

23

24

25

26 **ABSTRACT**

27 **Objective:**To evaluate the efficacy of direct intra articular (IA) injections of adipose derived
28 mesenchymal stem cells(ADSCs) and bone marrow derived mesenchymal stem cells (BMSCs) for
29 regenerating articular cartilage in surgically induced knee osteoarthritis (OA) in sprague-dawely
30 rats.

31 **Design:** A randomized-controlled study.

32 **Animals:** thirty Sprague dawely rats were divided into 5 groups (6 rats in each group).

33 **Procedures:**OA was surgically induced by medial collateral ligament (MCL) transection and
34 medial meniscal tear of the left knee joints to induce joint destabilization of the left knee. 4 weeks
35 after the operation, single dose of ADSCs, BMSCs and phosphate buffer saline (PBS) was
36 delivered to the operated knee by direct aseptic IA injection in each treated group (III), (IV) and
37 (V) respectively. The healing was assessed clinically, grossly and microscopically at 10 weeks
38 postoperatively.

39 **Results:** rats that received ADSCs grossly showed better efficiency in regenerating of articular
40 surface and closed to the normal knee morphology without any noticed defects and showed better
41 cartilage quality and lower degree of cartilage degeneration histopathologically and there was a
42 trend towards higher scores for all parameters in treated groups, and demonstrated that
43 chondrocytes and chondroid matrix regained their histological architecture upon ADSCs more than
44 BMSCs.ADSCs is mimicking the normal articular cartilage, the BMSCs alleviated inflammatory
45 process and increased the lay down of chondroid matrix and the superficial cracks remains for
46 some degree. ADSCs exhibited mild Immunohistochemical expression against Matrix
47 Metalloproteinase 9(MMP9) in comparison to other treated groups, at the time the control group
48 showed no expression at all.

49 **Conclusion and clinical relevance:**

50 The results of the present study demonstrated that ADSCs and BMSCs can alleviate knee OA via
51 their strong regenerative capacity on chondrocytes and increased chondroid matrix deposition. So,for
52 such positive results, ADSCs are more effective and easily available compared to BMSCs.

53

54 **Key words :** OA, MCL, ADSCs, BMSCs, Rat.

55

56 1. INTRODUCTION

57 Osteoarthritis is the most commonly diagnosed joint disease in both human and veterinary medicine
58 [1]. OA is a chronic, degenerative process characterized by progressive cartilage deterioration,
59 subchondral bone remodeling, and loss of joint space, marginal osteophytosis, and loss of joint function.
60 Although the etiology of OA may differ across species or among individuals within a species, some
61 components of the pathophysiology of the disease are consistent [2, 3]. OA is a condition not only
62 associated with focal damage of the articular cartilage, but also with other intraarticular structures. It is
63 characterized by inflammation and catabolic joint metabolism and biochemical changes which affect the
64 results of chondrocyte-based treatments [4].

65 Mesenchymal stem cells (MSCs) have been proposed instead of mature chondrocytes for OA
66 treatment, because of their paracrine effects, anti-inflammatory and immunomodulatory
67 properties, beside their capability to differentiate in cells of chondrocyte lineage within the lesion
68 site [5]. Different cell sources exist but currently the most investigated cells for cartilage
69 regeneration and OA treatment are BMSCs and ADSCs [6].

70 ADSCs have shown numerous advantages, including the high number, easier availability, and the
71 evidence to be able to differentiate toward osteoblasts and chondrocytes [7]. Intra-articular (IA) injection
72 of ADSCs reduced synovitis, osteophyte formation, cartilage degeneration [8], and improved the cartilage
73 degradation and reduced knee synovitis in OA rabbit model [9].

74 BMSCs have multipotent differentiation potential (could differentiate into numerous tissues, such as
75 bone, cartilage and fat), self-renewal capacity and immunomodulatory properties, has great potential for
76 use in stem cell-based articular cartilage diseases [10]. BMSCs also have shown desirable effects in the
77 treatment of OA, probably via the secretion of bioactive trophic factors to exert potent anti-inflammatory,
78 immunomodulatory, and antifibrotic effects [11].

79 Pain and disability are the primary symptoms for patients who suffer from OA.
80 relationship between a specific molecular, cellular or pathological event and OA pain, requires
81 therapeutic or prophylactic modification of that factor, severity of the pain defining the key changes
82 that cause OA pain needs to be investigated in pre-clinical models where such factors can be
83 therapeutically targeted [12].

84 This study aimed to evaluate the effectiveness of ADSCs and BMSCs derived MSCs in regeneration of
85 surgically induced osteoarthritic knee in sprague-dawley (SD) rats.

86 **2. MATERIALS AND METHODS**

87 *2.1. Animals, housing and feeding*

88 This study was carried out on a total number of 30 male Sprague–Dawley (SD) rats (body weight 200–
89 250 gram).Rats were housed at temperature 20°C-25°C in the animal house of Medical Experimental
90 Research Center (MERC), Faculty of Medicine ,Mansoura University. They were retained under
91 constant conditions and supplied with standard diet and water ad libitum. The experimental protocol of
92 this work was approved by the Local Ethical Committee, Faculty of Medicine, Mansoura University in
93 accordance with the Ethics committee of national research Center-Egypt with registration number
94 (09/189).

95 *2.2. Study design*

96 All rats were divided into 5 groups: group (I) (negative control group,6 rats).Surgical induction of OA
97 was performed in 25 rats which were divided in to group(II)(positive control), group (III): osteoarthritic
98 rats were treated with BMSCs, group(IV)osteoarthritic rats were treated with ADSCs,
99 group(V)osteoarthritic rats were treated with PBS. Single dose of a million cells derived from bone
100 marrow & adipose tissue and suspended in 100µl of PBS was delivered to the operated knee by direct
101 aseptic IA injection 4 weeks postoperative [13].

102 All rats were anaesthetized by intra-peritoneal (IP) injection of a mixture XylazineHcl in dose 10
103 mg/kg (Xylajet (20mg/ml), ADWIA, Egypt) and ketamine Hcl in dose 75mg/kg
104 (Ketamax(50mg/ml),Troikaa Pharmaceuticals Ltd,Gujarat, India) according to [14].

105 The skin over the medial aspect of the left knee joint was aseptically prepared .The rats were fixed in
106 dorsal recumbency in plate of wax .A 2-3 cm medial parapatellar incision was performed. Blunt
107 dissection was performed to expose the medial collateral ligament (MCL), which was next transected to
108 expose the medial meniscus. The medial meniscus was cut across its full thickness to induce joint
109 destabilization of the left knee. Following transection of the meniscus, the joint capsule and s/c tissues
110 were sutured with simple continuous pattern using 4/0 Vicryl. The skin was opposed by simple
111 interrupted stitches using 4/0 monofilament Nylonaccording to[15], After surgery ,the rats were kept in
112 a recovery room for about 2 h under heat lamps to maintain body temperature and to monitor any adverse
113 effects. Each rat was given amoxicillin (E-MOX,EIPICO, Egypt)in dose (20 mg/kg IM), and analgesic

114 Meloxicam (MOBITIL, MUP, Egypt) in dose (5 mg/kg SC) once a day for the first 3 days, and once
115 animals regained complete consciousness, permitted free cage activity until the end of the study .

116 2.3. BMSCs isolation and culture

117 Rat BMSCs were isolated by flushing morselized femurs and tibia from 4-week old, male, SD rats. The
118 harvested cells were cultured in BMSCs culture medium, consisting of low-glucose Dulbecco's
119 modified Eagle's medium (L-DMEM) containing 10% fetal bovine serum (FBS, Lonza, Verviers,
120 Belgium), 50 µg/ml gentamicin and 1.5 µg/ml fungizone. All media were renewed twice a week. These
121 primary cells were referred to as passage 0 (P0). The confluent cells were dissociated with 0.25% trypsin
122 and 0.01% EDTA, and subcultured in new six-well culture dishes at a plating density of 5×10^4 cells/well.
123 These procedures were repeated four times and the cultures were referred to as P1, P2, P3, P4 and P5
124 according to method of [16].

125 2.4. ADSCs isolation and culture

126 The steps of ADSCs preparation were performed under complete a septic condition in a biosafety
127 cabinet, while wearing appropriate personal protective equipment. Place adipose tissue in a
128 preweighed sterile petri dish and weigh to get a final tissue weight . Mince the fat into small pieces
129 with a sterile scalpel and blade until tissue is no longer fibrous. Place tissues into a 15-mL tube
130 with an equal volume of prewarmed PBS and agitate for 45 s. Allow the mixture to separate into
131 phases for 3–5 min and then remove the infranatant. Continue the process until the infranatant is
132 clear for successive 4 washes. Add an equal volume of collagenase solution to the adipose solution,
133 clean the outside of the tube with 70% EtOH, cover the top with para-film, and place in a 37°C
134 shaking water bath at 75 rpm for 1.5 min or until the tissue becomes homogenous. Vortex for 15 s
135 to thoroughly mix cells and then centrifuge at 1,200 rpm ($300 \times g$) for 5 min. Vortex solution for
136 10 s to get as many cells out into the media as possible. Then centrifuge again at 1,200 rpm (300
137 $\times g$) for 5 min., carefully, remove the supernatant consisting of lipids, primary adipocytes, and
138 collagenase solution, leaving the pelleted stromal vascular fraction . Resuspend the pellet in 1%
139 BSA solution. Transfer solution to a new 15-mL centrifuge tube, centrifuge cells at 1,200 rpm (300
140 $\times g$) for 5 min and remove the supernatant. When aspirating, keep the tip of the pipette very
141 superficial so the majority of liquid is removed. Resuspend the pellet in 1 mL of stromal

142 media. Centrifuge a 20- μ L aliquot in a microcentrifuge tube at 1,200 rpm ($300 \times g$) for 5
143 min. Remove the supernatant and resuspend the pellet in 20 μ L of red cell lysis buffer. Incubate for
144 5 min at room temperature. Add 20 μ L of Trypan Blue and count the cells with a
145 hemocytometer. Plate the cells at the appropriate density in complete stromal media and incubate
146 at 37°C and 5% CO₂. Change the media after 24 h to remove nonadherent cells. Media should be
147 changed about every 3 days according to method of [17].

148 2.5. Evaluation of OA

149 2.5.1. Clinical assessment

150 Subjective assessment of pain was performed by observing changes in general locomotor activity (e.g.,
151 guarding a specific area or avoiding weight-bearing on an injured limb and changes in food and water
152 intake and body weight [18].

153 Mechanical hyperalgesia was assessed by the Randall–Sellito analgesiometer (Ugo Basil,
154 Varese, Italy). Briefly, the rats were maintained in a normal/horizontal position. The left hind paw
155 was placed in an analgesiometer, which was composed of a cone-shaped paw-pressor with a
156 rounded tip that was used to apply linear increasing force to test paw. The withdrawal threshold
157 was taken as the point at which the rat vocalized or struggled vigorously, expressed as the force in
158 grams (g). The withdrawal threshold (gram) was recorded at the first, second, third and fourth
159 week respectively after treatment and compared to the control group [19].

160 All rats in each group were euthanized 10 weeks after surgery with IP injection of thiopental
161 sodium in a dose of 120 mg/kg [20]. Assessment of joint stiffness by measurement of maximum
162 extension angle of the knee. The left knee of each animal was dissected and the articular cartilage
163 was left intact. After the dissection, the maximum extension angle of each knee was measured
164 with zero degree represent as the maximum possible extension, so the lower the angle value, the
165 better the knee function [21].

166 2.5.2. Gross evaluation

167 The femoral condyle and tibial plateau were collected, and surfaces of the cartilage were examined
168 macroscopically and photographed using a digital camera. Cartilage lesions were evaluated by two
169 examiners who were blinded to treatments [22].

170

171 2.5.3. *Microscopical evaluation*

172 The preparation of knee specimen for the microscopic examination at 10 weeks postoperative.
 173 The fixation of the specimens was done in 10% buffered formalin, and then decalcified with EDTA
 174 for 8-10 weeks till they became soft. Fixed samples were processed by the paraffin embedding
 175 technique, sectioned, and stained by hematoxylin and eosin (H&E), Masson’s trichrome and
 176 Safranin O stains. Cartilage changes were graded according to histopathological Mankin score in
 177 (Table 1)[23].

178 **Table 1.** Histopathological Mankin scores

Cartilage structuring		Chondrocytes		Safranin-O Staining		Tidemark	
Score	Definition	Score	Definition	Score	Definition	Score	Definition
0	Normal	0	Normal	0	Normal	0	Intact
1	superficial fibrillation	1	Diffuse hypercellularity	1	Slight reduction	1	Tidemark infiltrated with vessel
2	Pannus and superficial fibrillation	2	Cell clusters	2	Moderate reduction		
3	Fissures to mid zone	3	Hypocellularity	3	Severe reduction		
4	Fissures to deep zone			4	No staining		
5	Fissures to calcified zone			5	Total disorganization		

179 2.5.4. *Immunohistochemical Analysis*

180 Paraffin embedded sections were rehydrated in graded alcohols, steamed in citrate buffer at pH 6 and
 181 probed at room temperature for 2 hours using the MMP-9 (rabbit polyclonal; 1:250; Abcam [AB38898]
 182 and processed with a polymer-HRP kit (BioGenex) with diaminobenzidine development and Mayer
 183 hematoxylin counterstaining according to[24].

184 The Immunohistochemical expression against mmp9 for the enzyme matrix metalloproteinase to
 185 display marked expression in the articular cartilage in the diseased group in comparison to other group
 186 and calculate number of immunopositive cells per 1000 cells.

187

188

189 2.5.5. *Statistical analysis*

190 All data obtained from the experiment were expressed as means \pm SEM. Statistical analysis of data
191 was carried out by software SPSS program [25] using the one-way analysis of variance ANOVA
192 followed by post hoc tukey for testing the significant differences between variables. Results were
193 considered significant only at the level of ($p \leq 0.05$).

194 **3. RESULTS**

195 *3.1. Clinical findings*

196 All rats experienced pain and discomfort in the form of gradually decreased activity, avoiding weight-
197 bearing on an injured limb, decreased appetite, pale appearance of conjunctiva and some osteoarthritic
198 rats suffered from weight loss. All these clinical signs were diminished gradually.

199 In mechanical hyperalgesia, the improvement of the decreased withdrawal threshold in ADSCs
200 treated group was significantly higher compared to all other treated groups but this improvement still
201 significantly lower than the control normal group (Table 2).

202 Assessment of joint stiffness by measurement of maximum extension angle of the knee, ADSCs
203 treated group showed a significant enhancement of the increased maximum angle of the knee extension
204 found in the diseased group, but still significantly higher than the control normal group, less than PBS
205 treated group and BMSCs treated group (Table 2).

206 *3.2. Gross finding*

207 The isolated articular cartilage surfaces from 5 groups were grossly observed. There was no gross
208 evidence of any side effects such as infection or tumor formation throughout the observation period.
209 Gross morphological features of the knee joints from various treatment groups were compared with
210 control normal group. Osteoarthritic knee joint showed formation of hard, thick, yellowish fibrotic tissue
211 and exhibited severe erosion and fibrillation (granular appearance)(Fig. 1A) over the whole articular
212 surface compared with the gross appearance of normal group with smooth, glistening surface with no
213 fibrillation or erosions(Fig. 1B).Also, macroscopic observations from femoral condyle in BMSCs group
214 represented intense reddish patches distributed in the almost of articular surface resulted from
215 diminishing in cartilage thickness reflecting the colour of red marrow of sponge bone and grossly evident
216 of less articular cartilage erosion and fibrillation in most regions of the articular knee surface compared
217 with the OA group(Fig.1C).In the ADSCs group, the gross observation of articular surface showing

218 homogeneity of grayish coloration near normal appearance without any noticed defects indicating better
219 efficiency in regenerating of articular surface and is closer to the normal knee morphology(Fig.1D,E).The
220 gross appearance of the PBS group was like OA group ,articular surface showing marked erosion of
221 trochlear articular surface exposing underling vascularized tissue (sponge bone of distal end of femur)
222 (Fig.1F),and partial erosion of condyloid articular surface with appearance of reddish coloration of
223 sponge bone (Fig.1G). In the ADSCs group, cartilage regeneration was significantly higher versus all
224 treated groups whereas no significant regeneration was found in PBS group in comparison to other
225 different treatment groups.

226

227 *3.3.Microscopical findings*

228 The histological score for the cartilage structure estimated that OA group showing significant
229 cartilage destruction towards increasing in the fissures to the deep zone ,fissures to the calcified
230 zone, articular degeneration ,fibrillation as dentated surface (Fig.2A;arrow) and articular surface
231 thinning (Fig.2B;arrow) in comparison to other groups, also OA joint displayed articular capsule
232 with exuberant fibrous proliferation protruding from capsule (Fig.2C;arrow) and hyperplasia in
233 synovial membrane appeared as multilayers cuboidal epithelium (Fig.2D; arrow) and congested
234 blood vessels. Meanwhile, the ADSCs group showed marked improvement of cartilage structure
235 with only minimal superficial fibrillation and normal synovial membrane appeared as monolayer
236 of flattened cuboidal epithelium (Fig.3B; arrow) with normal underling stromanealy similar to
237 control group. while in BMSCs group ,the histological view displayed hyperplastic synovial
238 membrane appears as multilayer of cuboidal to columnar epithelium (Fig.3D; arrow) which
239 showing significant improvement in histological score as compared to the OA group and PBS
240 group but still less than control normal (Fig.2E,F) and ADSCs treated group(Table 3) .

241 The histological examination for the chondrocytes within the various groups demonstrated that
242 OA group showing significant chondrocyte pathological alterations, including hypocellularity and
243 destruction of the lacunae and cloning of chondrocytes forming clusters (Fig.2A;arrow head) in
244 comparison to other groups, in the contrary, the ADSCs group showed marked significantly
245 improvement of chondrocytes histological architecture with normal chondrocytes inside its
246 lacunae and normal basophilic chondroid matrix (Fig. 3A;arrow) which only displayed mild
247 hypercellularity. while The histological examination for the chondrocytes in BMSCs group

248 displayed focal loss of chondrocytes appears and chondroid matrix as fade basophilic devoid from
249 lacunae (Fig.3C;arrow) showing significant improvement in histological score as compared to
250 PBS group which displayed fused lacunae (Fig.3E;arrow) and loss of chondroid matrix in articular
251 surface which appeared pale esinophilic(Table 3) .

252 The histological examination for cartilage stained with safranin O stain explore that OA group
253 showing Severe reduction in the staining of chondroid matrix which appears faint from red safranin
254 stain at which indicates marked loss of chondrocytes and loss of proteoglycan at chondroid matrix
255 (Fig.4A;arrow) in comparison to other groups, in the contrary, the ADSCs group showed slight
256 loss of proteoglycan at chondroid matrix(Fig.4B;arrow) while the remaining articular surface
257 appears normal red stained against safranin stain in comparison to other treated groups. while The
258 histological examination for cartilage in BMSCs treated group showing articular degeneration
259 represented by fissured surface and uneven distribution of safranin O stain with loss of
260 chondrocytes(Fig. 4C;arrow),The histological score for cartilage stained with safranin O stain in
261 BMSCs treated OA group and PBS treated group (Fig.4D; arrow) but still significantly higher than
262 normal group (Fig.4E;arrow) and no significant improvement in histological score as compared
263 to ADSCs treated group(Table 3).

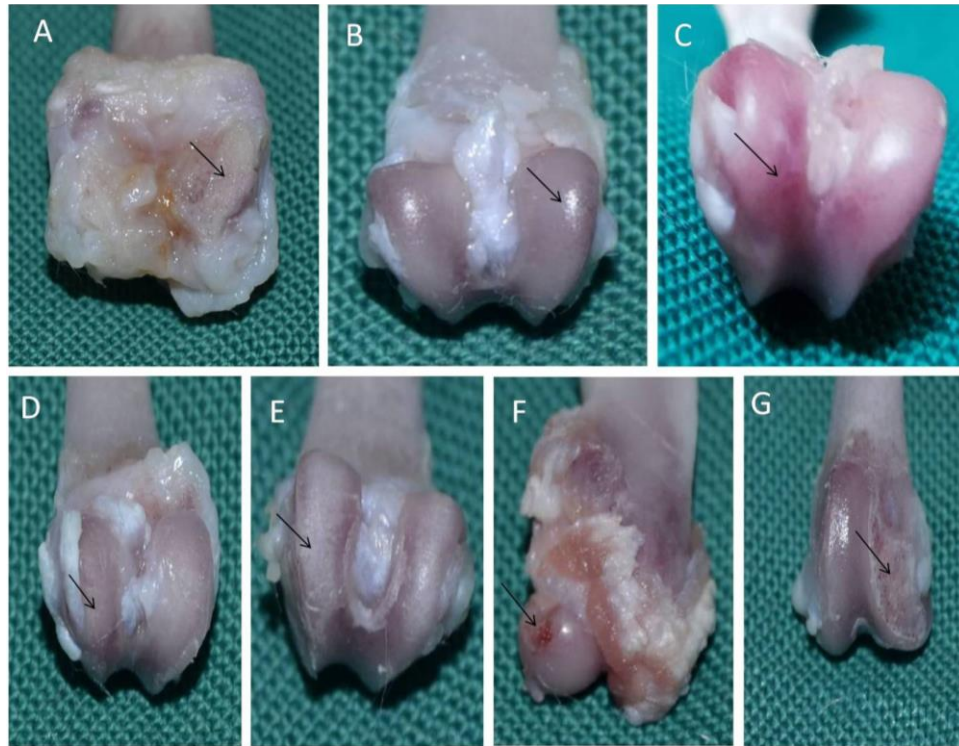264 The histological findings in OA group showing decrease length of articular surface with tidemark near
265 to articular surface (Fig.2B;arrow head) it was significantly destructed and penetrated blood vessels,more
266 significantly in OA group in the comparison to all other groups(Table 3).

267 Using masson trichrome stain which is specific stain for the collagen fiber in the chondroid
268 matrix revealed loss in OA group(Fig.5A) and PBS group (Fig.5D), meanwhile in the ADSCs
269 (Fig.5B) and BMSCs(Fig.5C)displayed marked restoration.The normal group was normal
270 histological appearance (Fig.5E).

271 The Immunohistochemical expression against MMP9 for the enzyme matrix metalloproteinase
272 displayed strong marked expression in the articular cartilage in the OA group (Fig.6A) in
273 comparison to other groups. ADSCs treated group exhibited mild expression of it (Fig.6B) in
274 comparison to other treated groups at the time the control normal group showed no expression at
275 all (Fig.6E) while in the BMSCs group displayed moderate expression in the articular cartilage
276 (Fig.6C) that showed significantly increase in expression in the articular cartilage as compared to
277 the control group and ADSCs treated group .But in the PBS treated group showed significantly

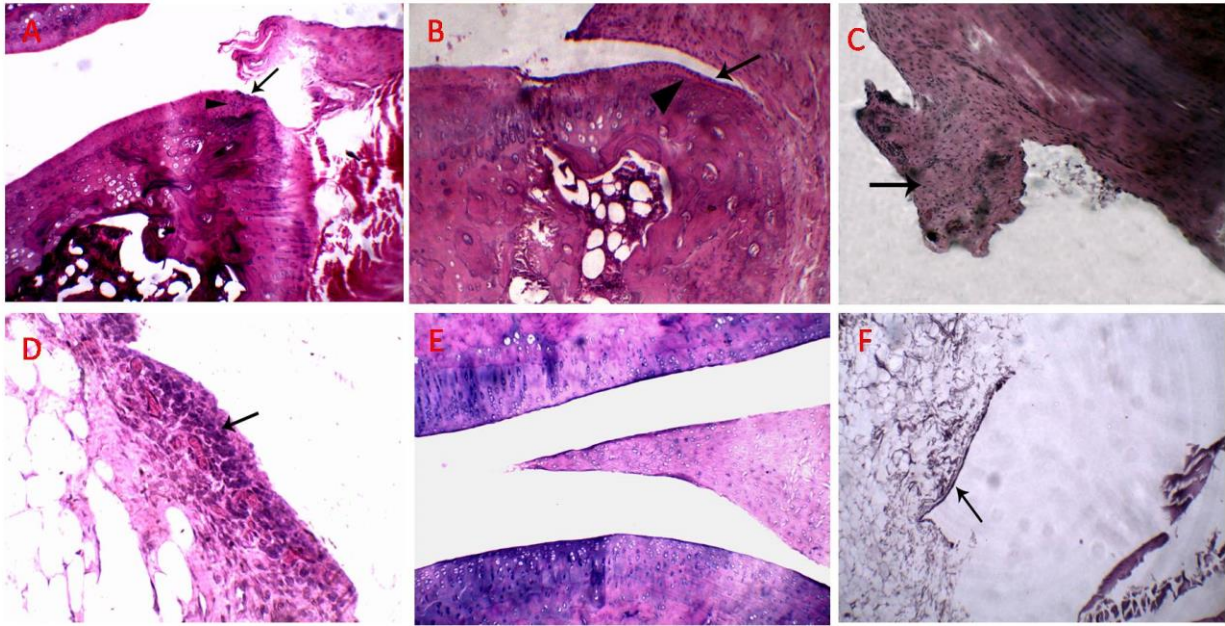
278 increase in expression in the articular cartilage (Fig.6D) as compared to all treated groups but
279 showed no significant improvement in histological score in expression in the articular cartilage as
280 compared to OA group(Table 4).

281



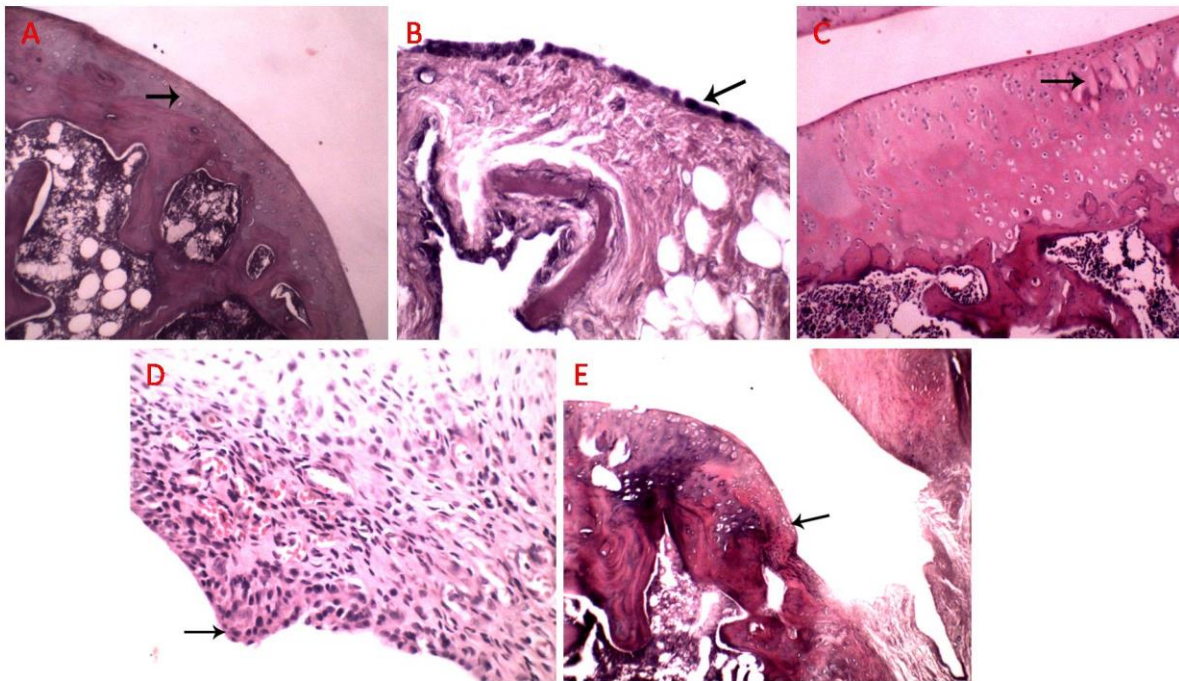
282

283 **Fig.1.**Gross morphological observations of articular cartilage in the knees of the rat show severe erosion with granular
284 (fibrillation) appearance in joint surface (black arrow; A) in The OA group;smooth and glistering articular surface
285 with no fibrillation or erosions (black arrow;B) in normal group; congestion and intense red spots distributed in the
286 almost of articular cartilage (black arrow;C) in BMSCs group; better efficiency in regenerating of articular surface
287 (black arrow; D,E) in ADSCs group; and marked erosion of cartilage exposing underlying vascularized tissue(black
288 arrow;F,G) in PBS group.



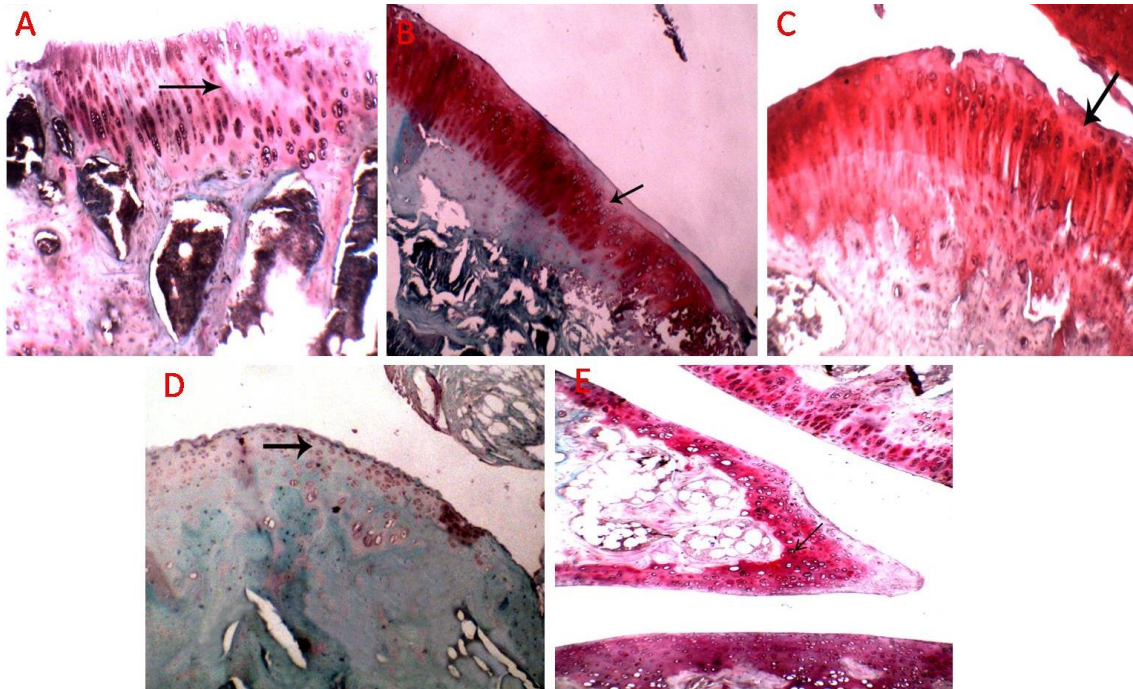
289

290 **Fig.2.** Histological view of femoral condyles at week 10 after surgery. H&E staining .The OA group at week 10 A,B,C
 291 (HE, 100x) ,D (HE, 400x) ; The control group E (HE, 100x),F (HE, 400x).



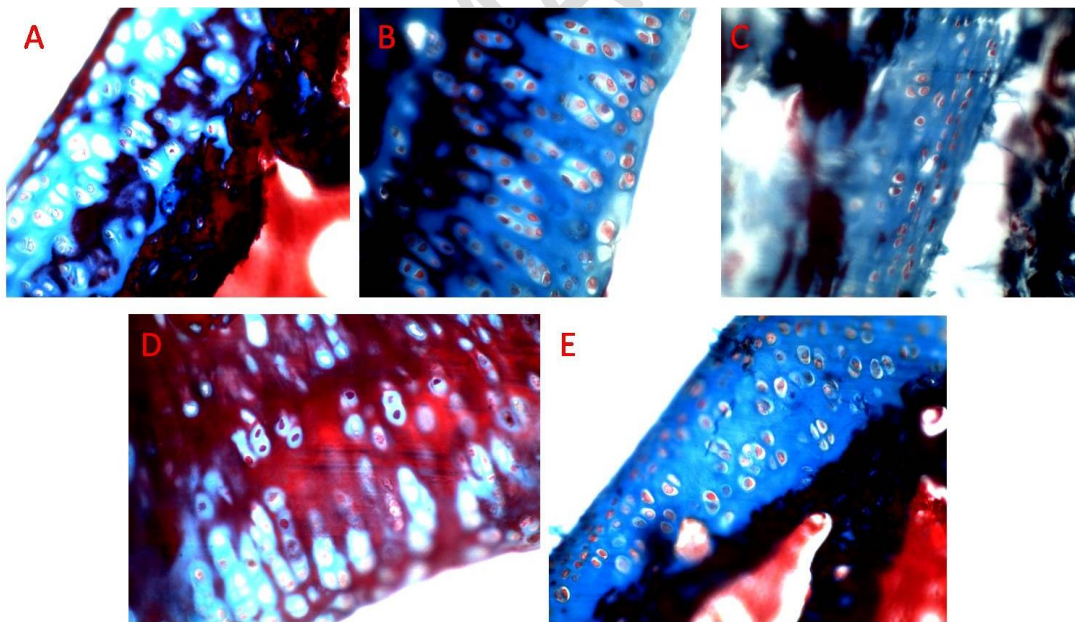
292
 293

294 **Fig.3.** Histological view of femoral condyles at week 10 after surgery. H&E staining the ADSCs group at week 10 A
 295 (HE, 100x), B (HE, 400x) ;The BMSCs group at week 10 C (HE, 100x), D (HE, 400x);The PBS group E (HE,
 296 100x).



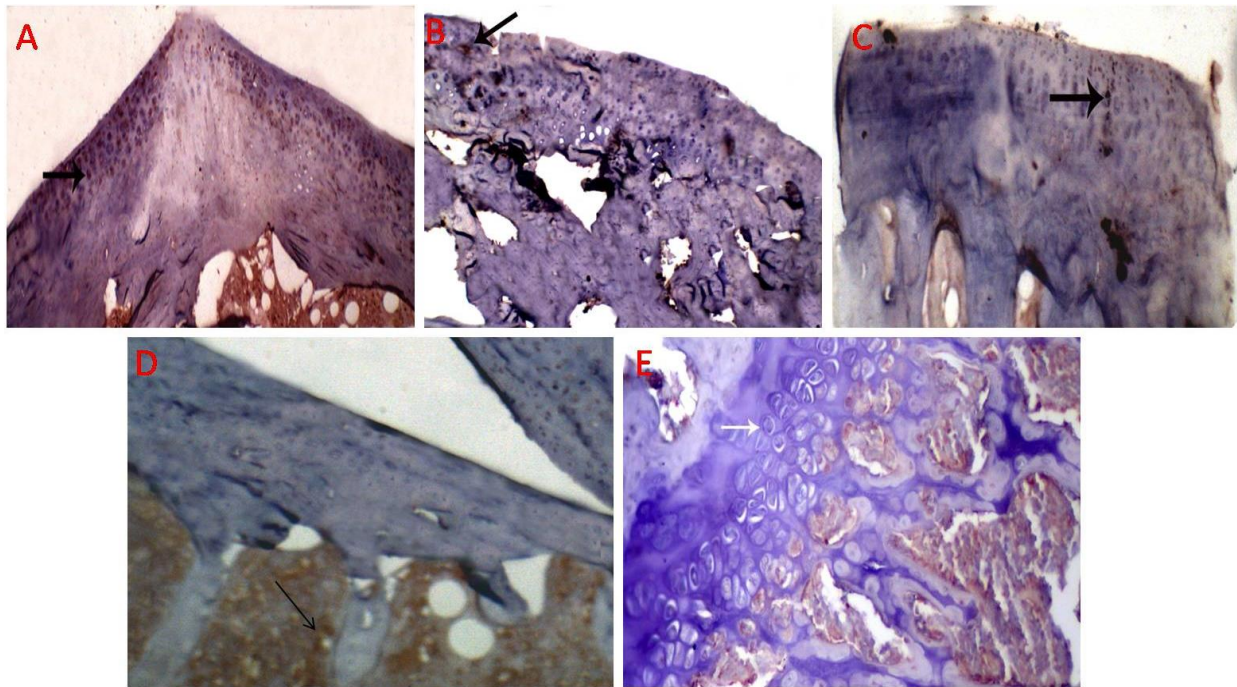
297

298 **Fig.4.** Histological view of femoral condyles at week 10 after surgery. The OA group at week 10 A (safranin O stain,
 299 100x); the ADSCs group at week 10 B (safranin O stain, 100x); The BMSCs group at week 10 C (safranin O stain,
 300 100x) ;The PBS group D (safranin O stain, 100x); The control group E (safranin O stain, 100x).



301

302 **Fig.5.** Histological view of femoral condyles at week 10 after surgery. The OA group at week 10 A (Masson trichrome,
 303 400x); the ADSCs group at week 10 B (Masson trichrome, 400x); The BMSCs group at week 10 C (Masson trichrome,
 304 400x); The PBS group D (Masson trichrome, 400x); the control group E (Masson trichrome, 400x).



305

306 **Fig.6.** Histological view of femoral condyles at week 10 after surgery.The OA group at week 10 A (IHC, DAB
 307 immunostain, hematoxylline as counter stain, 100x); the ADSCs group at week 10 B (IHC, DAB immunostain,
 308 hematoxylline as counter stain, 100x);The BMSCs group at week 10 C (IHC, DAB immunostain, hematoxylline as
 309 counter stain, 100x) ;The PBS group D (IHC, DAB immunostain, hematoxylline as counter stain, 100x); The control
 310 group E (IHC, DAB immunostain, hematoxylline as counter stain, 100x).
 311

312 **Table 2.** Mean \pm SD of assessment of secondary mechanical hyperalgesia using an analgesiometer and assessment
 313 of joint stiffness by measurement of maximum extension angle of the knee.

Groups	Withdrawal threshold (g)	Maximum extension angle of the knee
Control group	23.94 \pm 0.45 ^a	22.50 \pm 2.26 ^b
Diseased group	12.07 \pm 3.57 ^c	53.83 \pm 3.06 ^a
ADSCs treated group	16.59 \pm 1.12 ^b	27.26 \pm 2.14 ^b
BMSCs treated group	13.37 \pm 0.97 ^{bc}	39.15 \pm 2.26 ^a
PBS group	14.30 \pm 1.42 ^{bc}	51.50 \pm 2.26 ^a

314 Means with different superscript litters for each parameter are significantly different at $P \leq 0.05$.

315 **Table 3.**Median and range of histopathological evaluation of articular cartilage in the knees of the rat using
 316 Histopathological Mankin score.

Histopathological Mankin score				
Groups	Cartilage structure	Chondrocytes	Safranin-O Staining	Tidemark
Control group	0.17 ^d (0.00-1.00)	0.00 ^c (0.00-0.00)	0.00 ^c (0.00-0.00)	0.11 ^b (0.00-0.00)
Diseased group	3.50 ^a (3.00-4.00)	2.50 ^a (2.00-3.00)	3.33 ^a (3.00-4.00)	1.00 ^a (1.00-1.00)
ADSCs treated group	1.33 ^c (1.00-2.00)	1.00 ^b (1.00-1.00)	1.00 ^b (1.00-1.00)	0.00 ^b (0.00-0.00)
BMSCs treated group	2.33 ^b (2.00-3.00)	1.67 ^{ab} (1.00-3.00)	1.33 ^b (1.00-2.00)	0.00 ^b (0.00-0.00)
PBS treated group	3.33 ^a (3.00-4.00)	2.33 ^a (2.00-3.00)	3.17 ^a (3.00-4.00)	0.67 ^a (0.00-1.00)

317 Median and range with different superscript litters for each parameter are significantly different at $P \leq 0.05$.

318 **Table 4.**Median and range of the Immunohistochemical expression against MMP9 for the enzyme matrix
 319 metalloproteinase.

Groups	The MMP9 relative expression
Control group	0.00 ^d (0.00-0.00)
Diseased group	111.20 ^a (105.00-116.00)
ADSCs treated group	23.00 ^c (18.00-29.00)
BMSCs treated group	45.00 ^b (43.00-47.00)
PBS treated group	105.60 ^a (102.00-112.00)

320 Median and range with different superscript litters for each parameter are significantly different at $P \leq 0.05$.

321

322

323 **4. DISCUSSION**

324 Osteoarthritis is the most common degenerative joint disorder, characterized by progressive
325 articular cartilage degradation, subchondral bone thickening, osteophyte formation, synovial
326 inflammation, and calcification of ligaments [26]. Its treatment is still a great challenge so in this study
327 we have tried to find an effective use of ADSCs and BMSCs for treatment surgically induced OA
328 that may be a promising in future clinical application.

329 It is known that OA treatment is usually symptomatic and non-curative, only aiming for pain
330 reduction and symptoms control [27], like analgesics and non-steroid anti-inflammatory
331 drugs [28]. Even surgical interventions, such as total knee or hip arthroplasty, could relieve pain and
332 deformity, but also induce postoperative complications [29]. So the main target of this study, is
333 therapeutic effect targeting reconstitution of articular surface and alleviating inflammation and pain to
334 optimal state which mimick the normal condition. In the present study, the ADSCs and BMSCs treated
335 rats showed a significant increase in clinical parameter, while OA-induced rat demonstrated marked
336 decrease in mechanical hyper-algesia and increased joint maximum extension. This indicates
337 decreased pain sensation and improves the state of the joint to higher degree. It was noticed that ADSCs
338 induced the best improvement and was time dependent, where rats after four weeks of treatment were
339 greatly resembling the others in the normal group, this may be due to its paracrine actions by secreting
340 various soluble and insoluble cytokines and chemokines that alleviates the pain sensation [30, 31].

341 Gross lesions show a remarkable normal cartilage covering in ADSCs and BMSCs and absence of
342 fibrillation or minutes erosion, in spite of the lesion were somewhat more pronounced in BMSCs,
343 which stated by [32], who confirmed that mesenchymal cells differentiate into chondrocytes and fill
344 cartilage lesions. Additionally, they found that direct transplantation of human MSCs into the knee
345 joints of Hartley strain guinea pigs with spontaneous OA could differentiate into chondrocytes and
346 were found to be located in new cartilage. Also [33,22] agreed with this study in observing femoral
347 condyle in ADSCs treated group founding that it was grossly evident of less articular cartilage erosion
348 and fibrillation in most regions of the articular knee surface compared with the OA group .

349 Although there are a lot of differing opinions on the disease pathogenesis but the gross lesion is
350 still the same. OA has a multifactorial etiology, including joint injury, aging, obesity, and heredity [34].
351 The present OA induced group displayed progressive articular erosion and fibrillation with multiple

352 noticed cracking, which is considered identical signs of OA, matching with the previous results [35,
353 36].

354 The gold standard in evaluation and comparison between different groups in this study is
355 histological examination. Improvements of various histopathological parameters in the adipose tissue
356 treated group in comparison with bone marrow indicate more efficiency of adipose tissue derived stem
357 cells. The adipose tissue treated group demonstrated minimal superficial fibrillation, normal
358 chondrocytes inside the lacuna, which is compatible with the results of [37], who investigated the
359 potential role of adipose tissue derived cells in alleviating OA.

360 On the contrary, BMSCs treated group showed enhancement in the histological parameters and
361 restoration of the chondroid matrix as previously mentioned [38- 40].

362 While this study results estimated that ADSCs treated group was more efficient in the restoration
363 of the chondroid matrix. The inflammatory process was pronounced attenuated in adipose tissue group
364 with nearly normal tidemark and normal vascularization without invasion of articular surface
365 comparable with other group which may be attributed to the paracrine anti-inflammatory response that
366 was initiated by adipose tissue derived cells [41- 43].

367 The chondrocytes were actively divided and surrounded by normal lacuna and well- organized
368 pattern in ADSCs and BMSCs rather than necrosis and depletion in PBS treated group. This
369 indicates the ability of differentiation and extremely regenerative role of MSCs which possess
370 multilineage differentiation potential and have ability in cell therapy for OA [44, 45]. Similarly
371 [22] agreed with this result and suggested that co cultures using ADSCs and chondrocyte
372 possessing peri-cellular matrix (PCM) are able to produce cartilaginous tissue in-vivo.

373 Also, the chondrocytes in ADSCs was apparently more normal than BMSCs, which was approved
374 by the most studied MSCs which were derived from bone marrows and adipose tissues [46]. It has been
375 shown that accessibility, processing procedures, and cell yield of MSCs obtained from adipose tissues
376 are comparable to those provided by the bone marrow [47].

377 The cartilage covering the joint surface showed marked variability so safranin O stain was used to
378 demonstrate the degree of cartilaginous matrix restoration and/or loss in different groups. The stem
379 cells treated groups displayed favorable deposition of cartilaginous matrix, on the contrary of OA
380 treated group, which displayed marked loss of cartilaginous matrix. ADSCs were more better than

381 BMSCs, implying the regenerative properties in cartilage by stem cells [48-50]. But in contrast to this
382 study, [51] found that BMSCs have an enhanced potential for chondrogenesis compared to ADSCs.

383 The decreased safranin O stain and changes between the different groups, along with the
384 appearance of surface fibrillation on the surface of articular cartilage in OA group and was minimized
385 in stem cells treated groups indicates that there is a direct correlation between stem cells and
386 proteoglycans deposition [33],The stability of matrix of articular cartilage is maintained by
387 proteoglycans[52, 53].ADSCs has stronger effect on the proteoglycans precipitation

388 The tide mark , is the destination that separates between articular surface and underlying tissue,
389 mostly affected by injury due to penetrating blood vessels to avascular surface cartilage, in attempts to
390 increases blood delivery to the surface and provides the elements for the inflammatory and reparative
391 process. The tide marks were nearly normal without penetrating blood vessels and avascular upper
392 cartilage in ADSCs and BMSCs groups, meanwhile the OA group was with proliferating angiogenesis
393 destructing the tide mark that implies the ability of stem cells to manage and reduce the levels of
394 inflammatory cytokines liberated in OA. This matched the previous results that reported by [22].The
395 regenerative effects of MSCs are attributed to its paracrine mechanisms with anti-inflammatory effects
396 [54].

397 The synovial membrane affected by the inflammatory cytokines liberated in OA appeared
398 proliferated and hyperplastic in OA group but decreased in thickness in ADSCs and BMSCs treated
399 groups.This indicates that the anti-inflammatory action of stem cells extended from the articular
400 surface to the neighboring structures. Also, they possess powerful limiting effect on liberated
401 cytokines, counteracting the adverse effect of harmful cytokines which was approved by[8,9]who
402 showed that ADSCs, when given at an early phase of experimental OA, inhibit synovial lining
403 thickening and forming of enthesophytes associated with ligaments, and cartilage destruction and
404 protect against joint destruction by both anabolic and catabolic mediators.

405 Masson trichrome is a specific stain for the collagen fiber in the chondroid matrix. It revealed loss
406 in diseased group. on the other hand, in ADSCs and BMSCs treated groups displayed marked
407 restoration andthis matched with previous results [40].Compared BMSCs treated group with the other
408 groups using Masson's trichrome staining ,it was found that BMSCs-injected group was closer to
409 normal, protected cartilage. It reduced the abnormal differentiation and proliferation and fibrosis in the
410 knee articular cartilage, thus slow down the process of cartilage degradation.

411 Histochemical staining was done to evaluate the degree of fibrosis. The results estimated that
412 ADSCs were the best in all the treated groups with minimal fibrosis, this means that the healing process
413 passes in normal consequence without any accumulation of fibrotic bundles which was reflected on
414 cartilaginous regeneration in the normal consequences and have impact on the normal movement .
415 This was agreed by [52,53]who assessed the effect of ADSCs differentiated chondrocytes (DCs) versus
416 ADSCs transplantation into the rat model of OA.

417 Immunohistochemical staining for MMP9 was done, in order to assess the degree of chondroid
418 matrix destruction and the ability of Stem cell therapy to reverse it .The results was compatible with
419 gross and histological examination where the ADSCs were the minimal expression and BMSCs was
420 the succeeding one .The highest expression was in OA group so the MMP9 results were to confirm the
421 degree of chondroid matrix destruction and loss of its proteoglycans. [55, 56]determined the
422 effectiveness of ADSCs, the expression of matrix metalloproteinase and the ability of ADSCs in
423 lowering expression in OA models.

424

425 **5. Conclusion**

426 The results of the present study demonstrated that ADSCs and BMSCs can alleviate knee OA via
427 their strong regenerative capacity on chondrocytes and increased chondroid matrix deposition. So,for
428 such positive results, ADSCs are more effective and easily available compared to BMSCs.

429

430 **Acknowledgement**

431 Many grateful thanks for Dr. Mohamed Ali Maher El-Adl Assistant Professor of Biochemistry
432 Department; Faculty of Veterinary Medicine, Mansoura University for his help in the statistical
433 analysis.

434 **Conflict of interest**

435 The authors declare that there is no any conflict of interest in the current research work.

436

437 **Animal ethics committee permission**

438 This study was approved by the Local Ethical Committee, Faculty of Medicine, Mansoura University
439 in accordance with the Ethics committee of national research Center-Egypt with registration number
440 (09/189).

441 Authors' contribution

442 M. G., A. R. and E. M. conceived of the idea, contributed to its design and coordination, helped in
443 acquisition of the data, performed the statistical analysis of the data and drafted the manuscript,
444 M.H. performed and interpreted the histopathological section, G. K. and A. Z. contributed to the
445 analysis and interpretation of the data, and revised the manuscript critically for important
446 intellectual content. All authors read and approved the final manuscript.

447

448 **6. REFERENCE**

- 449 [1] Anderson KL, O'Neill DG, Brodbelt DC, Church DB, Meeson RL, Sargan D, et al. Prevalence, duration
450 and risk factors for appendicular osteoarthritis in a UK dog population under primary veterinary care.
451 Scientific Reports. 2018;8:1-12.
- 452 [2] Trumble TN, Trotter GW, Oxford JRT, McIlwraith CW, Cammarata S, Goodnight JL, et al. Synovial fluid
453 gelatinase concentrations and matrix metalloproteinase and cytokine expression in naturally occurring
454 joint disease in horses. American Journal Of Veterinary Research. 2001;62:1467-77.
- 455 [3] An B-c, Wang Y, Jiang X, Lu H-s, Fang Z-y, Wang Y, et al. Effects of Baduanjin (八段锦) exercise on
456 knee osteoarthritis: A one-year study. Chinese Journal Of Integrative Medicine. 2013;19:143-8.
- 457 [4] Angele P, Niemeyer P, Steinwachs M, Filardo G, Gomoll AH, Kon E, et al. Chondral and osteochondral
458 operative treatment in early osteoarthritis. **Knee Surgery, Sports Traumatology, Arthroscopy.**
459 2016;24:1743-52.
- 460 [5] Wyles CC, Houdek MT, Behfar A, Sierra RJ. Mesenchymal stem cell therapy for osteoarthritis: current
461 perspectives. Stem Cells Cloning 2015;8:117.
- 462 [6] Pagani S, Borsari V, Veronesi F, Ferrari A, Cepollaro S, Torricelli P, et al. Increased chondrogenic
463 potential of mesenchymal cells from adipose tissue versus bone marrow-derived cells in osteoarthritic in
464 vitro models. Journal Of Cellular Physiology. 2017;232:1478-88.
- 465 [7] Casteilla L, Planat-Benard V, Laharrague P, Cousin B. Adipose-derived stromal cells: their identity and
466 uses in clinical trials, an update. World Journal Of Stem Cells. 2011;3:25.
- 467 [8] Ter Huurne M, Schelbergen R, Blattes R, Blom A, de Munter W, Grevers LC, et al. Antiinflammatory
468 and chondroprotective effects of intraarticular injection of adipose-derived stem cells in experimental
469 osteoarthritis. Arthritis & Rheumatism. 2012;64:3604-13.
- 470 [9] Desando G, Cavallo C, Sartoni F, Martini L, Parrilli A, Veronesi F, et al. Intra-articular delivery of
471 adipose derived stromal cells attenuates osteoarthritis progression in an experimental rabbit model.
472 Arthritis Research & Therapy. 2013;15:1-16.
- 473 [10] Gupta PK, Das AK, Chullikana A, Majumdar AS. Mesenchymal stem cells for cartilage repair in
474 osteoarthritis. Stem Cell Research & Therapy. 2012;3:1-9.
- 475 [11] Baraniak PR, McDevitt TC. Stem cell paracrine actions and tissue regeneration. Regenerative
476 Medicine. 2010;5:121-43.

477 [12] Malfait A-M, Little CB, McDougall JJ. A commentary on modelling osteoarthritis pain in small
478 animals. *Osteoarthritis And Cartilage*. 2013;21:1316-26.

479 [13] Tang Y, Pan Zy, Zou Y, He Y, Yang Py, Tang Qq, et al. A comparative assessment of adipose-derived
480 stem cells from subcutaneous and visceral fat as a potential cell source for knee osteoarthritis
481 treatment. *Journal Of Cellular And Molecular Medicine*. 2017;21:2153-62.

482 [14] Flecknell P, Lofgren JL, Dyson MC, Marini RR, Swindle MM, Wilson RP. Preanesthesia, anesthesia,
483 analgesia, and euthanasia. *Laboratory Animal Medicine: Elsevier*; 2015. p. 1135-200.

484 [15] Janusz M, Bendele A, Brown K, Taiwo Y, Hsieh L, Heitmeyer S. Induction of osteoarthritis in the rat
485 by surgical tear of the meniscus: inhibition of joint damage by a matrix metalloproteinase inhibitor.
486 *Osteoarthritis And Cartilage*. 2002;10:785-91.

487 [16] Song K, Huang M, Shi Q, Du T, Cao Y. Cultivation and identification of rat bone marrow-derived
488 mesenchymal stem cells. *Molecular Medicine Reports*. 2014;10:755-60.

489 [17] Koura SM, Salama M, El-Hussiny M, Khalil MESA, Lotfy A, Hassan SA, et al. Fluoxetine induces direct
490 inhibitory effects on mesenchymal stem cell-derived osteoprogenitor cells independent of serotonin
491 concentration. *Molecular Medicine Reports*. 2019;19:2611-9.

492 [18] Council NR. Recognition and Assessment of Pain. *Recognition and Alleviation of Pain in Laboratory*
493 *Animals: National Academies Press (US)*; 2009.

494 [19] Balaganur V, Pathak NN, Lingaraju MC, More AS, Latief N, Kumari RR, et al. Effect of S-
495 methylisothiourea, an inducible nitric oxide synthase inhibitor, in joint pain and pathology in surgically
496 induced model of osteoarthritis. *Connective Tissue Research*. 2014;55:367-77.

497 [20] Flecknell P, Waynforth H. Experimental and surgical technique in the rat. *Fundación Dialnet*.
498 1995;7:452-3.

499 [21] Rezende MUd, Gurgel HMdC, Vilaça Junior PR, Kuroba RK, Lopes ASS, Phillipi RZ, et al. Diacerhein
500 versus glucosamine in a rat model of osteoarthritis. *Clinics*. 2006;61:461-6.

501 [22] Jacer S, Shafaei H, Rad JS. An investigation on the regenerative effects of intra articular injection of
502 co-cultured adipose derived stem cells with chondron for treatment of induced osteoarthritis. *Advanced*
503 *Pharmaceutical Bulletin*. 2018;8:297.

504 [23] Charalambous CP. Biochemical and metabolic abnormalities in articular cartilage from osteo-
505 arthritic human hips. II: correlation of morphology with biochemical and metabolic data. *Classic Papers*
506 *in Orthopaedics*. Springer; 2014. p. 385-7.

507 [24] Qin T, Wu L, Hua Q, Song Z, Pan Y, Liu T. Prediction of the mechanisms of action of Shenkang in
508 chronic kidney disease: a network pharmacology study and experimental validation. *Journal Of*
509 *Ethnopharmacology*. 2020;246:112128.

510 [25] McCormick K, Salcedo J. *SPSS statistics for data analysis and visualization*. 2019.

511 [26] Chen D, Shen J, Zhao W, Wang T, Han L, Hamilton JL, et al. Osteoarthritis: toward a comprehensive
512 understanding of pathological mechanism. *Bone Research*. 2017;5:1-13.

513 [27] Ding C. Do NSAIDs affect the progression of osteoarthritis? *Inflammation*. Springer. 2002;26:139-42.

514 [28] Hermann W, Lambova S, Muller-Ladner U. Current treatment options for osteoarthritis. *Current*
515 *Rheumatology Reviews*. 2018;14:108-16.

516 [29] Khan HI, Aitken D, Chou L, McBride A, Ding C, Blizzard L, et al. A family history of knee joint
517 replacement increases the progression of knee radiographic osteoarthritis and medial tibial cartilage
518 volume loss over 10 years. *Osteoarthritis And Cartilage*. 2015;23:203-9.

519 [30] Maumus M, Manferdini C, Toupet K, Peyrafitte J-A, Ferreira R, Facchini A, et al. Adipose
520 mesenchymal stem cells protect chondrocytes from degeneration associated with osteoarthritis. *Stem*
521 *Cell Research*. 2013;11:834-44.

522 [31] Kuroda K, Kabata T, Hayashi K, Maeda T, Kajino Y, Iwai S, et al. The paracrine effect of adipose-
523 derived stem cells inhibits osteoarthritis progression. *BMC Musculoskeletal Disorders*. Springer.
524 2015;16:236.

525 [32] Sato M, Uchida K, Nakajima H, Miyazaki T, Guerrero AR, Watanabe S, et al. Direct transplantation of
526 mesenchymal stem cells into the knee joints of Hartley strain guinea pigs with spontaneous
527 osteoarthritis. *Arthritis Research & Therapy*. 2012;14:1-9.

528 [33] Mei L, Shen B, Ling P, Liu S, Xue J, Liu F, et al. Culture-expanded allogenic adipose tissue-derived
529 stem cells attenuate cartilage degeneration in an experimental rat osteoarthritis model. *PLoS One*.
530 2017;12:e0176107.

531 [34] Loeser RF, Goldring SR, Scanzello CR, Goldring MB. Osteoarthritis: a disease of the joint as an organ.
532 *Arthritis And Rheumatism*. 2012;64:1697.

533 [35] sadat Toghraie F, Razmkhah M, Gholipour MA, Faghih Z, Chenari N, Nezhad ST, et al. Scaffold-free
534 adipose-derived stem cells (ASCs) improve experimentally induced osteoarthritis in rabbits. *Archives Of*
535 *Iranian Medicine*. 2012;15:0-.

536 [36] Zhou J, Wang Y, Liu Y, Zeng H, Xu H, Lian F. Adipose derived mesenchymal stem cells alleviated
537 osteoarthritis and chondrocyte apoptosis through autophagy inducing. *Journal Of Cellular Biochemistry*.
538 2019;120:2198-212.

539 [37] Reich CM, Raabe O, Wenisch S, Bridger PS, Kramer M, Arnhold S. Isolation, culture and
540 chondrogenic differentiation of canine adipose tissue-and bone marrow-derived mesenchymal stem
541 cells—a comparative study. *Veterinary Research Communications*. Springer. 2012;36:139-48.

542 [38] Singh A, Goel S, Gupta K, Kumar M, Arun G, Patil H, et al. The role of stem cells in osteoarthritis: an
543 experimental study in rabbits. *Bone & Joint Research*. 2014;3:32-7.

544 [39] Mohammed S, Makhlof N, Baher W. The Effect of Bone Marrow Mesenchymal Stem Cells Versus
545 Methotrexate on the Knee Joint in A Rat Model of Rheumatoid Arthritis. *Journal Of Medical Histology*.
546 2018;2:45-56.

547 [40] Peng Y, Zhao R, Huang S, Xiong S, Yan Q, Jin A. Comparison of the therapeutic effect of BMSCs and
548 culture supernatant injection therapy on osteoarthritis and mechanism exploration. *Research*
549 *Square*. 2020.

550 [41] Suganuma S, Tada K, Hayashi K, Takeuchi A, Sugimoto N, Ikeda K, et al. Uncultured adipose-derived
551 regenerative cells promote peripheral nerve regeneration. *Journal Of Orthopaedic Science*. 2013;18:145-
552 51.

553 [42] Wu L, Cai X, Zhang S, Karperien M, Lin Y. Regeneration of articular cartilage by adipose tissue
554 derived mesenchymal stem cells: perspectives from stem cell biology and molecular medicine. *Journal*
555 *Of Cellular Physiology*. 2013;228:938-44.

556 [43] Veronesi F, Maglio M, Tschon M, Aldini NN, Fini M. Adipose-derived mesenchymal stem cells for
557 cartilage tissue engineering: state-of-the-art in in vivo studies. *Journal Of Biomedical Materials Research*
558 *Part A*. 2014;102:2448-66.

559 [44] Xie X, Wang Y, Zhao C, Guo S, Liu S, Jia W, et al. Comparative evaluation of MSCs from bone marrow
560 and adipose tissue seeded in PRP-derived scaffold for cartilage regeneration. *Biomaterials*.
561 2012;33:7008-18.

562 [45] Toupet K, Maumus M, Luz-Crawford P, Lombardo E, Lopez-Belmonte J, van Lent P, et al. Survival
563 and biodistribution of xenogenic adipose mesenchymal stem cells is not affected by the degree of
564 inflammation in arthritis. *PLoS One*. 2015;10:e0114962.

565 [46] Parker AM, Katz AJ. Adipose-derived stem cells for the regeneration of damaged tissues. *Expert*
566 *Opinion On Biological Therapy*. 2006;6:567-78.

567 [47] Tonchev AB, BeÅ J, Fiore M, RanÄ iÄ G, Chechi K, BojaniÄ V, et al. Adipobiology of stem cell-based
568 therapy: secretome insight. *Biomedical Reviews*. 2010;21:57-63.

569 [48] Al Faqeh H, Hamdan BMYN, Chen HC, Aminuddin BS, Ruszymah BHI. The potential of intra-articular
570 injection of chondrogenic-induced bone marrow stem cells to retard the progression of osteoarthritis in
571 a sheep model. *Experimental Gerontology*. 2012;47:458-64.

- 572 [49] Ude CC, Sulaiman SB, Min-Hwei N, Hui-Cheng C, Ahmad J, Yahaya NM, et al. Cartilage regeneration
573 by chondrogenic induced adult stem cells in osteoarthritic sheep model. PLoS One. 2014;9:e98770.
- 574 [50] Basu J, Ludlow JW. Exosomes for repair, regeneration and rejuvenation. Expert Opinion On
575 Biological Therapy. 2016;16:489-506.
- 576 [51] Hennig T, Lorenz H, Thiel A, Goetzke K, Dickhut A, Geiger F, et al. Reduced chondrogenic potential of
577 adipose tissue derived stromal cells correlates with an altered TGF β receptor and BMP profile and is
578 overcome by BMP-6. Journal Of Cellular Physiology. 2007;211:682-91.
- 579 [52] Latief N, Raza FA, Bhatti FUR, Tarar MN, Khan SN, Riazuddin S. Adipose stem cells differentiated
580 chondrocytes regenerate damaged cartilage in rat model of osteoarthritis. Cell Biology International.
581 2016;40:579-88.
- 582 [53] Cha MH, Do SH, Park GR, Du P, Han K-C, Han DK, et al. Induction of re-differentiation of passaged
583 rat chondrocytes using a naturally obtained extracellular matrix microenvironment. Tissue Engineering
584 Part A. 2013;19:978-88.
- 585 [54] Cosenza S, Ruiz M, Maumus M, Jorgensen C, Noël D. Pathogenic or therapeutic extracellular vesicles
586 in rheumatic diseases: role of mesenchymal stem cell-derived vesicles. International Journal Of
587 Molecular Sciences. 2017;18:889.
- 588 [55] Shirai T, Kobayashi M, Nishitani K, Satake T, Kuroki H, Nakagawa Y, et al. Chondroprotective effect
589 of alendronate in a rabbit model of osteoarthritis. Journal Of Orthopaedic Research. 2011;29:1572-7.
- 590 [56] Dai T, Shi K, Chen G, Shen Y, Pan T. Malvidin attenuates pain and inflammation in rats with
591 osteoarthritis by suppressing NF- κ B signaling pathway. Inflammation Research. 2017;66:1075-84.

592