



RADIOGRAPHIC VOLUMETRIC ASSESSMENT OF SECONDARY ALVEOLAR CLEFT GRAFTING WITH STEM CELLS TISSUE-ENGINEERING

Abdullah Ahmed Ali^a, Khaled Mohammad Ali^b, Dina Sabry Abd-Alfattah³

ABSTRACT

Objective: To compare the radiographic outcome of alveolar cleft bone grafting with expanded mesenchymal stem cells (MSCs) seeded into a resorbable matrix to standard iliac cancellous bone graft. **Subjects and methods:** Fifteen patients with unilateral alveolar cleft aged 7-12 years old were randomly divided into two groups: Group I: Alveolar cleft grafting with expanded autogenous bone marrow stem cells seeded in collagen sponge, platelet rich plasma and nanohydroxyapatite. Group II: Alveolar cleft grafting with cancellous bone harvested from anterior iliac crest. Ideal cleft volume was calculated from cone beam CT with computer aided engineering. Follow up evaluation with cone beam CT and Bone fill was calculated on three and six months postoperatively. **Results:** The mean ideal cleft volume was 678 mm³ and 726 mm³ in group I and group II respectively with no significant difference. At three months postoperatively, there was a Significant difference in the mean volume of bone fill (BF) between group I and group II (7% BF and 47% BF respectively). Furthermore, the difference increased significantly at six months to become 10% BF in group I and 60% BF in group II. **Conclusion:** The hybridized scaffold used in the study for seeding of stem cells that contains collagen sponge, PRP and nanohydroxyapatite still needs improvement in mechanical and biodegradation properties to support bone tissue engineering. Moreover, the radiographic volumetric analysis of cancellous bone graft which is the gold standard revealed suboptimal results that needs further researches to improve the outcome.

KEY WORDS: Radiographic assessment, Volumetric assessment, Stem Cells tissue engineering, Alveolar Cleft.

INTRODUCTION

The alveolar cleft is a maxillary bone defect resulting from incomplete fusion of the facial processes during embryonic development⁽¹⁾. For patients with cleft lip and palate, secondary alveolar bone grafting is performed when the patient has mixed dentition to create a bony bridge that restores dental arch continuity, repair the oronasal fistula, provide support to the structure of the alar base,

facilitate subsequent orthodontic treatment, and promote tooth eruption⁽²⁾.

The ideal treatment of alveolar cleft is not yet settled. Even good results were achieved with cancellous bone grafting which become the gold standard, the technique still has some concerns; it needs another donor site with many possible complications⁽³⁾. So, cleft lip and palate surgeons are looking for smart solution and searching for

1. Assistant lecturer, Oral and Maxillofacial Surgery, Faculty of Dental Medicine for Boys, Al- Azhar University, Cairo, Egypt.
2. Professor, Department of Oral and Maxillofacial Surgery, Faculty of Dental Medicine for Boys, Al-Azhar University, Cairo, Egypt.
3. Professor, Molecular biology, Department of Biochemistry, Faculty of Medicine, Cairo university, Cairo, Egypt.

• **Corresponding author:** d.abdallah08@gmail.com

DOI: 10.21608/ajdsm.2020.47539.1126

more conservative techniques that fulfill the optimal replacement with less complications.

In attempt to do that, many trials, materials, techniques and different outcome measures have been used other than cancellous bone grafting⁽⁴⁻⁶⁾. Different alloplastic biomaterials, such as hydroxyapatite and tricalcium phosphate either alone or in combination with cancellous bone graft, are used to fill in or to bridge bony defects⁽⁷⁾. In growing individuals, these materials may affect physiologic features such as tooth eruption and jaw development. Non resorbable hydroxyapatite, for example, impedes tooth eruption and distorts tooth development by initiating a dense cellular fibrous network within the dental follicle, preventing the formation of an eruptive pathway⁽⁸⁾.

Recently, stem cell tissue engineering is a promising technique for replacing many defective tissues and for alveolar cleft reconstruction^(9,10). To have a good conclusion of effectiveness of stem cell tissue engineering in alveolar cleft, accurate volumetric assessment⁽¹¹⁾ was needed to compare it with autogenous cancellous bone graft done by the same operator and with the same technique. That was the aim of our study.

SUBJECTS AND METHODS

Study design:

A prospective randomized controlled clinical study was approved by the ethical committee of faculty of dental medicine, Al-Azhar university. Fifteen patients with unilateral alveolar cleft with mean age of 9.93 years old (range: 7-12 years, eight girls and seven boys) were selected from those attending the outpatient clinic of Oral and Maxillofacial Surgery, Faculty of Dental Medicine, Al-Azhar University, Cairo, Egypt, according to the following inclusion criteria: Patients with unilateral alveolar cleft that require secondary alveolar cleft grafting and aged from 7 to 12 years old.

However, Patients with bilateral alveolar cleft, Patients with previous attempt of surgical closure of alveolar cleft, Patients with diseases affecting bone healing i.e. patients on cortisone and diabetic patients, Severely misaligned maxillary segment that require successive surgical and orthodontic correction before grafting and Syndromic patients were excluded from the study. To be included in the study, the parents signed a written consent form having all details about the procedure and acceptance to be a part of this study. All patients were randomly divided, according to grafting technique, into two groups:

Group I: Alveolar cleft grafting with expanded autogenous bone marrow stem cells seeded in collagen sponge, platelet rich plasma and nanohydroxyapatite.

Group II: Alveolar cleft grafting with cancellous bone harvested from anterior iliac crest.

I- Patient evaluation: patient history and Clinical examination were recorded including soft tissue condition, gingival health, presence of labionasal and palatal fistulae and dental condition. Also, pre-operative CBCT was acquired on maxilla for assessment of bone defect and dental status.

II- Surgical procedure:

II-A. Donor site preparation:

Cell Preparation (Group I, Stem cell group): Four weeks before grafting, under deep sedation and local anesthesia, 20 ml bone marrow was aspirated in the operating theatre under aseptic conditions from anterior iliac crest with bone marrow aspiration needle and placed in heparinized tubes for culturing and expansion. The bone marrow aspirate was carried on ice in sealed containers to the Molecular Biology and Tissue Engineering Unit (MBTEU) in the Department of Medical Biochemistry at Cairo University where cell cultures were performed. After reaching an average count of 5×10^6 , the cultured cells were collected and resuspended in 1 ml phosphate buffered saline and transferred to the operating room in sterile tubes on the day of surgery⁽¹²⁾.

Cancellous bone grafting (Group II): The operations were performed by the same oral and maxillofacial surgeon. Under general anesthesia, routine draping and sterilization protocol were applied to expose the anterior iliac crest. Incision is made over the anterior iliac crest and deepened to the deep fascia. The musculofascial attachment of the abdominal wall muscles to the iliac crest is defined and any fatty covering should be cleared off to expose the attachment of these fascia. Incision, elevation and reflection of the periosteum was done to expose the superior surface of the iliac bone. Cancellous bone was harvested and collected in a sterile gauze. Wound was closed in layers.

II-B. Recipient site preparation (Alveolar cleft site) in all patients:

Under general anesthesia, a labial incision was made along the gingival border from the first permanent molar to the contralateral central incisor with vertical releasing incisions. Circular incision around the edges of the cleft was performed separating nasal and oral layers. Nasal mucosa was reflected cephalically to reconstruct nasal floor. Oronasal fistula was closed. Prior to graft insertion bur holes were drilled using surgical round burs in the bone bordering the recipient site to accelerate healing and graft incorporation.

Graft preparation and insertion: For group I, PRP was prepared. 12 ml blood was aspirated and collected into citrated tubes then centrifuged at 3500 rpm for 15 min at room temperature using a multi-speed 4000 rpm vertical rotor. Expanded stem cells were seeded into several cones of collagen sponge (Resorba Company). Nanohydroxyapatite (sigma Aldrich) and PRP were added. The hybrid scaffold was gently packed into the defect. For group II, the cancellous bone chips were packed and condensed into the prepared alveolar cleft site against the reconstructed nasal floor until slight overfilling was achieved. The gingival mucoperiosteal flaps were sutured. The wound was checked daily for primary wound healing. Antibiotic coverage was administered (Augmentin 100 mg / kg/ day in two

divided dose for five days). Ibuprofen syrup was prescribed four times daily for three days. Alpha-Amylase syrup 3 was taken three times daily for three days. Also, nasal decongestant drops were prescribed twice daily for three days in addition to daily repeated use of warm saline mouth rinse. The patient was discharged after 6 days.

III- Radiographic evaluation:

CBCT were acquired 1 week preoperatively, three and six months postoperatively using Planmeca ProMax 3D Classic machine (Planmeca, Helsinki, Finland). A standard CBCT scanning protocol was applied (Fig.1).

Data acquisition: The ideal alveolar cleft defect shape and volume (DV) were determined using reverse-engineering software⁽¹³⁾. Preoperative DICOM (Digital Imaging and Communications in Medicine) data from the CBCT images were processed and saved in the standard triangulated language (STL) format by image analysis software (Mimics; Materialise, Leuven, Belgium). Maxillary bone was mirrored by Geomagic Wrap 2017 software. (Geomagic, Morrisville, North California) (Fig.2). The original and mirror-reversed 3D objects were precisely adjusted by automatic registration. Then, the bone defect was segmented and calculated.

Newly formed bone volume measurement: Postoperative DICOM data from the CBCT images were processed by Mimics software and reconstructed as 3D images and saved in the STL format. Preoperative and postoperative STL data were aligned (registration), superimposed by Geomagic Wrap 2017 (Fig.3). Boolean algebra operation was used to subtract preoperative STL data (DV) from 3 and 6-month postoperative STL data (DV₃ and DV₆ respectively). The bone fill (BF%) was calculated using the following equation:

$$\text{Bone fill at 3 months (BF}_3\%) = (DV - DV_3 / DV) \times 100\%.$$

$$\text{Bone fill at 6 months (BF}_6\%) = (DV - DV_6 / DV) \times 100\%.$$

$$\text{Bone fill between 3 and 6 months (BF}_{3,6}\%) = (DV_3 - DV_6 / DV_3) \times 100\%.$$

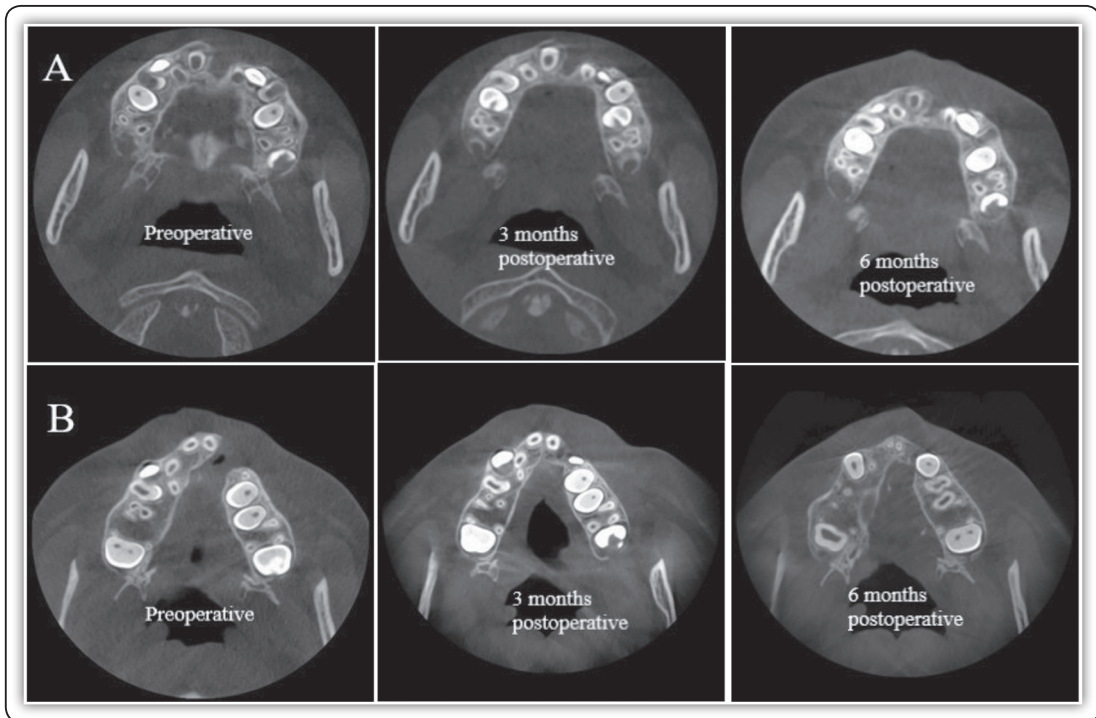


FIG (1) A- CBCT images (axial cuts) for a case in group I. B- CBCT images (axial cuts) for a case in group II.

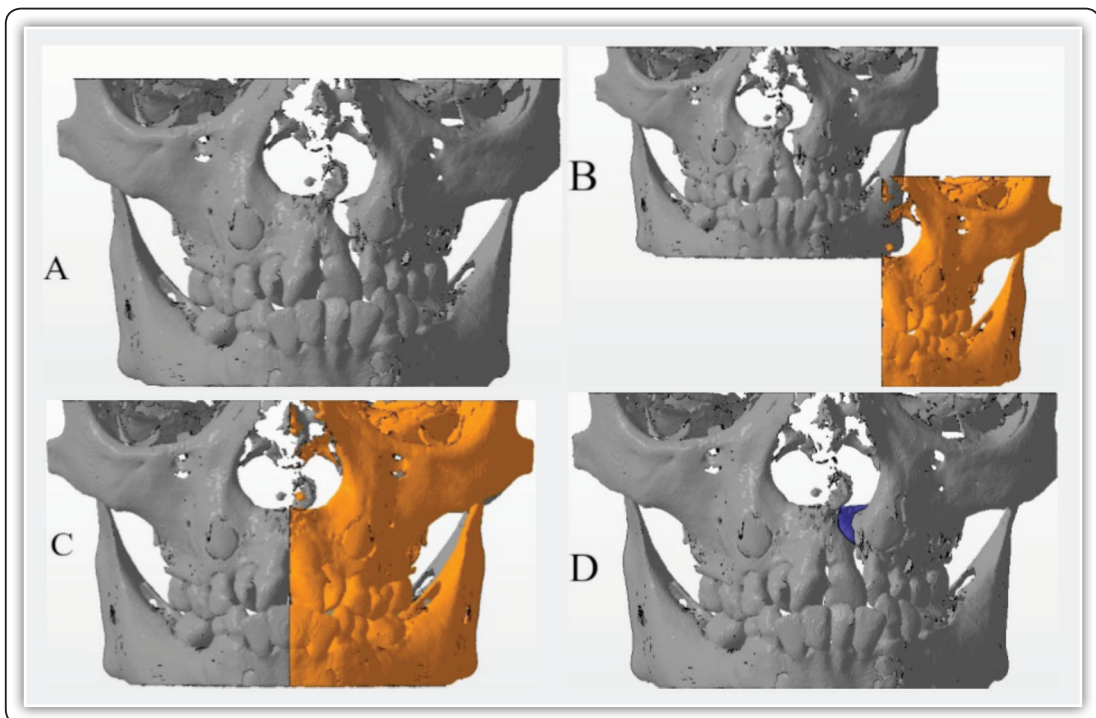


FIG (2) Preoperative alveolar defect volume segmentation. A- Preoperative 3D virtual head models (gray) of alveolar cleft patient. B- The grey model represents the original preoperative model and the orange one represents the mirror image of non-cleft side. C- Alignment and superimposition of the mirrored non cleft side on the cleft side. D- Segmentation of alveolar defect volume (blue).




FIG (3) A) Three-dimensional virtual head models. The red represents the preoperative model and the blue represents the 3-month postoperative one. The blue and red model represents the superimposition. B) Three-dimensional virtual head models. The red represents the preoperative model and the yellow represents the 6-month postoperative one. The yellow and red model represents the superimposition.

Statistical analysis

The collected data was revised, coded, tabulated and introduced to a personal computer using Statistical package for Social Science (IBM Corp. Released 2013. IBM SPSS Statistics for Windows, Version 22. Armonk, NY: IBM Corp). Mean, Standard deviation (SD), Minimum and maximum values (range) for numerical data and Frequency and percentage of non-numerical data were calculated. Paired-Samples T Test was used to assess the statistical significance of the difference among the volumetric changes within each group. Independent-Samples T Test was used to assess the statistical significance of the difference between group I and group II. Chi-square test was used to assess the suitability of both groups for comparisons regarding the age, gender. P- Value was set ($P > 0.05$: Non-significant {NS}, $P < 0.05$: Significant {S} and $P < 0.01$: Highly significant {HS}).

RESULTS

Pre-operatively, the mean ideal alveolar cleft defect volume in group I was $677.9 \text{ mm}^3 (\pm 92.13)$ while in group II was $726.79 \text{ mm}^3 (\pm 234.09)$ when

independent T-test was applied, there was no statistical significant difference between the two groups ($P = 0.128$).

At three months, the mean defect volume was $629.97 \text{ mm}^3 (\pm 89.51)$ and $361.39 \text{ mm}^3 (\pm 248.45)$ in group I and II respectively. After six months, the mean defect volume was $567.07 \text{ mm}^3 (\pm 68.7)$ and $229.89 \text{ mm}^3 (\pm 203.64)$ in group I and II respectively table (1).

In group I, at 3 months there is a decrease in defect volume significantly with p value 0.002 with more decreasing in defect volume significantly after 6 months with p value 0.0009. As regard group II, by comparing the cleft defect volume in group II preoperatively and after 3 months, we found that there is decreasing in alveolar defect volume significantly followed by significant reduction after 6 months with p value= 0.002.

As regard comparison of alveolar defect reduction in the graft in group I and II, we found significant reduction of defect volume on follow up after 3 months (p value =0.001), after 6 months (p value=0.0001) and from 3 to 6 months (p value=0.0014) as shown in table (2) and figure (4).

TABLE (1) Distribution of volumetric data of alveolar cleft defect in both groups.

Groups / intervals post-operative		Defect volume (DV) (mm3)			
		Min	Max	Mean	Std. Deviation
Group I	Preoperative	535.9	801.6	677.97	92.132
	3 months	492.75	761.52	629.97	89.512
	6 months	471.32	673.29	567.17	68.708
Group II	Preoperative	535.67	1211.4	726.79	234.093
	3 months	208.91	819.9	399.57	231.671
	6 months	128.56	619.9	308.41	204.717

TABLE (2): Percentage of bone fill (BF) in both groups. BF1-3 %: (Preoperative -3 months). BF1-6%: (Preoperative -6months) BF3-6 %:(3 months - 6 months)

	BF 1-3		BF 1-6		BF 3-6	
	Group I	Group II	Group I	Group II	Group I	Group II
1	5%	21%	20%	26%	16%	6%
2	9%	61%	20%	76%	12%	38%
3	8%	42%	12%	69%	4%	65%
4	6%	32%	19%	49%	14%	24%
5	5%	56%	15%	65%	11%	20%
6	7%	65%	14%	69%	8%	11%
7	9%	55%	13%	68%	4%	29%
8	8%		16%		9%	
Mean	7%	47%	16%	60%	10%	28%

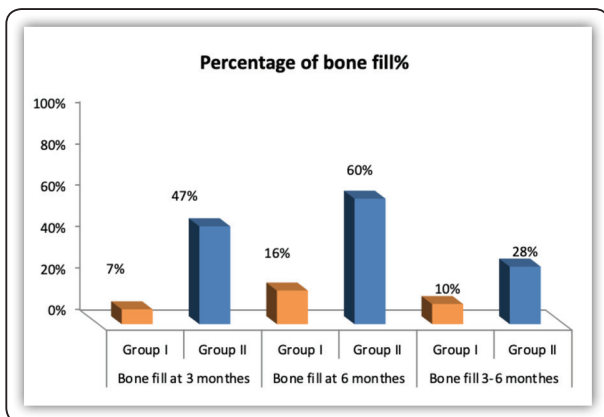


FIG (4) Bar chart presenting comparison of bone fill of the graft through post-operative 3 and 6 months follow up in both groups.

DISCUSSION

The alveolar cleft reconstruction is a significant component of the cleft lip surgical treatment protocol. However, the ideal treatment of alveolar cleft is not yet settled. Even we achieved good results with cancellous bone grafting which become the gold standard, the technique still has some concerns; it needs another donor site with possible complications⁽³⁾.

Recently, stem cell tissue engineering is a promising technique for replacing many defective tissues and for alveolar cleft^(9,10). To have a good conclusion of effectiveness of stem cell tissue

engineering, we need to compare it with autogenous cancellous bone done by the same operator and with the same technique. That what we did in our study.

In this study, the iliac crest was selected for aspiration of bone marrow mesenchymal stem cells (BMMSCs) according to previous positive results^(14,15). The technique of multiplication of stem cells was used in many publications and considered as a standard for cell culturing and expansion^(12,16,17). The collagen type 1 and nano-hydroxyapatite COLI/n-HA was used as a scaffold for seeding the BMMSCs according to reported positive results in enhanced bone formation by increasing the proliferation and differentiation of osteoblasts in vivo and in vitro^(18,19). The platelet rich plasma (PRP) was used to deliver growth factors to the graft⁽²⁰⁾. In the present study, the hybridized scaffold was used to promote biocompatibility and osteogenic induction of BMMSCs.

Although different clinical methods have been employed for the evaluation of secondary ACG outcomes, radiographic assessment is a method as important as, or even superior to, clinical evaluation. Currently, 3D X-ray imaging is the standard method used to verify treatment outcomes of alveolar bone grafts⁽²¹⁾. Cone-beam CT may be offered as an alternative to helical CT because of its advantages, such as lower effective radiation dose, shorter exposure times, and easy access⁽²²⁾.

In this study, all patients were scanned by CBCT (Promax 3D classic, Planmeca, Helsinki, Finland). Moreover, to reduce radiation exposure, we used small field of view (≤ 10 cm height \times 10 cm width) with optimization of machine setting. From the literature, the effective dose of the same machine for small field of view of standard exposure of the child was 38 μ Sv⁽²³⁾. Sum calculation of the effective doses of the three CBCT scans required for assessment along the follow up time was 114 μ Sv which is lower than the effective dose from a single CT examination of the head⁽²⁴⁾.

Recently, 3D volumetric analysis has been widely used to assess the outcomes of bone grafting in patients with clefts⁽²⁵⁾. Linderup et al⁽²⁶⁾ introduced a novel semiautomatic technique for volumetric assessment of alveolar grafts using standardized image acquisition including anatomical boundaries of the alveolar bone defect. Cranio-caudal and bucco-palatal boundaries are often difficult to discriminate; therefore, Janssen et al⁽²²⁾ tried to overcome the difficulty by mirroring the contralateral unaffected side over the alveolar cleft defect to delineate the original bony boundaries of the defect.

In this study, the newly formed actual bone was indirectly calculated by subtracting the postoperative defect volume from the preoperative defect volume. The ideal defect volume was estimated by computer aided engineering software using mirror-reversed techniques to obtain the ideal alveolar bone morphology. Image superimposition of the contralateral side over the defect could also reduce observer dependency when attempting to identify the bucco-palatal borders⁽²²⁾. This greatly decreased the chances of manual errors.

However, there were an important limitation associated with this method that need to be resolved. After surgery, patients with alveolar clefts still experience skeletal growth and eruption of teeth in the maxillary complex which might influence the results.

In the current study, defect volume assessment reveals significant primary ossification at 3 months post-operative in group I and group II (7% - 54% respectively). Group II showed higher percentage of ossification than group I. This may be due to lack of enough strength of collagen sponge to support the original graft volume and its partial resorption in group I and lesser resorption rate of cancellous bone in group II. Behnia et al⁽²⁷⁾ reported 51.3% bone formation at 3 months in their clinical study. They used PRF, PDGF and expanded MSCs on biphasic bone substitute. However, in their earlier study⁽²⁸⁾, they reported bone formation less than 50% when the scaffold lacks PRF as a supply of growth factors.

After 6 months in the current study, the ossification continued to increase to reach 16% and 72% in group I and group II respectively. Group II showed higher percentage of bone formation than group I. The most resorption occurred during the first 3 months in group II after that there was enough stability in graft volume.

Pradel et al.⁽²⁹⁾ reported 40.9% bone fill and 59.1% graft volume reduction in tissue engineered group compared to 36.6% bone fill and 63.4% graft volume reduction in autogenous group after 6 months follow up in a case series of 8 children. They concluded that tissue engineered bone is promising alternative to autogenous one. However, after complete re-ossification of the graft, it remained unclear where the former bony boundaries of the cleft were situated, since cranio-caudal and bucco-palatal boundaries are also often difficult to discriminate.

On contrary, Hibi et al.⁽³⁰⁾ described a case of alveoloplasty using injectable bone consisting of a gel of platelet-rich plasma with autogenous mesenchymal stem cells and human thrombin. However, a titanium mesh plate had to be applied to maintain the space, which was later removed to not hinder tooth eruption. At 9 months postoperatively the case showed 79.1% regenerated bone by CT. On observation, the preserved intact palatal wall as observed in CT served as a base over which the gel can be poured against. A situation that could not be present in many cases that have not only alveolar but also palatal cleft. In addition, preservation of primary graft volume by titanium mesh may play a role in larger amount of bone formation in their case. Unfortunately, exposure of hardware with loss of the graft and need to second surgery for its removal may hinder its use.

In a similar way, Khojasteh et al.⁽³¹⁾ use the lateral ramus cortical bone plate (LRCP) reconstructed as a cave with expanded stem cell from buccal pad of fat mounted on bovine bone mineral. 75% of bone fill in CT was regenerated after 6 months. The possible explanation is that, the cave of cortical bone gave a natural outline to the regenerated bone to follow,

benefit from its rigidity and slow resorption rate, larger volume of bone graft was preserved. But with the need of a second surgical site with its possible complications.

CONCLUSION

The hybridized scaffold used in the study for seeding of stem cells that contains collagen sponge, PRP and nanohydroxyapatite still needs improvement in mechanical and biodegradation properties to support bone tissue engineering. Moreover, the radiographic volumetric analysis of cancellous bone graft which is the gold standard revealed suboptimal results that needs further researches to improve the outcome.

REFERENCES

1. Seifeldin SA. Is alveolar cleft reconstruction still controversial? (Review of literature). *Saudi Dent J.* 2016 Jan;28(1):3-11.
2. Seike T, Hashimoto I, Matsumoto K, Tanaka E, Nakaniishi H. Early postoperative evaluation of secondary bone grafting into the alveolar cleft and its effects on subsequent orthodontic treatment. *J Med Invest.* 2012;59(1-2):152-65.
3. Brudnicki A, Rachwalski M, Wiepszowski L, Sawicka E. Secondary alveolar bone grafting in cleft lip and palate: A comparative analysis of donor site morbidity in different age groups. *J Craniomaxillofac Surg.* 2019 Jan;47(1):165-169.
4. Mossaad A, Badry TE, Abdelrahman M, Abdelazim A, Ghanem W, Hassan S et al. Alveolar Cleft Reconstruction Using Different Grafting Techniques. *Open Access Maced J Med Sci.* 2019 Apr 29;7(8):1369-1373.
5. Stasiak M, Wojtaszek-Słomińska A, Racka-Pilszak B. Current methods for secondary alveolar bone grafting assessment in cleft lip and palate patients - A systematic review. *J Craniomaxillofac Surg.* 2019 Apr;47(4):578-585.
6. Guo J, Li C, Zhang Q, Wu G, Deacon SA, Chen J et al. Secondary bone grafting for alveolar cleft in children with cleft lip or cleft lip and palate. *Cochrane Database Syst Rev.* 2011 Jun 15;(6):CD008050.
7. Scalzone A, Flores-Mir C, Carozza D, d'Apuzzo F, Grassia V, Perillo L. Secondary alveolar bone grafting using autologous versus alloplastic material in the treatment of cleft lip and palate patients: systematic review and meta-analysis. *Prog Orthod.* 2019 Feb 11;20(1):6.

8. Pradel W, Lauer G. Tissue-engineered bone grafts for osteoplasty in patients with cleft alveolus. *Ann Anat.* 2012 Nov;194(6):545-8.
9. Moreau JL, Caccamese JF, Coletti DP, Sauk JJ, Fisher JP. Tissue engineering solutions for cleft palates. *J Oral Maxillofac Surg.* 2007 Dec;65(12):2503-11.
10. Kamal M, Ziyab AH, Bartella A, Mitchell D, Al-Asfour A, Hölzle F et al. Volumetric comparison of autogenous bone and tissue-engineered bone replacement materials in alveolar cleft repair: a systematic review and meta-analysis. *Br J Oral Maxillofac Surg.* 2018 Jul;56(6):453-462.
11. Zhou WN, Xu YB, Jiang HB, Wan L, Du YF. Accurate Evaluation of Cone-Beam Computed Tomography to Volumetrically Assess Bone Grafting in Alveolar Cleft Patients. *J Craniofac Surg.* 2015 Sep;26(6): e535-9.
12. Kotobuki N, Hirose M, Takakura Y, and Ohgushi H. Cultured autologous human cells for hard tissue regeneration: preparation and characterization of mesenchymal stem cells from bone marrow. *Artif Organs.* 2004. 28(1): p. 33-9.
13. Du F, Li B, Yin N, Cao Y, Wang Y. Volumetric Analysis of Alveolar Bone Defect Using Three-Dimensional-Printed Models Versus Computer-Aided Engineering. *J Craniofac Surg.* 2017 Mar;28(2):383-386.
14. Narbona-Carceles J, Vaquero J, Suárez-Sancho S, Forriol F, Fernández-Santos ME. Bone marrow mesenchymal stem cell aspirates from alternative sources: is the knee as good as the iliac crest? *Injury.* 2014 Oct;45 Suppl 4:42-7.
15. McDaniel JS, Antebi B, Pilia M, Hurtgen BJ, Belenkiy S, Necsoiu C et al. Quantitative Assessment of Optimal Bone Marrow Site for the Isolation of Porcine Mesenchymal Stem Cells. *Stem Cells Int.* 2017 April; 30:1-10.
16. Abdel Aziz MT, Atta HM, Mahfouz S, Fouad HH, Roshdy NK, Ahmed HH, et al. Therapeutic potential of bone marrow-derived mesenchymal stem cells on experimental liver fibrosis. *Clin Biochem.* 2007. 40(12): p. 893-9.
17. Abdel Aziz MT, El-Asmar MF, Haidara M, Atta HM, Roshdy NK, Rashed LA, et al. Effect of bone marrow-derived mesenchymal stem cells on cardiovascular complications in diabetic rats. *Med Sci Monit.* 2008. 14(11): p. 249-55.
18. Pradel W, Tausche E, Gollogly J, Lauer G. Spontaneous tooth eruption after alveolar cleft osteoplasty using tissue-engineered bone: a case report. *Oral Surg Oral Med Oral Pathol Oral Radiol Endod.* 2008 Apr;105(4):440-4.
19. Korn P, Schulz MC, Range U, Lauer G, Pradel W. Efficacy of tissue engineered bone grafts containing mesenchymal stromal cells for cleft alveolar osteoplasty in a rat model. *J Craniofac Surg.* 2014;42(7):1277-1285.
20. Sakio R, Sakamoto Y, Ogata H, Sakamoto T, Ishii T, Kishi K. Effect of Platelet-Rich Plasma on Bone Grafting of Alveolar Clefts. *J Craniofac Surg.* 2017 Mar;28(2):486-488.
21. Stasiak M, Wojtaszek-Słomińska A, Racka-Pilszak B. Current methods for secondary alveolar bone grafting assessment in cleft lip and palate patients - A systematic review. *J Craniofac Surg.* 2019 Apr;47(4):578-585.
22. Janssen NG, Schreurs R, Bittermann GKP, Borstlap WA, Koole R, Meijer GJ et al. A novel semi-automatic segmentation protocol for volumetric assessment of alveolar cleft grafting procedures. *J Craniofac Surg.* 2017 May;45(5):685-689.
23. Ludlow JB, Timothy R, Walker C, Hunter R, Benavides E, Samuelson DB et al. Effective dose of dental CBCT-a meta-analysis of published data and additional data for nine CBCT units. *Dentomaxillofac Radiol.* 2015;44(1):20140197.
24. Ludlow JB. Dose and risk in dental diagnostic imaging: with emphasis on dosimetry of CBCT. *Korean J Oral Maxillofac Radiol.* 2009; 39:175-184.
25. Blessmann Weber JB, de Macedo Menezes L, Azeredo F, Lessa Filho LS. Volumetric assessment of alveolar clefts: a literature review. *J Oral Pathol Med.* 2017 Sep;46(8):569-573.
26. Linderup BW, Küsel A, Jensen J, Cattaneo PM. A novel semiautomatic technique for volumetric assessment of the alveolar bone defect using cone beam computed tomography. *Cleft Palate Craniofac J.* 2015 May;52(3): e47-55.
27. Behnia H, Khojasteh A, Soleimani M, Tehranchi A, Atashi A. Repair of alveolar cleft defect with mesenchymal stem cells and platelet derived growth factors: a preliminary report. *J Craniofac Surg.* 2012 Jan;40(1):2-7.
28. Behnia H, Khojasteh A, Soleimani M, Tehranchi A, Khoshzaban A, Keshel SH et al. Secondary repair of alveolar clefts using human mesenchymal stem cells. *Oral Surg Oral Med Oral Pathol Oral Radiol Endod.* 2009 Aug;108(2): e1-6.
29. Pradel W, Lauer G. Tissue-engineered bone grafts for osteoplasty in patients with cleft alveolus. *Ann Anat.* 2012 Nov;194(6):545-8.
30. Hibi H, Yamada Y, Ueda M, Endo Y. Alveolar cleft osteoplasty using tissue-engineered osteogenic material. *Int J Oral Maxillofac Surg.* 2006 Jun;35(6):551-5.
31. Khojasteh A, Kheiri L, Behnia H, Tehranchi A, Nazeman P, Nadjmi N et al. Lateral Ramus Cortical Bone Plate in Alveolar Cleft Osteoplasty with Concomitant Use of Buccal Fat Pad Derived Cells and Autogenous Bone: Phase I Clinical Trial. *Biomed Res Int.* 2017; 2017:6560234.