



Molecular Assessment of *Theileria equi* infection in Horses in Egypt

Mostafa Al-Araby^{1, #},
Shimaa Abd El-Salam
El-Sayed^{2, #}, **Mohamed**
Abdo Rizk^{3,4, *}

¹ Department of Parasitology,
Faculty of Veterinary Medicine,
Mansoura University, Mansoura
35516, Egypt

² Department of Biochemistry
and Chemistry of Nutrition,
Faculty of Veterinary Medicine,
Mansoura University, Mansoura
35516, Egypt

³ Department of Internal
Medicine and Infectious
Diseases, Faculty of Veterinary
Medicine, Mansoura
University, Mansoura 35516,
Egypt

⁴ National Research Center for
Protozoan Diseases, Obihiro
University of Agriculture and
Veterinary Medicine, Inada-
Cho, Obihiro, Hokkaido, Japan
these authors equally
contributed in this work

***Corresponding author**

Mohamed Abdo Rizk,
Department of Internal
Medicine and Infectious
Diseases, Faculty of
Veterinary Medicine,
Mansoura University,
Mansoura 35516, Egypt, E-
mail address:
dr_moh_abdo2008@mans.edu
.eg, ORCID: 0000-0002-5250-
6172.

**Accepted: January
2021**

Abstract

In the current study, blood–DNA samples were collected from horses (n= 147) reared in Dakahlia province, Egypt to conduct an epidemiological survey of *Theileria equi*. Microscopic examination of Giema stained blood smears was used for initial detection of the infected animals. *T. equi* was detected in nine (6%) blood smears. Using a species-specific PCR reaction targeting the *T. equi* merozoite antigen-1. *T. equi* was found in 14 (9.52%) of the examined horse samples. Subsequently, five horses were carrier for the infection without any apparent clinical signs or detection of the parasite in the examined blood smears. To summarize, the results demonstrated the occurrence of *T. equi* in horses in Egypt, either as acute infection or carriers. These findings have economic implications and highlight the urgency of implementing effective prophylactic and control strategies across Egypt to reduce incidence of equine piroplasmiasis.

Keywords:

Theileria equi, Egypt, PCR, Horse.

INTRODUCTION

Equine piroplasmosis is a parasitic disease transmitted by hard ticks that affecting horses, mules, and donkeys with significant economic losses (Garba et al., 2011). Equine piroplasmosis is caused by *Theileria equi* (*T. equi*) and *Babesia caballi* and characterized by severe hemolysis of erythrocytes, hemoglobinuria, severe anemia, icterus, and sometimes deaths (El-Sayed et al., 2015). As a result, treating such cases will demand a massive cash budget, and performance will suffer greatly of the challenges in fulfilling international export regulations or competing in equestrian sports events (Hussain et al., 2014). The disease could be found all over the world in tropical and subtropical areas, including Europe, Africa and Asia (Hussain et al., 2014). Remarkably, the majority of animals that recover from parasitic diseases as *Babesia spp.* and *Theileria spp.* become carriers for the infection (Calder et al., 1996). Furthermore, some animals have a subclinical illness and are resistant to clinical piroplasmosis. (Bock et al., 2004). It is also necessary to recognize carriers and subclinical infections in horses in order to establish the level of threat caused by *Babesia* and *Theileria* parasites. As a result, epidemiological surveys based on infection molecular diagnoses are required to

investigate the efficacy of current parasite effective management. As a result, parasite management strategies should be improved based on findings of such surveys. Tick-borne diseases have been found due to the adoption of high - sensitivity molecular techniques that have enabled researchers to better understand their epidemiology. Standard microscopical approaches are inefficient for diagnosing carriers in these animals due to their low parasitemia. The PCR technique's sensitivity in detecting infection with low parasitemia, on the other hand, has been observed (Rosales et al., 2013). PCR also can detect parasite DNA during the acute phase of infection, when antibodies are not yet detectable by serological diagnostic tools (Rosales et al., 2013). As a result, for epidemiologic studies of *Babesia* and *Theileria* infection, DNA detection techniques such as PCR assays are preferred (Mosqueda et al., 2012).

Clinical illnesses caused by *Theileria equi* are common in Egyptian horses (Mahmoud et al., 2016). Several epidemiological investigations of *Theileria equi* have already been conducted in Egypt (Mahmoud et al., 2016). However, most of previous epidemiological studies have focused on microscopy as well as serological approaches to detect infection. As a result, we conducted an epidemiological survey of *T. equi* in the present study, using blood–DNA samples collected from horses reared in Dakahlia province.

MATERIALS AND METHODS

1. Animals and clinical examination

A total of 147 blood samples were obtained from horses reared in Dakahlia province in the north of Egypt (Fig. 1). Blood specimens were collected from all animals to be examined for the presence of *T. equi* infection. Nine horses out of 147 revealed clinical manifestations such as fever, discoloration in mucous membrane, and lymphadenopathy of equine piroplasmosis, with *T. equi* infection confirmed by microscopic examination of Giemsa-stained blood smears (Fig. 2). During the sampling period, other animals appeared to be in good health (Table 1).

2. PCR detection of *Theileria equi*

Whole blood were collected from each animal and the nucleic acid was extracted using a commercial kit (Promega, Madison, WI, USA) following the manufactures instructions. *T. equi* was detected in DNA samples from the collected blood samples using a diagnostic nested PCR test targeting the *T. equi* merozoite antigen-1 (EMA-1) for *T. equi*, as previously described (Battsetseg et al., 2001). The primer sequences were reported in (Table 2). 40 cycles of enzyme activation at 95°C for 10 minutes, denaturation at 94°C for 1 minute, primer annealing at 60°C for 1

minute, amplification at 72°C for 1 minute, and final extension at 72°C for 5 minutes were used. After that, the product was refrigerated to 4 °C. The PCR products were then gel electrophoresed on 1.5 % agarose gel with TBE buffer and stained with ethidium bromide. The final PCR product was then examined under ultraviolet light. For the first and second PCRs, the positive *T. equi* technique gives bands of 268 and 218 bp, respectively.

3. Statistical analyses

Using the Open Epi software, the upper and lower limits of the confidence intervals of the positive rates for *T. equi* parasite were evaluated. (<http://www.openepi.com/v37/Proportion/Proportion.htm>).

Results

Fever, increased respiratory rate, tachycardia, and pale or icteric conjunctiva were shown in 9- animals in the current investigation, indicating equine piroplasmosis. Only two animals were found to have lymphadenopathy (Table 1). Microscopic examination of blood smears revealed presence of the parasite in nine (6%) animals (Fig. 1). *Theileria equi* were detected in RBCs with two forms; round and pyriform or pear shaped piroplasm, measuring 2 X 1 µm. Four merozoites sometimes form Maltese cross. Using a species-specific PCR technique, 14 (9.52 %) of the DNA samples collected from horses (n = 147) were positive for *T. equi* (Fig. 2& Table 3). Subsequently, five

animals were found to be carriers for infection without presence of either clinical signs or *T. equi* in the blood smears. (Table 3).

Table 1: Clinical parameters of healthy horses and *T. equi*- infected horses

Parameters	Healthy animals (n=138)	Horses infected with <i>T. equi</i> (n= 9)*
RT (° C)	37.19 ± 0.08	40.11 ± 0.72
RR (breath/min)	13.12 ± 1.05	28.61 ± 3.17
HR (beat/min)	31.945 ± 0.42	51.01 ± 2.40
MM (n)	Bright red	Pale (n=6) Icteric (n=3)
LN (prescapular and/or prefemoral)	Normal	Lymphadenopathy (n=2)

*Infection detected by microscopy examination of Giemsa-stained blood smears. RT, rectal temperature, RR, respiratory rate, HR, heart rate, LN, lymphnode

Table 2. PCR primers used in the present study

Primer name	Primer sequence	Reference
EMA5F	5- TCGACTTCCAGTTGGAGTCC-3	(Kappmeyer et al., 1993)
EMA6R	5-AGCTCGACCCACTTATCAC-3	
EMA7F	5-ATTGACCACG TCACCATCGA-3	
EMA8R	5-GTCCTTCTTGAGAACGAGG-3	

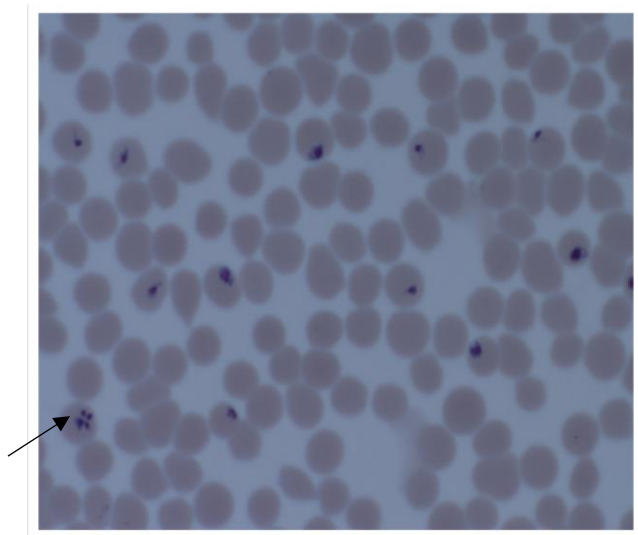


Fig. 1. *T. equi* in RBCs of horses (x 100).

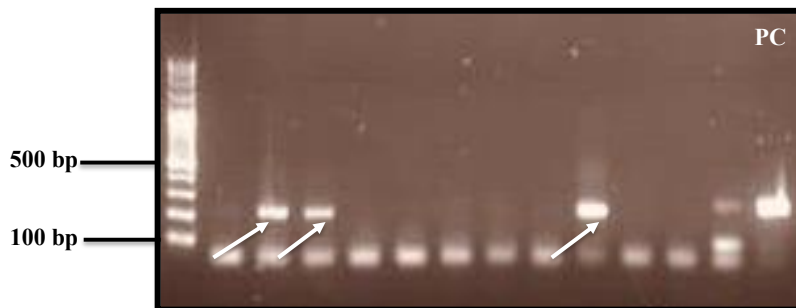


Fig. 2. Detection of *T. equi* infection in horses reared in Dakahlia province in Egypt using **nested** PCR assay. PC: positive control; NC: negative control. The **expected** size of the PCR products was 218 bp. Arrows indicate positive samples.

Table 3. Confidence interval % and horses number infected with *T. equi* using PCR assay

Animal type	Samples No.	Positive No.	% CI ^a	Carriers No.
Horse	147	14	9.52 (5.75 – 15.35)	5

^a 95% confidence interval.

DISCUSSION

Equine piroplasmosis is an infectious disease with a great economic impact worldwide (Kumar et al., 2004). Furthermore, the affected horses show weakness and inability to work or race, as well as the costs of treatment (El-Sayed et al., 2015). In the present study, the infection by *T. equi* was investigated in clinically ill and apparently healthy horses reared in Dakahlia province, Egypt. Microscopically, the identified piroplasm of *T. equi* were similar to that reported previously (OIE, 2008; Kuraa and Nageib, 2017; Soliman et al 2021)

Nested PCR assay revealed presence of the infection in 14- animals. While only 9 horses appeared positive during microscopic examination of blood smears. Such difference might be attributed to the high sensitivity of PCR- based assay for detection the infection when compared with the traditionally used microscopic method (Byamukama et al 2021). In fact, clinical equine piroplasmosis is very common among Egyptian horses (Mahmoud et al., 2016; Soliman et al. 2021). As a result, our preliminary results serve as a warning to develop immediate control strategies for this potentially dangerous disease. The results of this study were close to that obtained by Soliman et al. (2021) who detected 8.9% of

examined apparently normal horses in Giza, Egypt were positive for *T. qui* infection. Despite the fact that, the infection rate predicted in this study is lower than that previously recorded by Mahmoud et al. (2016), who used a PCR assay on horses and reported 36.4 percent infection. Variations in abiotic factors and tick fauna distribution could explain the differences. Furthermore, the prevalence of *T. equi* (34%) found by Salib et al. (2013) or those (38.8%) detected by Farah et al. (2003). Horse populations in Egypt were found to be higher than those estimated in this study utilizing microscopic examination of blood smears Variations in the diagnostic procedures used could explain such differences. Applying the same pattern as before, Montes Cortés et al. (2017) reported 44% infection rate by *T. equi* in Spain using indirect fluorescence antibody testing (IFAT), which is greater than those recorded in the current study. In conclusion, the results reported the existence of *T. equi* in horses in Dakahlia province Egypt, either as acute infection or carriers. These findings have economic implications and highlight the importance of successfully implementing prophylactic and control techniques throughout Egypt to reduce equine piroplasmosis prevalence.

Acknowledgments

This study supported by the Ministry of Education, Culture, Sports, Science, and Technology of Japan. The authors would like to thank owners and staff of the study farms in Egypt.

REFERENCES

- Battsetseg, B., Xuan, X., Ikadai, H., et al., 2001. Detection of *Babesia caballi* and *Babesia equi* in *Dermacentor nuttalli* adult ticks. *Int. J. Parasitol.* 31, 384–386.
- Byamukama, B., Vudriko, P., Tumwebaze, M.A., Tayebwa, D.S., Byaruhanga, J., Angwe, M.K., Li, J., Galon, E.M., Ringo, A., Liu, M. and Li, Y., 2021. Molecular detection of selected tick-borne pathogens infecting cattle at the wildlife–livestock interface of Queen Elizabeth National Park in Kasese District, Uganda. *Ticks and Tick-borne Diseases*, p.101772. <https://doi.org/10.1016/j.ttbdis.2021.101772>
- Bock, R., Jackson, L., de Vos, A., Jorgensen, W., 2004. Babesiosis of cattle. *Parasitology*; 2(129 (Suppl.)): S247–69.
- Calder, J. A., Reddy, G. R., Chieves, L., Courtney, C. H., Littell, R., Livengood, J. R., 1996. Monitoring *Babesia bovis* infections in cattle by using PCR-based tests. *J Clin Microbiol*; 34: 2748–55.
- El-Sayed, S.A., Rizk, M. A., Terkawi, M.A., Mousa, A., El Said, E.S.E.S., Elsayed, G., Fouda, M., Yokoyama, N., Igarashi, I., 2015. Cocktail of *Theileria equi* antigens for detecting infection in equines. *Asian Pac. J. Trop. Biomed.* 5, 977e981.
- Farah, A.W., Hegazy, N. A., Romany, M. M., Soliman, Y. A., Daoud, A. M., 2003. Molecular detection of *Babesia equi* in infected and carrier horses by polymerase chain reaction. *Egypt J Immunol.*;10(2):73–9.
- Garba, U. M., Sackey, A. K. B., Tekdek, L. B., Agbede, R. I. S., Bisalla, M., 2011. Clinical manifestations and prevalence of piroplasmosis in Nigerian royal horses. *J Vet Adv.*; 1(1): 11–15.
- Hussain, M. H., Saqib, M., Raza, F., Muhammad, G., Asi, M. N., Mansoor, M. K., et al., 2014. Seroprevalence of *Babesia caballi* and *Theileria equi* in five draught equine populated metropolises of Punjab, Pakistan. *Vet. Parasitol.* ; 202(3–4): 248–256.
- Kappmeyer, L.S., Perryman, L. E., Knowles, D.P., 1993. A *Babesia equi* gene encodes a surface protein with homology to *Theileria* species. *Mol. Biochem. Parasitol.* 62,121–124.
- Kumar, S., Yokoyama, N., Kim, J. Y., Huang, X., Inoue, N., Xuan, X., et al., 2004. Expression of *Babesia equi* EMA-1 and EMA-2 during merozoite developmental stages in erythrocyte and their interaction with erythrocytic membrane skeleton. *Mol Biochem Parasitol.*;

Kuraa, H.M. and Nageib, B.R., 2017. Parasitological and molecular detection of *Theileria equi* in donkeys in Assiut governorate. Egyptian Journal of Agricultural Research, 95(1), pp.271-284.

Mahmoud, M. S., El-Ezz, N.T., Abdel-Shafy, S., Nassar, S. A., El Namaky, A.H., Khalil, W. K., Knowles D., Kappmeyer L., Silva, M.G., Suarez C.E. 2016. Assessment of *Theileria equi* and *Babesia caballi* infections in equine populations in Egypt by molecular, serological and hematological approaches. Parasit Vectors. 2016 May 4: 9: 260.

Montes Cortés, M. G., Fernández-García, J. L., Habela Martínez-Estélez, M. Á. , 2017. Seroprevalence of *Theileria equi* and *Babesia caballi* in horses in Spain. Parasite. ;24:14.

Mosqueda, J., Olvera-Ramirez, A., Aquilar-Tipacamu, G., Canto, G. J., 2012. Current advances in detection and treatment of babesiosis. Curr Med Chem.; 19:1504–18.

OIE (2008) Equine Piroplasmosis (Equine Babesiosis, Equine Theileriosis, Biliary Fever). August 29, 2008., Pp:1-5.

Rosales, R., Rangel-Rivas, A., Escalona, A., Jordan, L. S., Gonzatti, M. I., Aso, P. M., Perrone, T., Silva-Iturriza, A., Mijares, A., 2013. Detection of *Theileria equi* and *Babesia caballi* infections in Venezuelan

horses using Competitive-Inhibition ELISA and PCR. Vet Parasitol.; 196:37–43.

Salib, F.A., Youssef, R. R., Rizk, L. G., Said S.F., 2013. Epidemiology, diagnosis and therapy of *Theileria equi* infection in Giza, Egypt. Vet World; 6(2):76–82.

Soliman, A. M., Elhawary, N. M., Helmy N.M., Gadelhaq, S. M., 2021. Molecular and microscopic detection of *Babesia caballi* and *Theileria equi* among working horses and donkeys in Cairo and Giza provinces of Egypt. PREPRINT, <https://doi.org/10.21203/rs.3.rs-757240/v1>

دراسة وبائية لطفيل ثيليريا اكواي *Theileria equi* في الخيول في مصر.

مصطفى عبدالسلام العربي¹ شيماء عبدالسلام السيد² ، و محمد عبده رزق^{3،4}
¹ قسم الطفيليات - كلية الطب البيطري- جامعة المنصورة
² قسم الكيمياء الحيوى و كيمياء التغذية- كلية الطب البيطري- جامعة المنصورة
³ قسم الامراض الباطنة و الامراض المعدية- كلية الطب البيطري- جامعة المنصورة.
⁴ المعهد القومى لاجتياح امراض الاوليات- جامعة اوبيهيرو للزراعة والطب البيطري- اليابان

اجريت هذه الدراسة لإجراء مسح وبائي لطفيل ثيليريا اكواي *T. equi* و ذلك بجمع عينات الدم من عدد ١٤٧ من الخيول التي تمت تربيتها في محافظة الدقهلية، مصر. و تم عزل الحمض النووى لاجراء تفاعل البلمرة المتسلسل PCR و الذى يستهدف جين (*T. equi merozoite antigen-* 1). و قد اسفرت النتائج على اكتشاف طفيل الثيليريا اكواي فى عدد ١٤ (٩,٥٢٪) من عينات دم الخيول التي تم فحصها باستخدام تفاعل البلمرة المتسلسل PCR بينما تم اكتشاف طفيل الثيليريا اكواي فى ٩ (٦٪) من مسحات الدم فقط و بالتالى فان عدد ٥ خيول يعتبروا حامل للمرض بدون ظهور اى اعراض او اكتشاف للطفيل فى مسحات الدم تم فحصها ميكروسكوبيا. و هذه النتائج لها اهمية اقتصادية لتسليط الضوء على ضرورة تنفيذ استراتيجيات وقائية في جميع أنحاء مصر للحد من انتشار طفيل ثيليريا اكواي.