



Manuscript ID

ZUMJ-2112-2429 (R1)

DOI

10.21608/zumj.2022.110886.2429

OREGENAL ARTICLE

Fetuin A Effect on Iron Status and Heparin level in Adenine Induced Chronic kidney Disease Male Rat Model.

Reham Hassan Ebrahim Ali^[1], Mohamed sayed Ahmed Zamzam^[1], Heba Essam El Din El Sayed Ali^{[1]*},
Wesam M.R. Ashour^[1]

Physiology Department, Faculty of Medicine, Zagazig University, zagazig, Egypt

ABSTRACT

Corresponding author:

Heba Essam El Din El Sayed

Email:

hebaessam921@gmail.com

Submit Date 2021-12-16 00:44:07

Revise Date 2022-01-08 00:15:00

Accept Date 2022-01-16 18:28:37

Background: Chronic kidney disease describes loss of kidney function gradually; it may not become apparent in early stages until chronic kidney disease reaches an advanced stage that lead to accumulation of fluid, electrolytes and wastes and development of anemia Aim of study: The aim of this study was to investigate the possible role of fetuin A in improving anemia resulting from adenine induced chronic kidney disease in male rat.

methods: Group A: rats feed normal diet for 21 days. Group B: rats feed normal diet with adenine for 21 days. Group C: rats feed normal diet with adenine for 21 days after that intraperitoneal administration of fetuin A every other day for 2 weeks. Serum samples were assayed for: creatinine, urea, iron , total iron binding capacity, ferritin, tumor necrosis factor, hepcidin. Hemoglobin content, blood indices were determined, and estimated Glomerular filtration rate was measured in addition, histopathology of the kidney was done

Results: In group B: there was significant increase in serum creatinine, urea and ferritin decrease in serum iron, total iron binding capacity, hemoglobin content and estimated Glomerular filtration rate and no significant change in blood indices .Regarding inflammatory markers significant increase .Regarding renal histopathology there was moderate tubular necrosis, tubular dilatation, and mononuclear leucocytes infiltration. In group C we observed that fetuin A ameliorated these changes. .

Conclusion: Fetuin A improve anemia in chronic renal failure in rat model, may be due to reduction of hepcidin or it is anti-inflammatory and anti fibrotic effect.

Keywords: Adenine; fetuin A; anemia;rats.

INTRODUCTION

Iron is a vital element in human metabolism. Due to its unique ability to act both as an electron donor (in its ferrous state) and as an electron acceptor (in its ferric state), iron plays an imperative part in cellular respiration as well as oxygen transport and storage [1].

Chronic kidney disease (CKD) is manifested by reduced kidney functions that affect many aspects of human health [2].

Anemia in CKD can result from various mechanisms (malnutrition lead to iron, folate or vitamin b12 deficiency; severe secondary

hyperparathyroidism as elevated level of parathyroid hormone lead to impairment of erythropoietin synthesis [3]; destruction of RBCS due to release of cytokines as result of systemic inflammation; reduced erythropoietin production is the most important and specific etiology causing CKD-associated anemia [3]

Iron status can be assayed by either biochemical indices that detect early changes in iron status such as serum iron level, total iron binding capacity (TIBC), transferrin saturation and serum ferritin level [4] or hematological parameters that can demonstrate defective erythropoiesis after

prolonged changes of iron such as hemoglobin content (HB), mean corpuscular hemoglobin (MCH) and hematocrit values [4]

Fetuin A is a hepatokine also known as alpha 2-heremans schmid glycoprotein with half-life 1-2 days and its molecular weight of approximately 60 kda [5], it is secreted mainly from the liver (>95%) [6].

Fetuin A is multifunction protein as it inhibits soft tissue calcification process, modulates innate immunity, it acts as negative acute phase protein that decrease in injury or infection [7], it blocks the fibrotic factor transforming growth beta 1 binding to surface receptors. TGF- β activates hepcidin MRNA expression in hepatocytes, fetuin A reduce hepcidin in other way as fetuin A is TGF- β antagonist [8].

Serum fetuin A is reduced in chronic renal disease [9], these data are supported by *Mohamed et al.* [10] who studied the role of fetuin A as indicator for vascular disease in end staged renal disease patients and correlations between fetuin A and hemoglobin content and TIBC.

Research gap:

This study was done to investigate the possible role of fetuin A in improving anemia resulting from adenine induced chronic kidney disease in male rat according to *Mohamed et al.* [10] who studied the role of fetuin A as indicator for vascular disease in end staged renal disease patients and correlations between fetuin A and hemoglobin content and TIBC and *Robison et al.*, [8] who studied that fetuin A has anti-fibrotic effect by blocks the fibrotic factor transforming growth beta. fetuin-A is also known to play a role in macrophage deactivation and has anti-inflammatory role according to *Li et al.* [11].

METHODS:

Drugs and chemicals:

Fetuin A from fetal bovine serum lyophilized powder (sigma Aldrich).

Adenine, bio reagent (sigma-Aldrich).

Sodium carboxymethyl cellulose (sigma-Aldrich).

Experimental animals:

A total number of 30 (local strain) adult male albino rats weighing 160- 180 gm, were obtained from the animal house of faculty of Veterinary Medicine Zagazig University. The animals were kept in plastic cages (30 inches in length, 18 inches in width and 24 inches in height). Each 10 rats were housed per cage in the animal house of physiology department, faculty of medicine, zagazig university under hygienic conditions ,on free access to

ordinary diet (zagazig faculty of agriculture).all rats were kept at a comfortable temperature (20 to 24 °c), had free access to water and maintained on normal light -dark cycle. Before starting of the study, the animals were acclimated to animal house conditions for 3weeks.

Physiology department committee and the institutional animal care and use committee, zagazig university (ZU -IACUC) approved the experimental protocol (ZU-IACUC/3/F/137/2019).

Experimental protocol:

The study was conducted on 30 healthy adult male albino rats (10-12 weeks), the rats were divided into 3 equal groups (n=10 rats).

Group A (control group n=10 rats): feed normal diet for 21 days, then treated intraperitoneal with 0.5ml saline every other day for 2 weeks.

Group B (adenine induced chronic kidney disease group n=10 rats): feed normal diet with adenine 220 mg/kg daily taken orally for 21 days by oral gavages dissolved in sodium carboxymethyl cellulose 0.5% [12], then treated intraperitoneal with 0.5ml saline every other day for 2 weeks.

Group C (fetuin A treated group n=10 rats): feed normal diet with adenine 220 mg/kg daily taken orally for 21 days by oral gavages dissolved in sodium carboxymethyl cellulose 0.5% [12], after that intraperitoneal administration of fetuin A 5 mg/kg [13], every other day as half-life of fetuin A 1-2 days [5] for 2 weeks.

Blood sampling and biochemical analysis:

Timing: blood sample were collected after three weeks from induction of chronic kidney disease for confirmation of impaired renal function then at the end after injection of fetuin A.

Blood collected from rat tail vein into clean plastic centrifuge tubes, blood sample were withdrawn into two eppendorf tubes for each rat; one was with (edta.k₂) as an anticoagulant while the other was without any anticoagulant.

The blood samples with an anticoagulant were taken fresh for assaying hemoglobin content (HB), mean corpuscular volume (MCV), mean corpuscular hemoglobin (MCH) and mean corpuscular hemoglobin concentration (MCHC) by automated blood analyzer.

While the samples without anticoagulant were centrifuged at 5000 round per minute for 15 min at 4 °c then the supernatant was collected and frozen at -70 °c , serum samples were assayed later for serum iron , serum ferritin , total iron binding capacity

,tumor necrosis factor alpha and hepcidin : by ELISA kits

Measuring estimated glomerular filtration rate by this equation according to level of creatinine level :

If plasma creatinine $<52\mu\text{mol/l}$,eGFR = $880\times \text{rat weight}^{0.695}\times\text{creatinine}^{-0.660}\times\text{urea}^{-0.391}$,plasma creatinine $\geq 52\mu\text{mol/l}$, eGFR = $5862\times \text{rat weight}^{0.695}\times\text{creatinine}^{-1.150}\times\text{urea}^{-0.391}$ according to **Besseling et al.**[14].

Histopathology:

For histopathological examination, necropsy of the rats was performed at end of experiment. The kidney samples were collected following euthanasia, fixed in 10% buffered formalin and processed routinely for light microscopy. Sections (5 μm) were taken from paraffin-embedded tissues and stained with haematoxylin and eosin (h&e).the histopathological analysis was carried out blindly by an expert pathologist.

Statistical analysis. The data obtained in the present study were expressed as mean \pm SD for quantitative variables and statistically ANOVA with [POST HOC (LSD)] test was used to compare means among all studied groups, p value < 0.05 was considered statistically significant.

RESULTS

Serum creatinine changes: oral adenine showed significant increase in CKD group compared to control rats, while fetuin A injection induced significant decrease in serum creatinine in group 3 when compared to adenine induced CKD group (table 1).

Serum urea changes: oral adenine showed significant increase in serum urea in group 2 when compared to control rats. Injection with fetuin A induced significant decrease in serum urea in group 3 when compared to adenine induced CKD group (table 1).

Estimated glomerular filtration changes: oral adenine showed significant decrease in estimated glomerular filtration in CKD group compared to control rats. Injection with fetuin A induced significant increase in estimated glomerular filtration in group 3 compared to adenine induced CKD group (table 1).

Serum iron changes: significant decrease in serum iron in CKD group compared to control rats. In group 3 fetuin A induced significant increase in serum iron compared to adenine induced CKD group (table 2).

Serum ferritin changes: significant increase in serum ferritin in CKD group compared to control rats. In group 3 fetuin A induced significant decrease in serum ferritin compared to adenine induced CKD group (table 2).

Total iron binding capacity changes: significant decrease in TIBC in CKD group compared to control rats. In group 3 fetuin A induced significant increase in TIBC compared to adenine induced CKD group (table 2).

Hemoglobin content changes: significant decrease in HB in CKD group compared to control rats. In group 3 fetuin A induced significant increase in HB compared to adenine induced CKD group (table 3).

Blood indices changes (MCH, MCV and MCHC): the results showed insignificant change in CKD group when compared to that of group 1. In group 3the results showed insignificant change when compared to that of group 1 and group 2(table 3).

Serum tumor necrosis factor and hepcidin: oral adenine showed significant increase in serum tumor necrosis factor and hepcidin in CKD group compared to control rats. Injection with fetuin A in group 3 induced significant decrease in tumor necrosis factor and hepcidin compared to adenine induced CKD group (table 4).\

Histopathologic results: light photo microscopic picture of h & e stain $\times 400$ magnification.

Group a: showed glomerulus normal in size and shape with intact glomerular capillaries kidney tubules normal with intact patent lumen, with normal interstitial tissue (figure 1a).

Group b: showed moderate tubular necrosis, tubular dilatation, and mononuclear leucocytes infiltration (figure 1b).

Group c: showed mild tubular necrosis, tubular dilatation, and mononuclear leucocytes infiltration (figure 1c).

Table (1) : Mean values of serum creatinine, urea and estimated glomerular filtration rate that showed the effect of oral adenine and fetuin A injection in three studied groups.

| parameters | | Group A | Group B | Group C |
|-------------------------|----------------|-----------------|--------------------------|--------------------------|
| Serum creatinine(mg/dl) | Mean \pm SD | 0.4 \pm 0.027 | 2.13 \pm 0.13 | 0.95 \pm 0.07 |
| | P value of LSD | | P $<$ 0.001 ^a | P $<$ 0.001 ^b |

| parameters | | Group A | Group B | Group C |
|--|----------------|------------|-----------------------|-----------------------|
| Serum urea(mg/dl) | Mean ± SD | 32.33±2.31 | 116.8±5.35 | 83.29±3.96 |
| | P value of LSD | | P< 0.001 ^a | P< 0.001 ^b |
| estimated glomerular filtration rate (ml/ min) | Mean ± SD | 1,6 ± 0,47 | 0,85±0,5 | 1,13 ± 0,6 |
| | P value of LSD | | P< 0.001 ^a | P< 0.001 ^b |

Table (2): Mean values of serum iron, ferritin and TIBC that showed the effect of oral adenine and fetuin A injection in three studied groups.

| parameters | | Group A | Group B | Group C |
|-----------------------|----------------|-------------|-----------------------|-----------------------|
| Serum iron(µg/dl) | Mean ± SD | 197.4±5.03 | 161.2±3.52 | 165.4±1.43 |
| | P value of LSD | | P< 0.001 ^a | P< 0.01 ^b |
| Serum ferritin(ng/dl) | Mean ± SD | 124±15.45 | 235.05±26.03 | 214.29±23.33 |
| | P value of LSD | | P< 0.001 ^a | P< 0.05 ^b |
| TIBC(µg/dl) | Mean ± SD | 392.36±6.47 | 294.65±14.69 | 343.14±8.81 |
| | P value of LSD | | P< 0.001 ^a | P< 0.001 ^b |

a Significant compared to group A. b Significant compared to group B.

Table (3) : Mean values of hemoglobin content and blood indices that showed the effect of oral adenine and fetuin A injection in three studied groups.

| parameters | | Group A | Group B | Group C |
|--------------------|----------------|------------|-----------------------|----------------------|
| Hb content (mg/dl) | Mean ± SD | 15±0.86 | 8.26±0.6 | 9.02±0.28 |
| | P value of LSD | | P< 0.001 ^a | P< 0.05 ^b |
| MCV(fl.) | Mean ± SD | 56.66±0.94 | 55.92±0.81 | 56.58±0.97 |
| | P value of LSD | | p>0.05 ^a | p>0.05 ^b |
| MCH(pg.) | Mean ± SD | 23.85±1.17 | 22.91±1.05 | 23.28±1.09 |
| | P value of LSD | | p>0.05 ^a | p>0.05 ^b |
| MCHC(g/dl) | Mean ± SD | 34.2±0.83 | 33.1±0.87 | 33.7±0.77 |
| | P value of LSD | | p>0.05 ^a | p>0.05 ^b |

a Significant compared to group A. b Significant compared to group B.

Table (4): Mean values of serum tumor necrosis factor alpha and hepcidin that showed the effect of oral adenine and fetuin A injection in three studied groups.

| parameters | | Group A | Group B | Group C |
|------------|----------------|-----------|-----------------------|-----------------------|
| TNFα | Mean ± SD | 51±3.39 | 127.3±5.29 | 75.4±2.75 |
| | P value of LSD | | P< 0.001 ^a | P< 0.001 ^b |
| hepcidin | Mean ± SD | 40.54±5.2 | 173.7±17.75 | 88.9±6.45 |
| | P value of LSD | | P< 0.001 ^a | P< 0.001 ^b |

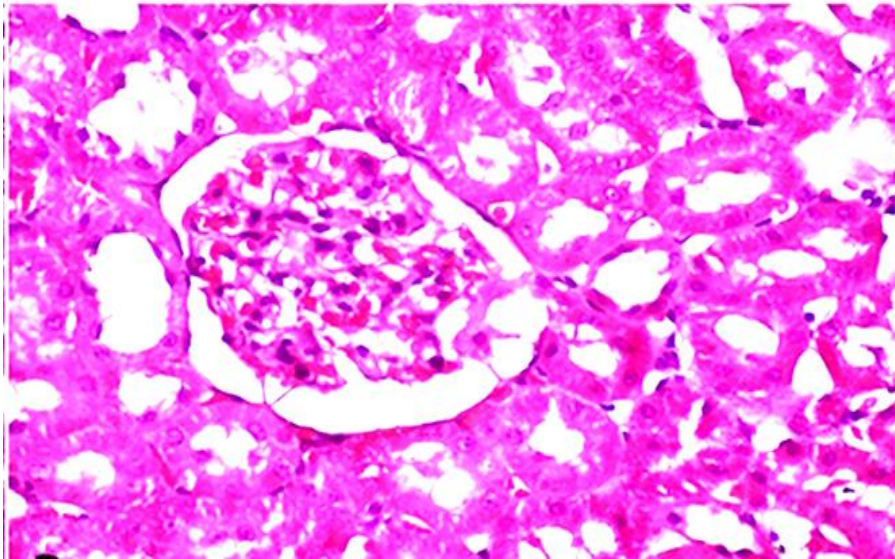


Figure 1a: Photomicrograph of rat kidneys (control group) showed glomerulus normal in size and shape with intact glomerular capillaries kidney tubules normal with intact patent lumen, with normal interstitial tissue.

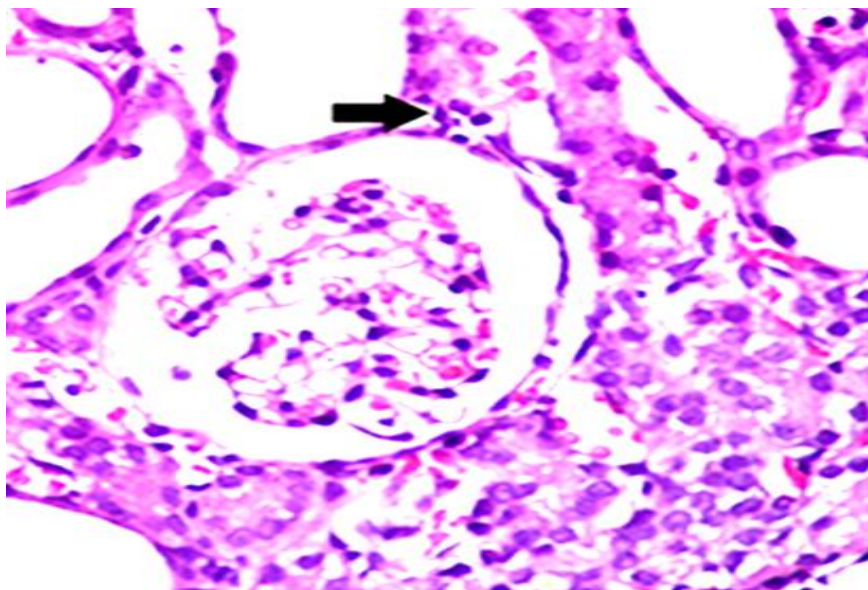


Figure 1b: Photomicrograph of rat kidney (adenine CKD group) moderate tubular necrosis, tubular dilatation, and mononuclear leucocytes infiltration.

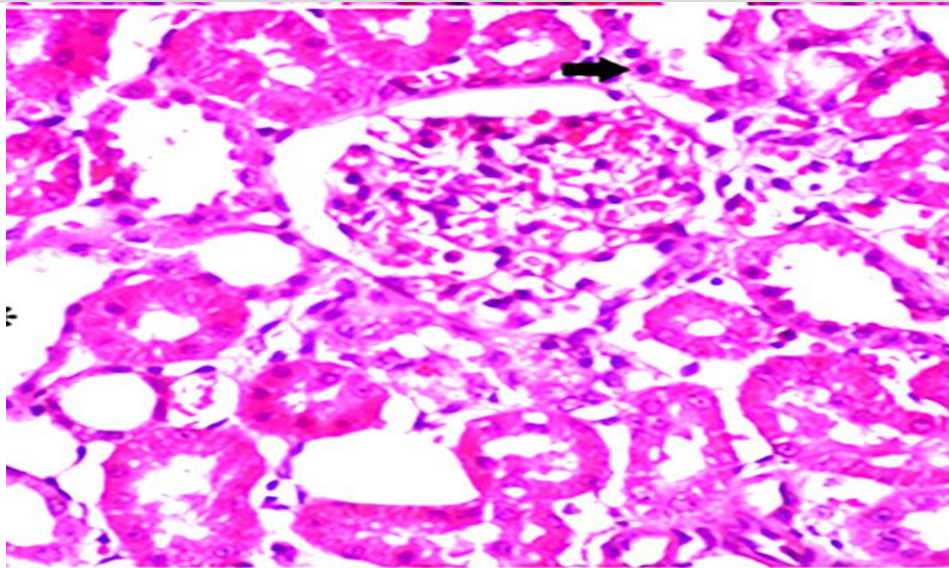


Figure 1c: Photomicrograph of rat kidney (fetuin A treated group) mild tubular necrosis, tubular dilatation, and mononuclear leucocytes infiltration.

DISSCUSSION

This study was designed to investigate the possible role of fetuin A on iron status in chronic kidney disease in male rat model. After 28 days of induction of CKD and at end of the study serum creatinine ,urea ,estimated glomerular filtration rate , serum iron level, total iron binding capacity, hemoglobin content, mean corpuscular volume, mean corpuscular hemoglobin ,mean corpuscular hemoglobin concentration , tumor necrosis factor alpha and hepcidin were determined.

As regards kidney function tests, our study showed that in adenine induced chronic kidney disease group, serum urea and creatinine were high and estimated glomerular filtration rate was low, when compared with control group this result is in line with what stated by *Muñoz abellán et al.* [15] that adenine decreased estimated glomerular filtration rate and *Multuay et al.* [16] that there was significant negative correlations between fetuin-A and creatinine.

As regard iron status in adenine induced chronic kidney disease group, serum iron, total iron binding capacity and hemoglobin content are lower but serum ferritin is higher with no change in MCV,MCH and MCHC when compared with control group, that occur due to inflammation as result of released cytokines that lead to destruction of RBCS [3] and deficiency of renal erythropoietin [2] that stimulate RBCS production [17] ,but diminished erythropoietin synthesis is the most

essential and specific cause so anemia of CKD is form of normocytic normochromic anemia [18] .

Inflamed kidney has a reduced ability for adequate erythropoietin production [2] in addition; inflammatory mediators and markers such as C - reactive protein and hepcidin were found to antagonize the response to erythropoietin [19].

There was a significant increase in the iron storage ferritin in group 2, we suggested that the higher serum ferritin concentrations represent an increased state of inflammation, as it acts as an acute phase reactant [20]; furthermore, ferritin has non-storage roles within the body, such as protection from oxidative damage [21]. Indeed, its synthesis is increased in response to oxidative stress [22] which was stated to occur in chronic kidney disease [23], and it is, therefore, a non-reliable indicator of iron disturbance [20].

Decreased serum iron together with depleted ferritin under physiological levels is indicative of absolute iron deficiency anemia. However, decreased serum iron level together with high ferritin is occurring in inflammation, infection, liver or kidney disease, and cancer [24].

In addition, the total iron binding capacity, which indicates transferrin saturation that is responsible for iron transport through the plasma [25], TIBC decreased in group 2, as a result of inflammation in CKD, the liver ability to synthesize proteins, including transferrin, is reduced [26].

As regard inflammatory markers in adenine induced chronic kidney disease group, serum tumor

necrosis factor alpha and hepcidin were high when compared with control group.

Hepcidin, a polypeptide hormone released by the liver which is raised in CKD [3] plays a crucial role in iron homeostasis. Inflammatory cytokines increase hepcidin production that reduces iron release from storage sites as the liver or recycling macrophages of the reticuloendothelial system leading to functional iron deficiency contributing to renal anemia [27]. Hepcidin also binds to enterocytes causing poor absorption of dietary iron [26].

Histopathological study of rat kidney adenine induced CKD (group 2) showed moderate tubular necrosis, tubular dilatation, and mononuclear leucocytes infiltration as orally adenine is rapidly metabolized to 2, 8-dihydroxyadenine, which is formed crystals that deposited in the microvilli causing inflammation in renal tubule and interstitial degeneration and progression to renal failure[2], tubulo interstitial fibrosis and anemia [28] .

Adenine begins the fibrotic response in kidney by increasing the profibrotic proteins as connective tissue growth factor , transforming growth factor-beta , collagen and fibronectin[29] .

The severity of the adenine-induced kidney damage is correlated with the dose and the duration of the exposure [15], *Ali et al.* [2] stated that renal histopathological examination of rats treated by oral adenine 0.25%w/w for 35 days showed renal tubulointerstitial fibrosis 10 days after the end of adenine treatment. Furthermore, rats fed a 0.75% adenine-containing diet for 3 weeks and then switched to normal diet for 4 weeks, showed markedly tubulointerstitial fibrosis [30].

In group c, fetuin A increased estimated glomerular filtration rate ,decrease level of serum urea , creatinine ,tumor necrosis factor alpha,hepcidin and ferritin moreover it may antagonize adenine inflammatory effect, as fetuin A was closely correlated to inflammation, fetuin A seems to play a role in inflammation by down regulating the pro-inflammatory cytokines produced by macrophages [31] , fetuin-A is also known to play a role in macrophage deactivation and has anti-inflammatory role [11,32].

In addition, fetuin A may have a role in inhibition of renal fibrosis as it has antifibrotic effect [33,34] ,fetuin A acts as an antagonist of the fibrogenic growth factor TGF. It could be demonstrated that incubation of fetuin-a with hepatic stellate cells significantly inhibited collagen

synthesis in hepatic stellate cells, potentially linking fetuin-a as an antifibrotic agent [34].

We observed that fetuin A improve anemia by elevation of serum iron, total iron binding capacity and hemoglobin content, these were supported by what stated by *Mohamed et al.* [10] who studied the role of fetuin A as marker for vascular disease in end staged renal disease patients, this study showed that there were significant positive correlations between fetuin A and hemoglobin content and TIBC.

These results may be due to anti-inflammatory role of fetuin A [11,32] ., this may improve erythropoietin level and decrease hepcidin level, in addition, TGF- β production is associated with CKD progression [35] . Circulating TGF- β levels is a reliable biomarker of CKD [36]. TGF- β activates hepcidin mRNA expression in hepatocytes [37], fetuin A reduce hepcidin in other way as fetuin A is TGF- β antagonist [34].

Conclusion: fetuin A improve anemia result from kidney disease could be due to reduction of hepcidin or as result of improvement of renal function due to its anti-inflammatory and anti-fibrotic role.

Conflict of interest: None

Financial disclosure: None

REFERENCES:

1. **Gafter-Gvili A, Schechter A, Rozen-Zvi B.**Iron Deficiency Anemia In Chronic Kidney Disease. *Acta Haematol* 2019;142:44-50.
2. **Ali BH, Al-Husseni I, Beegam S, Al-Shukaili A, Nemmar A, Schierling S, et al.** Effect Of Gum Arabic On Oxidative Stress And Inflammation In Adenine-Induced Chronic Renal Failure In Rats. *Plos One.* 8(2):E55242. Doi: 10.1371/Journal.Pone.0055242. Epub 2013 Feb 1. PMID: 23383316; Pmcid: Pmc3562323.
3. **Babbitt JL And Lin HV.**"Mechanisms Of Anemia In CKD" *Journal Of The American Society Of Nephrology* .2012.23.10 1631-634.
4. **Asif N, Ijaz A, Rafi T, Haroon Zh, Bashir S, Ayyub M.** Diagnostic Accuracy Of Serum Iron And Total Iron Binding Capacity (TIBC) In Iron Deficiency State. *J Coll Physicians Surg Pak.* 2016 Dec;26(12):958-961.
5. **Wojtysiak-Duma B, Malechajędraszek A, Burska A, Duma D And Donica H.** Serum Fetuin-A Levels In Patients With Type 2 Diabetes Mellitus.*Ann Umcs Sect Ddd* 2010;2(14):93-9.
6. **Jahnen-Dechent W, Heiss A, Schäfer C And Ketteler M .** Fetuin-A Regulation Of Calcified Matrix Metabolism. *Circ Res* 2011;108(12):1494-9.
7. **Sindhu S, Akhter N, Shenouda S, Wilson A And Ahmad R.**Plasma Fetuin-A/A2-Hs-Glycoprotein Correlates Negatively With Inflammatory Cytokines,

- Chemokines And Activation Biomarkers In Individuals With Type-2 Diabetes. *Bmc Immunology*. 2016;17:33.
8. **Robinson KN, Teran-Garcia M.** From Infancy To Aging: Biological And Behavioral Modifiers Of Fetuin-A. *Biochimie*. 2016 May;124:141-149. Doi: 10.1016/J.Biochi.2015.12.016. Epub 2015 Dec 29. PMID: 26740309.
 9. **Ossareh S, Marghoob B, Bayat R.** Relationship Between Fetuin-A And Vascular Or Valvular Calcification In Hemodialysis Patients. *J Clini Nephrol*. 2019; 3: 001-011. Doi: 10.29328/Journal.Jcn.1001021
 10. **Mohamed A, Mohammed N, Abdallah A, Hassan M And Kamel S.** Associations Of Fetuin-A Level With Vascular Disease In Hemodialysis Patients With Or Without Type Ii Diabetes Mellitus. *The Egyptian Journal Of Internal Medicine* 2013, 25(4), 218. Doi:10.4103/1110-7782.124996.
 11. **Li W, Zhu S, Li J, Huang Y, Zhou R, Fan X, Yang H, Gong X, et al.** A Hepatic Protein, Fetuin-A, Occupies A Protective Role In Lethal Systemic Inflammation. *Plos One* 2011, 6,18–24
 12. **Rahman A, Yamazaki D, Sufiun A, Kitada K, Hitomi H, Nakano D ,et al.**A Novel Approach To Adenine-Induced Chronic Kidney Disease Associated Anemia In Rodents. Retrieved June 19, 2020, From <https://Journals.Plos.Org/Plone/Article>.
 13. **Zhang P, Shen H, Huang J, Wang H, Zhang B, Zhou R, et al.** Intraperitoneal Administration Of Fetuin-A Attenuates D-Galactosamine/Lipopolysaccharide-Induced Liver Failure In Mouse. *Dig Dis Sci*. 2014 Aug;59(8):1789-97. Doi: 10.1007/S10620-014-3071-0. Epub 2014 Mar 7. PMID: 24604240; Pmcid: Pmc4119259.
 14. **Besseling PJ, Pieters TT, Nguyen I T, De Bree PM,, Willekes N, Dijk AH, et al.** A Plasma Creatinine- And Urea-Based Equation To Estimate Glomerular Filtration Rate In Rats. *American Journal Of Physiology-Renal Physiology*,2021;320(3). <https://doi.org/10.1152/Ajprrenal.00656.2021>.
 15. **Munoz M, Garcia-Erce AJ And Remacha FA.** Disorders Of Iron Metabolism. Part 1: Molecular Basis Of Iron Homeostasis. *J. Clin. Pathol*. 2011, 64, 281–286.
 16. **Mutluay R, Koncadedertekin C, İşıktaşsayilar E, et al** .Serum Fetuin-A Is Associated With The Components Of Miac (Malnutrition, Inflammation, Atherosclerosis, And Calcification) Syndrome In Different Stages Of Chronic Kidney Disease. *Turk J Med Sci*. 2019; 49(1):327-335. Published 2019 Feb 11. Doi:10.3906/Sag-1809-43
 17. **Lombardero M, Kovacs K And Scheithauer BW.**Erythropoietin: A Hormone With Multiple Functions. *Pathobiology* 2011;78(1), 41-53. Doi:10.1159/000322975.
 18. **Kautz L, Jung G, Valore Ev, et al.** Identification Of Erythroferrone As An Erythroid Regulator Of Iron Metabolism. *Nat Genet* 46:678–684, 2014. Doi: 10.1038/Ng.2996
 19. **Boaz M, Azoulay O, Schwartz If, Schwartz D, Assady S, Kristal B.** Malnutrition Risk In Hemodialysis Patients In Israel: Results Of The Status Of Nutrition In Hemodialysis Patients Survey Study. *Nephron* 2019;141:166-176. Doi: 10.1159/000495150.
 20. **Khan A, Khan Wm, Ayub M, et al.** Ferritin Is A Marker Of Inflammation Rather Than Iron Deficiency In Overweight And Obese People. *J Obesity Article Id*. 1937320,2016.Doi:10.1155/2016/1937320.
 21. **Tran J, Story C, Moore D, Metz M.** Unexpected Increased Ferritin Concentration In Patients With Anorexia Nervosa. *Ann Clin Biochem*. 2013 Sep;50(Pt 5):504-6. Doi: 10.1177/0004563213490289. Epub 2013 Jul 29. PMID: 23897102.
 22. **Shivasekar M, Kaliaperumal, Ramachandran and William E.** Response Of Ferritin To Oxidative Stress In Rheumatoid Arthritis. *Asian Journal Of Pharmaceutical And Clinical Research*.2014; 7. 93-94.
 23. **Ling Xc, Kuo Kl.** Oxidative Stress In Chronic Kidney Disease. *Ren Replace Ther* 4, 53 (2018). <https://doi.org/10.1186/S41100-018-0195-2>
 24. **Nairz M, Theurl I, Wolf D, Weiss G.** Iron Deficiency Or Anemia Of Inflammation? : Differential Diagnosis And Mechanisms Of Anemia Of Inflammation. *Wien Med Wochenschr*. 2016 Oct;166(13-14):411-423. Doi: 10.1007/S10354-016-0505-7. Epub 2016 Aug 24. Pmid: 27557596; Pmcid: Pmc5065583.
 25. **Adams PC, Barton JC.** A Diagnostic Approach To Hyperferritinemia With A Non-Elevated Transferrin Saturation. *J Hepatol*. 2011 Aug;55(2):453-8. Doi: 10.1016/J.jhep.2011.02.010. Epub 2011 Feb 24. PMID: 21354228.
 26. **Gheith I, El-Mahmoudy A.** Hemogram And Iron Indices In Renal Anemia And The Amelioration With Carica Papaya Leaf Extract Applied On Albino Rat Model. *Biosci Rep*. 2019 Apr 26;39(4):Bsr20181699. Doi: 10.1042/Bsr20181699. Pmid: 30936264; Pmcid: Pmc6487265.
 27. **Besarab A And Coyne DW** . Iron Supplementation To Treat Anemia In Patients With Chronic Kidney Disease. *Nat. Rev. Nephrol*. 6, 699, <https://doi.org/10.1038/Nrneph.2010.139>.
 28. **Webster AC, Nagler EV, Morton RL and Masson P** .Chronic Kidney Disease. *Lancet*. 2017;389:1238–52.
 29. **Thakur R, Sharma A, Lingaraju MC, et al.** Ameliorative Effect Of Ursolic Acid On Renal Fibrosis In Adenine-Induced Chronic Kidney Disease In Rats. *Biomedpharmacother*.2018;101:972-980.
 30. **Sueyoshi M, Fukunaga M, Mei M, Nakajima A, Tanaka G, Murase T et al.** Effects Of Lactulose On Renal Function And Gut Microbiota In Adenine-Induced Chronic Kidney Disease Rats. *Clinical And Experimental Nephrology*, 23(7),2019; 908-919.
 31. **Kebapcilar L, Bilgrir O, Cetinkaya E, Akyol M, Bilgrir F And Bozkaya G.**The Effect Of Helicobacter

- Pylori Eradication On Macrophage Migration Inhibitory Factor, C-Reactive Protein And Fetuin-A Levels. Clinics.2010;65:799-802.
32. **Wang HE and Sama A.** Anti-Inflammatory Role Of Fetuin-A In Injury And Infection. Curr.Mol. Med. 2012, 12,625–633.
33. **Karabag T, Kucuk E, Tekin I, Sayin M, Gursoy Y and Aydin M .** Relationship Of Fetuin-A With Restenosis In Patients Who Underwent Revascularization, Journal Of Laboratory Medicine,2016; 40(1), 43-48.
34. **Zhou Y, Yang S and Zhang P .** Effect Of Exogenous Fetuin-A On Tgf-B/Smad Signaling In Hepatic Stellate Cells. Biomed Res Int. 2016;2016:8462615. Doi:10.1155/2016/846261
35. **Loeffler I and Wolf G.** Transforming Growth Factor-B And The Progression Of Renal Disease. Nephrol. Dial. Transplant. 2014;29(Suppl. 1):I37–I45.
36. **Seifert ME, De Las Fuentes L, Rothstein M, Dietzen DJ, Bierhals AJ, Cheng SC, et al.** Circulating Transforming Growth Factor-B1 Levels And The Risk For Kidney Disease In African Americans. Kidney Int. 2009;76:72–80.
37. **Chen H, Chiu Y, Hsu S, Pai M, Yang J and Peng Y .** Mp571relationship Between Fetuin A , Vascular Calcification And Fracture Risk In Dialysis Patients. Nephrology Dialysis Transplantation, 31(Suppl_1),2016; I530-I530.

el nouwairy, H., ebrahim ali, R., Ashour, W., zamzam, M. Fetuin A effect on iron status and hepcidin level in adenine induced chronic kidney disease male rat model. *Zagazig University Medical Journal*, 2022; (839-847): -. doi: 10.21608/zumj.2022.110886.2429