

## Six Strand Technique For Primary Flexor Tendon Repair

M.R.Hassan, H.EFarag and A.S.Ibrahim

Orthopedic Surgery, Dept., Faculty of Medicine, Benha Univ., Benha, Egypt

E-mail: Hamadashaker66@gmail.com

### Abstract

Tendon repairs made with six strands may survive both active and passive finger movements. When compared to traditional 2-strand repairs, multi-strand repairs have a reduced rupture rate. There have, however, been no randomised prospective clinical trials that have looked at this specific topic. The goal of this study is to evaluate the clinical outcomes of six strand flexor tendon repair with early active mobilisation as a postoperative rehabilitation strategy for patients with acute flexor tendon damage. Method: We examine the clinical outcomes of flexor tendon restoration utilising a six-strand suture approach in 46 of 22 patients' fingers. In a protective splint, fingers were actively mobilised shortly after surgery. The typical follow-up duration is six months. The following criteria were used to choose all of the patients: Adults, ages 15 to 55, with open flexor tendon injuries in the hand who presented to us within 48 hours after injury and were operated on. Patients who met the following criteria were not included in the study: The damaged finger has poor vascularity. A severe cutaneous lesion that may necrotize or inhibit initial wound healing. Early finger mobility is hampered by associated fractures. Injuries to the flexor and extensor tendons are common. FDP and FDS were both repaired in all zones utilising 3-0/4-0 Prolene sutures using a modified 6 strands (Savage method) approach. Outcomes: Based on the Strickland assessment system, 91 percent of patients had good to outstanding results, with a 4 percent rupture rate. Conclusion: In terms of ultimate functional range and rate of rupture, multi-strand flexor tendon repair outperforms traditional 2-strand repair.

**Key words:** flexor tendons , Early mobilization , six-strand.

### 1. Introduction

Flexor tendon injuries are difficult to treat and manage to get the best possible result for the patient. Several techniques to flexor tendon damage have permitted effective repairs rates of 70-90 percent since Kirchmayr published the first flexor tendon repair in 1917. When compared to secondary repair or tendon transplant surgery, first surgical repair provides a higher functional outcome. The literature suggests that effective flexor tendon injury repair requires little gapping at the repair site, no interference with tendon vascularity, secure suture knots, a smooth union of tendon end, and adequate strength for healing. However, the specific surgical strategy now employed by surgeons to achieve success is still debatable [1].

The IFSSH (International Federation of Societies for Surgery of the Hand), the largest international assembly of hand surgeons, identified a variety of repair techniques used in repairing flexor Tendon lacerations based on information presented at meetings of major hand societies around the world, including the IFSSH (International Federation of Societies for Surgery of the Hand), the largest international assembly of hand surgeons. While the modified Kessler repair is still employed for the main tendon suture, hand surgeons are increasingly adopting multi-strand repairs such double Kessler repairs, cruciate repairs, 4-strand and 6-strand looping suture repairs savage and its variations. Surgeons in Europe, the United States, and Australia have reported double Kessler, 4- or 6-strand repairs of damaged tendons. Tendon repairs using looping sutures are more common in Asian nations such as Japan, China, and Singapore [2].

6-strand tendon repairs can tolerate both vigorous and passive finger movements. When compared to traditional 2-strand repairs, multi-strand repairs have a reduced rupture rate. There have, however, been no

randomised prospective clinical trials that have looked at this specific topic.[3].

Early use of passive and active wrist and digital motion as a technique of increasing the strength and glide of regenerated tendons is quite beneficial. Following flexor tendon repair, mobility is critical for healing and restoration. Experiments have demonstrated that early mobility promotes tendon repair and reduces adhesion [4].

The most frequent approach of treating the recovering flexor tendon is early mobilisation. With so many options, today's hand therapist must not only know what they are, but also why and when they should be used. There is no one-size-fits-all approach to managing a repaired flexor tendon; a specialist who is unfamiliar with the evolution of current procedures is ill-equipped to develop the best therapy for a specific patient [5].

### 2. Patients and methods

22 patients with 46 acute flexor tendon lesions were studied prospectively, where primary flexor tendon repair was carried out and then the patients were followed up for an average duration of 6 months.

The study represents the management of 46 finger lesions (1zone I, 17 zone II, 6 zone III, 3 zone IV, 19 zone V) and 1 thumb lesions in zone IV.

#### 2.1. Criteria of inclusion of patients in this study:

- 1- Adults: age 15-55.
- 2- with acute flexor tendon injuries in the hand ,open ones.
- 3- presenting to us and operated on within the first 48 hours of injury

#### 2.2. Criteria of exclusion of patients in this study:

1. Poor vascularity of affected finger.

2. Severe cutaneous lesion with risk of necrosis or prevent primary closure of wound
3. Associated fractures interfere with early movement of fingers

Complex flexor & extensor tendon injury.

**2.3 Pre operative Evaluation:**

All patients were initially seen at the orthopedic emergency room. Thorough examination and assessment was carried out. This includes:

History, Examination, X-ray evaluation, Intravenous antibiotics, Tetanus prophylaxis

Intraoperatively, thorough evaluation of the injury, determination of the injured structures and accurate determination of the zone of injury is carried out Anesthesia, The surgical approach zigzag incision, Debridement and irrigation, Flexor tendon retrieval, Refreshing tendons ends

**Tendon suture:**

Both, FDP and FDS were repaired in all zones by modified 6 strands (Savage method) technique using 3-0/4-0 Prolene sutures described in the review of literature

**Postoperative care**

Dorsal blocking splint used to hold the wrist 20-40 flexion the MP joints are flexed at least 60 degrees, and PIP and DIP joint in nearly full extension. Patient started active flexion of finger directly post operatively or can be delayed for couple of days till patient tolerate pain. Mostly we include the four fingers, there has been a gradual trend toward decreasing the degree of wrist flexion in postoperative protective splint

**Postoperative Rehabilitation**

Postoperative rehabilitation is the corner stone of a successful treatment of recent flexor tendon lesions. We applied it on immediate postoperative. We employed the early active mobilization protocol, where it basically focuses on more global active motion. We aimed at actively mobilization all joints distal and proximal to the lesion from the DIP to elbow, all this procedure is carried out with the dorsal extension block splint.

Return to professional activity is usually allowed after 3 months postoperatively to allow maximum recovery

**Patients were seen with the following frequency:**

- Once a week during the first 3 weeks postoperatively, at the end of the 5th week postoperatively, at the end of the 3rd month postoperatively
- Then with varying degrees of frequency according to individual variations as well as the needs of our study.

**Late postoperative**

The final assessment was considered according to the guidelines most commonly adopted in literature:

One month after return to work with the same level of activity with no significant change in the last 3 months follow up in patients with complications requiring a second procedure, the assessment just prior to the 2nd procedure was considered to be the final one.

The most frequently referenced method is Total Active Motion (TAM) as described by the American Society for Surgery of the Hand (ASSH)

Table (1) Postoperative care, Early active mobilization.

Dorsal Splint position	Motion allowed
Wrist 30° flexion	0-3 days
MCP 70° flexion	Antioedematous measures, limb elevation, active flexion allowed as much as patient can
IP full extended	0-2 weeks
Wrist 30° flexion	Encourage protected active finger flexion
MCP 70° flexion	
IP full extended	2-6 weeks
Wrist 0° flexion	Encourage protected active finger flexion
MCP 50° flexion	
IP full extended	6 weeks
Intermittent splinting: removed during exercise	Splint removed during exercise and patients continuous gliding exercise, flexion extension of the wrist with finger full flexed.
	Instruction to avoid simultaneous wrist and finger extension.
Splinting at night	Blocking exercises begin if active tip to distal palmar crease is more than 3 cm
No splint	Passive extension can begin at 7 weeks
	8 weeks
	Progressive resistive exercises initiated.
	14 weeks
	unrestricted use of hand

**Table (2)** TAM evaluation system of the ASSH.

<b>Excellent</b>	<b>100 %</b>
<b>Good</b>	> 75%
<b>Fair</b>	>50%
<b>Bad</b>	<50%

**3. Results**

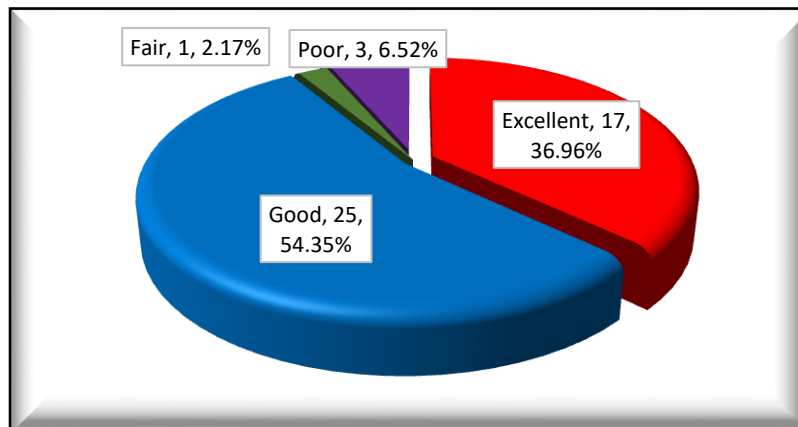
**According to ASSH evaluation**

- Return of 100% of active motion (excellent results) achieved in 17 finger
- Return of > 75 of achieve motion (good results) achieved in 25 finger
- Fair results achieved in 1 fingers.
- Poor results were achieved in 3 fingers

**Table (3)** Evaluation of TAM according to (ASSH) evaluation

<b>Level of TAM</b>		
	<b>N</b>	<b>%</b>
<b>Excellent</b>	17	36.96
<b>Good</b>	25	54.35
<b>Fair</b>	1	2.17
<b>Poor</b>	3	6.52
<b>Total</b>	46	100.00

This table shows that the excellent (54.76%), good (35.71%), poor (7.14%) and fair (2.38%) of level of TAM



**Fig. (1)** Evaluation of TAM according to (ASSH) evaluation

**Overall incidence of complications**

The overall incidence of complications was 14.3% (6 digits with complications) Table (22) shows the incidence of each complication in relation to the whole series.

**Table (4)** Incidence of Complications in the study group.

<b>Complications</b>	<b>No.</b> <b>[n=6 (14.3%)]</b>	<b>%</b>
<b>Infection</b>	1	2.17
<b>Rup</b>	2	4.35
<b>Skin contracture</b>	3	6.52

**4. Discussion**

For hand surgeons, flexor tendon injuries are a challenging, severe, and frustrating condition. Zone II injuries continue to be the most difficult to treat and

have the worst outcomes. Full mobility is not often obtained, even after precise surgical restoration. [6] When looking at the outcomes of flexor tendon restoration in the literature, there is a broad range of

range of motion from 50 to 100 percent. Physical therapy may begin sooner and be more aggressive with a robust six-strand repair. This may result in fewer adhesions, scarring, quicker edoema reduction, and an increase in ultimate range of motion, particularly in zone II [7]. The tensile strength of the six strand suture was shown to be superior than the two and four strand approaches in biomechanical experiments. According to the investigations, the break strength of a traditional Kessler repair is 24 N, a 4-strand repair (Lee double-loop) is 38 N, and a Savage 4-strand repair is 53 N. The average ultimate strength before breaking in the Savage 6-strand repair is 84 N. The strength of the repair rises as the number of core sutures increases. [8] Following flexor tendon repair, mobility is critical for healing and repair. Experiments have demonstrated that early mobility promotes tendon repair and reduces adhesion. Kleinert et al. and Lister et al. were among the first to report impressive clinical outcomes using active extension-passive flexion mobilisation and a dynamic traction splint. Subsequently, several writers observed similar findings. Nonetheless, flexion contracture of the finger may occur, and consistent flexion of the distal interphalangeal joint has proved difficult to establish. Poor differential gliding between the superficialis and profundus tendons in zone 2 causes the issue, which leads to adhesion development. [9] Active movement of the damaged finger will resolve these issues since it allows for normal physiological gliding between the tendons. The effects of early active mobilisation and active extension-passive flexion mobilisation have been observed in many investigations. [9] Over time, the functional outcomes of flexor tendon restoration have improved dramatically. However, there is still a trade-off between decreased scar development and the chance of re-rupture. The tendon restoration procedure and postoperative therapy programme should strike a balance between scar development and the danger of rupture. [6] The care of 46 finger lesions in 22 individuals was the subject of our research. The average age of the participants was 33.05 years (ranges from 23-48). The majority of the patients who had been operated on (66%), were manual labourers. The damaged tendons in various hand zones were repaired using a six-strand approach (Savage technique) (I-V). We started early active mobility of the repaired finger in a protective splint right after surgery (wrist flexion 30o, MCP 70o, interphalangeal joint 0o extension) and then changed the splint as per our procedure. The average follow-up time was 12.7 months. The final outcomes of the American Society for Surgery of the Hand's total active motion score were good to exceptional in 91.2 percent of patients (excellent 36.9% and good 54.3%, respectively). According to Strickland's assessment, 91.2 percent of the patients were in good to excellent condition (73.9 excellent, 17.3 good). We assessed two ruptures (4 percent) as bad results.

## 5. Conclusion

Suture technique and splinting procedures that are stronger will surely allow for more vigorous post-repair mobility programmes. The considerably enhanced outcomes that are now being attained using the approaches detailed in this research, however, give us great hope. When a strong, gap-resistant suture approach, such as the six strand technique employed in our research, is combined with early postoperative controlled mobility therapy, 91.2 percent of patients had excellent or good postoperative range of motion.

There will undoubtedly continue to be an avalanche of scientific and clinical data leading to repair and motion techniques that will provide consistently outstanding outcomes in this challenging field.

## References

- [1] Y. F. Wu and J. B. Tang .Recent developments in flexor tendon repair techniques and factors influencing strength of the tendon repair .The Journal of Hand Surgery(European Volume).vol 39E(1),PP.6–19,2014.
- [2] M.Sirotakova and D.Elliot, Early active mobilization of primary repairs of flexor pllicis longus tendon with two Kessler two-strand core sutures and a strengthened circumferential suture .j HandSurg{Br}.vol.29,pp.531-535,2004.
- [3] R.Savage, G.Risitango, Flexor tendon repair using six stand method of repair and early active mobilization, Journal ofHandSurgery.vol.14,pp.396-399,1989.
- [4] M. Karen Pettengill. The Evolution of Early Mobilization of the Repaired Flexor Tendon. J HAND THER.vol.18,pp.157–168,2005.
- [5] Michael A. Baskies, David V. Tuckman, Management of Flexor Tendon Injuries following Surgical Repair Bulletin of the NYU Hospital for Joint Diseases.vol.66(1),PP.35-40,2008.
- [6] S.Christiana , T.Tsu-Min, Clinical Results of Flexor Tendon Repair in Zone II Using a Strand Double Loop Technique..J Hand Microsurg.vol.7(1),pp.25–29,2015.
- [7] Hoffmann GL, Buchler U, Vogelin E. Clinical results of flexor tendon repair in zone 2 using a six-strand double loop technique compared with a two-strand technique. J Hand Surg Eur (2008) 33(4):418–22(6)
- [8] R.Savage, G.Risitango, Flexor tendon repair using six stand method of repair and early active mobilization, Journal of Hand Surgery.vol.14B,pp.396-399,1989.
- [9] LK.Ref Hung, KW.Pang, Active mobilization after flexor tendon repair: comparison of results following injuries in zone 2 and other zones. Journal of Orthopedic Surgery.vol.13(2),pp.158-163,2005.