

# Toxic Effect of Subchronic Use of Arsenic on the Liver of Adult Male Albino Rats and the Ameliorating Effect of Cerium Oxide Nanoparticles: Biochemical and Histological Study

Original  
Article

*Dalia M. Biram<sup>1,2</sup>, Youssef Hussein<sup>2,3</sup> and Rasha R. Salem<sup>1</sup>*

<sup>1</sup>*Department of Anatomy and Embryology, Faculty of Medicine, Alexandria University, Egypt*

<sup>2</sup>*Department of Anatomy and Histology, Faculty of Medicine, Mutah University, Al-Karak, Jordan*

<sup>3</sup>*Department of Human Anatomy And Embryology, Faculty of Medicine, Zagazig University, Egypt*

## ABSTRACT

**Introduction:** Arsenic is a heavy metal which is commonly present in the atmosphere. Most contamination of inorganic arsenic is caused by food, particularly seafood. The respiratory, cardiovascular, skin, central nervous system, kidneys, and liver are impaired by prolonged human exposure to arsenic. Cerium oxide nanoparticles (CeONPs) has promising antioxidant regenerative and hepatoprotective potentials against various pathologies caused by oxidative stress.

**Material and Methods:** All rats were subdivided into 3 groups (n=10) for a period of 8 weeks study: • Group I (the control group) where rats were injected 250 µl of phosphate buffered saline (PBS) intraperitoneally every other day. • Group II (the arsenic group) received arsenic trioxide, 3mg/kg body weight/day which is equivalent to 75% of LD50 value of a 70 kg body weight human (1–4mg/kg) and lesser than one thirteenth of LD50 value of rats (40mg/kg) by orogastric tube once daily for 8 weeks.

**Results:** Histological and ultrastructural tests have measured the hepatic toxicity. Additionally, it is tested by determination of an oxidative stress marker. Not only were CeONPs proven safe at the proposed dosage, but they also managed to reduce hepatic injury on both histological and biochemical aspects through their concomitant administration of Arsenic. Hepatic provocation on both histological and biochemical levels appeared to be mitigated. These hepatoprotective activity has been attributed to CeONPs' observed antioxidant action as demonstrated by the large difference in rates of MDA.

**Conclusion:** Therefore the purpose of this analysis was to evaluate either the CeONPs Shows hepatoprotective properties whether administered to or not concurrently with Arsenic.

**Received:** 05 December 2021, **Accepted:** 19 January 2022

**Key Words:** Arsenic, hepatotoxicity, nanoparticles, oxidative stress.

**Corresponding Author:** Rasha R. Salem, PhD, Department of Anatomy and Embryology, Faculty of Medicine, Alexandria University, Egypt, **Tel.:** +20 10 2571 2480, **E-mail:** rasha\_elrechy\_omar@yahoo.com

**ISSN:** 1110-0559, Vol. 46, No. 2

## INTRODUCTION

Arsenic is a heavy metal which is the 33rd element in the Periodic (Table 1) Arsenic is found in nature in three allotropic metallic forms yellow, black and grey, as well as a variety of ionic forms. Arsenic's most common oxidation values are +5, +3, and -3, indicating that it can form both inorganic and organic structures in the environment. And inside the human body<sup>[1,2]</sup>.

When it reacts with other elements like oxygen, chlorine, and sulphur, it becomes inorganic arsenic, however when it reacts with hydrogen and carbon, it becomes organic arsenic. Due to the lack of colour or odour in most arsenic compounds, the presence of arsenic in food, drink, or the atmosphere is not immediately detectable, resulting in a substantial human health effect given the deadly nature of arsenic<sup>[1,3]</sup>.

Arsenic is widely used in the environment, owing to naturally occurring sources such as volcanoes, sulphide

ores, and crustal rock weathering. Metal extraction, pesticide use, and airborne release from the melting of metals, namely nickel and copper, are all examples of artificial sources<sup>[4,5]</sup>.

People are exposed to arsenic on a regular basis because of its widespread environmental presence. Food, notably seafood, food additives, white and brown rice, and mushroom poisoning are the most common sources of inorganic arsenic<sup>[6,7,8]</sup>.

Arsenic has also been added with food to increase the growth and weight gain of hens and other farm animals in the veterinary industry. Moreover, arsenic compounds were previously frequently and haphazardly employed to treat disorders related to nutrition, such as anemia, cholera, skin disorders, malaria, and nerve tissue trypanosomiasis of the nervous tissue<sup>[9,10]</sup>.

Humans' respiratory, cardiovascular, skin, central nervous system, kidneys, and liver may be damaged by

long-term arsenic exposure. In terms of its teratogenic effects on animals, epidemiological studies have found a relevant link between high arsenic levels in water and occurrence of stillbirths and miscarriages<sup>[11]</sup>.

Cerium which is the first element in the lanthanide family, is the most common odd metal on earth. (CeONPs) are utilized to make a variety of industrial products, including oxygen sensors, polishing resources, and ultraviolet filters, which are also employed in the glass and optical industries. They also show promise as a diesel fuel that may be utilized to improve combustion efficiency as well as lowering diesel soot emissions.<sup>[12]</sup> It is self-evident that cerium oxide (CeO) may exist in both trivalent (Ce<sup>3+</sup>) and tetravalent (Ce<sup>4+</sup>) oxidation states, allowing for redox reactions.<sup>[13]</sup> CeONPs have a number of promising biological uses due to their regenerative power to chase free radicals, besides its anti-apoptotic, anti-angiogenic, and anti-inflammatory capabilities.<sup>[14]</sup> Many studies have been performed so far to understand the efficacy of cerium nanoparticles in the treatment of various reactive oxygen species-induced illnesses<sup>[15]</sup> such as neurological disorders<sup>[16]</sup> as well as inherited and acquired retinal disorders.<sup>[17]</sup> CeO, on the other hand, protects against endometriosis<sup>[18]</sup> hypertensive patients with microvascular anomalies<sup>[19]</sup> as well as in serious kidney damage.<sup>[20]</sup> Furthermore, CeONPs could inhibit cancer evolution and prepare tumor cells to radiotherapy.<sup>[21]</sup>

As a result, the goal of this study is to see if CeONPs can reduce Arsenic-induced hepatotoxicity in rats *in vivo*. Few studies have looked at CeONPs' protective effects on the livers of arsenic-treated animals, and there aren't enough experimental research on their effect on liver cellular activity. The goal of this research was to see how CeONPs affected hepatocytes of the adult male albino rats in trial to know the pathogenesis of the drug.

## MATERIALS AND METHODS

### Materials

CeONPs with a size of 25 nm (number 544841) were purchased from Sigma–Aldrich (St Louis, MO, USA) and diluted to 0.4 mg/ml in water. The resulting was treated at 230 V for 2 minutes by a USR3/2 907 sonicator right before *in vivo* use (Julabo Labortechnik, Seelbach, Germany).

EIMC United Pharmaceuticals supplied the sodium arsenate (Cairo, Egypt).

### Animals

We used thirty mature male Sprague Dawley rats (6–8 weeks old, 200–250 g). Rats were housed in standard laboratory conditions and fed a standard laboratory meal and water. Animals were cared for and used in accordance with guidelines established by the Animal House Center, Faculty of Medicine, Alexandria University.

### Experimental design

Rats were randomly divided into three groups of ten rats each for an eight-week study:

**Group I** (control): every other day, rats were given 250 µl of phosphate buffered saline (PBS) injected intraperitoneally (IP).

**Group II** (arsenic group) got 3mg/kg body weight/day of arsenic trioxide<sup>[22]</sup> by orogastric tube once daily for 8 weeks

**Group III** (CeONPs+ arsenic) was given IP injections of CeONPs suspension at a dose of 0.5 mg/kg once a week for 8 weeks, plus 3mg/kg body weight/day of arsenic trioxide<sup>[22]</sup> by orogastric tube once daily for 8 weeks

Animals were euthanized 24 hours after the last injection (day 15 of the research). Within one hour blood samples were collected (5 ml) from the aorta, then centrifuged at 1000g for ten minutes. Samples of liver tissue were obtained for histopathological assessment.<sup>[23]</sup>

### Liver function assays

Alkaline phosphatase, total protein, serum alanine aminotransferase (ALT) and aspartate aminotransferase (AST). Albumin and total bilirubin were used to determine globulins, which were obtained by subtracting albumin from total protein levels. Calorimetric kits from Spectrum Diagnostics were used to calculate all of the results (Cairo, Egypt). The absorbance of specimens was measured at 546 nm against a reagent blank using Humalyzer junior photometer (Human Diagnostics, Germany)

### Tissue samples

Small samples of rat liver were removed, cleaned, and divided into three groups: the first was kept at -80 °C until used for oxidative stress and antioxidant enzyme activity measurements; catalase (CAT), GSH value, and the amount of Malondialdehyde (MDA) and superoxide dismutase (SOD) were determined.<sup>[23,24]</sup>

The second group was homogenized for light microscope histological evaluation, while the third group was prepared for transmission electron microscopy ultrastructure study.

### Histology study

#### Light microscopy

The hepatic tissues (0.5 cm<sup>3</sup>) were placed in a 10% formol saline solution. All specimens were dehydrated in ethanol, then immersed in xylol before being embedded in paraffin. Hematoxylin and eosin (H&E) were used to stain 6 µm paraffin slices<sup>[25]</sup> At the Faculty of Medicine, Alexandria University . photomicrographs were taken with an Olympus microscope (fitted with a digital camera).

#### Transmission electron microscopy

Liver specimens (1mm<sup>3</sup>) were immersed in 3% glutaraldehyde in PBS (pH 7.4) for 24 hours at 4 °C, then

rinsed, fixed with 1% OsO<sub>4</sub> for 2 hours. After that, the specimens were dehydrated in a graded series of ethanol before being placed in epoxy resin. On a LKB microtome, ultrathin slices (90 nm) were cut with a diamond knife. They were then mounted on copper grids and dyed twice, once with uranyl acetate and once with lead citrate<sup>[26]</sup>. TEM (Jeol 100 CX, Tokyo, Japan) connected with a digital camera was used to obtain electron micrographs. At the unit of electron microscopy in Faculty of Science, Alexandria University.

### **Statistical analysis**

The information was collected and processed. The Statistical Package for Social Sciences (SPSS/version 21) software was used to conduct the statistical analysis. The following is the statistical tests that were used:

The mathematical mean, the standard deviation, and the variance are all terms that are used in mathematics. In the case of normally distributed data, an independent t-test was used to compare two independent populations, whereas more than two populations were studied. F-test (ANOVA) to be used. The level of significant was 0.05<sup>[12]</sup>.

## **RESULTS**

### **Biochemical results**

The biochemical statistical results were exposed in (Table 1, Histograms A,B,C-(Figure 1) that revealed insignificant statistical differences in the mean values of all biochemically analyzed parameters of (CeO<sub>2</sub>+ arsenic) managed group (G3) when compared to the control group (G1). However, the arsenic group (G2) revealed deteriorated and insufficient liver function that was statistically indicted by significant rise in the mean values of total bilirubin (T. B.), aminotransferases (AST, ALT), and alkaline phosphatase (ALP), in addition to significant decreases in the mean values of total proteins (T. P.) and albumin despite a statistically insignificant decline in the mean globulin's value when compared with the control group (G1). On the other hand, the third group (CeO<sub>2</sub>+ arsenic) revealed statistically significant reduce of the mean values of T.B., AST, ALT, and ALP beside significant statistical increases in the mean T. P. and Albumin, in spite of a statistically insignificant rise in the mean globulin's

values when compared with the group (G2): the arsenic group (Figure 2, Table2).

### **Histological results**

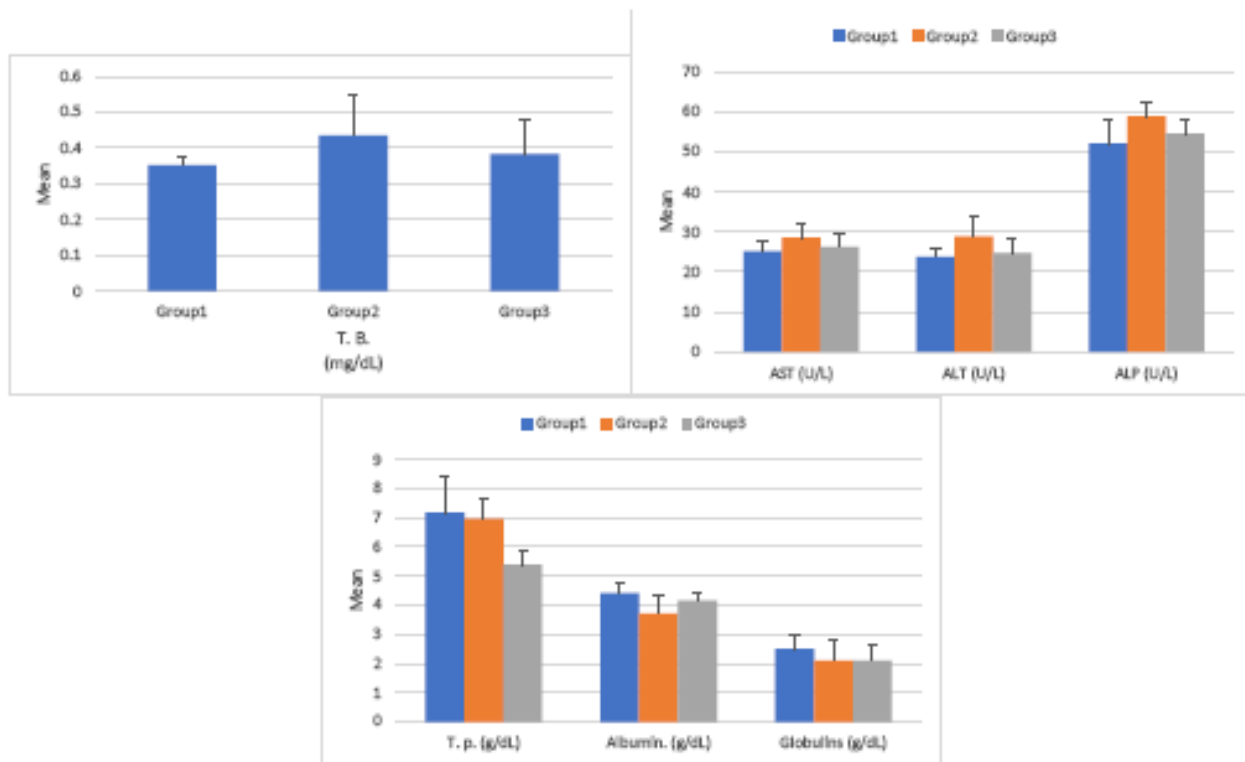
The control hepatic specimens (group 1) revealed a normal appearance that characterized by radially arranged anastomotic hepatocytes cords that were present from the central veins and blood sinusoids that lined by Kupffer cells were present between them, hepatocytes have bulky spherical nucleus with obvious nucleolus (Figure 3-G1).

The administration of Arsenic in G2 revealed that clear signs of hepatic deteriorations; these involved congested blood vessels, extensive vacuolar degeneration of liver cells, the blood sinusoids were engorged and lined with many Kupffer cells. Some areas of necrotic injury of hepatocytes in the form of small and picknotic nucleus with aggregated condensed chromatin, absence of nucleolus were noticed. There were also portal fibrosis, the portal tract (PT) in between the hepatic lobules despite of a slightly dilated portal vein (PV) and presence of multiple new angiomatous vessels (A) together with portal inflammatory cellular infiltration (if) (Figures 4,5 G2).

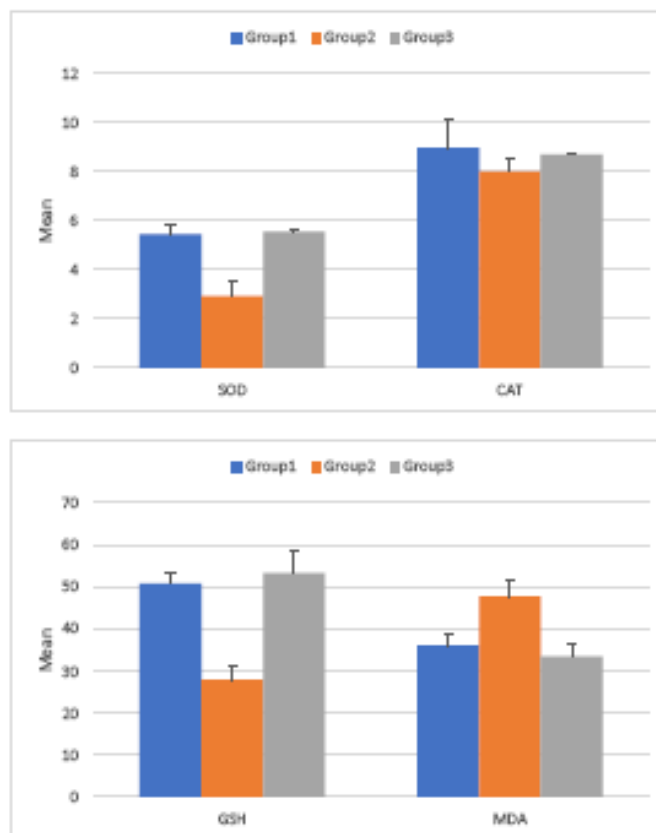
Liver of rats treated with CeONPs in combination with Arsenic showed marked recovery and restoration of almost normal hepatic appearance and architectures (Figure 6 G3)

### **Transmission electron microscopy**

The Liver cell of rat of groups I revealed healthy and normal ultrastructure seen as a normal euchromatic nucleus of hepatocyte and obvious nucleolus with Golgi apparatus, numerous rough endoplasmic reticulum and many mitochondria (Figure 7). Liver of group II which were subjected to Arsenic alone, the transmission electron microscopic observation cleared damage and injury of cells and nuclear membranes, less obvious nucleolus, destruction of mitochondria and rough endoplasmic reticula., with raised cytoplasmic fat droplets, cytoplasmic vacuoles (Figure 8). Rats of experimental group III which exposed to Arsenic plus CeONPs showed marked recovery and restoration of healthy ultra-structures, the mitochondria showed electron dense particles within its substance (Figure 9). Giving the appearance similar to those of group I

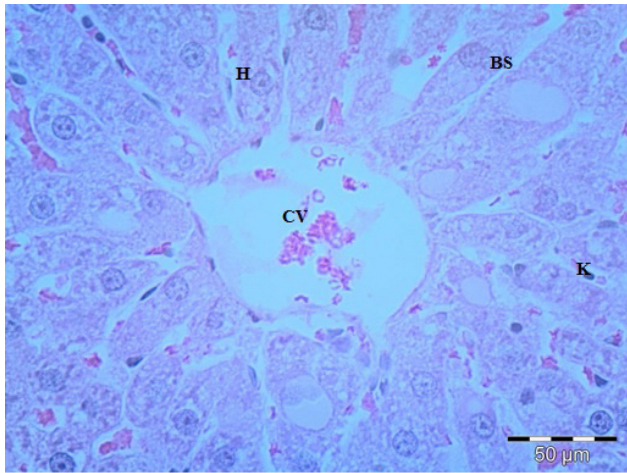


**Fig. 1:** Histograms (A,B and C) showing significant increases of the liver enzymes and total bilirubin together with significant decreases in albumin and total proteins, as well as insignificantly decreased globulins in G2 when compared to both control group (G1) and group (G3). In contrast, group 3 revealed insignificant mean values of all analyses when compared to the control group (G1).

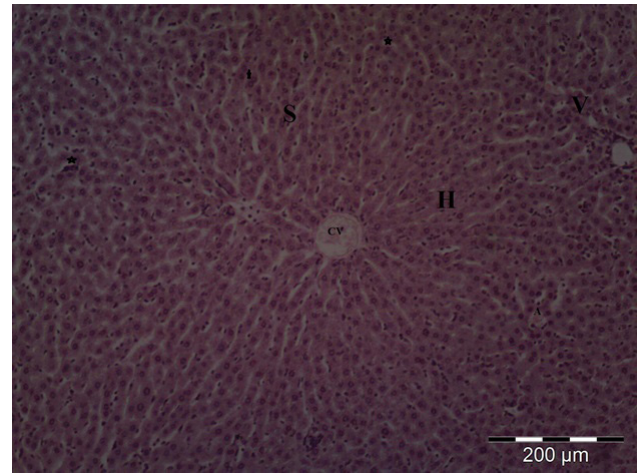


**Fig. 2:** Histograms (D and E) showing significant decreases of the oxidative markers SOD,CAT,GSH and significant increase of MDA in the arsenic group G2 when compared to (G1). In contrast, G3 revealed significant increases of the oxidative markers SOD,CAT,GSH and significant decrease of MDA when compared to group (G2)

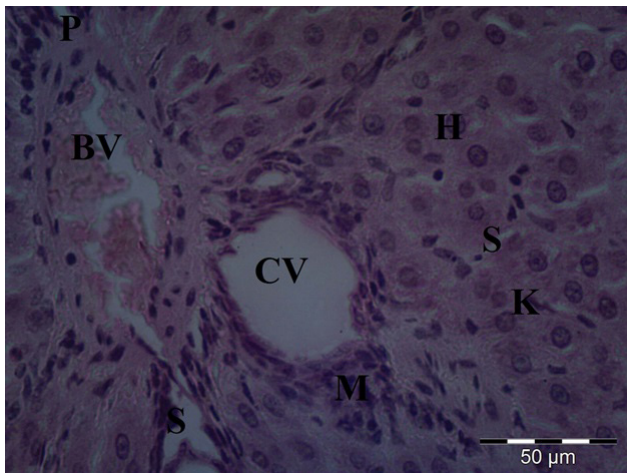




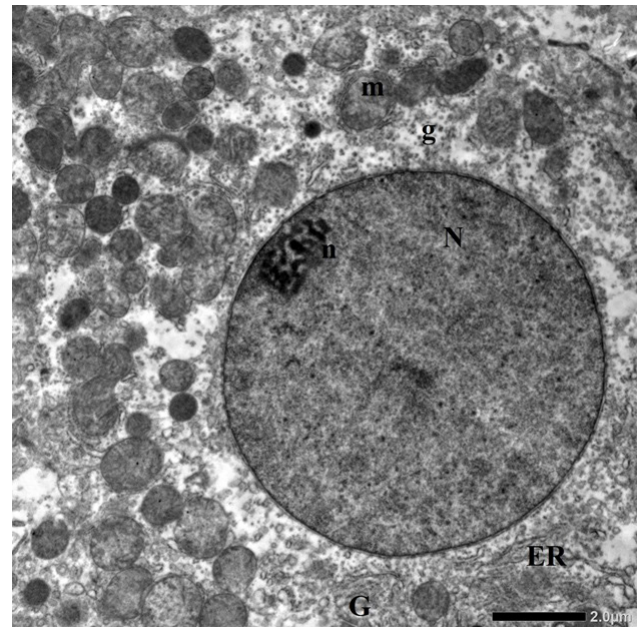
**Fig. 3:** A photomicrograph of a control rat liver specimen (G1) Revealing the hepatocytic cords (H) radiating from the central vein (CV) and the blood sinusoids (BS) containing kupffer cells (K); Hematoxylin [Hx.]& Eosin [Eo.] X400.



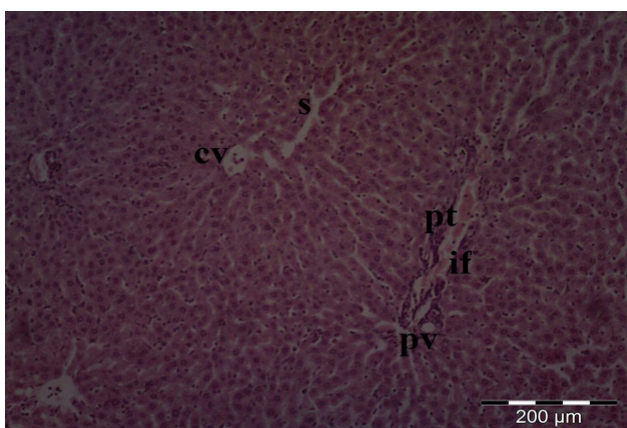
**Fig. 6:** Light photomicrograph of rat liver after eight weeks of exposure to CeONPs with Arsenic, showed marked decreased in degenerated hepatic cells (H), normal sized central vein (CV) and sinusoidal spaces (S) with the presence of some vacuoles(V) Notice some bi-nucleated hepatocytes (Star)H&E



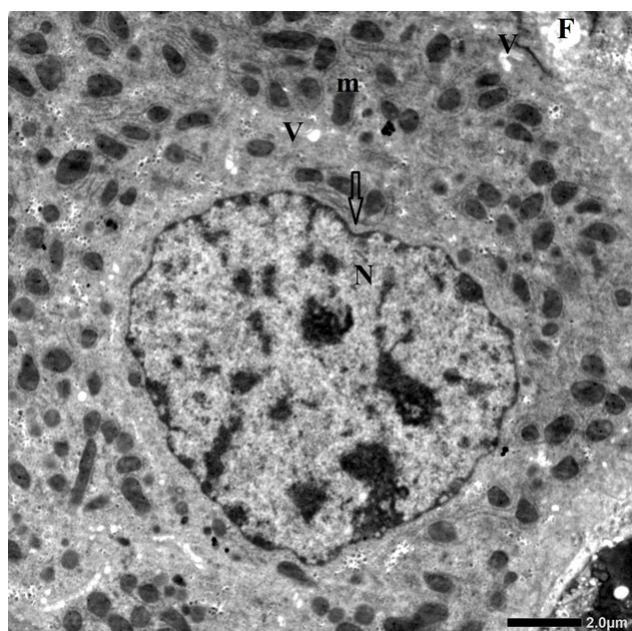
**Fig. 4:** Light photomicrograph of liver of rat after eight weeks of exposure to Arsenic revealed shrunken hepatocytes (H) with vacuolated cytoplasm, widening of blood sinusoids with abundant mononuclear cells (m) near sinusoids (S). Congested blood vessels (BV).The sinusoid walls showed numerous Kupffer cells (Kc).Notice that there were degenerated areas containing pyknotic nuclei (p) H&E



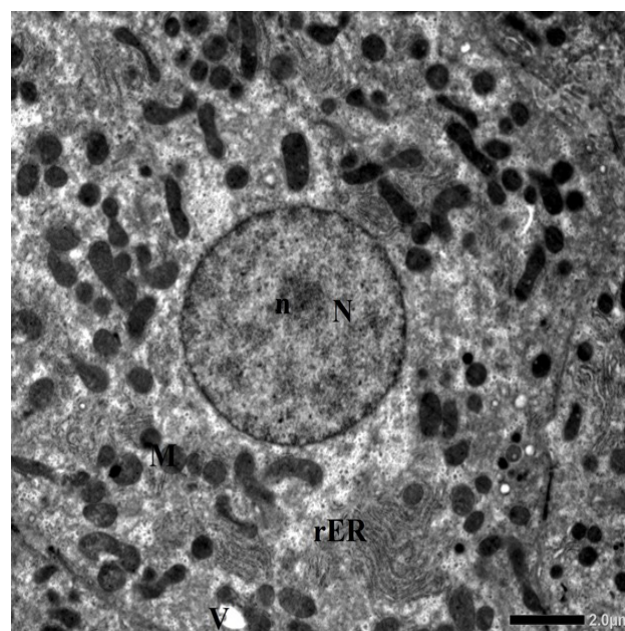
**Fig. 7:** Transmission electron microscopic photograph of the liver of control group revealed normal euchromatic nucleus (N) of hepatocyte and nucleolus(n) with Golgi apparatus (G),Rough endoplasmic reticulum (ER) and many mitochondria (m) abundant glycogen granules(g) TEM mag. =2500X



**Fig. 5:** Light photomicrograph of rat liver after eight weeks of Arsenic exposure( G2) revealed hepatic lobules formed of hepatocytic cords (H) and blood sinusoids (S) as well as portal tract (pt) in between the hepatic lobules despite of a slightly dilated portal vein (PV) with portal inflammatory cellular infiltration (if) H&E



**Fig. 8:** Electron micrographs of hepatocytes of rat treated with Arsenic for 8 weeks GII, revealed that destruction of cell membrane of liver cell with diminished size of its nucleus (N) with indentation (arrow) and less prominent nucleolus, swollen and pleomorphic mitochondria (m), large fat droplets (F), many cytoplasmic vacuoles (V), rarefaction of cytoplasm TEM mag.2000X.



**Fig. 9:** Transmission electron microscopic picture of a section of liver of group 3 showed, hepatocyte had euchromatic nucleus (N) and prominent nucleolus (n) . rough endoplasmic reticulum (rER), numerous mitochondria (m) Containing electron dense particles ,some vacuoles (v) TEM mag.12000X.

**Table 1:** Results of different analyzed chemical substances in serum of all groups

Analyzed substances	Group1	Group2	Group3	ANOVA P value	P1	P2	P3
T. B. (mg/dL)	0.352±0.022	0.436±0.112	0.383±0.097	16.21 0.001*	0.016*	0.171	0.0001*
AST (U/L)	25.142±2.770	28.558±3.681	26.308±1.713	11.31 0.0021*	0.015*	0.092	0.0483*
ALT (U/L)	23.819±2.143	28.875±4.88	24.787±2.486	10.98 0.0065*	0.005*	0.182	0.015*
ALP (U/L)	52.211±6.179	58.948±3.498	54.592±3.439	17.25 0.001*	0.002*	0.091	0.0058*
T. p. (g/dL)	7.184±1.262	6.965±0.888	5.397 ±0.515	8.25 0.016*	0.112	0.003	0.0488*
Albumin. (g/dL)	4.41±0.363	3.714±0.216	4.171±0.284	19.25 0.001*	0.001*	0.322	0.0004*
Globulins (g/dL)	2.515± 0.476	2.104±0.664	2.106±0.507	2.01 0.365 N.S.	0.488	0.220	0.496

ALP (alkaline phosphatase), ALT (alanine aminotransferase), AST (aspartate aminotransferase), G (group), T. B. (total bilirubin) and T. p. (total proteins).

Data was presented as mean±SD

P1 comparison between group 1 and 2

P2 comparison between group 1 and 3

P3 comparison between group 2 and 3



**Table 2:** Effect of Arsenic used alone or with CeONPs on Mean + SD on hepatic antioxidant enzymes in rats

Parameters	Group I (control)	Group II	Group III	ANOVA <i>P</i> value	P1	P2	P3
SOD	5.454±0.365	2.926±0.572	5.563±2.16	16.85 0.001*	0.0001	0.2133	0.001
CAT	8.979±1.189	7.99±0.591	8.689±0.07	17.65 0.001*	0.001	0.492	0.002
GSH	50.776±3.139	27.96±3.463	53.280±5.333	21.3 0.001*	0.001	0.108	0.001
MDA	36.155±2.82	47.724±3.799	33.41±2.912	16.85 0.001*	0.001	0.023	0.001

Number per group = 10

Data was presented as mean±SD

P1 comparison between group 1 and 2

P2 comparison between group 1 and 3

P3 comparison between group 2 and 3

GSH :Glutathione

SOD: Super Oxide Dismutase

CAT: CAT alase

MDA: Malondialdehyde

## DISCUSSION

Liver is the major organ exposed to chronic arsenic poisoning and its function in arsenic biotransformation is well known; this function is mainly found in areas of the world with high levels of arsenic in water especially used in beverages<sup>[27]</sup>

The exact mechanisms through which this heavy metal injures the liver may be caused through oxidative stress<sup>[28,29]</sup>, extreme inflammation<sup>[30,31]</sup> And alterations in cell methylation<sup>[30,31,32,33]</sup>. All the cellular apoptosis and the major necrosis involved oxidative stress. Definitely, it has been discovered in various systems that in cell death, reactive oxygen species (ROS) are formed and antioxidant inhibition of ROS development moreover catalase or superoxide dismutase detoxifying enzymes have protective vitality<sup>[34,35]</sup>.

ROS consist of superoxide, nitric oxide, hydrogen peroxide and hydroxyl radicals. Owing to its simple passage through membrane barriers to the nucleus of the cell, hydroxyl radical is the key toxic and interacts strongly with DNA<sup>[36]</sup>. The present study showed that arsenic had decreased antioxidant pool (GSH) and antioxidant enzyme levels (SOD, CAT).

These results coincided with certain preceding studies<sup>[37,38,39,40,41,42]</sup>. All who concluded that arsenic enhanced lipid peroxidation and protein oxidation, both, of which reflect high oxidative stress indices. Reports of other liver injury factors (ALT, AST, ALP) were also enhanced by arsenic intoxication.

The present study found that arsenic, induced damage to the hepatocytes And necrosis contributes to the release of liver enzymes into the bloodstream, which may be The key factor in clearing the significant elevation of their serum values. This comes in agreements with many preceding researches<sup>[43,44,45,46,47,48,49,50,51]</sup>. The same arsenic effect has been observed in mitochondrial islet cells.<sup>[33]</sup>

Many studies have shown that arsenic may inhibit complex I of the mitochondrial electron transport chain, which contributes to increased mitochondrial permeability transition (MPT) with the development of ROS and thiol oxidation<sup>[52]</sup>. In addition, Arsenic mediated apoptosis may be triggered by aggregation of the mitochondrial material and transmembrane potential disruption<sup>[53]</sup>

Arsenic poisoning, whether acute, subacute, chronic resulted in the deposition of arsenic in the hepatic and renal tissues, resulting in an increase in hepatic enzymes and histopathological pathological changes such as inflammatory infiltration, fatty infiltration, and cellular necrosis.<sup>[42,48,49,54]</sup> In the current study, both centrilobular and perilobular hepatocytes showed vacuolations and lipid accumulation, which manifested as Steatosis. This is consistent with past research. Steatosis is a common cellular reaction to toxic abuse that is usually reversible, but its prevalence in the liver is particularly well-known because it plays such an important role in fat metabolism<sup>[42,55]</sup>

Intake of CeONPs (group III) kept liver cells near normal hepatic histological ultrastructure, with acidophilic granular cytoplasm and central nuclei, many bi-nucleated hepatocytes and electron dense particles in mitochondria clarifying the shelter of CeONPs and its protective effects of the tested dose on hepatic histological ultrastructure. Blood sinusoids, on the other hand, were clearly dilated, as evidenced by the large gap between the radiating cellular cords in hepatic lobule. This was in according with the findings of Heba G. Ibrahim *et al*<sup>[23]</sup> who investigated the role of cerium in the regeneration of liver cells following doxorubicin intoxication. The similar gaps were observed after intratracheal injection of CeONPs at doses of 1–7 mg/kg. this was done to increase the vitality of hepatocytes by increasing the given dose of CeONPs. Numerous mechanisms for sinusoidal dilation have been identified by Marzano *et al*, including a veno-occlusive lesion (portal outflow obstruction), a non-specific inflammatory response caused by other different drugs, such as oral contraceptive

pills. Sinusoidal dilatation is hypothesized to be caused by stimulation of the interleukin-6 and vascular endothelial growth factor-related pathways.<sup>[56]</sup>

Fortunately, taking CeONPs and Arsenic (group III) at the same time revealed preserved hepatic architecture. In the cytoplasm and vesicular nuclei of hepatocytes, there was very little vacuolation. The histological features of the portal tract were intact, and inflammatory cell infiltration was reduced. CeONPs inhibit ROS production and the scavenge the present ones. Moreover, they stimulate many antioxidant enzymes<sup>[23]</sup> The findings of this study corroborated prior research that revealed CeONPs could protect rats from hepatotoxicity caused by monocrotaline consumption<sup>[23]</sup> and decrease hyperlipidemia in CCl<sub>4</sub>-induced liver toxicity<sup>[57]</sup> Several bi-nucleated hepatocytes were found, which might be used to determine the hepatocytes' efficient regeneration influence in comparison to the a single nucleus present in Arsenic group. Bi-nucleated hepatocytes are the most susceptible to hepatocyte growth hormones<sup>[58]</sup> and frequently undergo mitosis in cases of liver injury and damage. This was in accordance with the findings of Heba G. Ibrahim *et al.*<sup>[23]</sup>

Hepatocytes architecture was highly conserved in group III, according to electron microscopy. Group II, on the other hand, displayed highly damaged hepatocytes with significant rarefaction in the cytoplasm, which is a characteristic of hydropic degeneration. as well as a dilated rER in group III (DOX+CeO) were less rarefied/ vacuolated than those in group II. They had euchromatic spherical nuclei that were regular with prominent nucleoli and organelles with normal structure

Nanoparticles of cerium could be found in mitochondria, lysosomes, endoplasmic reticulum, and even the nucleus, according to Singh and colleagues<sup>[59]</sup> Because of the wide spectrum of intracellular distribution, the cells are protected from various oxidative stress processes. The presence of CeONPs in the mitochondria, as demonstrated in this study, considerably improves their antioxidative capacity.<sup>[60,61]</sup>

## CONCLUSION

The results of this work indicated the role of oxidative stress caused by arsenic toxicity, which may be measured by an increase in liver enzymes and MDA levels, as well as a decrease in GSH levels, in addition to histopathological damage. CeONPs -at the tested dose- were found to have a hepatoprotective effect against arsenic-induced hepatotoxicity, with no obvious side effects. On hepatocytes. Furthermore, because they have anti-oxidant properties, they reduce the structural and biochemical effects of arsenate on the liver. Such findings will be of help for future *in vivo* studies with a variety of cancer animal models rather than adult healthy rats.

## CONFLIT OF INTERESTS

There are no conflicts of interest.

## REFERENCES

1. Mandel BK, Suzuki KT. Arsenic round the world: a review. *Talanta*. 2002; 58: 201-35.
2. Orloff K, Mistry K, Metcalf S. Biomonitoring for environmental exposures to arsenic. *J. Toxicol. Environ. Health B Crit. Rev.* 2009; 12: 509-24.
3. Chou S, Harper C, Ingerman L, Lladós F, Colman J, Chappell L. Etc. Toxicological Profile for Arsenic. US Department of health and human service. Agency for Toxic substances and disease registry 2007.
4. Campillo N, Vinas P, Garcia IL, Cordopa MH. Determination of arsenic in biological fluids by electrothermal atomic absorption spectrometry. *Analyst*. 2000; 125: 313-7.
5. Chappell WR, Beck BD, Brown KG, Chaney BR, Cothorn R, Chaney R, etc. Inorganic arsenic: a need and an opportunity to improve risk Assessment. *Environ. Health perspect.* 1997; 105: 1060-70.
6. Magalhaes MCF. Arsenic. An environmental problem limited by solubility. *Pure Appl. Chem.* 2002; 74: 1843-50.
7. Nepusz T, Petroczi A, Naughton DP. Food alert patterns for metal contamination analysis in seafoods: longitudinal and geographical perspectives. *Environ. Int.* 2009; 35: 1030-3.
8. Petroczi A, Naughton DP. Mercury, cadmium and lead contamination in seafood: a comparative study to evaluate the usefulness of Target Hazard Quotients. *Food Chem. Toxicol.* 2009; 47: 298-302.
9. Jones FT. A broad view of arsenic. *Poultry Sci.* 2007; 86: 2-14.
10. Leonard A, Lauwery C. Carcinogenicity, teratogenicity and mutagenicity of arsenic. *Mutation Res.* 1980; 75: 49-62.
11. Concha G, Vogler G, Lezcano D, Nermell B, Vahter M. Exposure to inorganic arsenic metabolites during early human development. *Toxicol. Sci.* 1998; 44: 185-90.
12. Dahle JT, Arai Y. Environmental geochemistry of cerium: applications and toxicology of cerium oxide nanoparticles. *Int. J. Environ. Res. Public Health.* 2015; 12 (2): 1253–1278.
13. Nelson BC, Johnson ME, Walker ML, Riley KR, Sims CM. Antioxidant cerium oxide nanoparticles in biology and medicine, *Antioxidants.* 2016 ; 5 (2) :15.
14. Amin KA, Hassan MS, Awad E S, Hashem KS. The protective effects of cerium oxide nanoparticles against hepatic oxidative damage induced by monocrotaline. *Int. J. Nanomed.* 2011; 6: 143–149.



15. Ge X, Li, Yuan Q, 1d ceria nanomaterials: versatile synthesis and bio-application, *J. Mater. Sci. Technol.* 2015; 31 :6645–654.
16. Kwon HJ, Cha MY, Kim D, Kim DK, Soh M, Shin K, Hyeon T, Mook-Jung I. Mitochondria-targeting ceria nanoparticles as antioxidants for Alzheimer's disease. *ACS Nano.* 2016; 10 (2): 2860–2870.
17. Cai X, McGinnis FJ. Nanoceria: a potential therapeutic for dry AMD, in: C. Bowes Rickman, M.M. LaVail, E.R. Anderson, C. Grimm, J. Hollyfield, J. Ash (Eds.), *Retinal Degenerative Diseases: Mechanisms and Experimental Therapy.* Springer International Publishing, Cham. 2016; pp. 111–118.
18. Chaudhury K, Babu N, Singh AK, Das S, Kumar A, Seal S. Mitigation of endometriosis using regenerative cerium oxide nanoparticles. *Nanomedicine.* 2013; 9 (3):439–448.
19. Minarchick VC, Stapleton PA, Sabolsky EM, Nurkiewicz TR. Cerium dioxide nanoparticle exposure improves microvascular dysfunction and reduces oxidative stress in spontaneously hypertensive rats. *Front. Physiol.* 2015; 6 339.
20. Manne NDPK, Arvapalli R., Nepal N, Shokuhfar T, Rice KM, Asano S, Blough ER. Cerium oxide nanoparticles attenuate acute kidney injury induced by intra-abdominal infection in Sprague–Dawley rats., *J. Nanobiotechnol.* 2015 ; 13 (1):1–11.
21. Chen F, Zhang XH., Hu XD, Zhang W, Lou ZC, Xie LH, Liu PD, Zhang HQ. Enhancement of radiotherapy by ceria nanoparticles modified with neogambogic acid in breast cancer cells. *Int. J. Nanomed.* 2015 ; 10 4957.
22. North DW, Gibb HJ, Abernathy CO. Arsenic: past, present and future considerations. In: Abernathy CO, Calderon RL, Chappell WR (Eds.), *Arsenic-Exposure and Health Effects.* Chapman and Hall, London, 1997. pp. 407–423.
23. Heba G, Ibrahima, Noha Attiaa,b, Fatma El Zahraa A, Hashema, Moushira AR, El Heneidya. Cerium oxide nanoparticles: In pursuit of liver protection against doxorubicin-induced injury in rats. *Biomedicine & Pharmacotherapy.* 2018 ; 103: 773–781
24. Reitman S, Frankel S, A colorimetric method for the determination of serum glutamic oxalacetic and glutamic pyruvic transaminases, *Am. J. Clin. Pathol.* 1957 ; 28 (1): 56–63.
25. Bishop ML, Fody EP, Schoeff LE, *Clinical Chemistry: Principles, Techniques, and Correlations,* Wolters Kluwer Health, Philadelphia, 2013 pp. 278–280.
26. Suvarna SK, Layton C, Bancroft .D, *Bancroft's Theory and Practice of Histological Techniques,* Churchill Livingstone, Oxford, 2013 pp. 493–508.
27. Santra A, Das GJ, De BK, Roy B, Guha Mazumder DN. Hepatic manifestations in chronic arsenic toxicity. *Indian J. Gastroenterol.* 1999; 18, 152–155.
28. Kitchin KT. Recent advances in arsenic carcinogenesis: modes of action, animal model systems, and methylated arsenic metabolites. *Toxicol. Appl. Pharmacol.* 2001; 172, 249–261.
29. Patrick L. Toxic metals and antioxidants: Part II. The role of antioxidants in arsenic and cadmium toxicity. *Altern. Med. Rev.* 2003; 8, 106–128.
30. Chen H, Li S, Liu J, Diwan BA, Barrett JC, Waalkes MP. Chronic inorganic arsenic exposure induces hepatic global and individual gene hypomethylation: implications for arsenic hepatocarcinogenesis. *Carcinogenesis.* 2004; 25, 1779–1786.
31. Mukherjee S, Das D, Mukherjee M, Das AS, Mitra C. Synergistic effect of folic acid and vitamin B12 in ameliorating arsenic-induced oxidative damage in pancreatic tissue of rat. *J. Nutr. Biochem.* 2006b; 17, 319–327.
32. Mukherjee S, Das D, Darbar S, Mitra, C. Dietary intervention affects arsenic-generated nitric oxide and reactive oxygen intermediate toxicity in islet cells of rats. *Curr. Sci.* 2003; 85, 786–793.
33. Majumdar S, Mukherjee S, Maiti A, Karmakar S, Das AS, Mukherjee M, Nanda A, Mitra C. Folic acid or combination of folic acid and vitamin B12 prevents short-term arsenic trioxide-induced systemic and mitochondrial dysfunction and DNA damage. *Environ. Toxicol.* 2009; 24, 377–387.
34. Fiers W, Beyaert R, Declercq W, Vandenabeele . More than one way to die: apoptosis, necrosis and reactive oxygen damage. *Oncogene.* 1999; 18, 7719–7730.
35. Proskuryakov SY, Konoplyannikov AG, Gabai VL. Necrosis: a specific form of programmed cell death? *Exp. Cell Res.* 2003; 283, 1–16.
36. Robertson RP, Harmon J, Tran PO, Tanaka Y, Takahashi H. Glucose toxicity in cells: type-2 diabetes, good radicals gone bad and the glutathione connection. *Diabetes.* 2003. 52, 581–587.
37. Flora, SJ, Dube SN, Arora U, Kannan GM, Shukla MK, Malhotra PR. Therapeutic potential of meso-2,3-dimercaptosuccinic acid or 2,3-dimercaptopropane sulfonate in chronic arsenic intoxication in rats. 1988; 8(2): 111-116.
38. Mourelle M, Favaris L, Amezcua, JL. Protection against thalium hepatotoxicity by silymarin. *J. Appl. Toxicol.* 1988; 8: 351-354.
39. Chang WC, Wu HL, Shi GY, Murota SI, Mortia I. Cytoprotective effect of reduced glutathione in arsenical induced endothelial cell injury. *Toxicology.* 1991; 69: 101-107.

40. Zaman K, MacGill RS, Johnson JE, Ahmad S, Pardini RS. An insect model for assessing oxidative stress related to arsenic toxicity. *Arch. Insect Biochem. Physiol.* 1994; 29(2):199-209.
41. Chouchane S. In *vitro* effect of arsenical compound on glutathione-related enzymes. *Chem. Res. Toxicol.* 2001; 14(5):517- 522.
42. Ahmed T. Elshennawy, Mahmoud A. El-Gharieb, Mohammad A. Hashem. Histophysiological Evaluation of the Effect of Alpha-Tocopherol and Dimethyl Diphenyl Bicarboxylate on Arsenic-Induced Hepatotoxicity in Adult Male Albino Rats. *Bull. Egypt. Soc. Physiol. Sci.* 2008;28 (1)
43. Lech T. and Flora F. Massive acute arsenic poisoning. *Forensic Sci. Int.* 2005; 151: 273.
44. Aposhian HV. and Aposhian MM. Newer developments in arsenic toxicity. *J. Am. Coll. Toxicol.* 1989; 8: 1297-1305.
45. Abernathy CO. and Obanian EV. Non-carcinogenic effects of inorganic arsenic. *Environmental Geochemistry and Health.* 1992; 14:35-41.
46. Tripathi N. and Flora SJ. Effects of some thiol chelators on enzymatic activities in blood, liver and kidneys of acute arsenic exposed mice. *Biomed. Environ. Sci.* 1998; 11(1):38-45.
47. Guha Mazumder DN, Das Gupta J, Santra A, Pal A, Ghose A, Sarkar S. Chronic arsenic toxicity in West Bengal; The worst calamity in the world. *J. Ind. Med. Associ.* 1998; 96:4- 7, 18.
48. Liu J, Liu, Y, Goyer RA, Achanzar W, Waalkes MP. Metallothionein-I/II null mice are more sensitive than wild-type mice to the hepatotoxic and nephrotoxic effects of chronic oral or injected inorganic arsenicals. *Toxicol. Sci.* 2000; 55(2):460-467.
49. Flora SJ, Pant SC, Malhotra PR, Kannan GM. Biochemical and histopathological changes in arsenic-intoxicated rats. *Alcohol.* 1997; 14(6):563-568.
50. Alward BFMA. Developing a precautionary warning for heavy metals using loons as target species. Thesis. 2007; Tufts University. 102 pages.
51. Sangita Majumdar, Subhra Karmakar, Anasuya Maiti, Monalisa Choudhury, Aniruddha Ghosh, Asankur Sekhar Das, Chandan Mitra. Arsenic induced hepatic mitochondrial toxicity in rats and its amelioration by dietary phosphate. *environmental toxicology and pharmacology* . 2011; 31: 107-118
52. Letak N, Vladimir G, Wanlaya U, Banafsheh M, David JM, Sten O. Indirect effects of box and bak initiate the mitochondrial alterations that lead to cytochrome c released during arsenic trioxide-induced apoptosis. *Cancer Biol. Ther.* 2005;4, 459-467.
53. Cai X, Shen YL, Zhu Q, Jia PM, Yu Y, Zhou L, Huang Y, Zhang JW, Xiong SM, Chen SJ, Wang ZY, Chen Z, Chen GQ. Arsenic trioxide-induced apoptosis and differentiation are associated respectively with mitochondrial transmembrane potential collapse and retinoic acid signaling pathways in acute promyelocytic leukemia. *Leukemia.* 2000;14,262-270.
54. Pillatzki AE. Hepatic element concentrations and gross and histological examinations of spring migrating lesser scaup (*Aythya affinis*) in upper Midwest. M.S. Thesis, South Dakota State University. 2007;128 pages.
55. Lee TC. and Ho IC. Differential cytotoxic effects of arsenic on human and animal cells. 1994;102 Suppl. 3:101-105.
56. Nalabotu SK, Kolli MB, Triest WE, Ma JY, Manne ND, Katta A, Addagarla HS, Rice KM, Blough ER, Intratracheal instillation of cerium oxide nanoparticles induces hepatic toxicity in male Sprague-Dawley rats. *Int. J. Nanomed.* 2011 ; 6: 2327.
57. Naik RN, Rao ST, Rao DD, Rao KR, Rao TM. Identification of anti hyperlipidemic activity of cerium oxide nano particles in rat model. *Int. J. Pharm. Sci. Res.* (2015) ; 6 (2) :728-732.
58. Hammad S., Friebel A, Begher-Tibbe B, Othman A, Vartak A, Hoehme S, Edlund K, Vonrecklinghausen I, Drasdo D, Hengstler JG. Role of Binucleated Hepatocytes in Hepatotoxicity and Liver Regeneration, *Naunyn-schmiedebergs Archives of Pharmacology*, Springer, 233 Spring St, New York, NY 10013 USA, 2014 pp. S46-S47.
59. Singh S, Kumar A, Karakoti A, Seal S, Self WT. Unveiling the mechanism of uptake and sub-cellular distribution of cerium oxide nanoparticles, *Mol. Biosyst.* 2010; 6(10): 1813-1820.
60. Pagliari F, Mandoli C, Forte G, Magnani E, Pagliari S, Nardone G, Licocchia S, Minieri M, Di Nardo P, Traversa E. Cerium oxide nanoparticles protect cardiac progenitor cells from oxidative stress, *ACS Nano.* 2012 ; 6 (5): 3767-3775.
61. S.K. Nalabotu, M.B. Kolli, W.E. Triest, J.Y. Ma, N.D. Manne, A. Katta, H.S. Addagarla, K.M. Rice, E.R. Blough, Intratracheal instillation of cerium oxide nanoparticles induces hepatic toxicity in male Sprague-Dawley rats, *Int. J. Nanomed.* 6 (2011) 2327.

## الملخص العربي

# التأثير السام للاستخدام الفرعي لأرسينيك على كبد ذكور فئران ألبينو البالغة والتأثير المُحسن للجسيمات النانوية لأكسيد السيريوم: دراسة بيوكيميائية وهستولوجية

داليا م. بيرم<sup>١،٢</sup>، يوسف حسين<sup>٢،٣</sup>، رشا ر. سالم<sup>١</sup>

<sup>١</sup>قسم التشريخ وعلم الأجنة، كلية الطب، جامعة الإسكندرية، مصر

<sup>٢</sup>قسم التشريخ والأنسجة، كلية الطب، جامعة مؤتة، الكرك، الأردن

<sup>٣</sup>قسم التشريخ البشري وعلم الأجنة، كلية الطب، جامعة الزقازيق، مصر

**الخلفية:** الزرنيخ معدن ثقيل يوجد عادة في الغلاف الجوي. معظم تلوث الزرنيخ غير العضوي ناتج عن الطعام ، وخاصة المأكولات البحرية. يتضرر الجهاز التنفسي والقلب والأوعية الدموية والجلد والجهاز العصبي المركزي والكلى والكبد بسبب تعرض الإنسان لفترات طويلة للزرنيخ. الهدف من العمل : التأكد من ان الجسيمات النانوية لأكسيد السيريوم (CeONPs) لها إمكانات واعدة للتجديد ووقاية الكبد ضد الأمراض المختلفة التي تسببها الإجهاد التأكسدي.

**المواد والطرق:** تم تقسيم جميع الفئران إلى ٣ مجموعات (ن = ١٠) لمدة ٨ أسابيع دراسة: • المجموعة الأولى (المجموعة الضابطة) حيث تم حقن الفئران ٢٥٠ ميكرو لتر من محلول ملحي فوسفات (PBS) داخل الصفاق كل يوم. • المجموعة الثانية (مجموعة الزرنيخ) تلقت ثالث أكسيد الزرنيخ ، ٣ ملجم / كجم من وزن الجسم / يوم وهو ما يعادل ٧٥٪ من قيمة LD<sub>٥٠</sub> لوزن جسم الإنسان ٧٠ كجم (١-٤ ملجم / كجم) وأقل من واحد على عشر من قيمة LD<sub>٥٠</sub> الجرذان (٤٠ ملجم / كجم) عن طريق الأنبوب الفموي مرة واحدة يوميًا لمدة ٨ أسابيع

**النتائج:** قامت الاختبارات النسيجية والتركيبية بقياس السمية الكبدية. بالإضافة إلى ذلك ، تم تحديد علامة الإجهاد التأكسدي. وقد ثبت أن الجسيمات النانوية لأكسيد السيريوم آمن بالجرعة المقترحة ، وتمكنوا أيضًا من تقليل الإصابة الكبدية على كل من الجوانب النسيجية والكيميائية الحيوية من خلال تناولهم المتزامن للزرنيخ. يبدو أن الاستفزاز الكبدي على المستويين النسيجي والكيميائي الحيوي قد تم تخفيفه. يعزى هذا النشاط الكبدي إلى مراقبة الجسيمات النانوية لأكسيد السيريوم علي تأثير مضادات الأكسدة

**الخلاصة:** لذلك كان الغرض من هذا التحليل هو تقييم الجسيمات النانوية لأكسيد السيريوم علي حماية الكبد سواء تم إعطاؤه بشكل متزامن أم لا مع الزرنيخ.