



Effect of Systemic Administration of Simvastatin on Dental Implant Stability

Aya M. Sharaf Eldeen^{1*}, Osama El-Shall², Mai S. Attia³

Codex : 12/22.01

azhardentj@azhar.edu.eg

http://adjg.journals.ekb.eg

DOI: 10.21608/adjg.2021.47686.1310

Oral Medicine & Surgical Sciences
(Oral Medicine, Oral & Maxillofacial
Surgery, Oral Pathology, Oral Biology)

ABSTRACT

Purpose: This study was designed to evaluate implant stability in partially edentulous patients by investigating the effect of systemic simvastatin administration on the bone regeneration around the dental implant. **Patients and Methods:** A total of 18 patients were divided into two groups. Group I:9 healthy patients underwent a one-stage titanium screw-type endosseous dental implant **and** Group II:9 patients on simvastatin therapy (20 mg daily) as a prophylaxis drug, underwent the same type of one stage titanium screw type of endosseous dental implant as the control group. Modified plaque index (MPI), Probing depth (PD) and Modified Gingival Index (MGI) were recorded. Implant stability was recorded immediately and after 6months. **Results:** Group II showed a higher mean implant stability (79.14 ± 4.38) than group I (72.86 ± 11.41) at 6 months with a non-significant difference Also, there is a nonsignificant difference of MPI, MGI, and PD between both groups after 3 and 6 months respectively.

Conclusion: Simvastatin group showed higher implant stability than the control group. Simvastatin might have the ability to assist and enhance the osseointegration procedure for bone surrounding the dental implant.

INTRODUCTION

Missing teeth are commonly replaced by dental implants. The aim of dental implants is to increase the patient satisfaction with enhanced chewing efficiency, physical health, and aesthetics⁽¹⁾.

KEYWORDS

Implant Stability, Simvastatin,
bone regeneration.

* A paper extracted from Master thesis titled “Effect of Systemic Administration of Simvastatin on Dental Implant Stability”

1. Dentist at Egyptian Ministry of Health, Cairo, Egypt.
2. Professor of Oral Medicine, Periodontology, Diagnosis and Radiology Faculty of Dental Medicine for Girls, Al-Azhar University, Cairo, Egypt
3. Associate Professor, Department of Oral Medicine, Periodontology, Diagnosis and Radiology, Faculty of Dental Medicine for Girls, Al-Azhar University, Cairo, Egypt.

* Corresponding author email: ayasharaf122@gmail.com

Implant stability is a measure of the clinical immobility of an implant, which is a direct sign or a necessary feature of osseointegration^(2,3). It is achieved on two levels: primary and secondary stability. Implant position, bone density, length, width, type of implant and drilling technique are a major factor to achieve the primary stability, The secondary stability is influenced by the implant surface and the wound healing time and depends on bone formation and remodeling at the bone interface of the implant⁽⁴⁾.

Osseointegration is one of the most important cause that affect the implant's success and survival⁽⁵⁾. A group of auxiliary treatments has been proposed with the modernization of implantology to enhance the osseointegration of implants and bone-to-implant contact (BIC). The use of hydroxymethylglutaryl coenzyme A reductase inhibitors (or statins) is one such auxiliary therapy. Statins are anti-cholesterol medicines that prevent liver cholesterol biosynthesis, thus lowering serum cholesterol levels and reducing the possibility of CVD^(6,7). Statins have been classified into, hydrophilic statins and lipophilic statins (such as simvastatin)⁽⁸⁾. In addition to their effect as cholesterol-lowering⁽⁹⁾, reducing osteoclastic activity^(10,11), differentiation of osteoblasts^(12,13), and increase bone through bone morphogenetic protein (BMP) -2⁽¹⁴⁻²⁰⁾.

Implant stability assessment is an important way of assessing the efficiency of an implant⁽²¹⁾. Accordingly, this study evaluated implant stability in partially edentulous patients by examining the effect of systemic simvastatin administration on the bone regeneration around the dental implant.

MATERIAL AND METHODS

Study population

Eighteen patients were involved in the present study, their age ranged from 30-50 years old. They were all suffering from missing one or more teeth. They were selected from outpatient clinics of Oral Medicine, Periodontology, Oral Diagnosis and Radiology department, Faculty of Dental Medicine

for Girls, Al-Azhar University. The study protocol was approved by the Research Ethics Committee (REC18-060). The persons were informed about the treatment process, and all of them signed consent forms voluntarily.

Patients Grouping

The selected patients were divided into two equal groups based on simvastatin therapy (Control & test groups). The test group patients were under a systemic simvastatin therapy regimen as an anti-cholesterol drug. **Group I (Control group):** 9 healthy patients were undergoing one stage titanium screw-type endosseous dental implant to restore a missed tooth. **Group II (Test group):** 9 patients on simvastatin therapy (20 mg daily) as a prophylaxis drug, underwent the same type of one stage titanium screw type of endosseous dental implant to restore a missed tooth.

Preoperative assessment:

Clinical assessment

All patients underwent visual examination and palpation of the entire oral mucosa and obtained full mouth scaling and root debridement followed by proper oral hygiene instruction. Patients were free of any systemic disease. The type of bone at the implant site should be D2 or D3.

Surgical procedure

- Surgical steps were done under strict aseptic environments. Following local anesthesia of the surgical area, (mepivacaine with epinephrine 1:100.000), Each surgical site received one implant. Site preparation of osteotomy by sequential drilling, the surgical arrangement followed the protocol labeled by the implant company surgical kit, with reduced low speed (1500 rpm) under irrigation with saline standard. All implants were placed at the alveolar crest level using an insertion force of 35 Ncm. Drilling direction must be parallel to the adjacent teeth, parallelism can be checked by using the parallel pin of the implant company.

- After a proper osteotomy site was prepared, the implant was removed from its sterile vial then held using its fixture adapter, Inserted into the prepared site, and screwed manually with apical pressure until there is resistance.
- Using an Ostell Guidance system (Osstell device from (Osstell AB, Goteborg, Sweden) to record the primary stability (PS) resonance Frequency Analysis (RFA) was achieved. The implant stability proportion values (ISQ) were recorded and the primary stability was assessed by inserting a Smart Peg# into the implant attached to the implant and keeping the transducer near and perpendicular to the Smart Peg without touch. A gingival former was placed for all implants using hand torque
- The mucoperiosteal flaps were modified around the implant neck to allow non-submerged healing and were stitched with silk sutures using interrupted sutures using non-resorbable sutures (3/0 black silk). Suture removal was done 14 days postoperatively.
- A post-operative digital periapical radiograph was taken to check the proper implant position and its relation to opposing landmarks and adjacent structures.
- Six months after surgery, the healing cap was removed then assessed the secondary stability using Ostell similar to primary stability, then placement the abutment supplied by the implant system company. After that proper adjustment of the abutment and direct impression was made for fixed appliance construction by heavy and light rubber base impression material.

The following clinical parameters were evaluated in this study: Modified Plaque Index (MPI), Modified Gingival Index (MGI) and Probing Depth (PD) at the time of placement, 3 and 6 months intervals. A periodontal probe was used for clinical measurements. Implant stability tested after surgery by Ostell at 6 months.

Statistical analysis:

Using SPSS version 18, data organisation and statistical analysis were achieved. The independent t-test was used for comparisons between the two groups classes. The paired t-test was used to compare stability from baseline to 6 months. All p-values are two-sided. P-values ≤ 0.05 were considered significant.

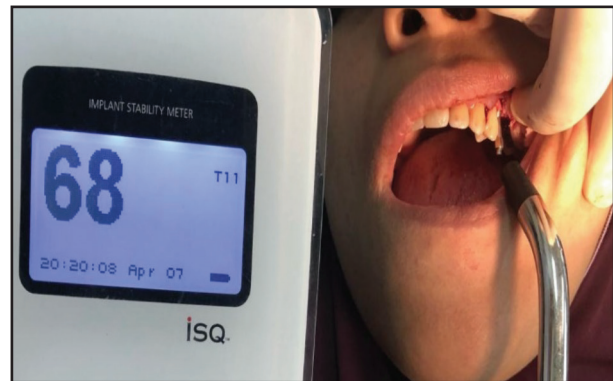


Figure (1) Ostell showing secondary stability reading

RESULTS

Modified Gingival Index (MGI): (Table 1) described the changes in the mean MGI in both groups. Both groups recorded a mean of 0 ± 0 at baseline, the mean value gradually increased by time after 3 and 6 months. A non-significant difference in the gingival index was observed on comparing results of 3 and 6 months postoperatively ($p=0.530$ at 3 months, $p=0.107$ at 6 months).

Modified Plaque Index (MPI): Both groups recorded a mean of 0 ± 0 at baseline. Group I showed a mean of 0.43 ± 0.53 at 3 months then mean value gradually increased by time after 6 months to reach 0.57 ± 0.53 . In Group II, the mean value of MPI gradually decreases by time from 3 (0.57 ± 0.53) to 6 ($.29 \pm 0.49$). A non-significant statistical difference in MPI was detected on comparing results of 3 and 6 months postoperatively ($p=0.606$ at 3 Ms, $p=0.122$ at 6 Ms).

Probing Depth (PD): Both groups recorded a mean of 0 ± 0 at baseline. Group I showed a mean of

PD 0.57 ± 0.53 at 3 months, while Group II showed 0.71 ± 0.49 . Then mean value gradually increased by time after 6 months to reach 0.86 ± 0.38 in both groups. A non-significant difference in probing depth was detected on comparing results of 3 and 6 months postoperatively ($p=0.591$ at 3 Ms, $p=1$ at 6 Ms).

Implant Stability: Group II recorded a higher mean value (67.57 ± 5.83) at baseline, (79.14 ± 4.38) and after 6 months compared to Group I which recorded (62.14 ± 13.67) at baseline, (72.86 ± 11.41) after 6 months. The results of mean revealed the difference between groups was not statistically significant ($p=0.362$). However, Group II recorded a higher mean value of difference by time (11.57 ± 3.2) compared to Group I (10.71 ± 5.9).

Table (1) Comparison of MGI, MPI, PD, and Stability between the two groups throughout the study.

	Group I	Group II	p
	Mean \pm SD	Mean \pm SD	
MGI			
Baseline	0.00 ± 0.00	0.00 ± 0.00	1.000
After 3Ms	0.29 ± 0.49	0.14 ± 0.38	0.530
After 6Ms	0.57 ± 0.53	0.14 ± 0.38	0.107
Difference From baseline to 6 Ms	0.57 ± 0.53	0.14 ± 0.38	0.107
MPI			
Baseline	0.00 ± 0.00	0.00 ± 0.00	1.000
After 3 Ms	0.43 ± 0.53	0.57 ± 0.53	0.606
After 6 Ms	0.53 ± 0.49	0.29 ± 0.49	0.122
Change From baseline to 6 Ms	0.53 ± 0.49	0.29 ± 0.49	0.122
PD			
Baseline	0.00 ± 0.00	0.00 ± 0.00	1.000
After 3 Ms	0.57 ± 0.53	0.71 ± 0.49	0.591
After 6 Ms	0.86 ± 0.38	0.86 ± 0.38	1.000
Difference From baseline to 6 Ms	0.86 ± 0.38	0.86 ± 0.38	1.000
Stability			
Baseline	62.14 ± 13.67	67.57 ± 5.83	0.362
After 6Ms	72.86 ± 11.41	79.14 ± 4.38	0.212
Change From baseline to 6 Ms	10.71 ± 5.9	11.57 ± 3.2	0.729

p: p-value for comparison between the two groups

DISCUSSION

In effective osseointegration, which has been recognized as a direct structural and functional link between the bone and the surface of a load-bearing implant, implant stability plays a significant role. Two major factors for the effectiveness of the implant are the initial stability during insertion (primary stability) and the progression of osseointegration in the subsequent healing process (secondary stability).⁽²²⁾

To enhance the bone response around the implant, one group of substances has been used: growth factors⁽²³⁾, morphogenetic proteins⁽²⁴⁾ and, more recently, hormones such as growth hormone, melatonin⁽²⁵⁾, and statins⁽²⁶⁾. So the present research was therefore conducted to assess the efficiency of drug administration with simvastatin on dental implant stability and osteointegration. This was performed by the assessing clinical parameters and calculating bone density radiographically.

In the present study, simvastatin was used for its anti-inflammatory and osteopromotor effects. The researchers found that by increasing osteoblast differentiation and promoting neovascularization through its effect on bone morphogenetic proteins and endothelial growth factors, simvastatin can speed up bone regeneration and soft tissue healing (19, 27). By inhibiting tissue-damaging enzymes including matrix metalloproteinase (MMPs), statins may also demonstrate anti-inflammatory effects.⁽²⁸⁾

The lack of human histological research makes the healing processes of the bone around dental implants difficult to understand⁽²⁹⁻³¹⁾. One technique is to track the change in bone density based on the CT's HU or the DVT's gray scale. The risk of radiation over doses rises with daily patient exposure to CT, which is key reason for limiting the use of CT to monitor bone changes⁽³¹⁾. Hence, CBCT was used in this study for its multiple benefits.

Resonance frequency analysis (RFA) For measurement of implant stability, was concerned about using ostell. It can also be used to assess the effect of early and delayed loading, assess stability

over some time, and early diagnose implant failure⁽³²⁾. Ostell was the first commercially available product for measuring implant stability. Electronic technology combines the transducer, the computer-aided analysis, and the excitation source in one machine. The implant stability quotient (ISQ) is the unit of measure used (ISQ from 0 to 100). When used at the time of implant placement, the baseline is shown for future comparison and the postoperative position of the implant.⁽³³⁾

Evidence,⁽³⁴⁻³⁶⁾ indicates that advanced tests and equipment may perform a greater role in the evaluation of implant stability compared to conventional methods. An important diagnostic and therapeutic instrument is the ability to monitor osseointegration and implant life expectancy. They confirm that the Ostell device is non-invasive, reliable, and can be used for long term implant integration follow-up.

Probing is a suitable method to evaluate potential negative changes in the peri-implant environment and should be done every 3 to 6 months.⁽³⁷⁾ The results of the present study showed that the use of simvastatin in patients receiving dental implants provided a similar clinical improvement to the control group. The mean of PD readings was (0.86 ± 0.38) at six months in the simvastatin group compared to the control group (0.86 ± 0.38).

A non-significant difference of MPI and MGI between both groups after 3 and 6 months was reported. However, the mean of MGI readings was lower ($0.14 \pm 0.38, 0.14 \pm 0.38$) at three and six months in the simvastatin group compared to the control group ($0.29 \pm 0.49, 0.57 \pm 0.53$).

Simvastatin has been shown to prevent macrophages from oxidizing LDLs.⁽³⁸⁾ Several studies have shown that statins lower the level of C-reactive protein (CRP).⁽³⁹⁾ The addition of statins greatly reduced the production of interleukin -6 (IL-6) by these cells. The statin-mediated decrease in CRP levels has also been proposed to be due to IL-6 inhibition. Statin-inhibited production of nicotinamide adenine dinucleotide phosphate oxidase, which is a major source of oxidant production.⁽⁴⁰⁾ Statins, like SMV, are believed

to have biologically important antioxidant and anti-inflammatory effects based on these results, which could prove to be beneficial in the improvement of clinical parameters.

Assessment of implant stability is usually a significant indicator of implant health⁽⁴¹⁾. In the current study, there was a statistically significant increase in mean implant stability within each group. where group II showed a higher mean increase of 79.14 ± 4.38 than group I 72.86 ± 11.41 at 6 months with a nonsignificant difference.

This improvement in implant stability in the group received simvastatin may be attributed to the osteogenic activity of simvastatin regarding bone metabolism revealed by several studies. SMV has been reported to encourage osteoblastic activity and inhibit osteoclastic activity. The transient exposure of the bone to statins was sufficient to induce a force of bone formation, which was likely induced by the local production of the bone morphogenic protein-2 (BMP-2). The BMP-2 promoter was used as a target to identify new compounds that stimulate its transcription and subsequent differentiation of the osteoblasts. SMV has been shown to reverse the suppressive effects of TNF and prevent the inhibition of BMP-2.⁽⁴²⁾

Results of the present study were consistent with a previous study⁽⁴²⁾ that showed that statins had a positive effect on growing osteogenesis around implants. The increased expression of BMP-2 and the resulting increased stimulation of osteoblasts have explained this. Besides, a drop in osteoclast activity may be detected in the decrease in the blood serum by a decrease in the histochemical marker⁽⁴³⁾. anti-inflammatory, antioxidant, antithrombotic, immunomodulatory, and angiogenic are other pleiotropic properties of statins⁽⁴⁴⁾.

A randomized clinical study showed that⁽⁴⁵⁾ the administration of simvastatin reduced the required functional loading time from 3-6 months (12-26 weeks) to almost 2 months (8 weeks) in the traumatic functional implant zone of dental implants. By enhancing dental implant osseointegration and increasing its stability faster than in the control group.

CONCLUSION

The patient who received simvastatin showed similar clinical changes during the healing time around the dental implant as a healthy one. The use of Ostell was a non-invasive and reliable tool to measure implant stability. Simvastatin might improve implant stability in partially edentulous patients.

CONFLICT OF INTEREST

None declared.

FUNDING

No funding was received for this study.

REFERENCES

- Alghamdi HS. Methods to Improve the Osseointegration of Dental Implants in Low Quality (Type-IV) Bone. *J Funct Biomater*. 2018;13:6-7.
- T Suer BT, Yaman Z, Buyuksarac B. Correlation of Fractal Dimension Values with Implant Insertion Torque and Resonance Frequency Values at Implant Recipient Sites. *Int J Oral Maxillofac Implants*. 2016;31:55-62.
- Albrektsson TO, Johansson CB, Sennerby L. Biological aspects of implant dentistry: osseointegration. *Periodontol* 2000. 1994;4:58-73.
- Adell R, Lekholm U, Rockler B, Brånemark PI. A 15-year study of osseointegrated implants in the treatment of the edentulous jaw. *Int J Oral Surg*. 1981;10:387-416.
- Walton TR. An Up-to-15-Year Comparison of the Survival and Complication Burden of Three-Unit Tooth-Supported Fixed Dental Prostheses and Implant-Supported Single Crowns. *Int J Oral Maxillofac Implants*. 2015;30:851-61.
- Gadi R, Figueredo VM. Low-density lipoprotein cholesterol-lowering therapies: what is on the horizon? *J Cardiovasc Med (Hagerstown)*. 2015;16:1-10.
- Goldstein JL, Brown MS. Regulation of the mevalonate pathway. *Nature*. 1990;343:425-30.
- Yandrapalli S, Malik A, Guber K, Rochlani Y, Pemmasani G, Jasti M, Aronow WS. Statins and the potential for higher diabetes mellitus risk. *Expert Rev Clin Pharmacol*. 2019;12:825-30.
- Gomasrashi M, Adorni MP, Banach M, Bernini F, Franceschini G, Calabresi L. Effects of established hypolipidemic drugs on HDL concentration, subclass distribution, and function. *High-Density Lipoproteins*. 2015: 593-615.
- Montazerolghaem M, Rasmusson A, Melhus H, Engqvist H, Karlsson Ott M. Simvastatin-doped pre-mixed calcium phosphate cement inhibits osteoclast differentiation and resorption. *J Mater Sci Mater Med*. 2016;27:83.
- Xu R, Shi G, Xu L, Gu Q, Fu Y, Zhang P, et al. Simvastatin improves oral implant osseointegration via enhanced autophagy and osteogenesis of BMSCs and inhibited osteoclast activity. *J Tissue Eng Regen Med*. 2018;12:1209-19.
- López-Álvarez M, López-Puente V, Rodríguez-Valencia C, Angelomé PC, Liz-Marzán LM, Serra J, et al. Osteogenic effects of simvastatin-loaded mesoporous titania thin films. *Biomed Mater*. 2018; 2:13-025017.
- Y Fang W, Zhao S, He F, Liu L, Yang G. Influence of simvastatin-loaded implants on osseointegration in an ovariectomized animal model. *Biomed Res Int*. 2015;2015:831504.
- Yueyi C, Xiaoguang H, Jingying W, Quansheng S, Jie T, Xin F, et al. Calvarial defect healing by recruitment of autogenous osteogenic stem cells using locally applied simvastatin. *Biomaterials*. 2013;34:9373-80.
- Dolkart O, Amar E, Shapira S, Marmor S, Steinberg EL, Weinbroum AA. Protective effects of rosuvastatin in a rat model of lung contusion: Stimulation of the cyclooxygenase 2-prostaglandin E-2 pathway. *Surgery*. 2015;157:944-53.
- Tanaka T, Matsushita T, Nishida K, Takayama K, Nagai K, Araki D, et al. Attenuation of osteoarthritis progression in mice following intra-articular administration of simvastatin-conjugated gelatin hydrogel. *J Tissue Eng Regen Med*. 2019;13:423-32.
- An T, Hao J, Sun S, Li R, Yang M, Cheng G, Zou M. Efficacy of statins for osteoporosis: a systematic review and meta-analysis. *Osteoporos Int*. 2017;28:47-57.
- Chalisserry EP, Nam SY, Anil S. Simvastatin Loaded Nano Hydroxyapatite in Bone Regeneration: A Study in the Rabbit Femoral Condyle. *Curr Drug Deliv*. 2019;16: 530-7.
- Alam S, Ueki K, Nakagawa K, Marukawa K, Hashiba Y, Yamamoto E, et al. Statin-induced bone morphogenetic protein (BMP) 2 expression during bone regeneration: an immunohistochemical study. *Oral Surg Oral Med Oral Pathol Oral Radiol Endod*. 2009 ;107:22-9.
- Jang YO, Kim SH, Cho MY, Kim KS, Park KS, Cha SK, et al. Synergistic effects of simvastatin and bone marrow-derived mesenchymal stem cells on hepatic fibrosis. *Biochem Biophys Res Commun*. 2018; 26: 497:264-71.
- Faot F, Marcello-Machado RM, Hermann C, Fontão FNGK. Splinted wide-short implants in the posterior region of an atrophic mandible opposed by an edentulous maxilla: immediate loading and 1-year follow-up. *Gen Dent*. 2019;67:29-33.

22. Friberg B, Sennerby L, Linden B, Gröndahl K, Lekholm U. Stability measurements of one-stage Brånemark implants during healing in mandibles. A clinical resonance frequency analysis study. *Int J Oral Maxillofac Surg*. 1999;28:266-72.
23. Ortolani E, Guerriero M, Coli A, Di Giannuario A, Minniti G, Polimeni A. Effect of PDGF, IGF-1, and PRP on the implant osseointegration. A histological and immunohistochemical study in rabbits. *Ann Stomatol (Roma)*. 2014;18;5:66-8.
24. Azimi M, Khodabandeh M, Deezagi A, Rahimi F. Impact of the Transfersome Delivered Human Growth Hormone on the Dermal Fibroblast Cells. *Curr Pharm Biotechnol*. 2019;20: 1194-202.
25. Hossam Eldein AM, Elghamrawy SH, Osman SM, Elhak AR. Histological evaluation of the effect of using growth hormone around immediate dental implants in fresh extraction sockets: an experimental study. *Implant Dent*. 2011;20:47-55.
26. Akram Z, Vohra F, Javed F. Efficacy of statin delivery as an adjunct to scaling and root planing in the treatment of chronic periodontitis: A meta-analysis. *J Investig Clin Dent*. 2018;9:e12304.
27. Maeda T, Kawane T, Horiuchi N. Statins augment vascular endothelial growth factor expression in osteoblastic cells via inhibition of protein prenylation. *Endocrinology*. 2003;144:681-92.
28. Gilbert R, Al-Janabi A, Tomkins-Netzer O, Lightman S. Statins as anti-inflammatory agents: A potential therapeutic role in sight-threatening non-infectious uveitis. *Porto Biomed J*. 2017;2: 33-9.
29. Barone A, Ricci M, Calvo-Guirado JL, Covani U. Bone remodeling after regenerative procedures around implants placed in fresh extraction sockets: an experimental study in Beagle dogs. *Clin Oral Implants Res*. 2011;22: 1131-7.
30. Santo VE, Gomes ME, Mano JF, Reis RL. Controlled release strategies for bone, cartilage, and osteochondral engineering--Part I: recapitulation of native tissue healing and variables for the design of delivery systems. *Tissue Eng Part B Rev*. 2013 ;19:308-26.
31. Hasan I, Dominiak M, Blaszczyzyn A, Bourauel C, Gedrange T, Heinemann F. Radiographic evaluation of bone density around immediately loaded implants. *Ann Anat*. 2015;199:52-7.
32. Swami V, Vijayaraghavan V, Swami V. Current trends to measure implant stability. *J Indian Prosthodont Soc*. 2016 ;16:124-30.
33. Valderrama P, Oates TW, Jones AA, Simpson J, Schoolfield JD, Cochran DL. Evaluation of two different resonance frequency devices to detect implant stability: a clinical trial. *J Periodontol*. 2007;78:262-72.
34. Vayron R, Nguyen VH, Lecuelle B, Haiat G. Evaluation of dental implant stability in bone phantoms: Comparison between a quantitative ultrasound technique and resonance frequency analysis. *Clin Implant Dent Relat Res*. 2018;20: 470-8.
35. Herrero-Climent M, Santos-García R, Jaramillo-Santos R, Romero-Ruiz MM, Fernández-Palacin A, et al. Assessment of Osstell ISQ's reliability for implant stability measurement: a cross-sectional clinical study. *Med Oral Patol Oral Cir Bucal*. 2013;18:877-82.
36. Nakashima D, Ishii K, Matsumoto M, Nakamura M, Nagura T. A study on the use of the Osstell apparatus to evaluate pedicle screw stability: An in-vitro study using micro-CT. *PLoS One*. 2018;13:0199362.
37. Gulati M, Govila V, Anand V, Anand BJSrn. Implant maintenance: A clinical update. 2014; 10: 593-616.
38. Zhang GQ, Tao YK, Bai YP, Yan ST, Zhao SP. Inhibitory Effects of Simvastatin on Oxidized Low-Density Lipoprotein-Induced Endoplasmic Reticulum Stress and Apoptosis in Vascular Endothelial Cells. *Chin Med J (Engl)*. 2018;131: 950-5.
39. Davignon J, Laaksonen R. Low-density lipoprotein-independent effects of statins. *Curr Opin Lipidol*. 1999;10:543-59.
40. Jeon SM, Bok SH, Jang MK, Lee MK, Nam KT, Park YB, et al. Antioxidative activity of naringin and lovastatin in high cholesterol-fed rabbits. *Life Sci*. 2001;69:2855-66.
41. Boora P, Rathee M, Bhorla M. Effect of Platelet Rich Fibrin (PRF) on Peri-implant Soft Tissue and Crestal Bone in One-Stage Implant Placement: A Randomized Controlled Trial. *J Clin Diagn Res*. 2015 ;9:ZC18-21.
42. Croes M, Kruyt MC, Boot W, Poursan B, Braham MV, Pakpahan SA, et al. The role of bacterial stimuli in inflammation-driven bone formation. *Eur Cell Mater*. 2019; 16;37: 402-19.
43. Jin J, Zhang X, Lu Z, Li Y, Lopes-Virella MF, Yu H, et al. Simvastatin inhibits lipopolysaccharide-induced osteoclastogenesis and reduces alveolar bone loss in experimental periodontal disease. *J Periodontol Res*. 2014;49:518-26.
44. Brittain SB, Gohil SV, Nair LS. Statins as bioactive molecules to support bone regeneration. *Curr Med Chem*. 2014;21:2980-8.
45. Mohammed AH, Al Kayat AJIDJ. Effect of Systemic Administration of Simvastatin on Dental Implant Stability: A Random Clinical Study. 2016; 38: 119-23.