



Three-dimensional Measuring of Zygomaticomaxillary Complex Symmetry after Fixation of Unilateral Zygomaticomaxillary Complex Fracture

Mahetab M. Montaser^{1*}, Fatma A. Khalifa², Fatma I. Mohamed³, Wael M. Shawkat⁴.

Codex : 14/22.01

azhardentj@azhar.edu.eg

http://adjg.journals.ekb.eg

DOI: 10.21608/adjg.2021.64304.1342

Oral Medicine & Surgical Sciences
(Oral Medicine, Oral & Maxillofacial
Surgery, Oral Pathology, Oral Biology)

ABSTRACT

Purpose: to evaluate the symmetry of the reduced unilateral zygomaticomaxillary complex (ZMC) fractures fixed with computer designed custom machined titanium miniplate and conventional titanium miniplate, using three dimensional computed tomography (3D-CT) analysis of ZMC position. **Patients and Methods:** Ten patients who suffered from unilateral ZMC fractured were involved in this study. The patients were randomly and equally divided into two groups. In group A, the ZMC fractures were reduced and fixed with computer designed custom machined titanium miniplates, whereas in group B, they were fixed by conventional 2.0mm titanium miniplates. Computed Tomography (CT) scan was performed for each patient pre and postoperatively, then imported as a Digital imaging communication in medicine (DICOM) to MIMICS software to make Standard tessellation language (STL) file for quantitative measurements, preoperative surgical planning was performed to group A for designing of custom made plates by mirror imaging of the unaffected side, segmentation and virtual reduction using PlastyCAD software, then fabrication of the final design of the plate by Computer numerically controlled (CNC) milling machines. **Results:** Clinical symmetry was achieved in all cases except two in group B. By radiographic analysis, there was a significant difference between the two groups. Group A showed smaller deviation from the unaffected side, indicating more adequate reduction in group A than group B. **Conclusion:** Custom made plate revealed adequate accuracy in restoring ZMC symmetry than conventional miniplates. The 3-D quantitative assessment used in this study successfully reflected symmetry levels

KEYWORDS

Zygomaticomaxillary complex
(ZMC) fracture, Custom made
plates, ZMC symmetry.

* Paper extracted from Master Thesis titled “Three-dimensional Measuring of Zygomaticomaxillary Complex Symmetry after Fixation of Unilateral Zygomaticomaxillary Complex Fracture”

1. MSc student, Department of Oral and Maxillofacial Surgery, Faculty of Dental Medicine for Girls, Al-Azhar University, Cairo, Egypt.
2. Assistant Professor of Oral and Maxillofacial Surgery Department, Faculty of Dental Medicine for Girls, Al-Azhar University, Cairo, Egypt.
3. Professor of Oral and Maxillofacial Surgery Department, Faculty of Dental Medicine for Girls, Al-Azhar University and Faculty of Dentistry, Deraya University, Almenya, Egypt.
4. Consultant and Head of department, Nasr City for Health Insurance Hospital, Cairo, Egypt.

* Corresponding author email: mahetabmontaser@yahoo.com

INTRODUCTION

Zygomaticomaxillary complex (ZMC) is the principal buttress between the cranium and the maxilla. ZMC strongly play an important role in the width and protrusion of the midface, which is considered the main and reliable structure for maintaining the facial form, function, and esthetics⁽¹⁾. Because of its prominent position, zygomatic fractures occur frequently in the midface. ZMC fractures which has no or minimal displacement can be treated in conservative way. For dislocated fractures; open reduction with internal fixation (ORIF) is indicated. In addition, the complicated and comminuted ZMC fractures are difficult to be treated, because of absence of anatomical landmarks that can facilitate bone reduction. Therefore, maxillofacial surgeons reduced the displaced segments in according to their previous clinical experience skills, which may result in unsatisfactory outcomes. Failure of anatomical reduction will affect the width and protrusion of the zygoma, as well as symmetry of the midface, leading to poor self-respect and psychological problems. Therefore, the most important factor that aim in the accuracy of treatment of the complicated ZMC fracture is the bone reduction and alignment^(2,3).

To re-establish zygomatic projection, facial symmetry, and correct orbital volume, the most of the displaced ZMC fractures require fixation with titanium miniplates. Recently, the custom made plates can be fabricated in any shapes design with great similarity. The specific custom plate configurations include the 3D, thickness, and width. While the holes of the screws were designed to give better clinical outcomes⁽⁴⁾.

Quantitative assessment of ZMC symmetry has great importance in the fields of maxillofacial trauma and reconstructive esthetic surgery, because of its importance in surgical planning and evaluation. However, there is no known way for the ZMC symmetry measurements and evaluation⁽⁵⁾. Direct clinical measurements of the patients are difficult

and time consuming techniques. Also, this approach is examiners dependent⁽⁶⁾.

Recently, three dimensional (3D) imaging based measurement techniques by using the ZMC landmarks can provide more detailed information about the ZMC symmetry and their surgical outcomes. Various techniques have been reported for 3D view superimposition, which extracted from either conventional CT or cone beam computed tomography (CBCT) images. These include superimposition of these landmarks. The accuracy of landmark identification is responsible for The reliability of these techniques⁽⁷⁾. Because of the ZMC structure shape, traditional radiographic ways for the evaluation of ZMC symmetry are subjected to distortion. On contrary, 3D computed tomography (3D-CT) techniques provide accurate measurements and provides accurate reads of different anatomical structures. Moreover, the 3D-CT technique avoids the distortion caused by improper head position. Thus, the accurate quantification of ZMC symmetry can be done with 3D-CT^(8,9).

Although there are a few articles studying the use of the custom made plates, they are mostly head and neck reconstruction studies and the exact success rate of applying those plates in the fixation of ZMC fractures is still unknown. Therefore, this prospective study was conducted to evaluate the use of custom-made plates in the fixation of ZMC fracture. Moreover, the accuracy of using custom made plates and conventional miniplates was quantitatively assessed by 3D measuring the facial symmetry, using 3D-CT.

PATIENTS AND METHODS

Study design and population

To address the research purpose, a prospective comparative study was designed and done on patients who suffered from unilateral ZMC fracture. They were selected from the out patient's clinic of the Department of Oral and Maxillofacial Surgery,

Faculty of Dental Medicine for Girls, Al-Azhar University, Alzahraa University Hospital, and Nasr City for Health Insurance Hospital, from May 2018 to September 2019. The patients were randomly and equally divided into two groups. In group A, the ZMC fractures were reduced and fixed with computer designed custom machined titanium miniplates, whereas in group B, they were fixed with conventional 2.0 mm titanium miniplates. The patients who fulfilled the following inclusion criteria were included in the study: (1) patients who had a unilateral ZMC fracture that was indicated for open reduction and internal rigid fixation (ORIF), (2) non-growing adult patients with no sex predilection, (3) lack of maxillofacial deformities on the contralateral side to be used as a control, (4) patients have to attend regular follow-up visits, (5) the time interval between the trauma and surgical intervention was less than four weeks, and (6) complete clinical and radiographic records were available⁽¹⁰⁾. Patients were excluded if they had one of the following conditions: (1) Patients with bilateral ZMC fractures, (2) patients who had a history of previous trauma, orthognathic surgery or congenital anomalies of the zygomaticomaxillary-orbital complex, which influence the normal symmetry of the ZMC, (3) a preoperative infection at the fracture sites, and (4) medical conditions that could interfere with the healing process such as: nutritional deficiency, uncontrolled diabetes, chemotherapy, radiotherapy⁽¹¹⁾. In accordance with the Declaration of Helsinki, all patients were informed about the research and written informed consent was obtained. The local ethics review committee of the Faculty of Dental Medicine for Girls at Al-Azhar University approved the study.

Surgical protocol

Pre-surgical preparation

Complete assessment was performed for every patient including laboratory investigation, trauma and medical history, chief complain, intra- and extraoral examination and ophthalmic examination.

Frontal, top, and worm photographic views were also performed to all patients to assess ZMC symmetry and eye position.

Radiographic assessment of ZMC symmetry

A preoperative multi-slice CT scan (coronal, axial, 3D) was requested for detection of the type of fracture and any associated injuries. The scan data were imported as Digital Imaging and Communications in Medicine (DICOM) standard files, which were loaded into Materialise Interactive Medical Image Control System (Mimics), for 3D reconstruction, virtual planning and linear measurements. To evaluate the preoperative ZMC symmetry, one investigator manually identified ZMC radiographic points, skeletal landmarks and a constructed 3D coordinate system (X, Y, Z axes) on a 3D skull image, by using Mimics software as follow:

- a. On the 3-D view, four pairs of ZMC radiographic points were identified on both affected and non-affected sides. The 3D multi-planar view was used to confirm the correct placement of the radiographic points.
- b. This was followed by placement of the skeletal landmarks for reconstruction of the coordinate system.
- c. Finally, the distances between the four ZMC radiographic points on both sides and the constructed coordinate system were measured automatically, resulting in 12 pairs of distances. All measurements were taken twice by the same investigator and the mean value for each landmark was calculated and for analysis and to compare between the affected and the normal sides.

The Descriptions of the landmarks and coordinate system are listed below: Fig. 1.

1. The ZMC radiographic points:

- a. MZ (maxillozygon): is the most prominent point on the zygomatico-maxillary suture, below the lateral third of the orbit.

- b. FZS (frontozygomatic suture): is the most anterior point of the frontozygomatic suture on the lateral orbital rim.
- c. Orbitale (O): is the most inferior point on the infra-orbital rim.
- d. Z (zygon): is the most lateral point of zygomatic arch.

2. Skeletal landmarks to reconstruct the 3D coordinate system:

- a. Nasion (N): is the most anterior point of the nasofrontal suture on the mid-sagittal plane.
- b. Subspinale (A): is the most posterior point of the maxillary alveolar process on the mid-sagittal plane.
- c. Basion (B): is the most anterior and inferior point on the sagittal midline of foramen magnum.

3. The 3D coordinate system:

The common origin of the three axes was N to compensate for the patient's head position

- a. The y-axis (the median sagittal plane): is the plane passing through the nasion and subspinale.
- b. The z-axis (coronal plane): The z axis included N and was perpendicular to the x and y axes.
- c. The x-axis (axial plane): is a plane perpendicular to the y- and z-axes at the nasion^(12,13).

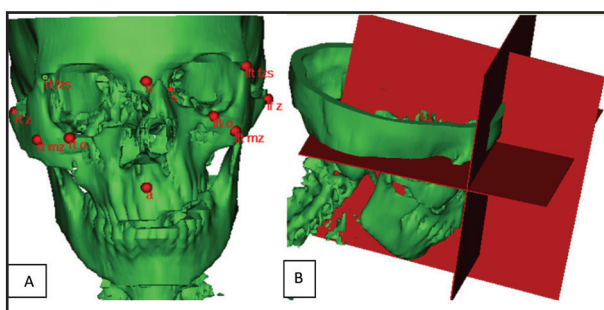


Figure (1) A preoperative 3D view on MIMICS software showing (A) the ZMC radiographic landmarks (Z, O, MZ, FZS) on the affected (right) and non-affected (left) sides, and (B) the 3D coordinate system

Computer-aided virtual planning and, design, and fabrication of custom machined titanium miniplates:

For each patient in group (A), Standard Tessellation Language (STL) file was exported from the multi-slice CT using InVesalius software. From each STL image, manual segmentation and cropping of the affected side was performed first by the use of the cutting tool, which provided in the software. Different colours were used to differentiate between mirror images and affected images. Segmental mirroring of the unaffected side was done to obtain a virtual 3D template which was duplicated, trimmed and adjusted manually until the mirrored portion fitted well with the affected side, to virtually restore the facial symmetry. By using the logical operations “union”, the mirrored unaffected and affected sides were grouped and exported in stereolithographic format, and then exported to PlastyCAD software for designing the custom made plates in group A. The custom made plates were designed on the virtually restored ZMC, with a 1 mm-thickness. The plates were designed to accurately rely on intact bones of the ZMC structures, to provide adequate stability. The design was done by cutting through block of titanium using 3D data through a CNC milling machines, using CAD/CAM⁽¹⁴⁾. The custom made plate thickness was 1 mm. Holes of 3.0 mm in diameter with 2.0-.3.0 mm spaces were used. The plates were sterilized before operation.

Surgical procedures

All the surgical procedures were performed under general anesthesia. To control hemostasis, Mepevacaine HCL 2% with 1: 20000 levonordefrin was injected at the incision lines. A forced duction test was performed at the beginning of the operation. A tarsorrhaphy was performed with 4-0 black silk, to help in lid retraction, ocular protection, and act as a Frost suture at the end of surgery. The choice of the surgical approach was governed by the fractures' extension and the surgeons' preferences, and included subciliary, subtarsal, infraorbital,

lateral eye brow, vestibular incisions, and pre-existing laceration. According to Ellis and Zide⁽¹⁵⁾, all surgical approaches were performed following the same steps. After exposure of all fracture lines, the displaced ZMC fracture was disimpacted with a Rowe zygomatic elevator, and then the displaced bones were reduced into their anatomical place.

In group A, the custom made plates were attached first to the uninjured part of the zygomatic bone. This helped the fractured segments to be easily reduced to the preoperative planned position, under the guidance of the plates. The screws used for the fixation of the custom plates, were conventional mini-screws. In group B reduction and fixation of the fractured segments was mainly based on the surgeon's clinical experience. Conventional titanium 1.0mm plate profile miniplates were used in fixation of all fracture lines in this group.

In both groups, the fixation sequence consisted of plate placement at the infraorbital rim. The second plate was inserted at the ZF suture. Finally, the third plate was applied at the ZMB. All plates were initially fixed in the correct position with screws on the two sides of the fracture segment. Complete fixation by the remaining screws was performed after checking the accuracy of the fractures reduction and all plates' position. In case of zygomatic arch fracture, it was reduced separately by zygomatic hook or via intraoral approach. And then, the arch contour was assessed by palpation. No plates were placed over the arch, because the stability of the zygoma has been maintained by the three points of fixation. After fixation of the ZMC fracture, the orbital floor was explored for releasing entrapped muscle and repairing bony defect if necessary, finally the forced-reduction test was done to check ocular movement. All incisions were sutured in the usual manner.

Frost suture was applied in all cases, using black silk 4/0, for suspension of the lower eyelid to the forehead by adhesives and was left for two days. Postoperative analgesics and antibiotic were prescribed for all patients.

Postoperative clinical and radiographic evaluation:

All patients were followed up for three months. Clinical examination was carried out immediately after surgery, on the 3rd and 7th day, then monthly till the end of the three months, and further on indication. Clinical examination was performed in cooperation with an ophthalmologist to evaluate the visual acuity (eye chart projector), binocular visual field screening (Bagolini striated glasses test)⁽¹⁶⁾, pupillary reactivity, anterior and posterior segment examination, extraocular motility, presence or absence of diplopia (cover test, Hess screen test), eye-lid examination (laceration, entropion, scleral show, and ectropion), medial and lateral dystopia, fundus examination, globe position (enophthalmos, exophthalmos, hypophthalmos), presence of corneal lesions.

On every follow up visit, the patients were assessed for the sensory functions of ION, eye movements, symmetry of the zygomatic bones, plate exposure, wound infection and dehiscence, pain, swelling, globe position, lower eye lid complications, MIO, and esthetic appearance of the scars. All patients were asked if they were satisfied or not with the final result. Photographs including frontal, top, and worm's views were taken for every patient immediately postoperative, 1, and 3, months postoperatively.

CT scan with the same preoperative parameters was requested on the second postoperative day for the evaluation of proper reduction of the fracture sites, accuracy of plate placement and 3D restoration of facial symmetry. The same preoperative measurements were carried out on Mimics software. To evaluate the amount of surgical changes, the postoperative difference between the affected and normal side was calculated, the smaller the deviation from the unaffected side measurements, the higher is the achieved ZMC symmetry. The amount of change of all radiographic measurements was compared among two groups.

Chromatography

Superimposition of the postoperative CT of group A and the preoperative virtually plan CT was performed on 3D-CT view on PLASTYCAD software to calculate the difference in reduction accuracy. The deviation was calculated as it is the difference between the final result and the preoperative planned design and it was illustrated with a color map to calculate the deviation area.

Statistical analysis

The collected data were recorded, tabulated, and analyzed statistically. Statistical analysis was performed with IBM SPSS Statistics for Windows, Version 23.0. Armonk, NY: IBM Corp. Numerical data were explored for normality by checking the distribution of data and using tests of normality (Kolmogorov-Smirnov and Shapiro-Wilk tests). Parametric data were presented as mean and standard deviation (SD) values, while non-parametric data were expressed as number and percentage of the total. Student's t-test was used to compare between the demographic and clinical data of the two groups. Repeated measures Analysis of Variance (ANOVA) was used to compare between affected and unaffected sides. Bonferroni's post-hoc test was used for pair-wise comparisons when ANOVA test is significant. The significance level was set at $P \leq 0.05$.

RESULTS

A total of ten patients (9 males and 1 female) with unilateral displaced ZMC fracture were included in this study. The mean age of the patients was 33.8 ± 12 years (range 17-50 years) at the time of surgery. Five patients underwent ORIF by custom made plates (group A) and five patients underwent ORIF by conventional titanium miniplates (groupB). The most frequent cause of trauma was MVA in six patients (60 %), followed by IPV in two cases (20%), falls in one patient (10%), and sports injury in one patient (10%). Five

cases had left ZMC fracture and five patients had right side fracture and two patients had zygomatic arch fracture. The time interval between the trauma and the primary surgical intervention ranged from 11 to 26 days (mean 23.1 ± 5). All patients recovered uneventfully after surgery. Regarding the affection of the ION, there was preoperative hypoesthesia in five cases, three of them showed mild improvement postoperatively, while the other two patients (group A) showed no improvement at the end of the follow up. All cases showed no affection of facial nerve pre- and postoperatively. Preoperative Anterior open bite (AOB) was only observed in two cases in group A that improved completely postoperatively. The demographic and clinical features of the study's patients are summarized in Table 1

Table (1) Demographic and clinical data of the patients

Study variables	Group A	Group B
Age (years)	Mean 33.8 ± 10.3	Mean 33.8 ± 14.5
Gender Male / Female	4/1	5/0
Etiology		
MVA	4	2
IPV	1	1
Sports	0	1
Fall	0	1
Time interval between trauma and operation (days)	20 ± 4	16 ± 4
ION Numbness		
Preoperative	3	2
postoperative	2	0
Anterior Open Bite (AOB)		
Preoperative	2	0
postoperative	0	0
MIO		
Preoperative	34.6 ± 8	39 ± 3
postoperative	38 ± 5	39 ± 3
Type of ZMC fracture		
III a	2	2
IV b	3	2
V	0	1

Study variables	Group A	Group B
Associated maxillofacial injuries		
Mandibular	1	0
Naso maxillary	1	3
Orbital floor	1	0
Anterior maxillary wall	1	0

Data presented as mean ±SD or numbers

All P-values were non-significant (P > 0.05)

Type III a: rotation around vertical axis internally,
 type IV b: rotation around horizontal axis laterally,
 type V: displacement of the complex en bloc

Clinical and ophthalmic evaluation

Preoperative ophthalmic examination revealed restriction of EOM in two patients of group A, one of them had restriction in all direction while the other one had restriction only in the upward gaze. Postoperatively the two patients showed complete

improvement. Binocular diplopia was observed in one patient in group A, which showed complete immediate improvement postoperatively. Hertel exophthalmometer was used to identify the presence of enophthalmos which was observed in eight patients. The degree of enophthalmos ranged from 3 to 5 mm. All patients showed complete improvement postoperatively, except three cases (one in group A and two cases in group B). Retinal detachment was observed in one case in group A, which showed no postoperative improvement. Ptosis of upper eye lid was present in four cases. All of them showed marked improvement postoperatively except one. Three patients suffered from upper eye lid laceration which revealed little improvement at the follow up end. Preoperative ecchymosis was observed in two cases that resolved completely postoperatively. Fat herniation was present in only one case that did not show any complete improvement postoperatively. Ophthalmic examination details are observed in Table 2.

Table (2) Pre-and postoperative ophthalmological examination

Ophthalmic assessment	Preoperative			Postoperative		
	Group A	Group B	P-value	Group A	Group B	P-value
Ocular restriction	2	0	0.444	0	0
Diplopia	1	0	0.3	0	0
Enophthalmos	3	5	0.444	1	2	0.2
Retinal detachment	1	0	0.3	1	0	0.3
Eye lid complication:						
Ptosis	3	1	0.524	3	1	0.524
Fat herniation	1	0	0.3	1	0	0.3
Upper eye lid laceration	1	2	0.2	1	2	0.2
Ecchymosis	0	2	0.444	0	0
Edema	5	5	1	0	0
Entropion	0	0	0	0	0
Ectropion	0	0	0	0	0

Data presented as numbers

All P value were non-significant (p>0.05)

Clinical symmetry was achieved in all cases except two in group B. One of them had preoperative zygomatic arch protrusion that remained unchanged postoperatively. This patient was unsatisfied with the results, but he refused to undergo any surgical interference. The other patient had preoperative laterally displaced zygoma, which showed little improvement postoperatively. However, the patient was satisfied with the final results. All remaining patients were satisfied with their facial symmetry Fig. 2. None of the patients developed scar hypertrophy of the surgical incisions. The only complaint was from patients who came with soft tissue laceration caused by trauma. During follow up period, no patient suffered from plate exposure except one case in group A, who had IOR plate exposure two weeks after surgery. The plate was removed under general anesthesia one month later.

Results of radiographic measurements

ZMC symmetry was evaluated on the pre- and postoperative 3D-CT imaging. The distance between the radiographic points (MZ, Z, O, FZS) and the three axes (X, Y, Z) were recorded and analysed. In every group, the radiographic measurements of the affected and unaffected sides were compared together. In the two groups, the preoperative distances between the radiographic points and the X and Z axes showed significant difference when comparing the affected and unaffected sides. While the distance to the Y axis showed no significant difference.

Postoperative analysis

In group A, there was adequate restoration of the ZMC symmetry as there was non-significant difference in the distances to the three axes in both affected and unaffected sides. On the other hand, group B showed improvement only in the distances between the radiographic points and the X axis, as there was no statistically significant difference between affected and unaffected sides. On contrary, there was a significant difference at Y-axis although

it was non-significant preoperatively. In addition, the records at Z-axis remained unchanged from preoperative records and still statistically significant, indicating inadequate segments reduction and fixation.

Comparison between the postoperative mean change in the two groups on each axis

The mean change in both groups were calculated, analysed and compared (Table 3), in order to determine the adequacy of fracture reduction and fixation. There was a statistically significant difference between the two groups. Group A showed smaller deviation from the unaffected side, indicating more adequate reduction in group A than group B.

Table (3) Comparison between the postoperative mean change in two groups on

Points/ axis	Postoperative measurements		
	Group A	Group B	P-value
X axis			
MZ-X	0.4 ±2.3	7.3±2.7	0.009*
Z-X	0.4 ±1.8	4.1±2.4	0.03*
O-X	-1.2±3.5	5±2	0.009*
FZS-X	1.1±2.8	6.1±1.8	0.03*
Y axis			
MZ-Y	0.6±4.9	8.8±4.4	0.03*
Z-Y	2.4±3.5	1.8±6.8	0.05*
O-Y	-1.7±6.5	10.7±6.2	0.02*
FZS-Y	1.1±2.8	6.1±1.8	0.03*
Z axis			
MZ-Z	-0.1±6.5	15±6.4	0.02*
Z-Z	-0.6±3	6.9±4.7	0.02*
O-Z	-0.9±7.2	12.9±10.8	0.05*
FZS-Z	0.04±0.7	8.1±5.9	0.009*

Data presented as mean±SD

*significant P-value ≤0.05

Chromatography

Superimposition of postoperative 3D-CT of adapted custom made plate and preoperative virtually planned plates in group A was performed on 3D-CT view on PLASTYCAD software, to calculate the difference in accuracy. The amount of difference between the final result and the preoperative planned design was illustrated by a color map. The amount of deviation ranged from 0.7 to 1.0 mm with mean 0.8 ± 0.1 mm and it was marked green in the five cases. The position of the reduced ZMC gave very good results and the metallic artefacts of the plate were responsible for the resultant deviated area (Fig. 3).

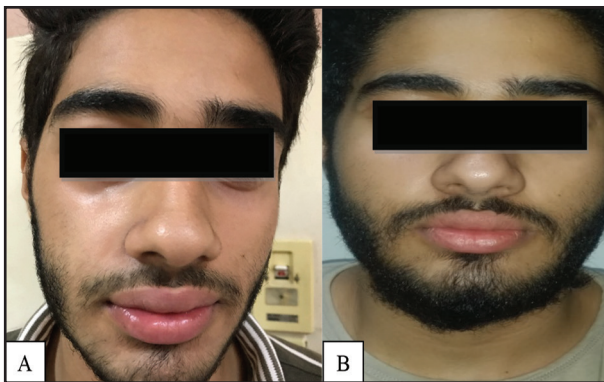


Figure (2) Photographs of a case no 5 of group A (A) preoperative clinical frontal view showing depression at the right infraorbital margin and zygoma, (B) postoperative clinical frontal and view showed adequate symmetry of ZMC

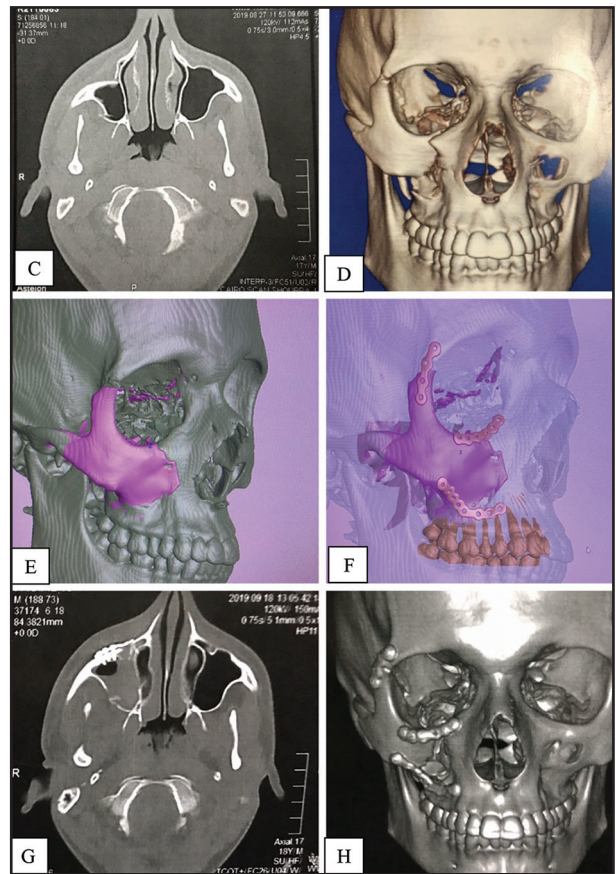


Figure (2) (cont d) (C) 2D-CT axial cut and; (D) 3D-CT cut showing preoperative depression at the level of the zygoma; (E) manual segmentation and resection of the affected side (gray) and segmental mirroring of the unaffected side to create a 3D template (purple), (F) 3D view showing the position of the final design of the custom- made plate away from teeth on the virtually restored ZMC; (G) postoperative 2D-CT axial cut and; (H) 3D-CT view showing symmetry of the zygoma

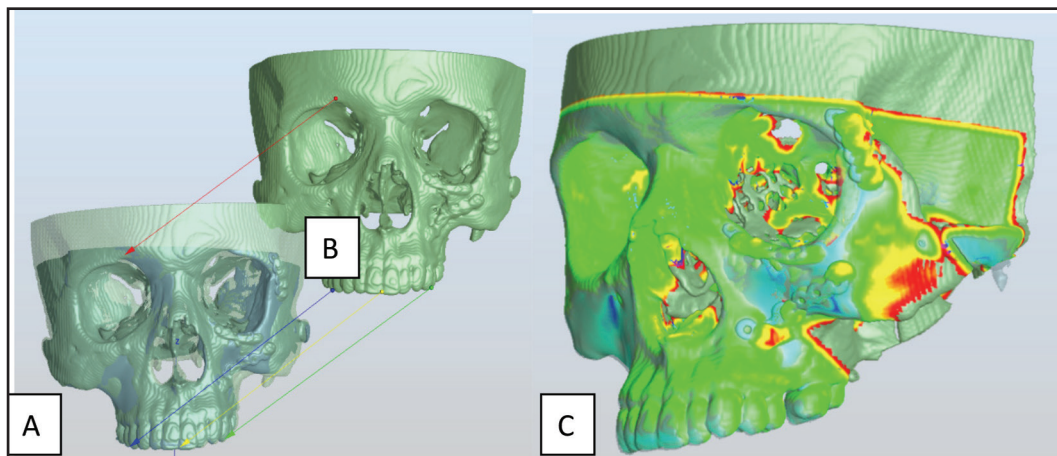


Figure (3) Showing (A) virtual plan made by mirroring of unaffected side, (B) postoperative 3D CT, and (C) color mapping of the virtual plan and postoperative CT image.

DISCUSSION

ZMC plays an important role in the mid face strength and stability, however; its projection makes this structure injure frequently. Fracture of this region varies in severity from a simple crack to major disruption. In case of high-energy injuries, comminution, displacement and orbital wall fracture are very popular, which make its reduction challenging.

CAS in maxillofacial applications has its useful role. creation of virtual models by CT segmentation and the unaffected side mirroring make the preoperative planning quite easy^(17,18), thus improving the postoperative surgical outcomes. Azarmehr et al⁽¹⁹⁾ used mirror imaging and RP techniques for anatomical adaptation of titanium mesh in reconstruction of delayed orbital fractures resulting in adequate restoration of the normal orbital volume with subsequent decrease in the degree of enophthalmos. On contrary, Udhay⁽²⁰⁾ compared the procedures of planning which uses the unaffected side mirroring with the surgical results and they found that the approach's accuracy was affected by natural asymmetry of the skull. In this study, CAS and mirror-imaging of the normal side was successfully used to restore the anatomy of ZMC fractures in group (A) by using PlastyCAD software, with adequate surgical outcomes.

The disadvantages of the conventional mini-plates such as screw loosening, plate corrosion, and fracture that occur due to plate over bending can be overcome by the integration of CNC milled patient-specific plates that based on digital files designed by computers have been created. The plate design is based on the individual patient's 3D imaging data which done by using block of titanium cut sheet⁽¹⁴⁾ and therefore the custom made plate can accurately fit the contour without any bending, thus facilitating the intraoperative procedures, reducing the time spent for operation, and improving results accuracy. in this study, the needed for ZMC reduction and fixation in group A was 68±21 minutes which is shorter than group B (109±68

minutes). This is because the custom made plate was found to be precisely fit on the bone surface without bending; however, the difference in fixation time was statistically insignificant. Moreover, these plates can reposition the displaced bony segments according to the position defined during preoperative planning,⁽²¹⁾ thus overcome the conventional method by which the experience of the surgeon is the key for the accuracy of reduction⁽²²⁾. The same findings were observed in group A of this study in which CNC milling machine was also used to create custom made plate which had the same parameters of the ordinary plates to fit the different cases⁽²³⁾. Concerning the rigidity of custom made plates, it was observed that, they are extremely rigid, providing the accurate bony fracture segments reduction and they can withstand extra loads when compared to conventional plates as also reported by many authors^(24,25). On the other hand, preoperative mistakes in virtual planning should be avoided, as custom made plate does not allow intraoperative bending, because of its rigidity⁽²⁶⁾. In addition, there is no definitive answer about the degree of accuracy of the milled custom made plates as they are designed on the mirrored normal side, which affected by the natural asymmetry of the skull. However, the overlying soft tissue can compensate this natural facial asymmetry⁽²⁷⁾.

Preoperative planning of the custom made plates took about two hours. Moreover, these plates are highly expensive when compared to conventional plates. Similarly, Yang et al⁽⁹⁾ observed that the restriction of the use of custom made plates is due to its high cost, long virtual planning, and production time. In spite of these drawbacks, Abdrlaziz et al⁽¹⁷⁾ recommended the performance of virtual planning and the use of custom plates because when surgeons design the virtual operative plan, this will facilitate the surgical procedures thus minimizing the operating time. Many authors expect that with time, the cost will decrease as the market needs for this technique will increase and they will find a cheaper alternative^(28,29).

The optimal surgical incisions to ZMC fractures should provide adequate access to the fractured segments with minimal injury to the adjacent structures and with excellent cosmetic results. In this study, the IOR was approached by subciliary incision in seven patients without any postoperative complication. This in contrast to Yoon et al⁽³⁰⁾ who observed high rate of postoperative ectropion, scleral show and scar formation following subciliary approach and they recommended transconjunctival approach. On contrary, transconjunctival incision may not be recommended as it requires lateral canthotomy for proper exposure and it causes massive postoperative edema when compared with subciliary approach. However, it was recommended that if the surgeon is well qualified in performing any incision, the postoperative complications will be reduced following any approach⁽³¹⁾.

Post-traumatic enophthalmos is considered one of the most common sequelae that follow ZMC fractures that remain a challenge to cranio-maxillofacial surgeons. Many theories explained the etiology of enophthalmos and the most accepted one is the increase in the orbital volume that usually follows ZMC fractures. So any improper reduction in ZMC will not correct the enophthalmos. It was reported that if the orbital volume increases by 1 cm³ it will result in 0.8 mm of enophthalmos⁽³²⁾. However, it becomes noticeable when it is greater than 3-4 mm. In the current study, three cases (one in group A and two cases in group B) had postoperative enophthalmos. But they are not clinically noticeable except one case.

Because of its simplicity, Hertel exophthalmometer was used in this study to measure the degree of enophthalmos⁽³³⁾. However, Hertel exophthalmometer has been objected on its use, as it shows a low reliability and poor reproducibility in serial measurements because it depends on the lateral margin as a reference point which may not be properly reduced in ZMC fracture treatment. For this reason, some authors advocated the use of CT based computerized hertel exophthalmometry⁽³⁴⁾. However, the

radiation risk of CT and its cost outweighed the disadvantages of Hertel exophthalmometry.

Many authors observed that the degree of postoperative ocular motility is influenced by the post traumatic soft tissue fragment relationships, as well as the timing of surgery. For this reason, late surgical correction will increase the incidence of fibrosis of orbital muscle and periorbital tissue resulting in permanent impairment of extra-ocular motility^(35,36). This is in accordance with the result of this study as the limitation in extraocular motility was completely improved in the two patients (group A), because of the early and proper surgical reduction of the fractured segments. No patients developed new EOM restriction after surgery, which is in contrast to the results of Ramphul and Hoffman⁽³⁷⁾.

Ptosis of the upper eye lid that appeared after trauma, could result from mechanical origin or neural origin. The upper eyelid edema can make the mechanical origin ptosis which may be temporary. In addition, damage to the muscle of levator palpebrae and facial skin of the upper eyelid may be the cause and if treated primary it could give best results⁽³⁸⁾. Ptosis which appeared secondary to trauma could cause oculomotor nerve injury and is usually resolves slowly. In this study, the etiology of ptosis that occurred in three patients in group A and one patient in group B, is due to traumatic damage in the muscle and facial skin of the upper eyelid, which were not repaired primarily in the emergency room.

The main goal of ZMC fracture reduction is mainly concentrate on symmetry recovery. For several years, the postoperative restoration of ZMC symmetry was judged visually and subjectively. Recently, many techniques have been studied to evaluate the 3D ZMC symmetry after fracture reduction and fixation by locating radiographic land-marks. In addition, the spatial position of the affected side can be recorded in accordance with the reference to the normal side pre- and postoperatively⁽¹⁷⁾.

The precision and reproducibility of these landmarks have been extremely studied by some authors, ^(39,40) who compared the results of the unaffected side pre- and postoperatively and they found that there was no actual difference in the radiographic points positions. Similarly in this study, the distance between the four pairs of anatomical landmarks and the three reference planes (x, y, and z) were measured pre- and postoperatively, and it was found that these landmarks can be easily marked and quantitatively assessed the degree of fracture displacement and the accuracy of ZMC reduction and fixation, as also reported by other studies^(39,41). For the reconstruction of the 3D coordinate system, three skeletal landmarks were defined (Basion, Nasion and Subspinale). In this study, technology of virtual planning helps surgeon to be more familiar to the steps of the surgical procedures and thus shortening the operation time and achieve adequate surgical outcomes as observed in group A. The preoperative measurements showed a statistical significance between affected and unaffected sides in both groups. However, there was not a difference between the reduced and the unaffected side in group A, which indicated that the virtual planning and the custom made plates were accurate and reliable in restoring ZMC symmetry and they are superior to conventional miniplates, as also reported by Louvrier et al ⁽⁴²⁾.

Chromatography is recently used to show the difference between postoperative CT and preoperative virtual plan ⁽⁴³⁾. Different colors reflect varying degrees of error, producing an image that is simple to interpret. In this study, chromatography was used to evaluate the preoperative design and the postoperative results in group A. There was an amazing result between reduced ZMC in group A and the surgical plans when the preoperative virtual CT and postoperative CT were superimposed, this is the same observations of Bao et al. ⁽³⁹⁾ who used the same technique.

This study showed the importance of using computer guided surgery in preoperative planning

especially the mirror imaging technique which obtain high symmetrical postoperative results, also virtual planning helps the surgeon to be familiar with the surgery thus enables him to handle any intraoperative difficulties. It also showed that custom made plates guide the surgeon rapidly and perfectly to do reduction and fixation thus reducing the time of the operation even with the un experienced surgeon. Moreover, it showed the importance of 3D measurements to evaluate the symmetry between the normal and the operated side. One of the limitations of this study is the prolonged time needed for preoperative preparation and fabrication of the custom made plates. The exact volume of the orbital cavity was not recorded in this study, which could be another limitation. Due to low reliability and poor reproducibility of Hertel exophthalmometer, CT based computerized Hertel exophthalmometry is recommended in the future studies to evaluate the degree of enophthalmos.

CONCLUSION

The application of virtual planning of the ZMC fracture reduction and fixation had its great efficacy, making the operator more familiar with the case during surgery. Custom made plate guide the reduction of the fracture, which decrease the reduction errors and reduce operation time. Custom made plate revealed adequate accuracy in restoring ZMC symmetry than conventional miniplates. The 3-D quantitative assessment used in this study successfully reflected symmetry levels

ACKNOWLEDGEMENTS

I am deeply thankful to Dr. Amr Mohamed Ekram, Consultant and former Associate Professor of Oral and Maxillofacial Surgery for his great help, active participation and guidance that enabled me to accomplish this work. I would like to express my everlasting gratitude to all My Professors, Colleagues and my Friends, so many of them influenced, encouraged, and inspired me throughout the years. I wish them the best of all.

RECOMMENDATIONS

It is recommended to use the custom-made plate for reduction and fixation of ZMC fracture if the preoperative time allows for good virtual planning.

CONFLICT OF INTEREST

None declared.

FUNDING

No funding was received for this study.

REFERENCES

- Malaviya P, Choudhary S. Zygomaticomaxillary buttress and its dilemma. *J Korean Assoc Oral Maxillofac Surg.* 2018;44:151-58.
- Farber SJ, Nguyen DC, Skolnick GB, Woo AS, Patel KB. Current management of zygomaticomaxillary complex fractures: A multidisciplinary survey and literature review. *Cranio-maxillofacial Trauma Reconstr.* 2016;9:313-22.
- Ji SY, Kim SS, Kim MH, Yang WS. Surgical methods of zygomaticomaxillary complex fracture. *Arch craniofacial Surg.* 2016;17:206.
- Neagu TP, Popescu SA, Cobilinschi C, Tincu R, Tiglis M, Lascar I. Osteosynthesis using plates and screws after removing a limited area of the periosteum in order to reduce misclassified during radiological assessment metacarpal shaft fractures. *J Med Life.* 2016;9:316.
- Belcastro A, Willing R, Jenkyn T, Johnson M, Galil K, Yazdani A. A three-dimensional analysis of zygomatic symmetry in normal, uninjured faces. *J Craniofac Surg.* 2016;27:504-8.
- Berkowitz B. The patient experience and patient satisfaction: measurement of a complex dynamic. *Online J Issues Nurs.* 2016;21:1.
- Yatabe M, Prieto JC, Styner M, . 3D superimposition of craniofacial imaging—The utility of multicentre collaborations. *Orthod Craniofac Res.* 2019;22:213-20.
- Farida M, Bessar AA, Ibrahim AMA, Dalia SA. Role of Multidetector Computed Tomography in Assessment of Maxillofacial Fractures. *Med J Cairo Univ.* 2020;88:225-31.
- Yang W, Choi WS, Leung YY. Three-dimensional printing of patient-specific surgical plates in head and neck reconstruction: a prospective pilot study. *Oral Oncol.* 2018;78:31-36.
- Tr Kim JH, Kim YS, Oh DY, Jun YJ, Rhie JW, Moon S-H. Efficacy of Altered Two-Point Fixation in Zygomaticomaxillary Complex Fracture. *Biomed Res Int.* 2020; 20:1515.
- Farag Allah SSEN, Abdallah MA, Almohandis WAA, Tawfik BEA. Assessment of Infraorbital Nerve Parasthesia after ZMC Fracture and Its Surgical Repair. *Egypt J Hosp Med.* 2020;78:278-85.
- A Vernucci RA, Aghazada H, Gardini K, et al. Use of an anatomical mid-sagittal plane for 3-dimensional cephalometry: A preliminary study. *Imaging Sci Dent.* 2019;49:159.
- E Oliveira Ruellas AC, Tonello C, Gomes LR, et al. Common 3-dimensional coordinate system for assessment of directional changes. *Am J Orthod Dentofac Orthop.* 2016;149:645-56.
- Wang Y-T, Chen C-H, Wang P-F, Chen C-T, Lin C-L. Design of a Metal 3D Printing Patient-Specific Repairing Thin Implant for Zygomaticomaxillary Complex Bone Fracture Based on Buttress Theory Using Finite Element Analysis. *Appl Sci.* 2020;10:4738.
- Ellis E, Zide MF. *Surgical Approaches to the Facial Skeleton* book. Lippincott Williams & Wilkins; 2006.
- Abdelrahman AM, ElSaied HMA, Allam RSHM, Osman MH. 'Wipe-out' after subscleral trabeculectomy in advanced glaucoma patients. *Delta J Ophthalmol.* 2017;18:94.
- Abdrlaziz L, Abozekry A. Advent of computer assisted surgery and its Application in oral and maxillofacial surgery. *Futur Dent J Egypt.* 2019;5:6.
- Coronel MM, Farag I, Shallik NA. Computer-Assisted 3D Reconstruction in Oral and Maxillofacial Surgery. In: *Virtual Endoscopy and 3D Reconstruction in the Airways.* Springer; 2019:67-8.
- Azarmehr I, Stokbro K, Bell RB, Thygesen T. Surgical navigation: a systematic review of indications, treatments, and outcomes in oral and maxillofacial surgery. *J Oral Maxillofac Surg.* 2017;75:1987-2005.
- Udhay P, Bhattacharjee K, Ananthnarayanan P, Sundar G. Computer-assisted navigation in orbitofacial surgery. *Indian J Ophthalmol.* 2019;67:995.
- Stokbro K, Bell RB, Thygesen T. Patient-specific printed plates improve surgical accuracy in vitro. *J Oral Maxillofac Surg.* 2018;76:2647.
- Nilsson J. On Virtual Surgical Planning in Cranio-Maxillofacial Surgery. 2019;55:2.

23. Brunso J, Franco M, Constantinescu T, Barbier L, Santamaría JA, Alvarez J et al. Custom-machined mini-plates and bone-supported guides for orthognathic surgery: a new surgical procedure. *J Oral Maxillofac Surg.* 2016;74:1061.
24. Ramos VF, Pinto L, Basting RT. Force and deformation stresses in customized and non-customized plates during simulation of advancement genioplasty. *J Cranio-Maxillofacial Surg.* 2017;45:1820-27.
25. Stokbro K, Borg SW, Andersen MØ, Thygesen T. Patient-specific 3D printed plates improve stability of Le Fort I osteotomies in vitro. *J Cranio-Maxillofacial Surg.* 2019;47:394-99.
26. Kärkkäinen M, Wilkman T, Mesimäki K, Snäll J. Primary reconstruction of orbital fractures using patient-specific titanium milled implants: the Helsinki protocol. *Br J Oral Maxillofacial Surg.* 2018;56:791-96.
27. Codari M, Pucciarelli V, Stangoni F. Facial thirds-based evaluation of facial asymmetry using stereophotogrammetric devices: Application to facial palsy subjects. *J Cranio-Maxillofacial Surg.* 2017;45:76-81.
28. Kubáč L, Kodym O. The impact of 3D printing technology on supply chain. In: *MATEC Web of Conferences.* Vol 134. EDP Sciences; 2017:27:22.
29. Tarsitano A, Battaglia S, Crimi S, Ciocca L, Scotti R, Marchetti C. Is a computer-assisted design and computer-assisted manufacturing method for mandibular reconstruction economically viable? *J Cranio-Maxillofacial Surg.* 2016;44:795-99.
30. Yoon SH, Lee JH. The reliability of the transconjunctival approach for orbital exposure: measurement of positional changes in the lower eyelid. *Arch craniofacial Surg.* 2017;18:249.
31. El-Anwar MW, Elsheikh E, Hussein AM, Tantawy AA, Abdelbaki YM. Transconjunctival versus subciliary approach to the infraorbital margin for open reduction of zygomaticomaxillary complex fractures: a randomized feasibility study. *Oral Maxillofac Surg.* 2017;21:187-92.
32. A Ebrahimi, MHK Motamedi, HR Rasouli. Enophthalmos and orbital volume changes in zygomaticomaxillary complex fractures: is there a correlation between them? *J Oral Maxillofac Surg.* 2019;77:134.
33. Pereira T de S, Kuniyoshi CH, Leite C de A, Gebrim EMMS, Monteiro MLR, Pieroni Gonçalves AC et al. A Comparative Study of Clinical vs. Digital Exophthalmometry Measurement Methods. *J Ophthalmol.* 2020; 10:1155.
34. Park NR, Moon JH, Lee JK. Hertel exophthalmometer versus computed tomography scan in proptosis estimation in thyroid-associated orbitopathy. *Clin Ophthalmol.* 2019;13:61.
35. Molinari AD. Strabismus following extraocular muscle trauma. *Ophthalmol.* 2018;15:1-20.
36. Dagi LR, Velez FG, Archer SM, et al. Adult Strabismus Preferred Practice Pattern. *Ophthalmology.* 2020;127:182-298.
37. Ramphul A, Hoffman G. Does preoperative diplopia determine the incidence of postoperative diplopia after repair of orbital floor fracture? An institutional review. *J Oral Maxillofacial Surg.* 2017;75:565-75.
38. Abdelhady A, Patel BC. Anatomy, Head and Neck, Eye Superior Tarsal Muscle (Mullers Muscle). *StatPearls.* 2019;22:201
39. Bao T, Yu D, Luo Q, Wang H, Liu J, Zhu H. Quantitative assessment of symmetry recovery in navigation-assisted surgical reduction of zygomaticomaxillary complex fractures. *J Cranio-Maxillofacial Surg.* 2019;47:311-19.
40. Ellegrino G, Grande F, Ferri A, Pisi P, Gandolfi MG, Marchetti C. Three-dimensional radiographic evaluation of the malar bone engagement available for ideal zygomatic implant placement. *Methods Protoc.* 2020;3(3):52..
41. Hingsammer L, Seier T, Johner J-P, et al. Does zygomatic complex symmetry differ between healthy individuals and surgically treated patients using intraoperative 3-dimensional cone beam computed tomographic imaging? *J Oral Maxillofac Surg.* 2020;78:798.
42. Louvrier A, Marty P, Barrabé A, et al. How useful is 3D printing in maxillofacial surgery? *J Stomatol oral Maxillofac Surg.* 2017;118:206-12.
43. Nazimi AJ, Soh HY, Nabil S, Nordin R. Use and evaluation of patient-specific titanium implant for delayed repair of posttraumatic frontonasomaxillary and supraorbital bone defect. *Craniofacial Trauma Reconstr Open.* 2017;1:37.