

**Original article****Ribeiro Fde's Parameters Versus CT Dimensions Measurement of Frontal Sinus for Identification of Age Range and Gender in Egyptian Sample****Rania M. Hadhoud¹ Eman A. Attia^{1*}**

¹ Department of Forensic Medicine and Clinical Toxicology, Faculty of Medicine, Ain Shams University -Egypt.

Abstract:***Corresponding author****Eman A. Attia****Email:**dremanabdelhakim@yahoo.com**Mobile:**

01020505328

ORCID ID:

000-0001-6008-68801

Background: Many studies were carried out to investigate the forensic significance of frontal sinus imaging, presuming that they could help in age and sex determination. **Objectives:** This study aimed to examine the Ribeiro parameters versus the CT dimensions measurement in identifying a person's age range and gender. **Materials and methods:** This is a cross-sectional study. 73 Egyptian adult patients were recruited for this study. A paranasal coronal CT scan and AP radiograph were performed for each patient. Frontal sinus Ribeiro Fde's measurements on a plain radiograph and CT diameters were evaluated. **Results:** Both plain radiograph and CT are simple and reliable methods for frontal sinus analysis. This study showed that both modalities could aid in the sex identification with variable predictive values; the best was for CT, with highly significant differences in the anteroposterior diameter and width of the frontal sinus left compartment and no significant difference in the right compartment dimensions. As for age estimation, both show comparable reliability in age estimation; the largest frontal dimensions as estimated by either of the imaging tools were found in the age range of 50-60 years. However, both show poor discrimination power. **Conclusion:** Both plain radiograph and CT are reliable, low-cost, and easily reproducible methods for frontal sinus analysis. CT showed better results in sex identification, and for age estimation, both offer comparable reliability in age estimation.

KEYWORDS

Frontal sinus, Ribeiro Fde's measurement, CT, sexidentification, age identification.

I. INTRODUCTION

In deceased cases where soft tissues have decomposed or DNA is damaged, fingerprint analysis or DNA identification will not be helpful for personal identification (Garhia et al., 2019). A basic stone in the deceased individuals' forensic identification uses the uniquely specifically variable anatomical structures, of which comparative radiography forms a major part (Ponde et al., 2008). Frontal sinus has got special consideration in forensic science due to its variable characteristics in each person (Garhia et al., 2019). The frontal sinus is bi-compartmental and located at the dorsal aspect of the superciliary arcs, lying between the inner and outer tables of the frontal bone. A bony septum separates both compartments and is usually off midline (Ponde et al., 2008).

It was reported that the frontal sinus is entirely developed by the age of 20 and remains unchanged till the elder age when bone resorption begins, then it shows further enlargement (Deraje et al., 2020). Therefore, frontal sinuses could not be demonstrated radiographically at birth; they begin to be aerated at the age of 2 and continue until their complete aeration at 20 (Tatlisumak et al., 2017).

Many studies were carried out to investigate the forensic significance of frontal sinus imaging, presuming that they could help in age and sex determination (Verma et al., 2014). Ribeiro Fde (2000) standardized

measuring parameters from the frontal sinus anteroposterior radiographs. Computed tomography (CT) is a well-known, considerably beneficial imaging tool. It has continuously growing applications, especially in the medical fields; among them is the use in forensic medicine, with superiority compared to plain radiographs (Tatlisumak et al., 2000). Studies have been conducted to utilize sinus radiography for the identification of remains, especially for the determination of sex and race (Divakar, 2017)

This study aimed to assess the reliability of RibeiroFde's criteria versus CT in measuring the frontal sinus dimensions and to propose its feasibility as a personal indicator for age and sex identification in an Egyptian population sample.

II. MATERIALS AND METHODS

2.1 Study design: this is a cross-sectional study (Diagnostic Accuracy testing)

2.2 Sample size and characteristics:

The current study included Egyptian adult patients who had frequent headaches and were referred to the Radiology Department, Al-Demrdash Hospital, Ain Shams University, for radiological assessment from the 1st of January 2020 till 31st of December 2020. After taking history, patients with previous facial surgery, trauma, or congenital disfigurement were excluded.

Then, after performing the AP radiograph, patients with aplasia or bilateral absence of frontal sinuses were excluded. It is worth noting that no pathological findings were detected in the sinuses of chosen patients. Out of 82 patients, 73 patients aged more than 18 years were eligible for this study: 37 males and 36 females. Informed written consent was obtained from each of the study participants. The study was approved by Ain-Shams University ethical committee.

2.3 Imaging parameters: paranasal coronal CT scan and AP radiograph were performed for each patient by the same radiology technician, axial reformats were performed. The patients' examinations were obtained from the department Picture Archiving and

Communication System (PACS) system and viewed using Digital Imaging and Communications in Medicine (DICOM) viewer: RadiAnt DICOM Viewer 2020.2.

- The maximum depth (maximum distance from the anterior to the posterior sinus borders) for the right frontal sinus (RT AP) and left frontal sinus (LT AP) and,
- The maximum width (distance from the medial to the lateral sinus borders) in the largest sinus axial image of both right frontal sinus (RT W) and left frontal sinus (LT W) compartments (Figure 1).

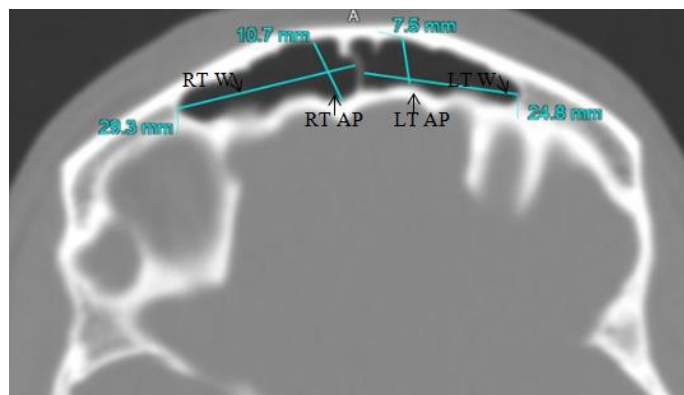


Figure 1: measuring frontal sinus compartments AP diameter and width.

RT W: right frontal sinus width, RT AP: right frontal sinus anteroposterior measurement, LT W: left frontal sinus width, LT AP: left frontal sinus anteroposterior measurement

In all the radiographs, the borderlines of the frontal sinus were determined, and the following markings were made based on Ribeiro Fde's measurement criteria. The reference lines were a baseline drawn horizontally along the upper limit of both orbital cavities; then, four lines were drawn perpendicular to the baseline:

- Line E: delineates the maximum lateral limit of the right frontal sinus.
- Line F: passed through the highest point of the right frontal sinus.
- Line G: was drawn through the highest point of the left frontal sinus.

- Line H: defined the most lateral limit of the left frontal sinus.

After then, the following measurements were estimated:

- Measurement A: the maximum width of the frontal sinus, the distance between E and H lines
- Measurement B: the distance between F and G lines.
- Measurements C and D: the distance between E to F lines and from G to H lines, respectively (Figure 2).

The mean of all was recorded and used in the final data analysis

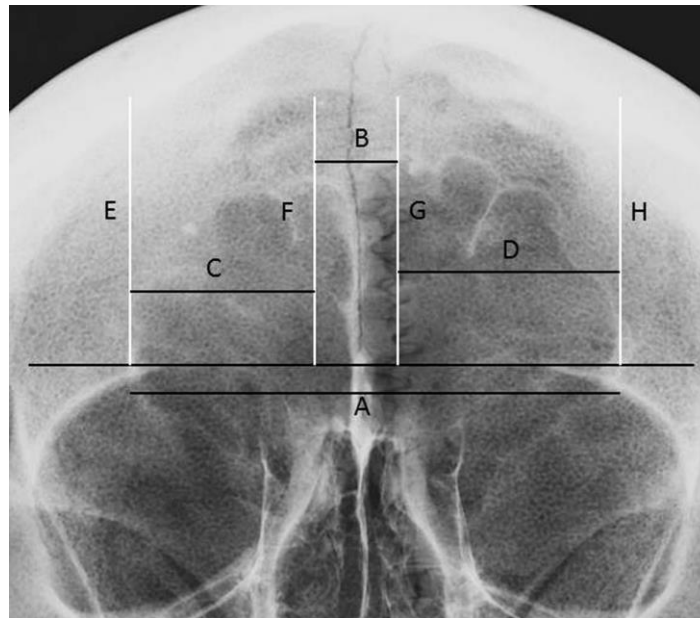


Figure 2: Markings based on Ribeiro Fde's measurement criteria (Ribeiro Fde, 2000)

2.4 Statistical analysis

All data were statistically analyzed using the Statistical Package for Social Sciences (SPSS for Windows, version 11.0). The numerical results were expressed as mean \pm standard deviation (SD), and the categorical results were expressed as percentages (%). Analysis of variation (ANOVA), student-t tests, and Pearson correlations was performed, then the p values were calculated, $p > 0.05$, < 0.05 , and < 0.01 were considered as non-significant, significant, and highly significant, respectively.

III. RESULTS

In this study, the left sinus compartment measures tend to be larger than the right. The left and right sinus compartments CT depths mean values were 9.7 & 9.3 mm consequently, CT widths mean values were 28.1 and 26.5 mm; hence, the plain radiograph maximum widths were 19.4 & 22.6 mm, respectively. However, these differences were statistically non-significant in the CT measures (depth and width) ($p > 0.05$). At the same time, they were statistically significant in the plain radiograph measures (maximum widths measurements of both right and left sinuses, measurements C & D) ($p = 0.02$). This study showed that the male gender comprised 50.7 % (37) of the study population (Figure 3)

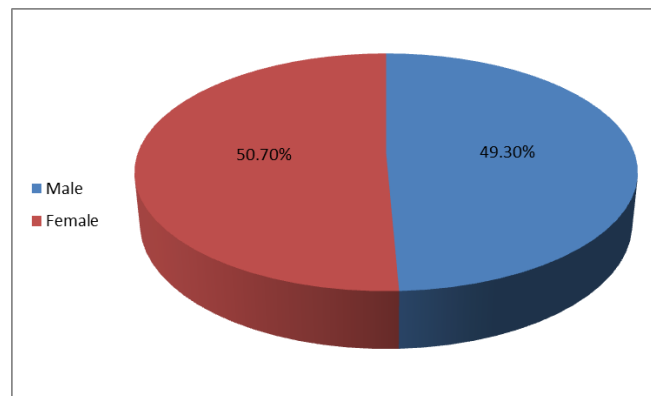


Figure 3: gender distribution of the study participants.

The differences between both genders in CT and the radiograph measurements were illustrated in tables(1and2) and figures(4and5). There were highly significant differences in the anteroposterior diameter and width of the frontal sinus left compartment regarding the CT measurements. Though they were higher in the male gender, no significant

difference was noted in the right compartment dimensions. For the radiograph dimensions, there was a highly significant difference in measurement A, a significant difference in measurements B & D, and a non-significant difference in measurement C between both genders.

Table 1: The difference in measured CT dimensions between males and females as estimated by student t-test

	left AP	Left W	Right AP	Right W
Male (n=37)	11.3 ± 1.95	31.7 ± 11.3	9.7 ± 2.4	27.1 ± 7.8
Female (n=36)	8.1 ± 2	24.5 ± 8.4	8.8 ± 2.5	25.8 ± 8.2
T	-6.9	-3.1	-1.6	-0.7
P	<0.01**	<0.01**	> 0.05	> 0.05

P value < 0.05 is considered significant.

NS=non-significant, * = significant, ** = highly significant

Left AP: left frontal sinus anteroposterior measurement, Left W: left frontal sinus width, Right AP: right frontal sinus anteroposterior measurement, Right W: right frontal sinus width.

Table 2: The difference in plain radiograph measures between males and females as estimated by student t-test

	Measurement A	Measurement B	Measurement C	Measurement D
Male (n=37)	64.5 ± 12.7	17.2 ± 10.6	20.5 ± 7.9	24.6 ± 8.9
Female (n=36)	54.4 ± 11.7	12.9 ± 4.1	18.4 ± 6.7	20.5 ± 8.4
T	-3.5	-2.3	-1.2	-2
P	<0.01**	<0.05*	> 0.05*	<0.05

P value < 0.05 is considered significant.

NS=non-significant, * = significant, ** = highly significant

Measurement A: the maximum width of the frontal sinus, the distance between E and H lines, Measurement B: the distance between F and G lines, Measurement C: the distance between E to F lines, and Measurement D: the space between from G to H lines

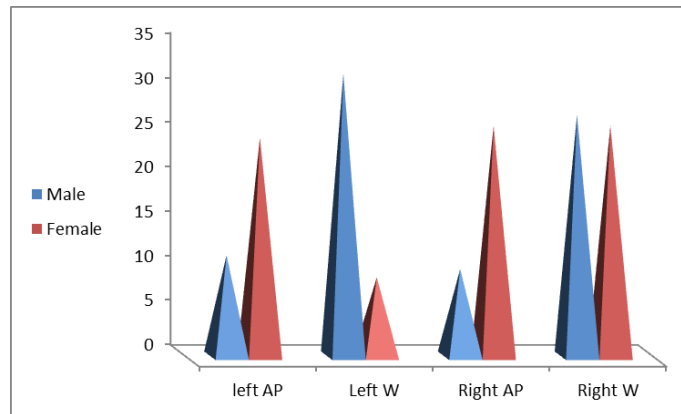


Figure 4: measured CT dimensions in the study participants.

Left AP: left frontal sinus anteroposterior measurement, Left W: left frontal sinus width, Right AP: right frontal sinus anteroposterior measurement, Right W: right frontal sinus width.

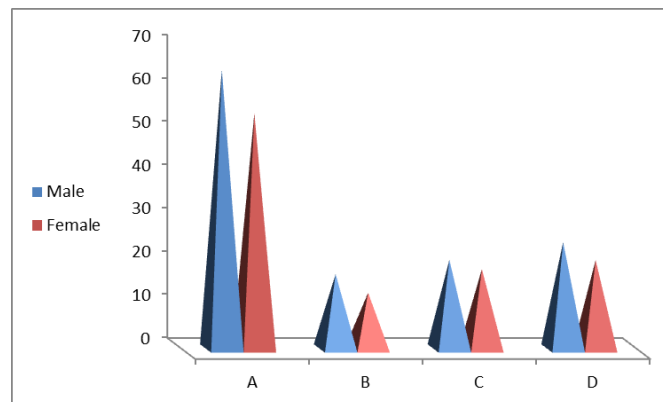


Figure 5: measured radiograph dimensions in the study participants.

Measurement A: the maximum width of the frontal sinus, the distance between E and H lines, Measurement B: the distance between F and G lines, Measurement C: the distance between E to F lines, and Measurement D: the space between from G to H lines

We further performed regression analysis for the parameters in which their mean values show a significant difference between both genders. Among them, the

left sinus depth as measured from CT showed the best predictive function with an R^2 value of 0.4, indicating adequate discriminative power (Figure 5).

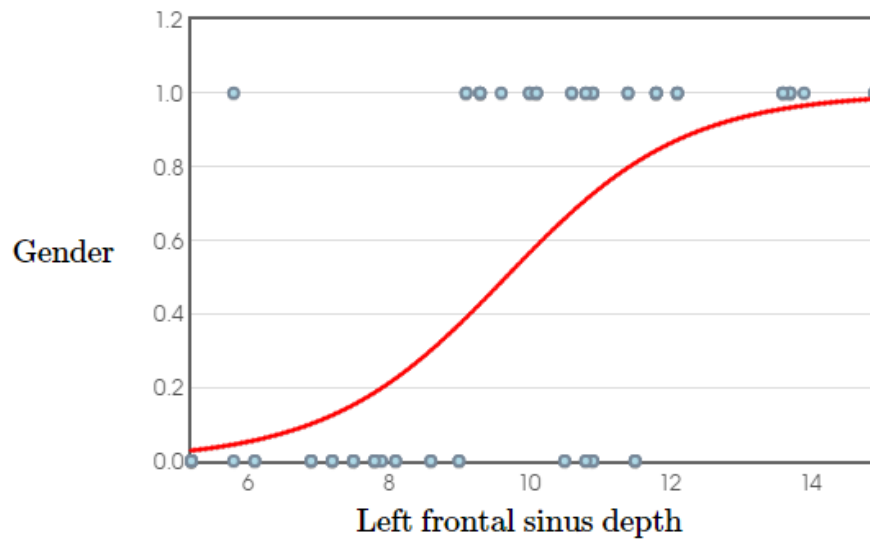


Figure 5: Predictive model of left frontal sinus depth (binary logistic regression analysis test).

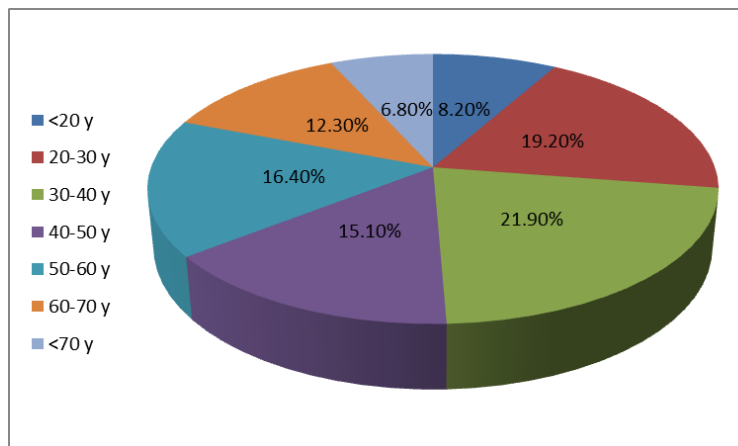


Figure 6: the age range of the study participants.

The study participants were categorized according to their age range; the highest percentage was that of the middle-aged patients (30-40 years), as they contributed 21.9% (16) of the patients (Figure 6).

The distributions of CT and radiograph dimensions according to age range were described in tables (3 and 4) and figures (7 and 8). The frontal dimensions as estimated by either imaging tools were the largest in the age range of 50-60 years old; then, they show a gradual decrease. Again, only the left frontal sinus

dimensions showed significant differences among the age ranges in the CT. Regarding radiograph dimensions, A measure (the width of both compartments) showed a significant difference, while B, C, and D differences

did not reach the significance level. Their mean values significantly differ among the variable age groups on regression analyses of the parameters. None of them showed considerable discriminative power (low R^2).

Table 3: The distribution of CT dimensions according to age range as estimated by ANOVA test

	left AP	Left W	Right AP	Right W
<20 y	10.1 ± 3	22.9 ± 14.4	9.7 ± 2.5	32.1 ± 4
20-30 y	10.4 ± 2.2	29.8 ± 10.8	9.7 ± 3.2	25.3 ± 8.5
30-40 y	9.3 ± 2.6	24.8 ± 8.6	8.9 ± 2.1	25.2 ± 6.9
40-50 y	9.4 ± 2.5	27.9 ± 10.5	9.4 ± 3.2	24.6 ± 8.7
50-60 y	11.3 ± 2.5	37.2 ± 8.8	10.1 ± 2.3	29.4 ± 9
60-70 y	7.7 ± 2	25.7 ± 9	7.8 ± 1.7	25.2 ± 9.1
>70 y	8.8 ± 1.3	23.7 ± 7.7	9.1 ± 1.1	26.1 ± 7.7
F	2.4	2.6	0.9	1
P	<0.05*	<0.05*	> 0.05	> 0.05

P value < 0.05 is considered significant.

NS=non-significant, * = significant, ** = highly significant

Left AP: left frontal sinus anteroposterior measurement, Left W: left frontal sinus width, Right AP: right frontal sinus anteroposterior measurement, Right W: right frontal sinus width.

Table 4: The distribution of radiograph dimensions according to age range as estimated by ANOVA test

	A	B	C	D
<20 y	58.4 ± 15	12.1 ± 2.1	25.1 ± 9.8	16.5 ± 7.3
20-30 y	57.1 ± 11.7	14.2 ± 8.6	18.8 ± 5.7	20.8 ± 9.3
30-40 y	57.9 ± 9.4	15.1 ± 7.6	17.8 ± 5.9	22.8 ± 6.9
40-50 y	57.5 ± 15.7	17.3 ± 11.5	18.3 ± 2.9	22 ± 10.1
50-60 y	71.8 ± 12.1	18.6 ± 10	21.1 ± 8.6	29.7 ± 9.7
60-70 y	55.8 ± 11.9	12.9 ± 6.1	18.8 ± 7.2	21.1 ± 6.2
>70 y	53.9 ± 13.8	11.6 ± 3.9	19.5 ± 7.5	20.9 ± 8
F	2.5	0.89	0.88	2.1
P	<0.05*	> 0.05	> 0.05	> 0.05

P value < 0.05 is considered significant.

NS=non-significant, * = significant, ** = highly significant

Measurement A: the maximum width of the frontal sinus, the distance between E and H lines, Measurement B: the distance between F and G lines, Measurement C: the distance between E to F lines, and Measurement D: the distance between from G to H lines

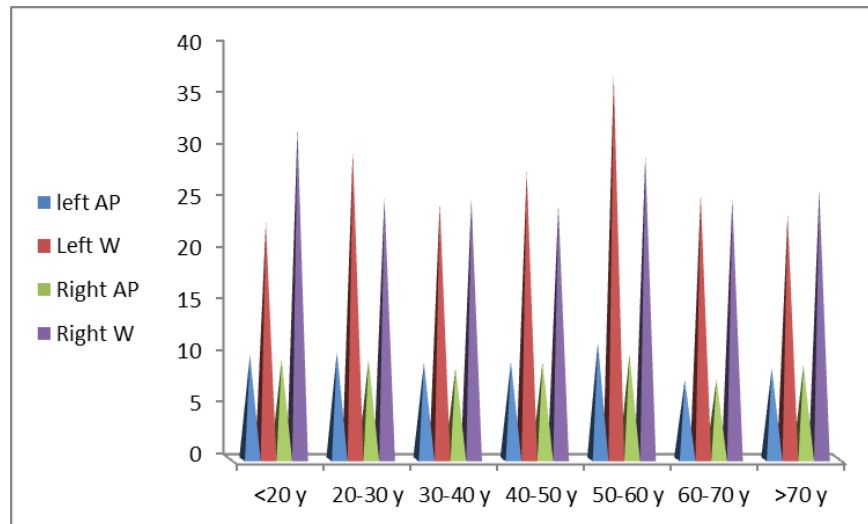


Figure 7: The distribution of CT dimensions according to age range.

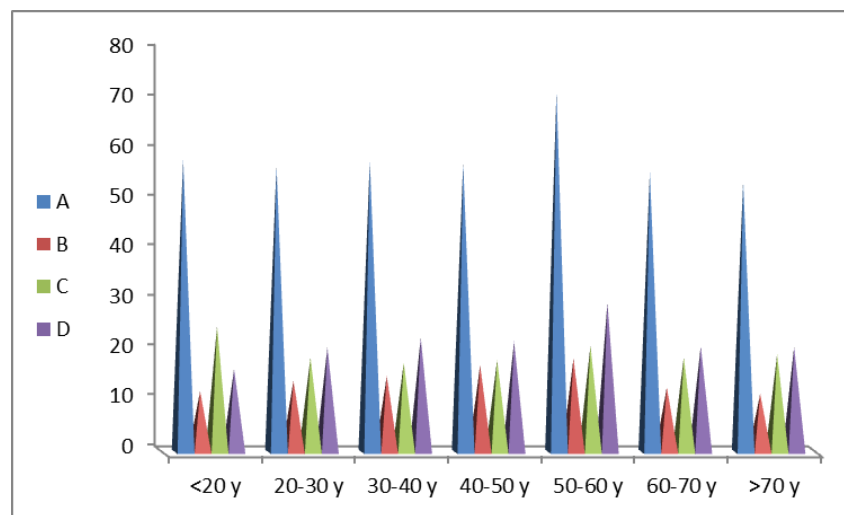


Figure 8: The distribution of radiograph dimensions according to age range.

Pearson correlation analysis was performed to test the correlation between patient age and any estimated measures.

Neither of the r values did reach the level of significance (Table 5).

Table 5: Pearson correlation test for different estimated CT and radiograph measures with the patient age

Measured diameter	R	P
left AP	-0.14	> 0.05
Left W	0.08	> 0.05
Right AP	-0.08	> 0.05
Right W	-0.06	> 0.05
A	0.06	> 0.05
B	0.01	> 0.05
C	-0.05	> 0.05
D	0.18	> 0.05

Left AP: left frontal sinus anteroposterior measurement, Left W: left frontal sinus width, Right AP: right frontal sinus anteroposterior measurement, Right W: right frontal sinus width. Measurement A: the maximum width of the frontal sinus, the distance between E and H lines, Measurement B: the distance between F and G lines, Measurement C: the distance between E to F lines, and Measurement D: the distance between from G to H lines

IV. DISCUSSION

In the absence of DNA or fingerprint records, identifying unknown human remains by radiographs performed during life and compared to postmortem radiographs has been recognized and accepted as a valid and simple tool in recent years (Cameriere et al., 2020). Radiological identification has been a cornerstone in forensic medicine. It could be achieved if the imaged structure fulfills two conditions, first, to be unique in each person, and second, to show relative overtime stability. The frontal sinus **tsmee** both requirements (Divakar, 2017).

In this study, the aplasia or unilateral absence of the frontal sinus excluded nine patients out of 82. Finally, 73 patients were eligible for the study, with a higher percentage than studies of Patil et al. (2012) and Cameriere et al. (2020). The patients were more than 18 years old to ensure complete frontal sinuses development. Specialists use different methods for frontal sinus analysis, as in Cameriere et al. (2020).

The authors assessed the frontal sinus plain radiograph using Ribeiro Fed's parameters and CT dimensions for each patient of an Egyptian sample. In this study, the left compartment side tended to be larger than the right, either with

statistically significant or non-significant differences. This was in concordance with many previous studies (Divakar, 2017, Soman et al., 2016). This discrepancy could be attributed to the fact that they develop independently.

The results showed that the frontal sinuses were generally larger in males than females, with variables significance levels. This agrees with many previous studies (Tatlisumak et al., 2008, Divakar, 2017)

In this study, there were highly significant differences between both genders in the anteroposterior diameter (depth) and width of the frontal sinus left compartment. Though they were higher in the male gender, no significant difference was noted in the right compartment dimensions. For the radiograph dimensions, this study showed a highly significant difference in A measurement (the maximum width of the frontal sinus), a considerable difference in B and D measurements (the distance between the highest points of both sinus compartments and the distance between the highest point and most lateral point of the left sinus) respectively, and non-significant

difference in C measurement (the distance between the highest point and most lateral point of the right sinus) between both genders. This means that regarding the frontal sinus CT imaging, the left sinus compartment width and depth could be sex determinants. In contrast, the total width of both compartments and the inter-compartment distance could also be determinants regarding plain radiograph imaging. Regression analysis revealed that the left sinus depth as measured from CT was the best predictive parameter with an R^2 value of 0.4, indicating adequate discriminative power. The studies of Hamed et al. (2014) and Mathur et al. (2013) reported statistically significant larger frontal sinus right and left compartments width and depth in males in comparison to females, and Lee et al. (2010) said that these differences were only found to be significant at or close to the midline.

In agreement with our results, the study of Chalkoo et al. (2018) concluded that the most discriminating variables for sex identification were the left depth and left width. In their research, Metin-Gürsoy et al. (2021) reported no significant difference between their studied groups

regarding the height of the frontal sinuses. A significant correlation was noted between the frontal sinus's maximum anterior, posterior dimensions. The studies of Camargo et al. (2007) and Uthman et al. (2010) also found that the left width and the left area are the most predicting factors suitable for identifying gender.

Another study on the Indian population revealed that the frontal sinus area was higher; the regression analysis revealed a predictive value of 0.64, which is greater than our results. This may be due to the frontal sinus's documented morphological variation (Beladavar et al., 2014). However, the results of Soman et al. (2016) and Navdeep et al. (2013) did not find any statistically significant difference between males and females in the frontal sinus dimensions. They concluded that the frontal sinus analysis is not reliable in sex identification.

This study found that the variable frontal sinus dimensions differ significantly among patients in different age ranges. As estimated by either imaging tools, the largest frontal dimensions were found in the age range of 50-60 years old; then, they showed a gradual decrease. Soman

et al. (2016) reported an increase in frontal sinus area with age. In line with our results, Soman et al. (2016), Mc- Laughlin et al. (2001), and Tatlisumaket al. (2008) found that the frontal sinus dimensions, after complete development, show a subsequent decrease as the age advances. The beginning of decline in Soman et al. (2010) study was at the 45 years age group and above, while in Mc- Laughlin et al. (2001) and Tatlisumak et al. (2008) studies were at the age of 40 years. They explained this by the hormonal and mechanical mastication stresses.

However, Fatu et al. (2006) and Karakas and Kavakli (2005) did not report this decrease, who described the osseous resorption as the cause of the increase in size. There is no doubt regarding the morphological variations among different populations, which could explain the other studies' variability results.

V. CONCLUSION

This study's results agreed with other studies that the frontal sinus could be potentially used for sex and age identification. For the studied Egyptian

sample, both plain radiograph and CT are reliable, low-cost, and easily reproducible methods for frontal sinus analysis. Both modalities could aid in the sex identification with variable predictive values, but the best results favored CT. As for age estimation, both show comparable reliability in age estimation. However, both show poor discrimination power.

VI. LIMITATIONS

The limitation of this study is the small sample size due to the small number of patients complaining of headaches and seeking medical advice, as Al-Demerdash Hospital is mainly serving patients in need. Further studies on larger sample sizes with wider geographic area involvement and more identifying parameters are recommended.

VII. REFERENCES

Belaldavar, C.; Hallikerimath, S. & Kale, A. (2014): Assessment of frontal sinus dimensions to determine sexual dimorphism among Indian adults". *J Forensic Dent Sci.* ;6(1).

Camargo, J.R.; Daruge, E.; Prado, F.B.; Caria, P.H.; Alves, M.C.; Silva, R.F. & Daruge, E.J. (2007): The frontal sinus morphology in radiographs of Brazilian subjects: Its forensic importance. *Braz J Morphol Sci.*; 24:239-43.

Chalkoo, A.H.; Sharma, P.; Nazir, N. & Tariq, S.(2018): Evaluation of the frontal sinuses' dimensions in sex estimation among a sample of adult Kashmiri population using multidetector computed tomography. *IP Int J Maxillofac Imaging* 2018;4(4):122-125.

Chaudhary, S. & Singh, U. (2016): Uniqueness of Frontal Sinus as a Personal Identification in Forensic Odontology. *Ann. Int. Med. Den. Res.*; 2(5):AT07-AT09.

Divakar KP (2017): Forensic Odontology: The New Dimension in Dental Analysis. *Int J Biomed Sci.*;13(1):1-5.

Fatu, C.; Puisoru, M.; Rotaru, M.&Truta, A.M. (2006): Morphometric evaluation of the frontal sinus in relation to age. *Ann Anat.* 2006; 188:275-80.

- Garhia, P.; Saxena, S. & Gupta, A. (2019): Frontal Sinus Variability as a Tool in Forensic Identification- A Pilot Study Using Radiographic Images and Software Analysis. *Int J Cur Res Rev.*; 11(8).
- Hamed, S.; El-Badrawy, A.& Abdel Fattah, S. (2014): Gender identification from frontal sinus using multidetector computed tomography. *J Forensic Radiol Imaging.*;2(3):117-120.
- Karakas, S.&Kavakli, A. (2005): Morphometric examination of the paranasal sinuses and mastoid air cells using computed tomography. *Ann Saudi Med.*;25 (1):41-5.
- Mathur, H.; Mathur, A.; Ahmed, J.; Horate, M.& Tripathi, P. (2013): Conventional frontal sinus imaging in identification of sex: original study in population of Udaipur City, India. *J Med Sci Clin Res.*;1(1):33–37.
- McLaughlin, R.B. J.; Rehl, R.M. & Lanza, D.C.(2001): Clinically relevant frontal sinus anatomy and physiology. *Otolaryngol Clin North Am.*; 34:1-22.
- Navdeep, K.; Sunira, C.; Parvathi, D.; Srinivasa, R.M.; Neeraj, T.&Ruhi, S. (2013): The forensic importance of frontal sinus in gender discrimination: a morphometric study. *J Oral Sign.*;5(1):2–5.
- Pondé, J.M.; Andrade, R.N.; Via, J.M.; Metzger, P. &Teles, A.C. (2008): Anatomical Variations of the frontal sinus. *Int J Morphol.*; 26:803–8.
- Ribeiro Fde A. (2000): Standardized measurements of radiographic films of the frontal sinuses: an aid to identifying unknown persons. *Ear Nose Throat J.*; 79:26–33.
- Soman, B.A.; Sujatha, G.P. &Lingappa, A. (2016): Morphometric evaluation of the frontal sinus in relation to age and gender in subjects residing in Davangere, Karnataka. *J Forensic Dent Sci.*;8.
- Tatlisumak, E.;Asirdizer, M. & Yavuz, M. (2011): Usability of CT Images of Frontal Sinus in Forensic Personal Identification, Theory and Applications of CT Imaging and Analysis. In book: *Theory and*

Applications of CT Imaging and Analysis, 1st edition, chapter: 15, InTech, ISBN: 978-953-307-234-0.

Tatlisumak, E.; Asirdizer, M.; Bora, A.; Hekimoglu, Y.; Etili, Y.; Gumus, O. & Keskin, S. (2017): The effects of gender and age on forensic personal identification from frontal sinus in a Turkish population. *Saudi Med J.*; 38(1):41-47.

Tatlisumak, E.; Ovali, G.Y.; Asirdizer, M.; Aslan, A.; Ozyurt, B.; Bayindir, P. & Tarhan, S. (2008): CT study on morphometry of frontal sinus. *Clin Anat.*; 21(4):287-93.

Uthman, A.T.; Al-Rawi, N.H.; Al-Naaimi, A.S.; Tawfeeq, A.S. & Suhail, E.H. (2010): Evaluation of frontal sinus and skull measurements using spiral CT scanning: An aid in unknown person identification. *Forensic Sci Int.*; 197:124. e1-7.

Verma, S., Mahima, V.G. & Patil, K. (2014): Radiomorphometric analysis of frontal sinus for sex determination. *J Forensic Dent Sci.*; 6(3):177-182.

الملخص العربي

مقاييس ريبيرو فد مقابل قياس أبعاد التصوير المقطعي للجيوب الأنفية لتحديد الفئة

العمرية والجنس في عينة من السكان المصريين

*رانية مصطفى هدهود، *إيمان عبد الحكيم عطية

*قسم الطب الشرعي والسموم الإكلينيكية/ كلية الطب البشري- جامعة عين شمس- مصر

الخلفية: تم إجراء العديد من الدراسات للتحقيق في أهمية تصوير الجيوب الأنفية في الطب الشرعي بافتراض أنها يمكن أن تساعد في تحديد العمر والجنس. **الأهداف:** هدفت هذه الدراسة إلى تقييم موثوقية معايير ريبيرو فد مقابل التصوير المقطعي المحوسب في قياس أبعاد الجيوب الأنفية الأمامية واقتراح جدواها كمؤشر شخصي لتحديد العمر والجنس في عينة من السكان المصريين. **المواد والطرق:** هذه دراسة مقطعية تم فيها اختيار 73 مريضاً مصرياً بالغاً. تم إجراء فحوصات الأشعة المقطعية التاجية وفحوصات الأشعة السينية لكل مريض. تم قياس قياسات الجيوب الأنفية الأمامية باستخدام معايير ريبيرو فد على صور الأشعة العادية بالإضافة إلى قياس أقطار الجيوب على التصوير المقطعي المحوسب. **النتائج:** يعتبر كل من التصوير الإشعاعي البسيط والتصوير المقطعي المحوسب طريقتين بسيطتين وموثوقتين لتحليل الجيوب الأنفية الأمامية. أظهرت هذه الدراسة أن كلا الطريقتين يمكن أن تساعد في تحديد الجنس مع القيم التنبؤية المتغيرة، مع إعطاء نتائج أفضل لصالح التصوير المقطعي المحوسب. بالنسبة لتقدير العمر، أظهر كلاهما موثوقية قابلة للمقارنة في تقدير العمر، وقد وُجدت الأبعاد الأكبر للجيوب الأمامية - كما تم تقديرها بواسطة كلتا الطريقتين - في الفئة العمرية من 50-60 عامًا. ومع ذلك، كلاهما يظهر قوة تمييز ضعيفة. **الخلاصة:** يعد كل من التصوير الشعاعي البسيط والتصوير المقطعي المحوسب طريقتين موثوقتين ومنخفضة التكلفة وقابلة للتكرار بسهولة لتحليل الجيوب الأنفية الأمامية. أظهر التصوير المقطعي نتائج أفضل في تحديد الجنس وتقدير العمر، أظهر كلاهما موثوقية قابلة للمقارنة في تقدير العمر.