

## ORIGINAL ARTICLE

**A new approach in treatment of chronic murine models of toxoplasmosis using nitrofurantoin antibiotic****Karim F. Abdallah<sup>1</sup>, Mohamed H. Saleh<sup>1</sup>, Shereen M. Kishik<sup>1</sup>, Ashraf M. Barakat<sup>2</sup>, Basmaa T. Ali<sup>1</sup>, Asmaa A. El Kholy<sup>1\*</sup>**<sup>1</sup> Parasitology Department, Faculty of Medicine, Benha University, Benha, Egypt<sup>2</sup> Zoonotic Diseases Department National Research Center, Giza, Egypt**\*Corresponding Author:**Asmaa Abd Elmoniem El-kholy, Parasitology  
Department of Pediatrics,  
Faculty of Medicine, Benha  
University, Benha, Egypt  
E-mail:[asmaakholy787@gmail.com](mailto:asmaakholy787@gmail.com)

Submit Date 2021-12-27

Revise Date 2022-01-14

Accept Date 2022-01-25

## ABSTRACT

**Background:** Standard therapies for toxoplasmosis have serious adverse effects and can't eliminate the cyst stage of chronic infection. Highly effective medications with few adverse effects are required. This work aimed to determine the efficacy of nitrofurantoin in the treatment of chronic toxoplasmosis as a means of overwhelming the limitations of other standard medications.**Methods:** A total of 42 laboratory-bred Swiss female albino mice were included. Six mice were left in the non-infected, non-treated group (G 1). The rest (12mice/each group) were experimentally infected orally with the T. gondii strain (ME49). Six weeks post-infection the experimental mice were divided into four groups. Group1:uninfected, untreated; Group2:infected, untreated mice (infected control); Group3:infected treated mice with nitrofurantoin for two weeks and Group 4: infected mice treated with a combination of nitrofurantoin and spiramycin for two weeks. Sixty days after infection, all mice were slaughtered. Parasitological (brain cyst count) and histological (using hematoxylin and eosin) measures were used to assess the therapeutic impact of nitrofurantoin in chronically infected mice (H & E).**Results:** High significant reduction of mean brain cyst count was observed in the nitrofurantoin monotherapy group in comparison with the infected control group. The combination-treated group had the best treatment efficacy, with the highest rates of brain cyst decrease. Histopathological studies of the brain tissues showed an obvious correlation with the results of the brain cyst counts.**Conclusions:** Nitrofurantoin is a possible anti-T.gondii option for clinical usage in chronic toxoplasmosis, as it enhances the antitoxoplasmic effect of standard toxoplasmosis treatment.**Keywords:** Toxoplasma gondii, chronic toxoplasmosis, nitrofurantoin.

## INTRODUCTION

**T**oxoplasma gondii is a human and animal intracellular protozoan parasite with a global distribution. Up to 70% of adults are asymptomatic carriers of this parasite, with unknown long-term health implications [1, 2].

Primary T. gondii infection of an immunocompetent host is converted to latency, which is defined by slowly increasing bradyzoites within tissue cysts usually found in the brain and skeletal muscles, following a brief acute stage characterized by the parasite's proliferative tachyzoite stage. Tissue cysts are controlled primarily by cellular immune mechanisms and stay alive for the life of the host[3]. Cyst rupture and fresh parasite proliferation may occur if the balance between the host immune system and the parasite is broken, resulting in clinical reactivation [4]. Due to the parasite's potential to pass the placental barrier and infect the developing embryo,

toxoplasmosis is a serious risk during pregnancy[5].

Furthermore, due to cyst rupture and unregulated tachyzoite proliferation, immunocompromised patients are more likely to have reactivated toxoplasmosis[6]. Those with underlying illnesses, such as AIDS, or those who are therapeutically immunosuppressed as a result of organ transplantation or cancer chemotherapy, are at risk. In AIDS patients who do not get extremely vigorous antiretroviral therapy or antiparasitic prophylaxis, toxoplasmic encephalopathy is the most prevalent clinical sign of reactivated illness. Reactivation can cause serious central nervous system (CNS) problems and even death if left untreated[6]. In humans, pyrimethamine plus sulfadiazine is the standard treatment for toxoplasmosis. These medications, however, are frequently intolerable due to significant side effects and are not necessarily suitable for long-term

use[7]. Other medications for clinical toxoplasmosis include azithromycin, clarithromycin, spiramycin, atovaquone, dapsone, and co-trimoxazole (trimethoprim-sulfamethoxazole) [8-11]. To prevent prenatal transmission, spiramycin monotherapy can be effective early in pregnancy. Spiramycin-treated individuals retained *T.gondii* DNA in their blood and remained infected in more than half of the cases[12]. Current treatments only inhibit actively growing parasites and have minimal efficacy against bradyzoites within tissue cysts, leaving the chronic infection unabated [7]. As a result, new and more effective treatment drugs with minimal toxicity are required to treat this condition [8,12,13]. Nitrofurantoin is a nitrofurantoin antibiotic utilized to treat or prevent urinary tract infections [14]. For individuals with recurrent urinary tract infections, it is an efficient chemoprophylactic drug. Pregnant women can use this medicine because it appears to have no detrimental effects on the developing baby[15]. It is resistant to the formation of bacterial resistance to a high degree, which is assumed to be related to its diverse mechanism of action [16]. In-vitro and in-vivo studies have revealed that many nitrofurantoin molecules have biological action. According to some researchers, many substances have been revealed to have anti-depressant effects and a central nervous system inhibitory effect, including anxiety alleviating, anti-convulsant, and anti-depressive properties. A few nitrofurantoin compounds have been discovered to exhibit potent antifilaria, schistosomiasis, and trypanosomiasis activity. The capacity of nitrofurantoin to produce free radicals, which react with molecular oxygen to form superoxide anion, hydrogen peroxide, and hydroxyl radicals, is responsible for their activity [17]. Furthermore, nitrofurantoin had a considerable impact on malondialdehyde (MDA) and glutathione (GSH), two antioxidant status indicators. *T.gondii*-induced MDA levels were decreased by nitrofurantoin, which also alleviated GSH depletion. Nitrofurantoin was reported to be effective in acute toxoplasmosis [18].

This study aimed to see how effective nitrofurantoin is as a treatment for chronic toxoplasmosis in mice, to see if it can compensate for the drawbacks of some of the other regularly used medications.

## METHODS

The National Research Centre (NRC) in Cairo, Egypt, hosted this experimental investigation from November 2018 to January 2019.

### *Study design:*

A total of 42 animals were classified into four groups: Group (1): six mice uninfected, and

untreated (normal control).Group (2):12 mice infected untreated (infected control).Group(3):12 mice infected and treated with nitrofurantoin100mg/kg (2mg for each mouse). Group (4):12 mice infected and treated with spiramycin and nitrofurantoin combination. All treated groups received medications six weeks post-infection after the toxoplasma cyst was mature and fully developed and continued treatment for the end of the experiment (eight weeks).

### *Parasite:*

NRC's zoonosis department generously provided the ME49 non-virulent strain of *T. gondii*. Every 8 weeks, a Swiss albino mouse was inoculated with 0.1ml of brain homogenate from previously infected mice containing approximately  $1 \times 10^2$  tissue cysts/ml to establish chronic toxoplasmosis [19].

### *Experimental animals:*

NRC's animal house provided 42 laboratory-bred Swiss female albino mice, six weeks old, and weighed around 20-25 grams. They were housed in plastic cages with white wood chips for bedding, were fed a commercial complete meal mixture and drank tap water, and were subjected to stringent lighting and temperature control ( $25 \pm 2^\circ\text{C}$ ).

### *Used Drugs:*

Nitrofurantoin: Uvamine Retard produced by Medical Union Pharmaceuticals was available in capsules (100mg) form. Nitrofurantoin is the active component. Capsules were evacuated then dissolved in distilled water (2.5ml for each capsule) then administered to mice orally via tube feeding in a concentration of 0.05 ml containing 2 mg for each mouse[19].

Spiramycin: was available as a film-coated tablet produced by Medical Union Pharmaceuticals. Tablets (704mg) were crushed then dissolved in distilled water (9ml for each tablet) to make suspension then administered orally via tube feeding in a dose of 0.05 ml containing 4 mg for each mouse [20].

### *Experimental infection:*

In a dose of 0.1 ml suspension of brain cysts, ten cysts were given to each mouse orally[21]. Assessment of anti-Toxoplasma effects of the studied drug: All mice were slaughtered and their brains were taken after the experiment (eight weeks). Each brain was halved. The number of brain cysts was counted at one-half. For histological inspection, the other half of each brain was fixed in 10% formalin and stained with hematoxylin and eosin.

### *Counting the brain cysts number:*

One-half of each brain was crushed individually in a mortar and a pestle. Brain emulsion homogenates

were created by mixing crushed brain tissue with 1 mL of 10% formalin. Using four distinct drops (25ml) placed on glass slides and examined under a bright-field microscope at a magnification of (40), the total number of cysts per mouse brain was calculated[20]. The average number of cysts in each group was then computed using the equation: cyst count in 100 µl × 10 ×2. To evaluate the pattern of cyst formation seen within the brains of *T. gondii* infected mice, the slides were left at room temperature to dry completely before being treated with methanol. Fixed air-dried films were stained for 10 minutes in absolute methanol with Giemsa stain diluted in a 1:20 ratio with water. A light microscope was used to examine the slides.

**Histopathological examination:**

Each mouse's brain tissue was fixed in 10% buffered formalin, dried in various alcohol concentrations, and cleaned with xylol, and embedded in paraffin blocks independently. H&E staining was used on tissue sections with a thickness of 4 µm. The slides were examined under a light microscope at ×100, ×400, and ×1000 magnifications for any pathological changes caused by *T. gondii*, such as necrosis and hemorrhage.

**Ethical consideration:**

The Research Ethics Committee, Faculty of Medicine, Benha University, Egypt, approved the study, and the animal experiment was done following internationally accepted standards.

**Statistical analysis**

The data was coded and entered using the Statistical Package for Social Science (SPSS) for Windows version 11.0. The data was represented using the mean and standard deviation (SD). The analysis of variance (ANOVA) approach was used to highlight statistically significant differences between the investigated groups. Student t-test used for comparing the mean number of brain cysts

of group (a) & group (b). F-test was used for comparison between groups (a, b & c). Values were judged statistically significant when P <0.05 was reached [22].

**RESULTS**

According to the findings, chronically infected mice treated with combined therapy (nitrofurantoin and spiramycin) accomplished the best results in relation to brain cyst count which was lower than the control infected group and nitrofurantoin monotherapy group. The brain cyst reduction rate in this group was higher than in the monotherapy group, and when compared to the infected control group, this difference was substantial. (G3= 60.1% and G4=79.5%).

Histopathology of the brains of *T. gondii*-infected and untreated mice (Fig. 1 & 2), exhibited extensive histopathological changes in mouse brain tissue and several large toxoplasma cysts dispersed throughout the brain parenchyma (Fig 1). Multiple localized necrosis accompanied by glia cell infiltration and perivascular cuffing with mononuclear inflammatory cells, as well as severe necrosis of neurons and neuronophagia, were also identified in the analyzed sections(Fig.2). Immature tissue cysts containing immature bradyzoites were seen associated with some necrotic neuron in the brain of mice treated with nitrofurantoin monotherapy 6 weeks post-infection for 2 weeks (Fig.3). Whereas, The brains of *Toxoplasma gondii*-infected mice treated with a spiramycin and nitrofurantoin combination for two weeks after infection showed degeneration and necrosis of certain neurons, as well as neuronophagia and periaastrocytic edema (Fig.4&5).

Table 1: Effect of nitrofurantoin monotherapy or combined therapy on the number of brain cysts in *Toxoplasma*(ME49) infected mice.

		Animal group		
		G2 a	G3 b	G4 c
Drug used & daily dose (mg/Kg)	No treatment		100mg/Kg Nitrofurantoin monotherapy six weeks post-infection	200 mg/Kg spiramycin +100 mg/Kg nitrofurantoin
Brain cyst Range	440-580	120-340	60-140	
Mean ± SD	526 ±40.05	210 ±69.44	100 ± 21.08	
Reduction rate	----	60.1%	79.5%	
Comparative study group	<b>Test of significance</b>	<b>P value</b>		



Animal group		
G2 a	G3 b	G4 c
a - b	t= 12.47	0.000*
a - c	t=29.76	0.000*
b - c	t=4.79	0.000*
a - b - c	F=23.56	0.000*

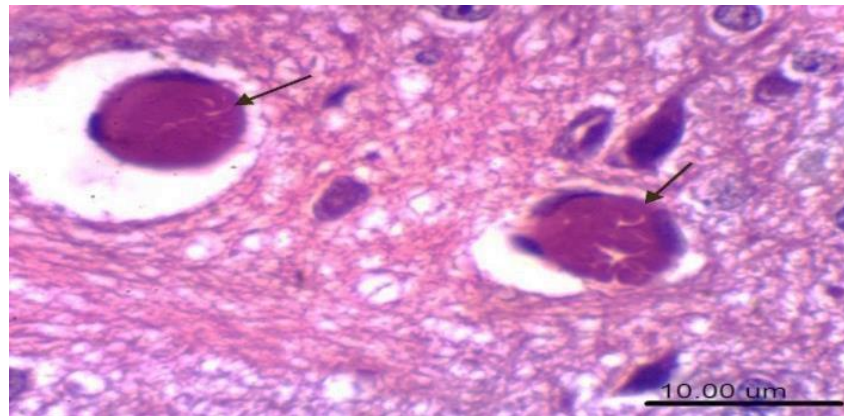


Figure 1: Infected untreated mice brain section (G2) showing mature well defined toxoplasma cysts (H&E, scale bar 25um) (X400).

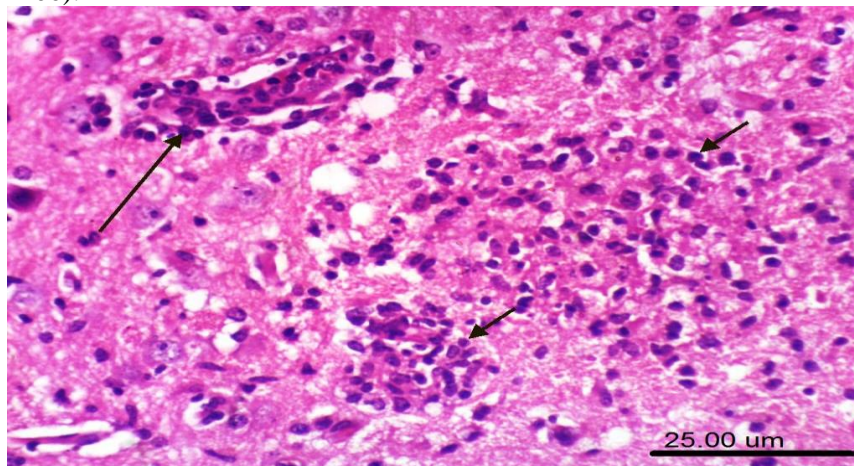


Figure 2: Infected untreated mice brain section (G2) showing perivascular cuffing(long arrow)and numerous localized necrosis coupled with glial infiltration(short arrow) (H&E, scale bar 25um).

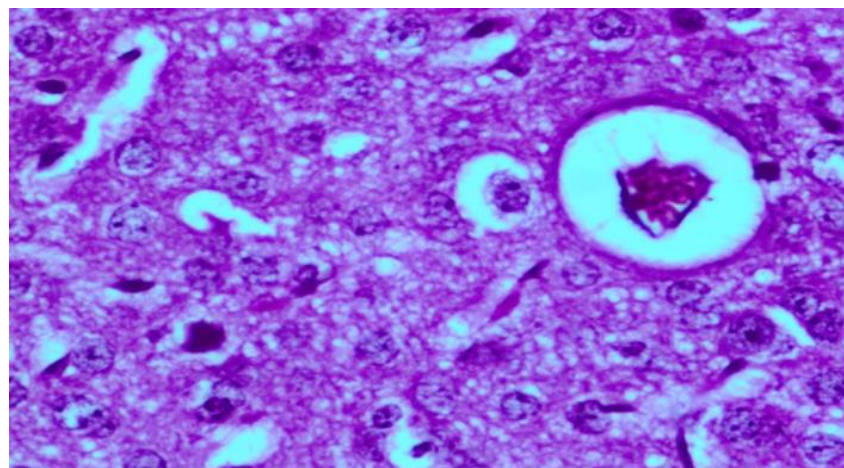


Figure 3: *Toxoplasma* infected mice brain section of nitrofurantoin monotherapy group (G3) showing immature tissue cyst containing immature bradyzoites associated with some necrotic neuron (H&E stain)( X 400).

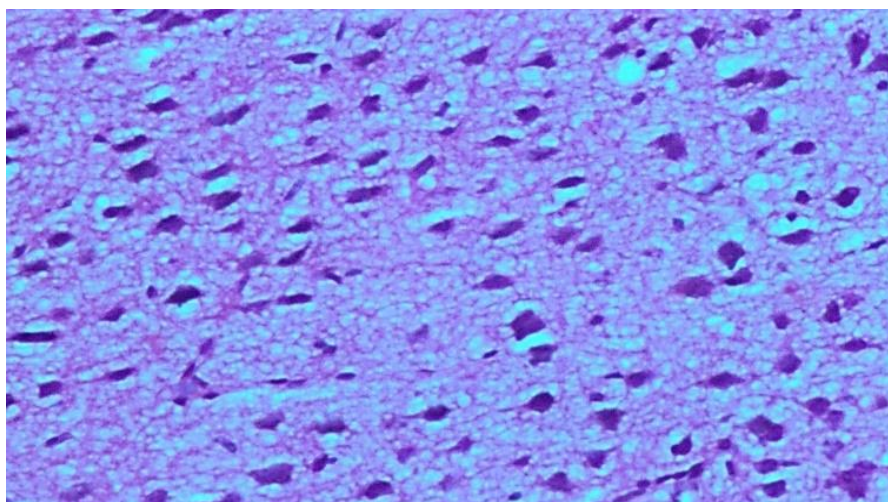


Figure 4: Toxoplasma infected mice brain section of combined drug therapy group (G4) showing periastrocytic edema with some necrotic neurons. (H&E stain)(X100).

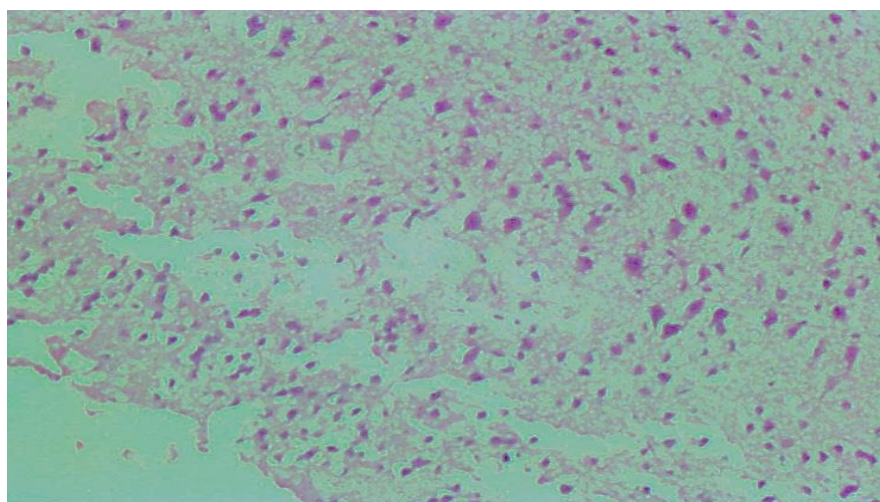


Figure 5: Toxoplasma infected mice brain section of combined drug therapy group (G4) showing degeneration and necrosis of some neurons with marked neuronophagia. (H&E stain) (X100).

#### DISCUSSION

The ineffectiveness and adverse effects of currently available antiparasitic treatments, as well as the risk of the evolution of resistant *Toxoplasma* strains, need the development of new and more effective drugs for the treatment of *Toxoplasma gondii* infection [23].

The Discovery of less toxic compounds to prevent and treat *T. gondii* would be extremely beneficial for the treatment of infections in immunocompromised patients [24]. Due to cellular immunological mechanisms that manage the process, cysts can stay in host tissues for years without generating any local inflammatory response, according to a previous study. If the balance between the host immune responses and the parasite is broken, cyst rupture and parasite proliferation can ensue, leading to clinical reactivation [3].

In this study, we assessed the therapeutic

antitoxoplasmic effect of nitrofurantoin in chronic toxoplasmosis which was mentioned before to have antitoxoplasmic action in vitro and in vivo in the acute stage in some handful of studies [18, 25]. Including classic mainstay antitoxoplasmic treatment spiramycin, we designed a versatile drug regimen to explore the synergistic activities mentioned in the material and methods section.

Our study revealed that the brain cyst reduction rate was higher in group 4 treated with a combination of spiramycin and nitrofurantoin compared with the nitrofurantoin monotherapy group (79.5% versus 60, 1%), most likely due to the synergistic impact.

In this study, nitrofurantoin exhibited significant activity against *T. gondii* on experimentally infected mice compared to the infected control group. This is consistent with Yeo et al.[25], who investigated the in-vitro and in-vivo anti-parasitic effect of nitrofurantoin against *T. gondii*(RH



strain), finding a significant reduction in *T. gondii* induced serum ALT and AST levels, as well as a significant effect on the antioxidant status indexes, i.e., glutathione (GSH) and malondialdehyde (MDA). According to the experts, nitrofurantoin is an effective anti-*Toxoplasma gondii* drug. These measurements suggest the efficacy of nitrofurantoin against *T. gondii*, which could explain the performance superiority that tainted the results of group 4, which received a combination of spiramycin and nitrofurantoin.

In agreement with these results, other researchers found that nitrofurantoin had antiparasitic activity against other protozoa. The efficacy of nitrofurans in the treatment of trypanosomiasis was well documented. Nitrofurans work by generating free radicals, which react with molecular oxygen to form superoxide anion, hydrogen peroxide, and the hydroxyl radical [17].

According to Maddison et al. [26], nitrofurantoin's mode of action involves many reductions and oxidation processes of its nitro component, culminating in the synthesis of parasite enzymes that react with cellular macromolecules and kill the parasite. This contradicts the findings of Maldonado [27], who discovered that nitrofurans affected the parasite's blood-borne form. However, they were ineffectual in destroying the amastigote tissue form.

Multiple large toxoplasma cysts were found throughout the brain parenchyma of infected control mice (G2). Multiple focal necroses associated with glia cell infiltration and perivascular cuffing with mononuclear inflammatory cells were also seen in examined sections, as well as marked necrosis of neurons and neuronophagia with the appearance of neurofibrillary tangles. This finding was supported by Waree [28], who discovered congestion of the meninges with numerous mononuclear cells infiltrating the meninges and some cuffing of mononuclear cells around arteries in the brains of toxoplasma chronically infected mice.

In our study, infected mice were given a combination of spiramycin and nitrofurantoin showed improvement in histopathological changes, which could be due to the synergistic action of these drugs, which could be explained by nitrofurantoin's antioxidant effect and spiramycin's ability to limit protein synthesis by attaching to the 50S component of bacterial ribosomes, as well as its high bioavailability [29].

### CONCLUSION

We may conclude from the findings of this study that nitrofurantoin may have potential antitoxoplasmic activity in chronic toxoplasmosis

infection. Before the nitrofurantoin regimen is approved for human infection therapy, more study is needed to determine its efficacy against *T. gondii* on a wider scale.

### REFERENCES

1. Israelski DM, Remington JS. Toxoplasmosis in the non-AIDS immunocompromised host. *Curr Clin Top Infect Dis* 1993 ;13:322- 356.
2. Liesenfeld O, Wong SY, Remington JS. Toxoplasma in setting of AIDS Textbook of AIDS medicine 2nd ed. Merigan T. C. Jr., Bartlett J. G., and Bolognesi D. Williams & Wilkins Baltimore, Md 1998 :225-259.
3. Hunter CA ,Suzuki Y, Subauste CS ,Remington JS. Cells and cytokines in resistance to *Toxoplasma gondii*. *Curr Top Microbiol Immuno* 1996; 219:113–125.
4. Bernsteen L, Gregory CR, Aronson LR, Lirtzman R A, Brummer DG. Acute toxoplasmosis following renal transplantation in three cats and a dog. *J Am Vet Med Ass* 1999;215: 1123-1126.
5. Liu QF, Wei S, Gao L, Jiang H, Lian B, Yuan Z et al. *Toxoplasma gondii* infection in pregnant women in China. *Trans R Soc Trop Med Hyg* 2009;103:162-166.
6. Montoya JG , Liesenfeld O. Toxoplasmosis. *Lancet* 2004; 363:1965-1976.
7. McCabe RE. Anti-toxoplasma chemotherapy, Toxoplasmosis: a comprehensive clinical guide. In D. H. M. Joynton, and T. G. Wreghitt (ed.) Cambridge University Press, Cambridge, United Kingdom 2001:319-359.
8. Al-Zanbagi NA. Effectiveness of myrrh and spiramycin as inhibitors for *Toxoplasma gondii* tachyzoites in vivo. *Mansoura J Forensic Med Clin Toxicol XV* 2007:117–128.
9. Araujo FG, Remington JS. Recent advances in the search for new drugs for treatment of toxoplasmosis. *Int J Antimicrob Agents* 1992; 1:153–164.
10. Petersen E, Schmidt DR. Sulfadiazine and pyrimethamine in the postnatal treatment of congenital toxoplasmosis: what are the options? *Expert Rev Anti Infect Ther* 2003; 1:175–182.
11. Serranti D, Buonsenso D, Valentini P. Congenital toxoplasmosis treatment. *Eur Rev Med Pharmacol Sci* 2011; 15:193–198.
12. Oz HS. Novel synergistic protective efficacy of atovaquone and diclazuril on fetal-maternal toxoplasmosis. *Int J Clin Med* 2014; 5:921–932.
13. Wei S, Daniel BJ, Brumlik MJ, Burow ME, Zou W et al. Drugs designed to inhibit human p38 mitogen-activated protein kinase activation treat *Toxoplasma gondii* and *Encephalitozoon cuniculi* infection. *Antimicrob Agents Chemother* 2007; 51:4324–4328.
14. Rixt AW, Angela H, Birgit CPK, Johan WM, Anouk EM. Review of the pharmacokinetic properties of nitrofurantoin and nitroxoline. *J Anti microb Chemother* 2018; 73(11): 2916–2926.

15. Gleckman R, Alvarez S, Joubert DW. Drug therapy reviews: Nitrofurantoin, Am J Hosp Pharm 1979; 36(3):342-51.
16. McOsker CC, Fitzpatrick PM. Nitrofurantoin: mechanism of action and implications for resistance development in common uropathogens. J Antimicrob Chemother 1994; 33:23-30.
17. Anand N , Sharma S . Approaches to Design and Synthesis of Antiparasitic Drugs. Pharmacology Library ,Elsevier Science & Technology 1997; 25: 258-272.
18. Abdallah KF, Saleh MH, Kishik SM, Ali BT, El Kholy AA. Assessment of nitrofurantoin efficacy on treatment of murine model of toxoplasmosis BJAS 2020; 5(2):253-256.
19. Djurković-Djaković O, Milenković V, Nikolić A , Bobić B , Grujić, J . Efficacy of atovaquone combined with clindamycin against murine infection with a cystogenic (Me49) strain of *Toxoplasma gondii*. J Antimicrob Chemother 2002; 50: 981-987.
20. Grujić J, Djurković-Djaković O, Nikolić A, Klun I, Bobić B. Effectiveness of spiramycin in murine models of acute and chronic toxoplasmosis. Int J Antimicrob Agents 2005; 25(3): 226-230.
21. El-Sayed, N.M. , Aly EM. *Toxoplasma gondii* infection can induce retinal DNA damage: an experimental study. Int J Ophthalmol 2014;35: 431-436.
22. Brink, D. Essentials of statistics, Brink D(ed), ventus publishing APS: Frederiksberg Denmark, 2nd ed 2010:1-103.
23. El-Sayed NM, Safar EH . A Brief Insight on Anti-*Toxoplasma gondii* Activity of Some Medicinal Plants. Aperito J Bacteriol Virol Parasitol 2014; 1:107.
24. Gomes TC, Andrade-Júnior HFD, Lescano SAZ, Amato-Neto V. Ação in vitro de drogas antiparasitárias, especialmente artesunato, contra *Toxoplasma gondii*. Revista da Sociedade Brasileira de Medicina Tropical 2012; 45(4):485-490.
25. Yeo SJ, Jin C, Kim S, Park H. In vitro and in vivo effects of nitrofurantoin on experimental toxoplasmosis. *Korean J Parasitol* 2016; 54(2), 155.
26. Maddison JE, Page SW, Church DB. Small animal clinical pharmacology. Elsevier Health Science 2008;5: 198-206.
27. Maldonado YA. Less common protozoan and helminth infections. In Infectious Diseases of the Fetus and Newborn. WB Saunders 2011:1042-1054.
28. Wares CF. TNF-related cytokines in immunity. In: Paul, W.E.(ed.) Fundamental immunology. 6th ed. Philadelphia: Lippincott Williams and Wilkins 2008:776-803.
29. James SMC, Louis VK. Drugs for Protozoal Infections Other Than Malaria, Mandell, Douglas, and Bennett's Principles and Practice of Infectious Diseases 2015; 1: 510-518.

#### To Cite

Abdallah, K., saleh, M., kishk, S., barakat, A., Ali, B., elkholy, A. A new approach in treatment of chronic murine models of toxoplasmosis using nitrofurantoin antibiotic.. *Zagazig University Medical Journal*, 2022; (1169-1175): -. doi: 10.21608/zumj.2022.112316.2440