



EGYPTIAN ACADEMIC JOURNAL OF
BIOLOGICAL SCIENCES
ZOOLOGY

B




ISSN
2090-0759

WWW.EAJBS.EG.NET

Vol. 14 No. 1 (2022)

www.eajbs.eg.net



The Immunomodulatory Role of Curcumin and Its Nanoparticles in Mice Testis Exposed to N, N'-Methylenebisacrylamide

Mona M. Atia¹, Hanem S. Abdel-Tawab¹, Amna M. Mostafa² and Seham A. Mobarak² *

1- Laboratory of Molecular Cell Biology and Laboratory of histology, Zoology Department, Faculty of Science, Assiut University, 71516, Egypt

2- Department of Zoology, Faculty of Science, South Valley University, Qena.

E.mail*: seham.ali@sci.svu.edu.eg

ARTICLE INFO

Article History

Received:22/12/2021

Accepted:14/1/2022

Available:16/1/2022

Keywords:

Acrylamide, Curcumin, Nano-Curcumin, serum protein fraction and Testis.

ABSTRACT

Mice's reproductive system, endocrine glands, and central nervous system are all toxic and carcinogenic when exposed to acrylamide (AC). The goal of this study is to show how Nano-curcumin differs from Curcumin in minimizing the effects of acrylamide in male mice. The mice were divided into five groups: control, control (Tween-80), Acrylamide (AC) group, AC+ Curcumin (Cur), and AC +Nano-curcumin (N.Cur). An increase in Caspase-3 in the testis was induced in the AC treated group. AC decreased albumin, IgG, and antitrypsin while increasing blood protein fractions like plasma transferrin. In addition, AC increases the amount of total white blood cells and neutrophils in the CBC while decreasing lymphocytes, RBC, and hemoglobin levels. The effects of N.Cur and Cur were reversed, and several severe histopathological alterations. N.Cur and Cur also reduced the amount of collagen fiber and the percentage of fibrosis in male mice generated by AC and corrected the AC-induced glycogen depletion. Finally, the efficiency of Nano curcumin can reduce the detrimental effects of acrylamide in the testis of mice.

INTRODUCTION

Acrylamide (AC) is an organic molecule with a small size found in a solid form at normal pressure and temperature. International Cancer Agency classified acrylamide as a “probable carcinogen” and in April 2002, studies declared that carbohydrate-rich food and low in protein produce large amounts of AC when cooked at high temperature for example frying and baking (Pan *et al.*, 2018).

Acrylamide is an unsaturated amide, with very high-water solubility. After ingestion of AC by animals or humans, it was absorbed and distributed into various vital organs such as; the heart, brain, liver, kidney, and thymus (Hu *et al.*, 2014). AC is known as a reproductive, neurotoxicant toxicant, and carcinogen in animals (Pundir *et al.*, 2019).

AC-induced toxicity is linked with oxidative stress and long-time exposure to AC induced mitochondrial decline and lastly resulted in apoptosis according to (Kandemir *et*

al., 2020). The balance between pro-apoptotic and anti-apoptotic proteins plays a critical function in cell survival. Cell death is linked to an increase in apoptotic proteins (Zheng *et al.*, 2016). Caspases, one of the variables regulating apoptosis, play a key part in this process known as programmed cell death (Hamdy *et al.*, 2017; Cantrell and McDougal, 2021).

Curcumin showed anti-inflammatory, antioxidant, and immunomodulatory properties, illustrating the possible therapeutic effects of curcumin as a treatment for inflammations, oxidative stress, and immune diseases (Memarzia *et al.*, 2021). Cur's antioxidant activity seems to be mediated by an ability to both scavenge ROS and activate endogenous antioxidant mechanisms that reduce the cellular levels of ROS (Castaño *et al.*, 2019).

Previous studies showed that curcumin has poor absorption and rapid metabolism, leading to low bioavailability of Cur. So, many types of nanocarriers of Cur have been studied to improve its bioavailability (Wang & Chen, 2019). Nanomedicine significantly improved the delivery of drugs, diagnosis, and treatment of many diseases (Wilson & Geetha, 2020). Nanotechnology can improve the effects of curcumin and increase its bioavailability and solubility to reach a specific organ and be able to cross biological barriers (Araya-Sibaja *et al.*, 2021; Patnaik *et al.*, 2021).

Our study goal is to Compare Cur and N.Cur in decreasing the harmful effects of AC in the testis of mice by histopathological, and immunohistochemical evaluations.

MATERIALS AND METHODS

Acrylamide and Curcumin (Sigma-Aldrich), mouse anti-cleaved caspase-3, goat anti- β -actin IgG, and mouse anti-goat IgG-HRP were purchased from Santa Cruz Biotechnology (Dallas, TX, USA). All additional materials were purchased from local providers with the highest analytical grade.

Ethical Statements:

This study was carried out in strict accordance with the guidelines of the National Health and Medical Research Council for the Care and Use of Animals. The Ethical Research No. in Qena university (12/23.05.2021).

Preparation of Bis-Acrylamide:

Acrylamide was weighed and dissolved immediately just prior to use in distilled water (Kumar *et al.*, 2018).

Preparation of N.Cur:

100 mg Cur powder was dissolved in 20 ml dichloromethane to make a Cur solution (5 mg/ml). N. Cur was synthesized as reported and the pellet was dissolved in 2% Tween80 solution (Rezayat, 2018).

Characterization of N.Cur:

TEM and Optical Properties:

A TEM was used to observe the size and the morphology of the N.Cur (Faculty of Science, Assiut University). Also, the Optical properties by using UV-visible spectroscopy analysis were determined (Abdellah *et al.*, 2018).

Particle Size and Zeta Potential:

Malvern Zetasizer ZS (Malvern Instruments, UK, Nawah Scientific Egypt) was used to measure the sizes and surface zeta potentials of the N.Cur. determined by dynamic light scattering (DLS) (Hanna & Saad, 2020).

Animal Experimental Design:

Male Swiss albino mice (*Mus musculus*) (N=50) weighing 25-30 gram were divided into five groups.

- Group (I) as control received distilled water.
- Group (II) as control received tween-80.
- Group (III) as AC oral administration; they were given an oral dose of (3 mg/kg) (Rezayat, 2018).
- Group (IV) as (AC+ Cur) and Group (V) as (AC+ N. Cur); mice administered oral doses of curcumin and nano curcumin (7 mg/kg) (Afolayan *et al.*, 2018) 30 min before administration of acrylamide. The doses were administered daily for four weeks

Immunohistochemistry Detection:

The deparaffinized tissue slices were rehydrated, followed by antigen retrieval in 10 mM sodium citrate buffer pH 6.0, blocking solution, and overnight treatment with mouse anti-C-casp.3. After that, the slides were incubated in a secondary antibody for two hours. The sections were then washed and stained with 3, 3'-diaminobenzidine (DAB), followed by hematoxylin counterstaining (Paxinos & Franklin, 2019).

Serum Protein Fractions Estimation:

After spinning at 5000 rpm for 5 minutes to recover serum samples from clotted blood, the concentration of total serum protein was determined. SDS-PAGE was used to separate 20 g of serum proteins, and the gel was stained with Coomassie blue then being destained with 40 percent methanol and 10% acetic acid. The optical density of each band was calculated using ImageJ software. The mean S.E. of at least three independent experiments is used to represent the data.

Complete Blood Count (CBC):

The examination of CBC (platelets count, red blood cells count (RBCs), leukocytes count (WBCs), total hemoglobin (HB) and hematocrit (HCT) assays) done by Automated Hematology Analyzer (Diff3) Mek-6410/Mek-6420 (Brantxt *et al.*, 1965).

Histopathological Examination:

Sections of the testis were fixed in 10% neutral buffered formalin pH 7.2, dried, cleaned in xylene, and embedded in paraffin for histological and histopathological investigations. The samples were stained with hematoxylin and eosin, Picrosirius Red Staining Protocol (Courtoy *et al.*, 2020), and Periodic acid Schiff (PAS) technique. Degeneration, cytoplasmic colour fading, nuclear condensation, nuclear fragmentation, and inflammation are the five histological parameters of the testis that were studied (Heijnen *et al.*, 2003). For morphometric analysis to measure the collagenous fiber in the testis, Fibrosis percentage % quantification is as follows: $\text{Fibrosis percentage \%} = \frac{\text{Total positive area}}{\text{Total section area}} \times 100$ (Bataller *et al.*, 2003; Wang *et al.*, 2007).

Statistical Analysis:

One-way analysis of variance (ANOVA) was used, followed by the student Newman-Keuls T test, using the software Graph Pad Prism 3 (Graph Pad Software Inc., USA).

RESULTS

DLS and Optical Properties of N.Cur:

The hydrodynamic diameter was used to determine the Size Distribution and Zeta Potential (Dynamic light scattering) for N.Cur (Fig. 1a). The absorbance N.Cur was calculated as shown in (Fig. 1b), with a peak at 432 nm.

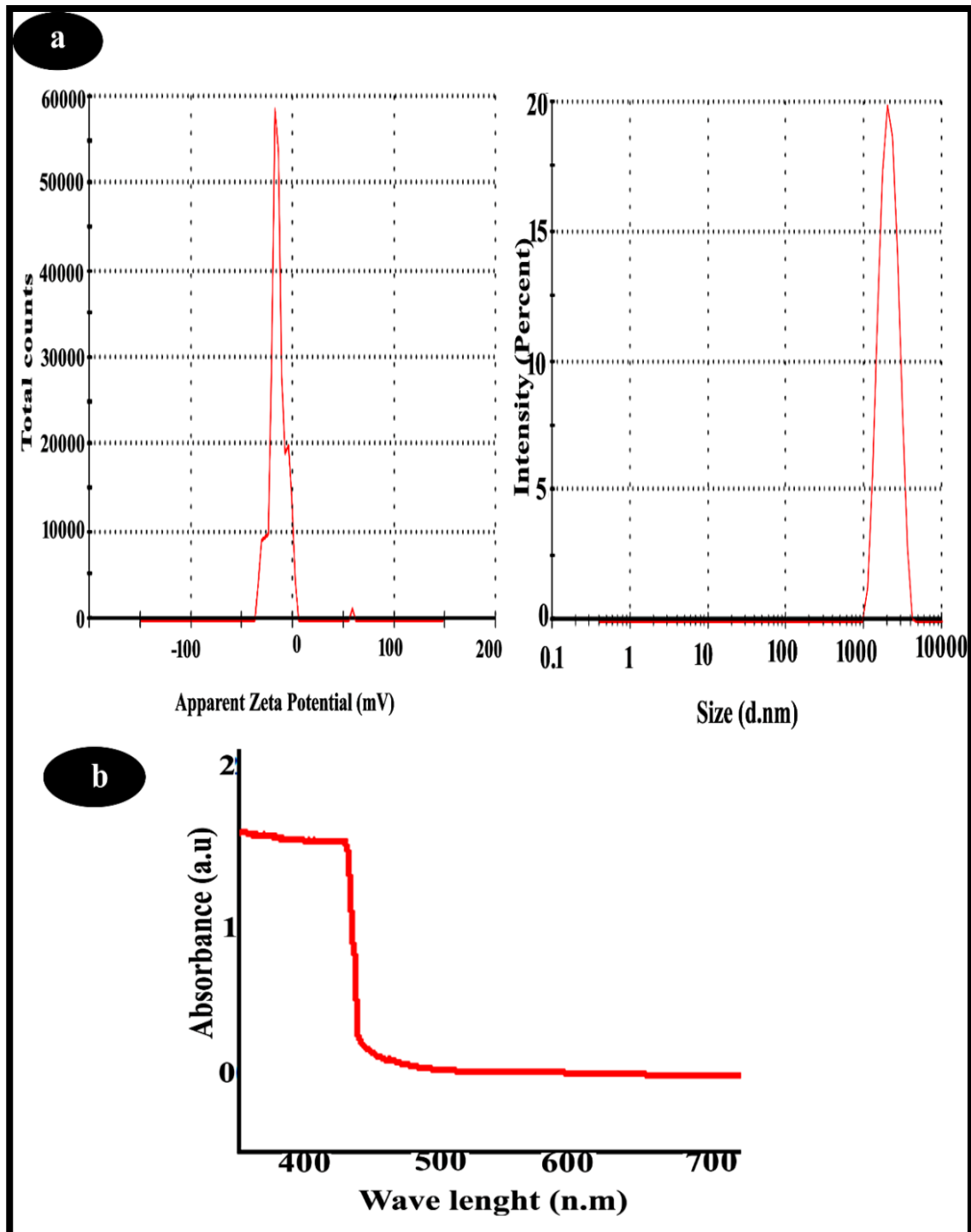


Fig. 1. (a) The measurements of the zeta potential and the mean particle diameter and (b) Optical absorption properties.

Bodyweight:

The administration of AC decreased (23.8%) the bodyweight of male mice versus those of control mice. While pretreatment of Cur and N.Cur groups increased body weight (28.72%) and (32.47%) respectively, versus those of AC group (Fig. 2).

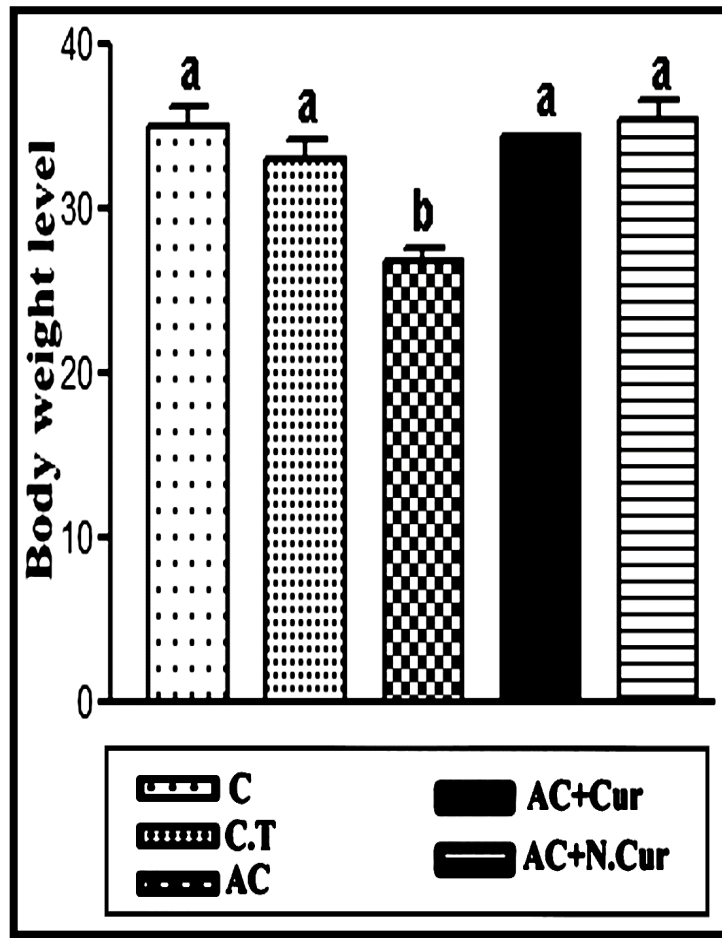


Fig. 2: The effects of different treatments on body weight mean value and \pm SEM of male mice. Values in the same column with unlike superscript signs are significantly different at $P < 0.001$.

Detection of Cleaved Caspase 3 by Immunohistochemistry:

IHC technique used to investigate staining intensity of c. casp.3 expression, the present study revealed no brown patches in the vast majority of testis indicating negative expression for c. casp 3 level staining in control mice (Fig. 3a). Furthermore, there was a variable increase in localization of brown patches in the testis of AC group (Figs. 3b) which indicates the up-regulation (153.4%) of c. casp.3 in comparison with control (Figs. 3e). N.Cur (Figs. 3d) co-treatment had significant effects in inhibiting the level of c. caspase 3 more than Cur (Figs. 3c). Noticeably, the c. casp.3 level was downregulated 47.7 % & 56.1 % in Cur and N.Cur (Fig. 3e) groups by contrast to the AC group.

The Analysis Measurement of Blood Serum Protein Fractions:

Densitometry calculation of IgG, albumin and antitrypsin levels in blood serum protein is shown in (Figs.4a & b) which revealed that; administration of AC significant decreased the previous protein levels (53.91 %, 55.79 % & 80.68%) respectively, versus those of its level of control mice. When Cur and N.Cur were given to AC treated mice, IgG, albumin and antitrypsin levels were significantly increased (57.64 %, 68.59 % & 307.7%) and (166.46 %, 93.63 % & 382.4 %) respectively, compared to AC group. In contrast, AC administration significantly increased the transferrin level (169.84%) but Cur and N.Cur were given to AC treated mice, its levels were significantly decreased (51.60 % & 35.52%) respectively, compared to AC group.

Complete Blood Count (CBC):

The effect of AC on mice blood significantly increases total WBCs, neutrophils, eosinophils, monocytes, MCV, MCH and MCHC levels compared to the control mice. Whereas AC experimental group recorded significantly decreased lymphocytes, RBCs, hematocrit, HB and platelets levels compared to the control mice. Co-administration with Cur and N. Cur decreased or increase the CBC parameters. The present results revealed that N. Cur was more effective than Cur in reducing the damages of CBC induced by AC (Table 1).

Table 1: Complete blood count (CBC) values, expressed as percentage \pm mean, evaluated in four different groups of male mice (Group 1 – Control (C); Group 2 - AC; Group 3 – AC+ Cur and Group 4; – AC+ N.Cur).

	Control	AC vs. Control %	AC+ Cur vs. AC%	AC+ N. Cur vs. AC%
TWBCs	4.23 a	100.02 % \pm 8.47 \uparrow b	53.55 % \pm 5.47 \downarrow a	35.43 % \pm 3.93 \downarrow a
Neutrophils	6.65 a	136.09 % \pm 15.70 \uparrow b	22.93 % \pm 13.27 \downarrow a	15.47 % \pm 12.10 \downarrow a
Eosinophils	0.27 a	787.5 % \pm 2.37 \uparrow b	21.12 % \pm 2.00 \downarrow b	15.5 % \pm 1.87 \downarrow b
Lymphocytes	87.65 a	18.92 % \pm 71.07 \downarrow b	3.49 % \pm 77.65 \uparrow a	9.26 % \pm 73.55 \uparrow b
Monocytes	5.70 a	45.6 % \pm 8.30 \uparrow a	19.88 % \pm 6.45 \downarrow a	22.29 % \pm 6.65 \downarrow a
RBCs	6.81 a	25.70 % \pm 5.06 \downarrow b	73.12 % \pm 8.76 \uparrow a	54.45 % \pm 7.82 \uparrow a
MCV	38.5 a	7.45 % \pm 41.37 \uparrow a	9.16 % \pm 37.58 \downarrow a	6.21 % \pm 38.80 \downarrow a
MCH	14.45 a	8.44 % \pm 15.67 \uparrow a	12.57 % \pm 13.70 \downarrow a	7.79 % \pm 14.45 \downarrow a
MCHC	37.70 a	7.08 % \pm 40.37 \uparrow b	9.04 % \pm 36.75 \downarrow a	7.60 % \pm 37.30 \downarrow a
HCT	29.40 a	20.51 % \pm 23.37 \downarrow b	40.14 % \pm 32.75 \uparrow a	30.08 % \pm 30.40 \uparrow a
HB	12.17 a	26.87 % \pm 8.90 \downarrow b	34.83 % \pm 12.00 \uparrow a	28.09 % \pm 11.40 \uparrow a
Platelets	962 a	71.73 % \pm 272 \downarrow b	53.68 % \pm 418 \uparrow c	131.99 % \pm 631 \uparrow c

Histopathological Examination:

Testis sections from control mice exhibited typical normal testis architecture as revealed by HE staining Fig. 5a (1 &2), while AC treatment showed an irregular testicle outline of the seminiferous tubules. Many degenerating and apoptotic germ cells were observed. The basement membrane was thickened and irregular. The interstitial cells of leydig had scanty cytoplasm with deeply stained or normal vesicular nuclei, a reduction in the number of the spermatogonial cells, large vacuolations between the inner cells and reduced leydig cells Fig. 5b (1 &2). Pretreatment with Cur showing approximately regularly arranged tubules and spermatogenesis, normal spermatogonia, normal primary spermatocytes and sertoli cells with few attached mature sperms. The interstitial cells of leydig had scanty cytoplasm and deeply stained or normal vesicular nuclei Fig. 5c (1 &2). Pretreatment with N.Cur showing highly preserved seminiferous tubules more or less like normal Fig. 5d (1 &2). Quantitative assessment using Heijnen's score confirmed that the histopathology induced by AC (200 %) vs. control was markedly decreased by Cur and N.Cur.by (44.4 % & 53.7%) compared to the AC group (Fig. 5e).

Analysis of Testis Fibrosis:

Collagen staining of picosirius red of testis sections from control mice revealed only a scanty amount of collagen fibers Fig. 6a (1 &2), while AC treatment induced marked collagen fibers (142.4 %) accumulation (Figs. 6 b1, b2 &e). Cur pretreatment reduced the deposition of collagen fibers (25%) (Figs. 6 c1, c2&e). Also pretreatment of N.Cur appear to reduce collagen fibers (53.8%) (Figs. 6 d 1,d2 &e).

PAS-analysis:

PAS-stained sections of the testis of the control mice showed intense magenta red stain in the basement membrane of the seminiferous tubules (Fig. 7a). AC showed disrupted and thickened PAS basement membrane in addition to the absence of well-

organized elongated spermatids, degeneration of epithelial lineage of the seminiferous tubules Figs 7b (1&2). In AC + Cur group the architecture of the seminiferous tubules was less preserved. Furthermore, there was a slightly corrugated PAS basement membrane Figs 7c (1&2). N.Cur co-treatment showed enhanced spermatogenesis in most of the seminiferous tubules. The tubules were surrounded by regular PAS basement membrane Figs 7d (1&2).

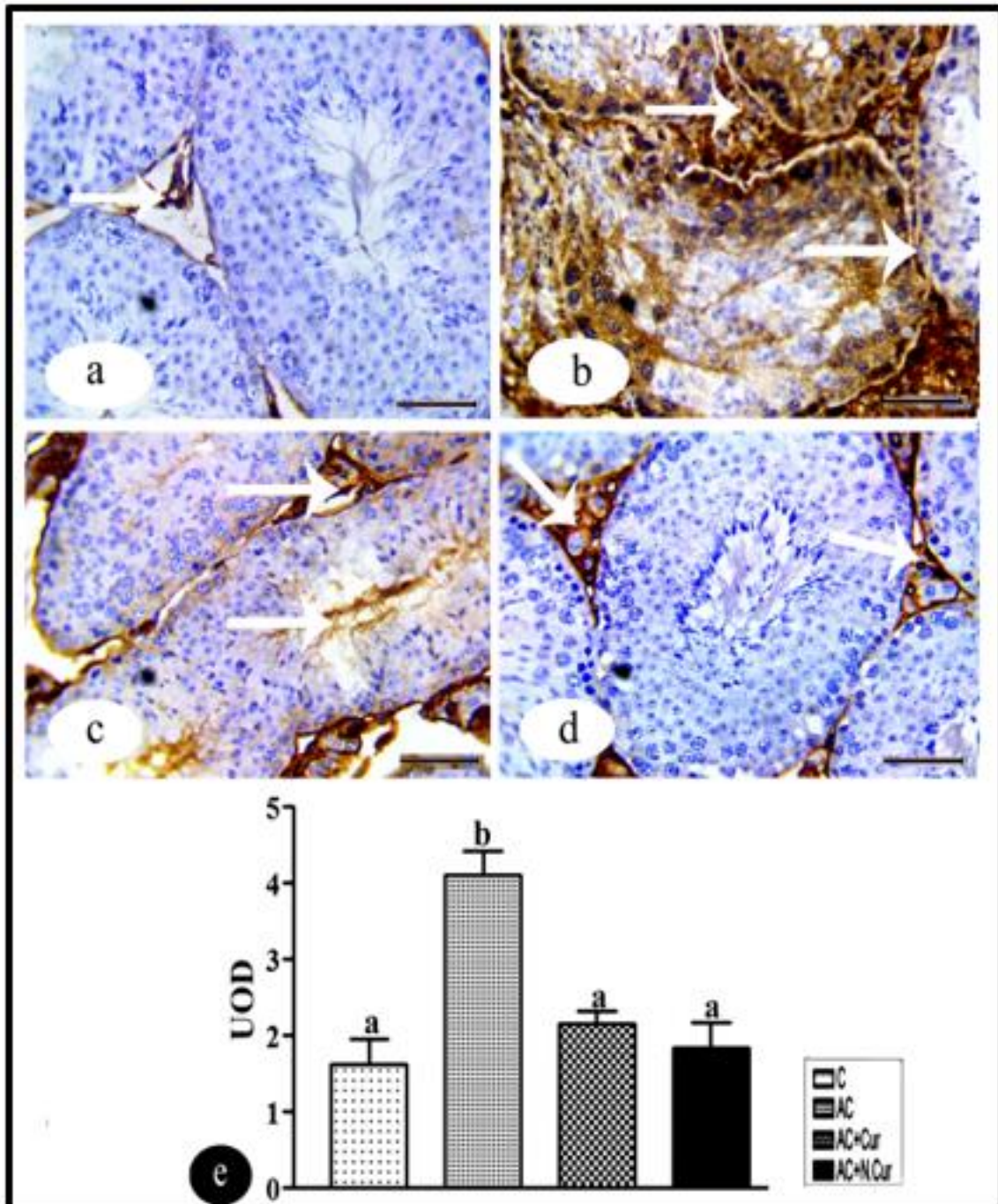


Fig. 3. IHC of c.casp.3 protein expression levels of testis in experimental groups, showing (a) control group negative reaction (arrows), (b) AC group showed positive reactions (arrows), (c) the AC+ Cur group and (d) AC+ N.Cur group had negative reactions (arrows) bar = 50 μ m. (e) Statistically, the values in the column with unlike superscript letters were significantly different ($p < 0.001$).

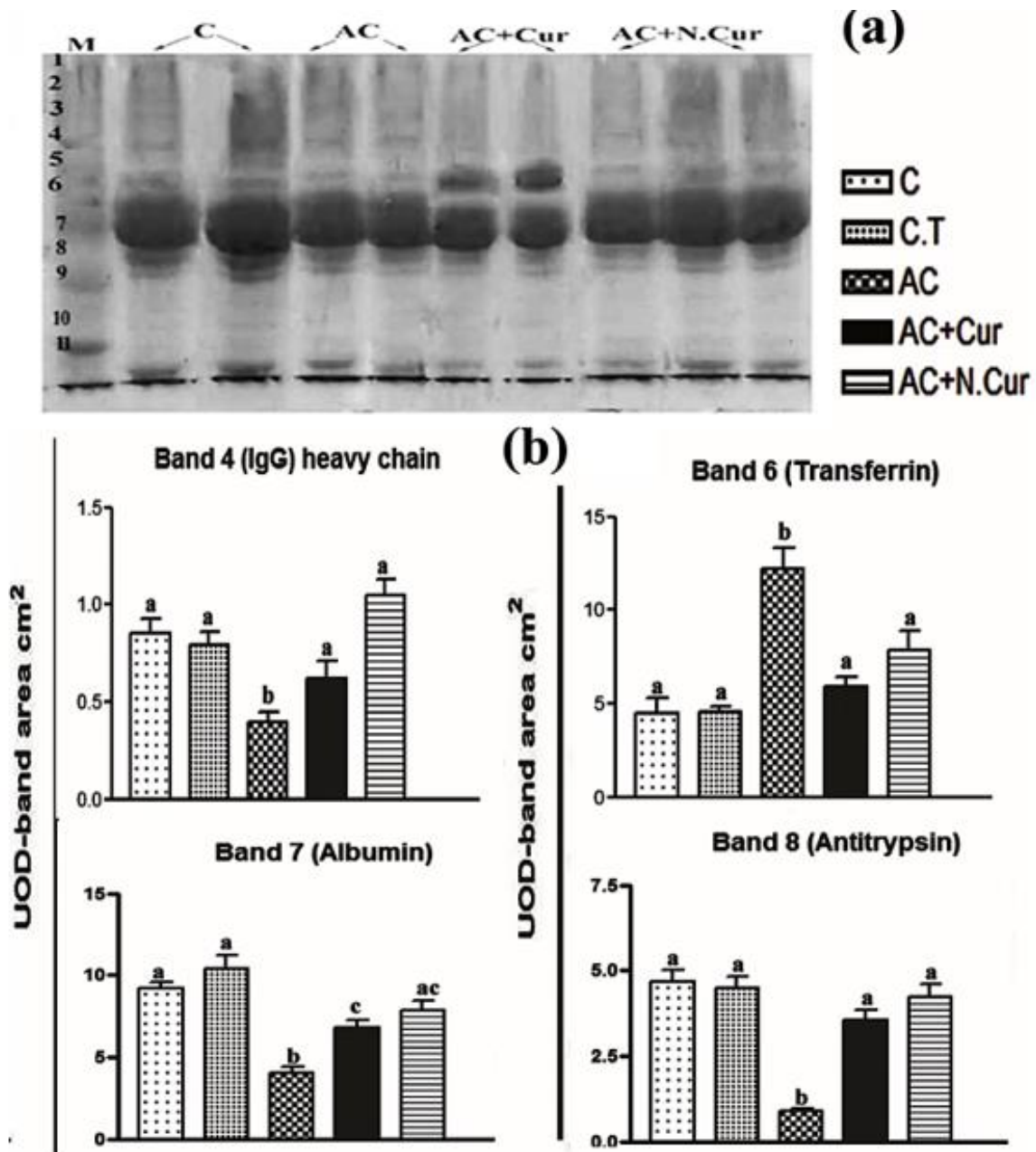


Fig. 4. (a) Serum protein electrophoresis (SPEP) of serum protein fractions of control and different treatments. As shown in the left side the pattern of major protein 4-Immunoglobulin G (168 KD), 6-transferrin (85 KD), 7-albumin (64 KD) and 8-antitrypsin (60 KD). (B) Values in the same column with unlike superscript letters are significantly different at $P < 0.001$.

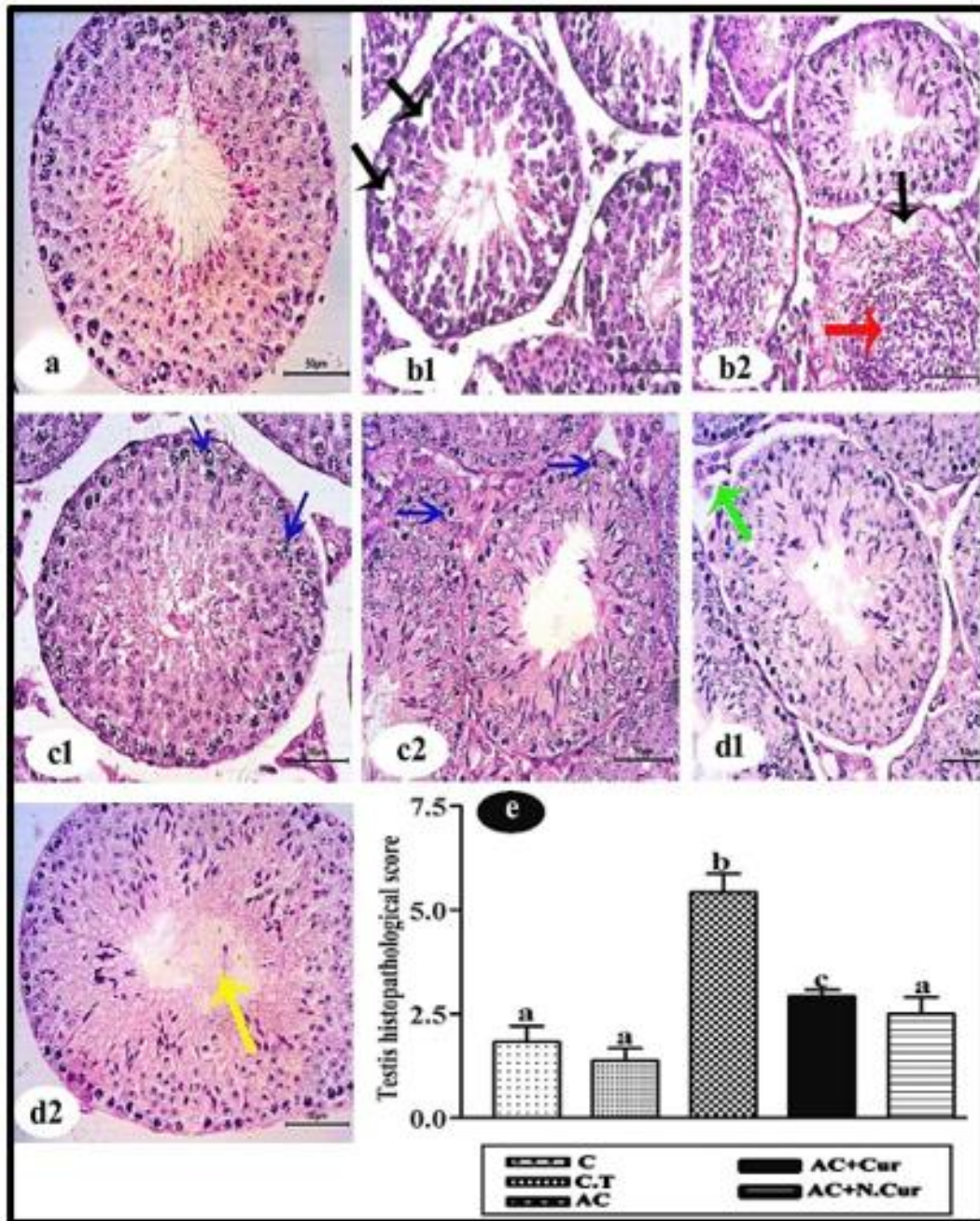


Fig. 5. Photomicrograph of HE-stained of testis sections of the different groups (a) Control: showing normal appear of testis tissue. (b1 & b2) AC group: showing an irregular testicle outline of the seminiferous tubules, large vacuolations between the inner cells (black arrow), disruption in spermatogenesis, decreasing the number of sperm, sloughing of germinal epithelium, tubules without lumen filled with cell debris and spermatocytes (red arrow). (c1&c2) AC+ Cur group: showing approximately regularly arranged tubules and spermatogenesis, while some cells have randomly dispersed chromatin (blue arrow), tubule without lumen while the other has a wide lumen. (d1&d2) AC+ N.Cur: showing nearly regular arranged tubules and spermatogenesis, reduced Leydig cells (green arrow), lumen filled with spermartogenesis more or less like normal (yellow arrow). (H&E Bar =50 μ m) and (e) Testis histopathology score was assessed in male mice for experimental groups. The data are expressed as mean \pm SE, and values of different letter are significantly different ($P < 0.001$).

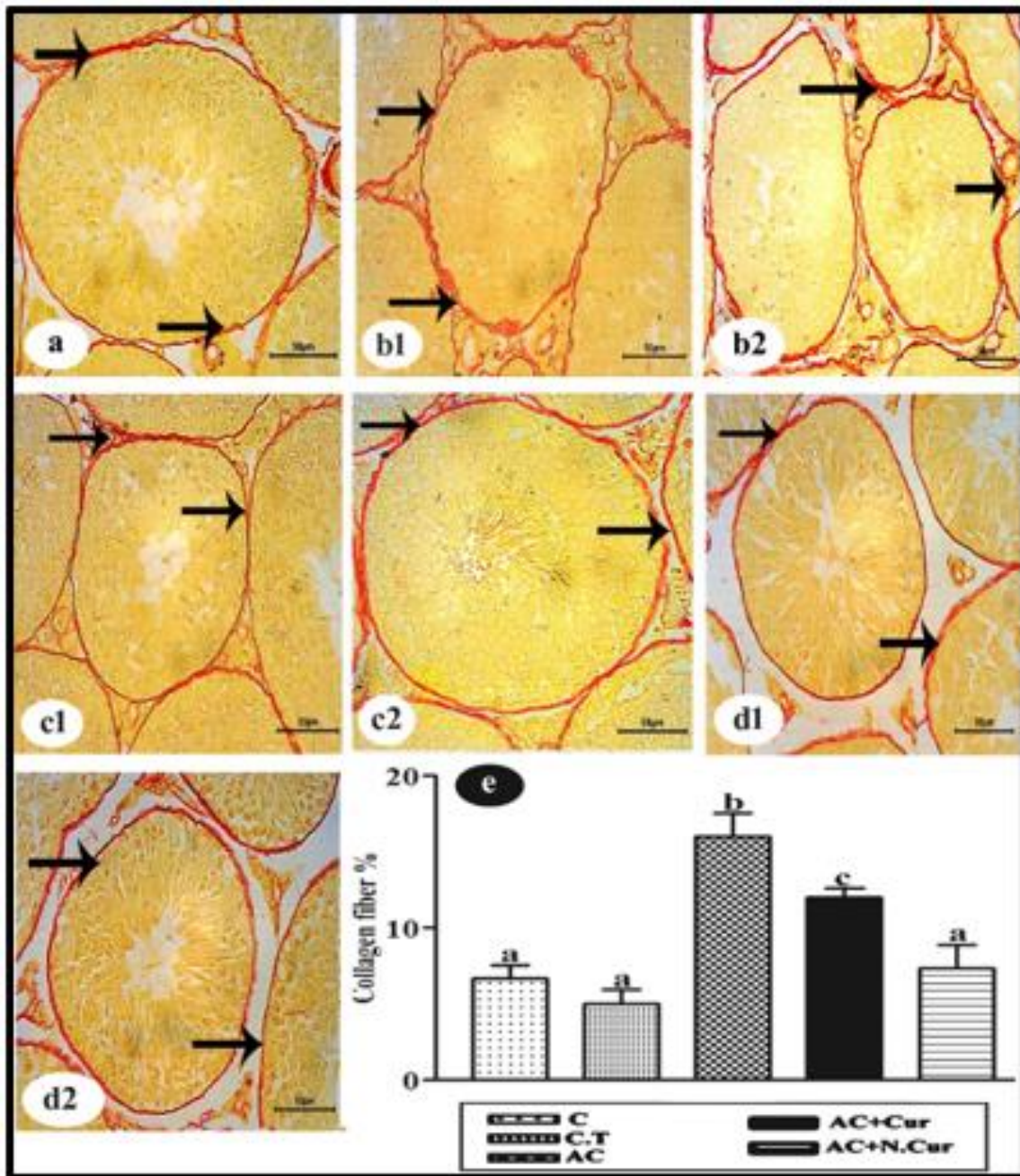


Fig. 6. (a): high microscopic force of the testis of control male mice, showing minimal amount of collagenous fibers (black arrows). (b1 & b2): AC group showed large amount of collagenous fibers (black arrows) in. (c1&c2): AC+ Cur group reduced the amount of collagenous fibers and (d1&d2) AC+ N.Cur group decreased the amount of collagenous fibers (picosirrus stain Bar =50 μ m) and (e) The percentage testis fibrosis score was assessed and the column with different letter are significantly different (P<0.001).

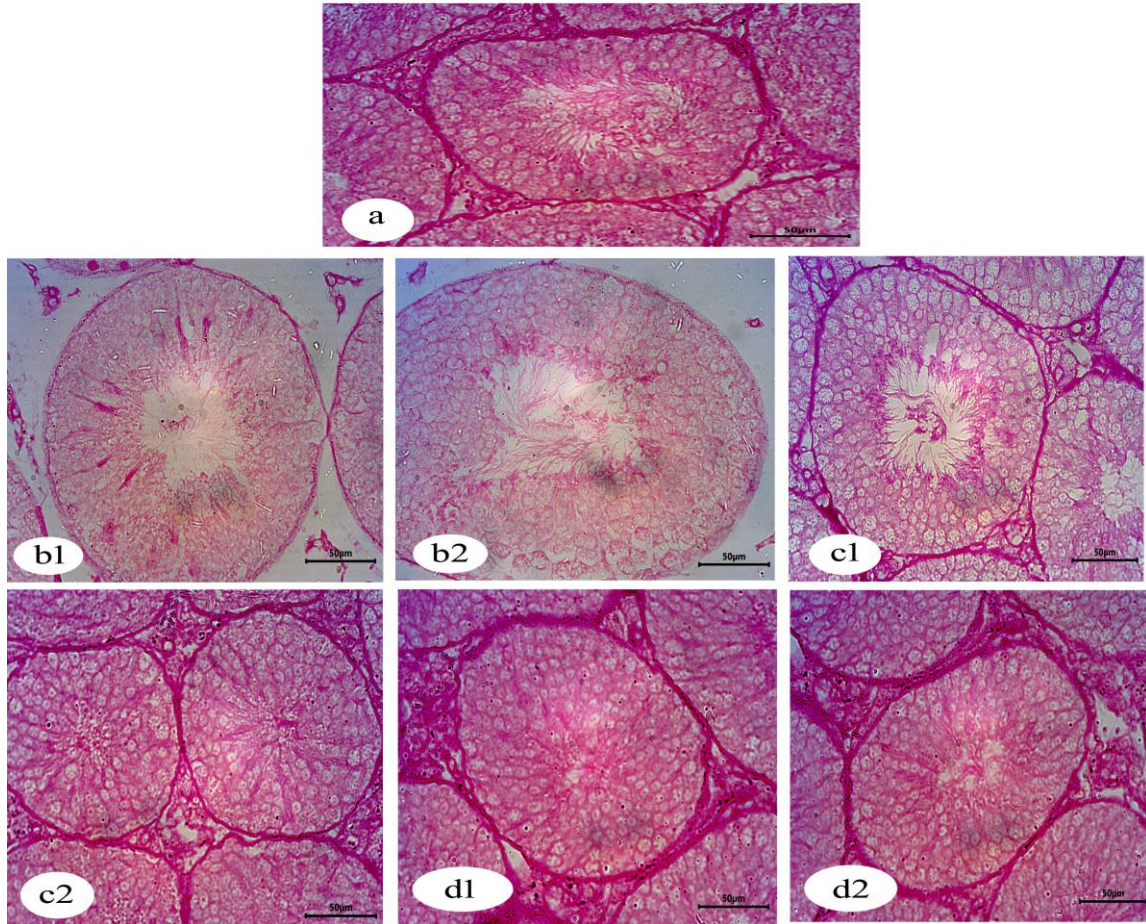


Fig. 7. (a): high microscopic force of the testis of control male mice, showing normal amount of carbohydrates, (b1 & b2): AC group, showing a decrease in the carbohydrate contents (c1&c2): AC+ Cur group, showing improvement of carbohydrate contents and (d1&d2) AC+ N.Cur group, showing similarity to the control (PAS stain Bar =50 µm)

DISCUSSION

In the current work, acrylamide significantly reduced the body weight of male mice and this resulted from protein and growth deficiencies. That may be due to malnutrition, or decrease in plasma and tissue proteins, or by the toxicity induced by AC in agreement with (Rawi *et al.*, 2012); (Wei *et al.*, 2014) and (Ghorbel *et al.*, 2015). N.Cur increased the bodyweight more than Cur that has great antioxidant and antitoxic effects in agreement with (Guo *et al.*, 2020). The higher solubility of N.Cur more than Cur is the reason for its improvement and weight gain according to (Liu *et al.*, 2013). Our results in accordance with (Mahjoob & Stochaj, 2021) suggested that nano particles-mediated delivery elevates curcumin concentrations in body fluids.

Acrylamide long exposure induced oxidative stress leading to mitochondrial decline and finally apoptosis to (Kandemir *et al.*, 2020). Yilmaz *et al.*, (2017) reported in an in vivo study that acrylamide expressed a high level of c.casp 3 in testis as compared to control in agreement with our study results, this is due to the toxic damage in spermatogenesis induced by AC that leads to germ cells apoptosis. Germ cells apoptosis may also cause a decrease in spermatogenic cells (Vardi *et al.*, 2009; Roshankhah *et al.*, 2019; Salahshoor *et al.*, 2016).

As an antioxidant, curcumin reduced the content of the c.casp 3 in the testis of

male mice in agreement with Mohammed *et al.*, (2021), and in vitro (Qin *et al.*, 2014). Cur induced a decrease in oxygen free radicals leading to an indirect decrease in ROS thus downregulating the expression of c.casp 3 according to Alhusaini *et al.*, (2018). Nano-curcumin possesses a beneficial bioactive property, upregulating Bax (proapoptotic) and downregulating Bcl-2 (anti-apoptosis) this according to (Pistritto *et al.*, 2016). Our study findings showed that N.Cur decreased c.casp 3 more than cur proving that N.Cur improved the spermatogenesis in agreement.

Our study findings, AC increased WBCs, neutrophils, monocytes, eosinophils, MCV, MCH and MCHC levels; this suggests nutritional impairment and presence of inflammation in organs, as an indicative of immune system activation by Acrylamide (Gonda *et al.*, 2017; Belhadj *et al.*, 2019; Grzybowska & Snarska, 2021).

On the contrary, acrylamide significantly decreased RBCs and HB values, (Ghorbel *et al.*, 2015) and (Ghadhban *et al.*, 2021) reported that AC toxicity can damage RBCs membrane and decrease its hemolytic resistance which indicated the occurrence of microcytic anemia, due to an increase in the destruction rate of RBCs, which take place in hemopoietic organs. AC is electrophilic and covalently binds to the cysteine residues and forms adducts with sulfhydryl groups on HB resulting in the loss of heme part of HB molecules, decreased HCT, and lymphocyte (Lal *et al.*, 2011; Rawi *et al.*, 2012; Hammad *et al.*, 2013), and PLTs (Belhadj *et al.*, 2019).

Cur treatment in our result showed an inflammatory effect according to various studies and improves the immune system from many immune disorders. Our results are in agreement with many studies, that appeared cur. decreased WBCs, neutrophils, and monocytes (Memarzia *et al.*, 2021), eosinophils, MCV, MCH (Jantawong *et al.*, 2021) and MCHC levels. Cur significantly increased RBCs, HB, PLTs, and HCT in agreement with (Manju *et al.*, 2013 and Hussain *et al.*, 2017).

In the existent study, our results suggested in agreement with Afolayan *et al.*, (2018) the bioavailability and controlled release of N.Cur could be responsible for the increase in humoral and cellular immune responses due to decreasing WBCs, neutrophil, monocytes, eosinophils, MCV, MCH and MCHC levels. While our results showed lymphocytes, RBCs, haemoglobin, HCT and Platelet levels were increased in the N.Cur group confirms its greater immunomodulatory potential according to (Afolayan *et al.*, 2018).

Our histopathological results of the testis administrated with the acrylamide showed various degenerations of spermatogonia, apoptosis, depletion of spermatogenic cells, reduction of Leydig cells and the epithelium of seminiferous tubules. Acrylamide histopathological changes of the testis could be explained by the production of ROS; oxidative stress affects germ cells leading to apoptosis, inhibition of cytoskeletal motor proteins proving the reproductive toxicity of AC (Hasanin *et al.*, 2018; Kalaivani *et al.*, 2018 and Wang *et al.*, 2010).

In agreement with our histopathological results, Curcumin as an antioxidant could reduce the damage of testis tissues by eliminating ROS levels induced by AC (Abdelhamid *et al.*, 2020). Cur and N.Cur help to protect cellular macromolecules including DNA from oxidative stress (Chandra *et al.*, 2010; Conti *et al.*, 2016; Pistritto *et al.*, 2016). Cur has been an effective substance in the reduction of AC toxicity in cell lines and/or animal studies. (Kahkeshani, 2015).

Administration of N.Cur as a daily supplement improved the spermatogenesis defects induced by malnutrition-treated rats (Mohammed *et al.*, 2021). Our morphometric analysis of collagen and glycogen deposition had a remarkable decrease of testis fibrosis and improvement of carbohydrate contents after treatment with Cur and N.Cur. The antioxidant mechanism of Cur and its nanoparticles is responsible for free

radical trapping ability and maintaining the activities of antioxidant enzymes (Ismail *et al.*, 2015).

We could conclude that acrylamide oral administration causes severe toxicity in the testis which induces apoptosis, decreases or increase serum protein fraction, and CBC parameter. In addition to severe histopathological change, fibrosis and glycogen depletion are caused by AC. Cur nanoformulations have been developed to enhance Cur delivery, thereby overcoming the low therapeutic effects. Nanocurcumin reduced the harmful damages induced by acrylamide more than free curcumin due to its high antioxidant, antiapoptotic, bioavailability and solubility.

REFERENCES

- Abdelhamid, F. M., Mahgoub, H. A., & Ateya, A. I. (2020). Ameliorative effect of curcumin against lead acetate-induced hemato-biochemical alterations, hepatotoxicity, and testicular oxidative damage in rats. *Environmental Science and Pollution Research*, 1-16.
- Abdellah, A. M., Sliem, M. A., Bakr, M., & Amin, R. M. (2018). Green synthesis and biological activity of silver-curcumin nanoconjugates. *Future medicinal chemistry*, 10(22), 2577-2588.
- Afolayan, F. I., Erinwusi, B., & Oyeyemi, O. T. (2018). Immunomodulatory activity of curcumin-entrapped poly d, l-lactic-co-glycolic acid nanoparticles in mice. *Integrative medicine research*, 7(2), 168-175.
- Alhusaini, A., Hasan, I. H., Aldowsari, N., & Alsaadan, N. (2018). Prophylactic Administration of Nanocurcumin Abates the Incidence of Liver Toxicity Induced by an Overdose of Copper Sulfate: Role of CYP4502E1, NF- κ B and Bax Expressions. *Dose-Response*, 16(4), 1559325818816284.
- Araya-Sibaja, A. M., Salazar-López, N. J., Romero, K. W., Vega-Baudrit, J. R., Domínguez-Avila, J. A., Contreras, C. A. V., ... & González-Aguilar, G. A. (2021). Use of nanosystems to improve the anticancer effects of curcumin. *Beilstein journal of nanotechnology*, 12(1), 1047-1062.
- Bataller, R., Schwabe, R. F., Choi, Y. H., Yang, L., Paik, Y. H., Lindquist, J., ... & Brenner, D. A. (2003). NADPH oxidase signal transduces angiotensin II in hepatic stellate cells and is critical in hepatic fibrosis. *The Journal of clinical investigation*, 112(9), 1383-1394.
- Belhadj Benziane, A., Dilmi Bouras, A., Mezaini, A., Belhadri, A., & Benali, M. (2019). Effect of oral exposure to acrylamide on biochemical and hematologic parameters in Wistar rats. *Drug and chemical toxicology*, 42(2), 157-166.
- Brantxt, K. H., Meulendijk, P. N., Poulie, N. J., Schalm, L., Schulte, M. J., Zanen, H. C., & Streefkerk, J. (1965). Data on the Determination of SCOT and SGPT Activity in Donor Blood for the Possible Prevention of Post-Transfusion Hepatitis. *Acta Medica Scandinavica*, 177(3), 321-5.
- Cantrell, M. S., & McDougal, O. M. (2021). Biomedical rationale for acrylamide regulation and methods of detection. *Comprehensive Reviews in Food Science and Food Safety*, 20(2), 2176-2205.
- Castano, P. R., Parween, S., & Pandey, A. V. (2019). Bioactivity of curcumin on the cytochrome P450 enzymes of the steroidogenic pathway. *International journal of molecular sciences*, 20(18), 4606.
- Chandra, A. K., Chatterjee, A., Ghosh, R., & Sarkar, M. (2007). Effect of curcumin on chromium-induced oxidative damage in male reproductive system. *Environmental Toxicology and Pharmacology*, 24(2), 160-166.

- Conti, L., Lanzardo, S., Ruiu, R., Cadenazzi, M., Cavallo, F., Aime, S., & Crich, S. G. (2016). L-Ferritin targets breast cancer stem cells and delivers therapeutic and imaging agents. *Oncotarget*, 7(41), 66713.
- Courtoy, G. E., Leclercq, I., Froidure, A., Schiano, G., Morelle, J., Devuyt, O., ... & Bouzin, C. (2020). Digital Image Analysis of Picrosirius Red Staining: A Robust Method for Multi-Organ Fibrosis Quantification and Characterization. *Biomolecules*, 10(11), 1585.
- Ghadhban, R. (2021). Melatonin and Vitamin C Administration Alone or as a Combination Ameliorative Role on Acrylamide Hematotoxicity Effects in Wistar Male Rats. *Egyptian Journal of Veterinary Sciences*, 52(2), 147-153.
- Ghorbel, I., Maktouf, S., Kallel, C., Chaabouni, S. E., Boudawara, T., & Zeghal, N. (2015). Disruption of erythrocyte antioxidant defense system, hematological parameters, induction of pro-inflammatory cytokines and DNA damage in liver of co-exposed rats to aluminium and acrylamide. *Chemico-biological interactions*, 236, 31-40.
- Gonda, Z., Béke, F., Tischler, O., Petró, M., Novák, Z., & Tóth, B. L. (2017). Erythrosine B Catalyzed Visible-Light Photoredox Arylation–Cyclization of N-Alkyl-N-aryl-2-(trifluoromethyl) acrylamides to 3-(Trifluoromethyl) indolin-2-one Derivatives. *European Journal of Organic Chemistry*, 2017(15), 2112-2117.
- Grzybowska, D., & Snarska, A. (2021). Acrylamide-induced changes of granulopoiesis in porcine bone marrow. *Journal of Veterinary Research*, 65(3), 323-327.
- Guo, M., Chen, Q., Liang, Y., Wang, Y., Luo, G., & Yu, H. (2020). Experimental and model-based study of biohydration of acrylonitrile to acrylamide in a microstructured chemical system. *AIChE Journal*, 66(10), e16298.
- Hamdy, S. M., Shabaan, A. M., Latif, A. K. M. A., Abdel-Aziz, A. M., & Amin, A. M. (2017). Protective effect of Hesperidin and Tiger nut against Acrylamide toxicity in female rats. *Experimental and Toxicologic Pathology*, 69(8), 580-588.
- Hammad, A. Y., Osman, M. E., & Abdelgadir, W. S. (2013). Effects of acrylamide toxicity on growth performance and serochemistry of Wistar rats. *British Journal of Pharmacology and Toxicology*, 4(4), 163-168.
- Hanna, D. H., & Saad, G. R. (2020). Nanocurcumin: preparation, characterization and cytotoxic effects towards human laryngeal cancer cells. *RSC Advances*, 10(35), 20724-20737.
- Hasanin, N. A., Sayed, N. M., Ghoneim, F. M., & Al-Sherief, S. A. (2018). Histological and ultrastructure study of the testes of acrylamide exposed adult male albino rat and evaluation of the possible protective effect of vitamin E intake. *Journal of microscopy and ultrastructure*, 6(1), 23.
- Heijnen, B. H., Straatsburg, I. H., Gouma, D. J., & van Gulik, T. M. (2003). Decrease in core liver temperature with 10 C by in situ hypothermic perfusion under total hepatic vascular exclusion reduces liver ischemia and reperfusion injury during partial hepatectomy in pigs. *Surgery*, 134(5), 806-817.
- Hu, Q., Xu, X., Li, Z., Zhang, Y., Wang, J., Fu, Y., & Li, Y. (2014). Detection of acrylamide in potato chips using a fluorescent sensing method based on acrylamide polymerization-induced distance increase between quantum dots. *Biosensors and Bioelectronics*, 54, 64-71.
- Hussain, M. A., Hassan, B. B., Masoud, R. E., & Al Tamany, D. (2017). Curcumin attenuates erythropoiesis in recombinant human erythropoietin-induced polycythemia in rats. *National Journal of Physiology, Pharmacy and Pharmacology*, 7(7), 766-770.

- Ismaiel, A. A., El-Denshary, E. S., El-Nekeety, A. A., Al-Yamani, A. F., Gad, S. A., Hassan, N. S., & Abdel-Wahhab, M. A. (2015). Ameliorative effects of curcumin nanoparticles on hepatotoxicity induced by zearalenone mycotoxin. *Global J Pharmacol*, 9(3), 234-245.
- Jantawong, C., Priprem, A., Intuyod, K., Pairojkul, C., Pinlaor, P., Waraasawapati, S., ... & Pinlaor, S. (2021). Curcumin-loaded nanocomplexes: Acute and chronic toxicity studies in mice and hamsters. *Toxicology reports*, 8, 1346-1357.
- Kahkeshani, N., Saeidnia, S., & Abdollahi, M. (2015). Role of antioxidants and phytochemicals on acrylamide mitigation from food and reducing its toxicity. *Journal of food science and technology*, 52(6), 3169-3186.
- Kalaivani, M., Saleena, U. V., Katapadi, K. G. K., Kumar, Y. P., & Nayak, D. (2018). Effect of acrylamide ingestion on reproductive organs of adult male wistar rats. *Journal of Clinical and Diagnostic Research*, 12(11).
- Kalpana, C., & Menon, V. P. (2004). Modulatory effects of curcumin on lipid peroxidation and antioxidant status during nicotine-induced toxicity. *Pharmacological Reports*, 56(5), 581-586.
- Kandemir, F. M., Yıldırım, S., Kucukler, S., Caglayan, C., Darendelioğlu, E., & Dortbudak, M. B. (2020). Protective effects of morin against acrylamide-induced hepatotoxicity and nephrotoxicity: A multi-biomarker approach. *Food and Chemical Toxicology*, 138, 111190.
- Kumar, J., Das, S., & Teoh, S. L. (2018). Dietary acrylamide and the risks of developing cancer: Facts to ponder. *Frontiers in nutrition*, 5, 14.
- Lal, R., Arora, M., & Sharma, A. (2011). Acrylamide caused hematotoxicity on mus musculus through gavage. *Indian Journal of Fundamental Applied Life Sciences*, 1, 330-334.
- Liu, X., Jiang, W., Gou, S., Ye, Z., Feng, M., Lai, N., & Liang, L. (2013). Synthesis and evaluation of novel water-soluble copolymers based on acrylamide and modular β -cyclodextrin. *Carbohydrate polymers*, 96(1), 47-56.
- Mahjoob, M., & Stochaj, U. (2021). Curcumin nanoformulations to combat aging-related diseases. *Ageing Research Reviews*, 101364.
- Manju, M., Vijayasree, A. S., Akbarsha, M. A., & Oommen, O. V. (2013). Protective effect of dietary curcumin in *Anabas testudineus* (Bloch) with a special note on DNA fragmentation assay on hepatocytes and micronucleus assay on erythrocytes in vivo. *Fish physiology and biochemistry*, 39(5), 1323-1330.
- Memarzia, A., Khazdair, M. R., Behrouz, S., Gholamnezhad, Z., Jafarnezhad, M., Saadat, S., & Boskabady, M. H. (2021). Experimental and clinical reports on anti-inflammatory, antioxidant, and immunomodulatory effects of *Curcuma longa* and curcumin, an updated and comprehensive review. *BioFactors*.
- Mohammed, E. S., Nadia, M., El-Hussieny, E. A., Eman, E. A., Hassan, M., & Zoheiry, M. (2021). Effects of free and nanoparticulate curcumin on chemically induced liver carcinoma in an animal model. *Archives of Medical Science: AMS*, 17(1), 218.
- Pan, X., Wu, X., Yan, D., Peng, C., Rao, C., & Yan, H. (2018). Acrylamide-induced oxidative stress and inflammatory response are alleviated by N-acetylcysteine in PC12 cells: involvement of the crosstalk between Nrf2 and NF- κ B pathways regulated by MAPKs. *Toxicology letters*, 288, 55-64.
- Patnaik, S., Gorain, B., Padhi, S., Choudhury, H., Gabr, G. A., Md, S., ... & Kesharwani, P. (2021). Recent update of toxicity aspects of nanoparticulate systems for drug delivery. *European Journal of Pharmaceutics and Biopharmaceutics*, 161, 100-119.

- Paxinos, G., & Franklin, K. B. (2019). *Paxinos and Franklin's the mouse brain in stereotaxic coordinates*. Academic press.
- Pistritto, G., Trisciuglio, D., Ceci, C., Garufi, A., & D'Orazi, G. (2016). Apoptosis as anticancer mechanism: function and dysfunction of its modulators and targeted therapeutic strategies. *Aging (Albany NY)*, 8(4), 603.
- Pundir, C. S., Yadav, N., & Chhillar, A. K. (2019). Occurrence, synthesis, toxicity and detection methods for acrylamide determination in processed foods with special reference to biosensors: A review. *Trends in food science & technology*, 85, 211-225.
- Qin, G., Zhang, Y., Zhang, B., Zhang, Y., Liu, Y., & Lin, Q. (2020). Environmental estrogens and progestins disturb testis and brood pouch development with modifying transcriptomes in male-pregnancy lined seahorse *Hippocampus erectus*. *Science of The Total Environment*, 715, 136840.
- Rawi, S. M., Marie, M. A. S., Fahmy, S. R., & El-Abied, S. A. (2012). Hazardous effects of acrylamide on immature male and female rats. *African Journal of Pharmacy and Pharmacology*, 6(18), 1367-1386.
- Rezayat, S. (2018). The protective effect of nano-curcumin in experimental model of acute pancreatitis: The involvement of TLR4/NF-kB pathway. *Nanomedicine Journal*, 5(3), 138-143.
- Roshankhah, S., Gholami, M. R., & Salahshoor, M. R. (2020). Evaluation of male infertility treatment following *Rhus coriaria* extract administration on rats exposed to morphine. *Molecular biology reports*, 47(8), 6073-6081.
- Salahshoor, M. R., Khazaei, M., Jalili, C., & Keivan, M. (2016). Crocin improves damage induced by nicotine on a number of reproductive parameters in male mice. *International journal of fertility & sterility*, 10(1), 71.
- Vardi, N., Parlakpinar, H., Ates, B., Cetin, A., & Otlu, A. (2009). Antiapoptotic and antioxidant effects of β -carotene against methotrexate-induced testicular injury. *Fertility and sterility*, 92(6), 2028-2033.
- Wang, H., Huang, P., Lie, T., Li, J., Hutz, R. J., Li, K., & Shi, F. (2010). Reproductive toxicity of acrylamide-treated male rats. *Reproductive Toxicology*, 29(2), 225-230.
- Wang, H., Zhang, Y., & Heuckeroth, R. O. (2007). PAI-1 deficiency reduces liver fibrosis after bile duct ligation in mice through activation of tPA. *FEBS letters*, 581(16), 3098-3104.
- Wang, T. Y., & Chen, J. X. (2019). Effects of curcumin on vessel formation insight into the pro-and antiangiogenesis of curcumin. *Evidence-Based Complementary and Alternative Medicine*, 2019.
- Wei, Q., Li, J., Li, X., Zhang, L., & Shi, F. (2014). Reproductive toxicity in acrylamide-treated female mice. *Reproductive Toxicology*, 46, 121-128.
- Wilson, B., & Geetha, K. M. (2020). Neurotherapeutic applications of nanomedicine for treating Alzheimer's disease. *Journal of Controlled Release*, 325, 25-37.
- Yilmaz, B. O., Yildizbayrak, N., Aydin, Y., & Erkan, M. (2017). Evidence of acrylamide-and glycidamide-induced oxidative stress and apoptosis in Leydig and Sertoli cells. *Human & experimental toxicology*, 36(12), 1225-1235.
- Zheng, Y. M., Lu, A. X., Shen, J. Z., Kwok, A. H. Y., & Ho, W. S. (2016). Imperatorin exhibits anticancer activities in human colon cancer cells via the caspase cascade. *Oncology reports*, 35(4), 1995-2002.