

Comparative Study between Effectiveness of Dermapen versus Dermapen Combined with Topical Ascorbic Acid in Treatment of Stretch Marks

Fawzia Amin Saafan, Moheiddin Fakhry Alghobary,

Fatma Feisal El dakrory, Eman Gaber Hamed Tky-Eldeen*

Department of Dermatology, Andrology & STDs, Faculty of Medicine - Mansoura University, Egypt

*Corresponding author: Eman Gaber Hamed, Mobile: (+20) 01064961174, E-Mail: emangaber24@yahoo.com

ABSTRACT

Background: Stria distensea is considered a distress for the women. Weight gain, family history of stretch marks, steroid use and pregnancy are considered the most common causes of its existence. Striae distensea treatment is considered a challenge, there are different methods in treatment of stria, but till now no single treatment is considered the best treatment for it.

Objective: This study aimed to evaluate and compare the effect of dermapen alone and dermapen combined with topical ascorbic acid in treatment of striae distensae.

Patients and methods: This study was conducted on 45 patients with stretch marks. Stretch marks treatment in each patient was divided into 2 groups. First group of stretch marks (right side) was treated with dermapen only: 3 sessions with 4 weeks interval. Second group (left side) was treated with dermapen combined with topical ascorbic acid with the same number of sessions.

Result: Our study revealed the effectiveness of both methods in treatment of stretch marks, but also it showed a difference in clinical improvement among the two groups concerning change in Manchester Scar Scale (MSS) score after treatment in favor of using dermapen with topical ascorbic acid, which gave better result than using dermapen alone.

Conclusion: The current study concluded that combination of vitamin C and dermapen is promising therapeutic modality with better satisfaction compared to dermapen alone in terms of stretch marks treatment with no adverse events.

Keywords: Stretch marks, Dermapen, Topical ascorbic acid.

INTRODUCTION

Striae distensae (stretch marks) are a permanent type of dermal scarring. The unattractive appearance of stretch marks may have a significant negative psychological impact on some individuals. Although their exact etiology is unknown, the incidence of stretch marks is often associated with rapid growth, abrupt changes in weight, and the use of corticosteroids⁽¹⁾. Consequently, they occur primarily among adolescents, obese individuals, and pregnant women. By the third trimester, approximately 90% of pregnant women develop stretch marks on their abdomen and/or breasts⁽²⁾. Striae generally follow cleavage lines that are transverse to the direction of the greatest tension, where the tissue is the weakest and least able to withstand mechanical stress. They are initially red (striae rubrae), later becoming white and more atrophic (striae albae)⁽¹⁾. Histologically, inflammatory changes are initially evident with dermal atrophy and loss of rete ridges. Stretch marks are distinguished from normal skin by densely packed areas of thin, horizontally arranged bundles of collagen lying parallel to the skin surface. Compared with normal skin, the number of vertical fibrillin fibers adjacent to the dermal-epidermal junction and elastin fibers in the papillary dermis are significantly reduced within stretch marks⁽³⁾.

A number of different methods are available for treating stretch marks as microneedling- topical tretinoin, glycolic acid peel, topical ascorbic acid and

laser. However, high-quality evidence for effective and long-lasting therapies is limited or lacking^(4,5). Thus, there are no consensus guidelines for treating striae. The lack of effective treatment results are either due to the permanence of skin atrophy or poor improvement in skin color.

Microneedling is one method of treating stretch marks that works by stimulating intradermal collagen production⁽⁶⁾, also it can be used as a means for achieving trans-epidermal drug delivery⁽⁷⁾. Ascorbic acid, which also enhances the production of normal collagen, can be delivered in this manner⁽⁸⁾. It therefore seems likely that ascorbic acid can improve the atrophic appearance of stretch marks. At the level of gene expression, ascorbic acid has also been shown to upregulate collagen synthesis and increase the synthesis of the inhibitor of metalloproteinase I, which decreases ultraviolet-induced collagen degradation⁽⁹⁾.

Review of literature revealed a lot of studies that addressed the efficacy of dermapen whether as single therapy⁽⁶⁾, or in combination with other treatment options^(10,11), but no available studies investigated the efficacy and safety of dermapen combined with topical ascorbic acid⁽¹²⁾.

The objective of this study was to compare between effectiveness of dermapen alone versus dermapen and topical ascorbic acid for treatment of stretch marks to find the better treatment for stretch marks.



This article is an open access article distributed under the terms and conditions of the Creative Commons Attribution (CC BY-SA) license (<http://creativecommons.org/licenses/by/4.0/>)

PATIENTS AND METHODS

This study is a comparative study that was carried out on 45 patients with red or white stretch marks. These patients were enrolled from the Dermatology Outpatient Clinic of Mansoura University Hospitals.

Ethical consent:

An approval of the study was obtained from Mansoura University Academic and Ethical Committee. Every patient signed an informed written consent for acceptance of the study. This work has been carried out in accordance with The Code of Ethics of the World Medical Association (Declaration of Helsinki) for studies involving humans.

Inclusion criteria: Subjects with stretch marks over 21 years old, both genders were enrolled in this study, all the stria cases were diagnosed by clinical examination.

Exclusion criteria: Patients who were already pregnant at the time of the treatment, patients with bleeding disorders, chronic liver disease, auto-immune disease, and chronic debilitating diseases. Patient using drugs exacerbating stria as topical or systemic steroid, and patients using other forms of treatment for stria as topical tretinoin, emollients, glycolic acid peel and laser, because that might affect the result of our study.

All participants were subjected to the following:

History taking: Present and past histories were taken searching for medical disorder, other skin disease, drug allergy, previous medication or intervention.

General examination: To exclude any systemic or autoimmune diseases that cause stretch marks.

Clinical assessment: Stretch marks appearance was assessed using the Manchester Scar Scale score at baseline and 1 month after the last treatment session⁽¹³⁾. Photographs of striae were taken at the baseline and 4 weeks after the final treatment.

Protocol of treatment:

The striae treatment areas were divided into 2 halves using the patients' umbilicus as the midline on the abdomen and the right and left sides of upper limb, lower limb, and breasts. (a) On the right half of the body, striae were treated with microneedling with dermapen only. (b) On the left half, striae was treated with microneedling with dermapen combined with topical ascorbic acid (20% solution) (Global Egypt Company).

Number of sessions: 3 sessions with 4weeks interval.

Technique:

(1) Photographs of the area were taken using a consistent background, position, and lighting, and they were compared to the post-treatment images. (2) Anesthesia was done using a thick application of topical anesthetic cream for about 60 min (EMLA® cream; Astra Pharmaceutical Products Inc., Westborough, MA). It was removed completely before starting the

procedure to prevent topical anesthetic intoxication. (3) The area was cleaned with alcoholic chlorhexidine. (4) The targeted device chosen was dermapen and sterilized needle was put into the top of hand piece of the dermapen. (5) Depth of the needle was chosen by turning the adjustment ring. (6) The active ingredient chosen to use was ascorbic acid (the use of sterile injectable products is important to avoid the risk of infection). (7) A thin layer of the liquid was applied with a disposable brush. (8) The device was passed and this process was repeated over and over. We rolled at least 20 passes in the same area in different ways. (9) The end point of treatment session is presence of uniform pinpoint bleeding. (10) After the use of dermapen, the needle was washed, sterilized by alcohol and kept in sterilized bag then labelled with the patient name and date. (11) The excess of liquid and blood was cleaned (thin layer of blood was left for at least 4 h to functions a natural PRP dress that helps to heal). Then, the area was covered with a thin plastic drape.

Clinical evaluation:

(I) Clinical improvement was evaluated using a quartile grading scale as follows; 0=no improvement, 1=mild (<25%), 2 =moderate (26-50%), 3=good (51-75%) and 4=excellent (percent improvement, >76%)⁽¹⁴⁾. (II) In addition, a patient satisfaction score was rated using the following scale: a 5-point scale ranging from 1 (very unsatisfied), 2 (unsatisfied), 3 (ok: neither satisfied nor unsatisfied), 4 (satisfied), and 5 (very satisfied).

Statistical Analysis

The collected data were coded, processed and analyzed using the SPSS (Statistical Package for Social Sciences) version 22 for Windows® (IBM SPSS Inc., Chicago, IL, USA). Shapiro-Wilk test was done to test the normality of data distribution. Significant data was considered to be nonparametric. Mean \pm SD for parametric numerical data. Frequency and percentage of non-numerical data. Percentage change from baseline was calculated using the formula: (values after treatment-values before treatment)/ values before treatment. Student T Test was used to assess the statistical significance of the difference between two study group means. For the comparison of more than two groups' means, one way analysis of variance (ANOVA) was used. Chi-Square test was used to examine the relationship between two qualitative variables. Fisher's exact test was used to examine the relationship between two qualitative variables when the expected count is less than 5 in more than 20% of cells. Pearson's correlation was used to assess the strength of association between two quantitative variables. The correlation coefficient defines the strength and direction of the linear relationship between two variables. Linear regression analysis was used for prediction of improvement. A p value was considered significant if \leq 0.05 at confidence interval 95%.

RESULTS

The present study was conducted on 45 patients with stretch marks. The patients were subjected to dermapen only on the right side and dermapen combined with topical ascorbic acid on the left side. Their mean age was 27.3 ± 4.4 years. Thirteen cases got pregnant (28.9%), while 66.7% had rapid weight gain

and 13.3% received steroid. Studied cases had different types of stretch marks where 62.2% had striae rubra, and 37.8% had striae alba. Abdomen was affected in 40%, LL in 24.4%, UL in 20%, breast in 11.1% and back in 4.4%. Baseline Manchester scale score (MSS) was 13.16 on the right side and 13.11 on the left side (Table 1).

Table (1): Age distribution, risk factors and stretch marks' features in all studied cases

		All cases	
		N=45	
Age (years) (Mean± SD)		27.3	±4.4
Risk factors		N	%
Previous pregnancy		13	28.9%
Rapid weight gain		30	66.7%
Steroid induced		6	13.3%
Types	Rubra	28	62.2%
	Alba	17	37.8%
Sites	Abdomen	18	40%
	Lower limb	11	24.4%
	Upper limb	9	20%
	Breast	5	11.1%
	Back	2	4.4%
MSS	Right side (Mean ± SD)	13.16	±1.1
	Left side (Mean ± SD)	13.11	±1.2

No significant differences were found regarding baseline MSS between studied sites (p>0.05). While after treatment, MSS showed significantly lower levels at sides treated with dermapen + ascorbic acid when compared to those sides treated with dermapen only (p=0.011). Comparing MSS after treatment to before treatment levels on each side revealed that MSS decreased significantly after treatment on right side and left side (p<0.001 for each) (Table 2).

Table (2). Comparison of MSS among the studied sites

MSS	Dermapen only		Dermapen + ascorbic acid		P ¹
	N=45		N=45		
	Mean	SD	Mean	SD	
Before treatment	13.2	1.1	13.1	1.2	0.851
After treatment	8.2	3.6	6.2	3.8	0.011
MSS Change (%)	38.1	26.4	53	28.9	0.012
p ²	<0.001		<0.001		

P¹: comparison between right and left sides using independent sample t test; P²: comparison between before and after treatment at each side using paired sample t test.

Better response was significantly associated with treatment by dermapen + ascorbic acid when compared to dermapen only (p=0.028). There was no significant association was found between side effects with type of treatment (Table 3).

Table (3). Association of response and side effects with type of treatment

	Dermapen only		Dermapen + ascorbic acid		P
	N=45		N=45		
	N	%	N	%	
Response of treatment:					
No Improvement =0	10	22.2%	7	15.6%	0.028
Mild improve (<25%)	8	17.8%	3	6.7%	
Moderate (26-50%)	16	35.6%	9	20%	
Good improve (51-76%)	7	15.6%	16	35.6%	
Excellent improve (>76%)	4	8.9%	10	22.2%	
Side effects:					
Post inflammatory hyperpigmentation (Figure 1)	9	20%	5	11.1%	0.245
Itching	7	15.6%	5	11.1%	0.535

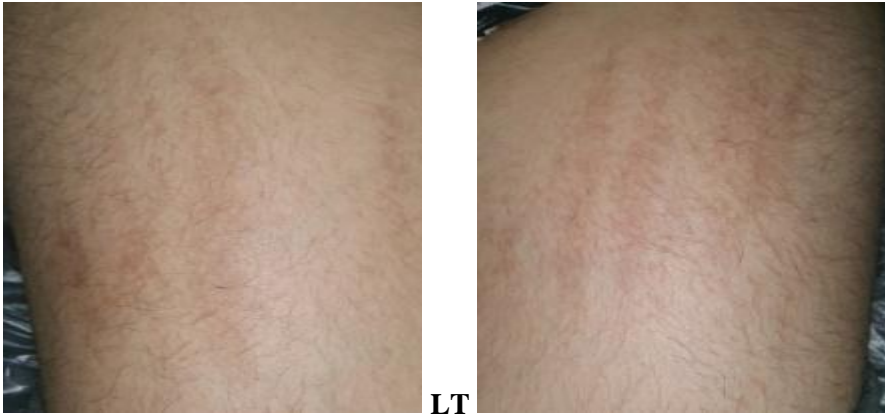


Figure (1): Post inflammatory hyperpigmentation in front of thigh after 3 sessions with dermapen in right side and dermapen plus topical vit. C in left side.

Better satisfaction was significantly associated with treatment by dermapen + ascorbic acid when compared to dermapen only ($p=0.008$) (Table 4).

Table (4). Association of patients' satisfaction with type of treatment

	Dermapen only		Dermapen + ascorbic acid		p
	N=45		N=45		
Very unsatisfied	6	13.3%	4	8.9%	0.008
Unsatisfied	7	15.6%	3	6.7%	
Ok (neither satisfied nor unsatisfied)	16	35.6%	5	11.1%	
Satisfied	11	24.4%	21	46.7%	
Very Satisfied	5	11.1%	12	26.7%	

MSS changes and patients' satisfaction showed significant positive correlation with improvement after dermapen only as well as after dermapen + ascorbic acid ($p<0.001$ for each). While age, and baseline MSS did not show significant correlation with improvement ($p>0.05$ for each) (Table 5).

Table (5). Correlation of improvement with age, MSS and satisfaction

	Dermapen only		Dermapen + ascorbic acid	
	Improvement		Improvement	
	r	p	r	p
Age	0.060	0.696	0.014	0.926
Baseline MSS	-0.138	0.367	-0.016	0.916
MSS change	0.955	<0.001	0.983	<0.001
Patients satisfaction	0.877	<0.001	0.907	<0.001

r, correlation coefficient. Pearson correlation was used.

Linear regression analysis was conducted for prediction of better improvement, using age, risk factors, baseline MSS and type of treatment as confounders. Significantly better improvement (β has positive charge) was predicted by using dermapen combined with ascorbic acid, as well as rubra type ($p=0.010$, <0.001 respectively) (Table 6).

Table (6). Linear Regression analysis for prediction of better improvement in all studied cases.

	β	p
Age	0.011	0.745
Previous pregnancy	0.014	0.963
Rapid weight gain	-0.100	0.739
Steroid induced	-0.173	0.677
Rubra versus alba	1.336	<0.001
Baseline MSS	-0.089	0.486
Combination of ascorbic acid to dermapen versus dermapen only	0.711	0.010

Linear regression was used; β , regression coefficient. Linear regression test was used.

CASE (1)

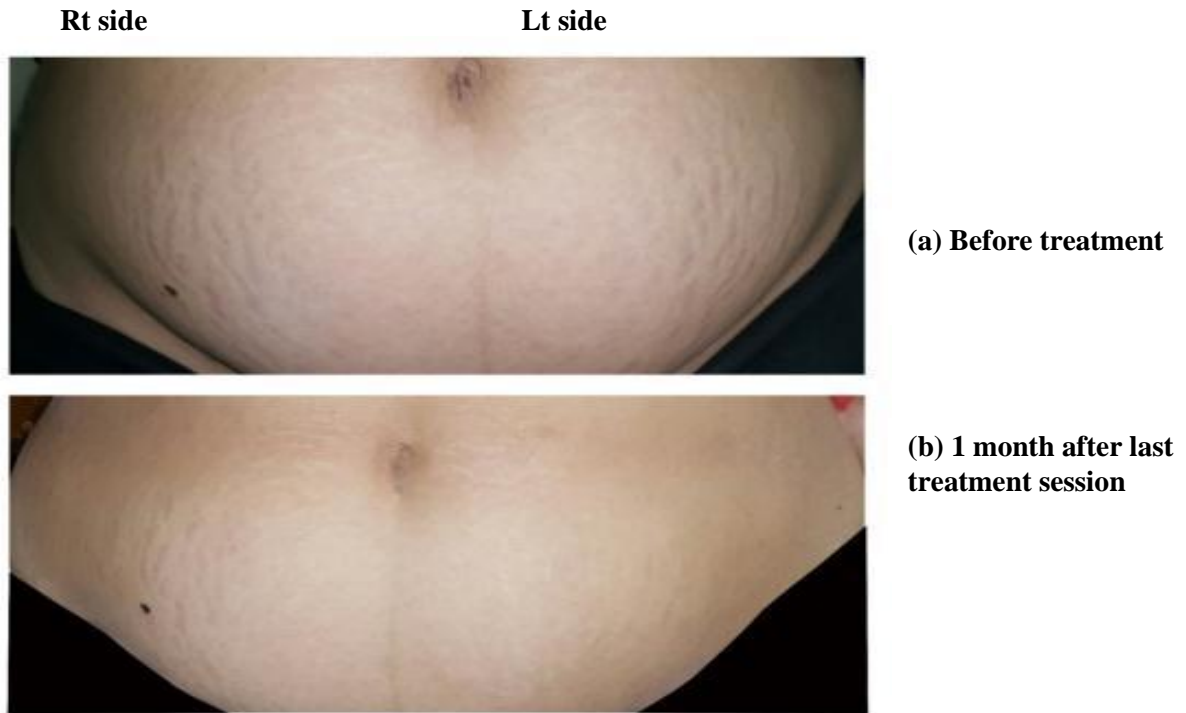


Figure (2): This case represents stria gravidarum, located in abdomen. The right side was treated by dermapen only and showed moderate response (26-50%). The left side was treated by dermapen plus topical vit. C and showed excellent response (>76%).

CASE 2

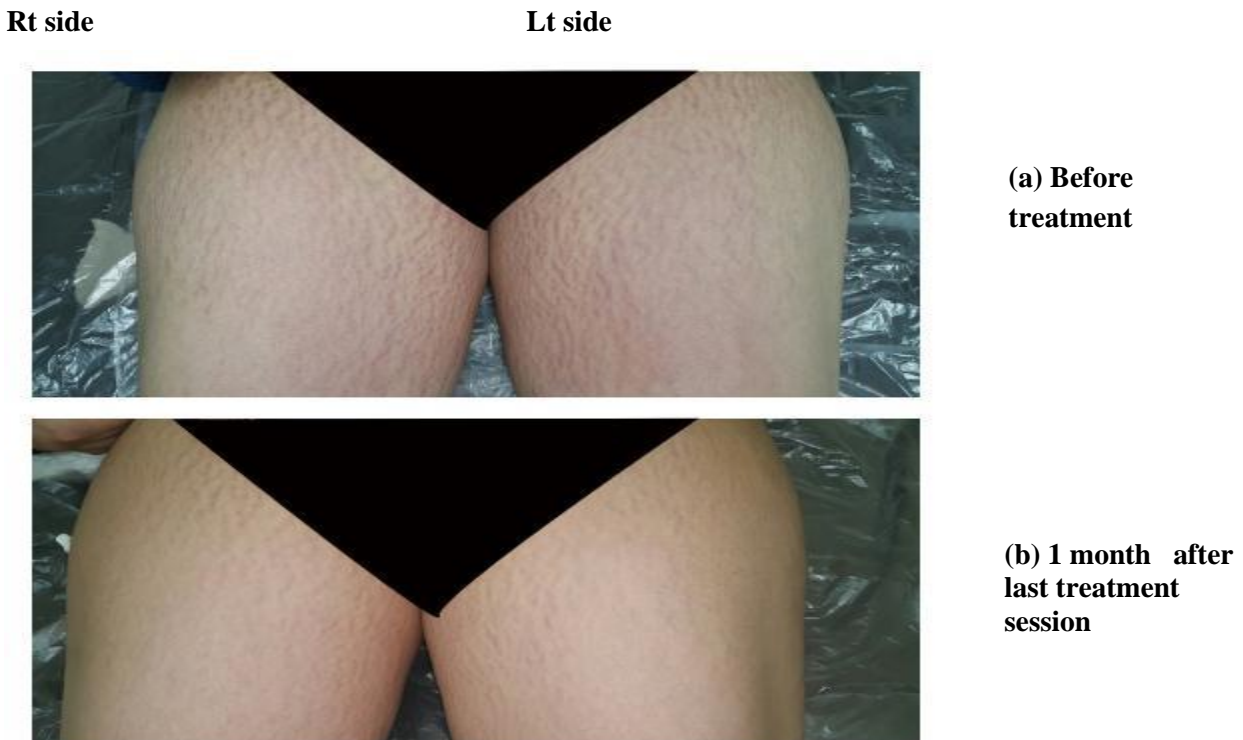


Figure (3): This is a case of stria rubra caused after steroid use in the front of the thigh. The right side was treated by dermapen only and showed moderate response (26-50%). The left side was treated by dermapen plus topical vit. C and showed good response (51-75%).

DISCUSSION

The current study demonstrated that there was significant decrease in MSS in both sides. This indicated the efficacy of both modalities in treatment of stretch marks. But, sides treated with dermapen + ascorbic acid showed more decrease in MSS when compared to those sides treated with dermapen only ($p=0.011$). Calculating percentage changes in MSS revealed that dermapen + ascorbic acid treatment was significantly associated with better change in MSS when compared to dermapen only (53% versus 38.1%, $p=0.012$). This means that adding vit.C (ascorbic acid) to microneedling for treatment of stretch marks was effective and gave better results. That is due to the important role of ascorbic acid (vitamin c) in production of normal collagen. It acts as an essential cofactor for the enzymes lysyl-hydroxylase and prolyl-hydroxylase, which are required for the post-translational processing of collagen types I and III ⁽¹⁵⁾.

Ascorbic acid also stimulates collagen production in the dermis by increasing rate of fibroblast proliferation. It therefore seems that ascorbic acid can cause improvement in the atrophic appearance of stretch marks. Regarding gene expression, ascorbic acid has also been shown to upregulate collagen synthesis and increase the synthesis of the inhibitor of metalloproteinase I, which decreases ultraviolet-induced collagen degradation ⁽⁹⁾.

Regarding microneedling; it is considered a proven means for delivering medications, such as ascorbic acid, into the skin ^(12, 15).

Casabona and Marchese ⁽¹⁶⁾ treated 35 cases presented with red ($n = 25$) and white ($n = 10$) striae using calcium hydroxylapatite combined with microneedling and topical ascorbic acid. CaHA filler was diluted 1:1 with lidocaine 2% without epinephrine. 3.0 mL of filler was injected per patient using a 23G needle. This was followed by microneedling and topical application of 20% ascorbic acid. Microneedling with ascorbic acid was repeated for 2 sessions after 1 and 2 months. Skin biopsies were obtained from a patient. They demonstrated that; the mean (\pm SD) pretreatment MSS scores were significantly decreased 1 month after the final treatments, indicating improvement in stretch mark appearance. They demonstrated that, patients were very satisfied ($n = 22$; 62.9%), satisfied ($n = 8$; 22.9%), neither satisfied nor dissatisfied ($n = 4$; 11.4%), or unsatisfied ($n = 1$; 2.8%) with their results of treatment. Analysis revealed a significant correlation between MSS and Patient Satisfaction scores ($r = 0.483$; $P = 0.003$). In addition, **Casabona and Marchese** ⁽¹⁶⁾ reported that microneedling with topical vitamin C for treating red and white stretch marks revealed an increase in the quantity and quality of dermal collagen and elastin fibers (skin biopsies) and, suggested that this combined treatment may produce better results than using each technique alone. Another study reported that microneedling + vitamin C groups was associated with better outcomes compared to microneedling, however

such improvement not reached the statistical significance as the satisfaction was similar among microneedling group and microneedling + vitamin C. However, there was highly statistically significant difference according to the histopathological evaluation (p -value < 0.001 *), the highest rate of collagen and elastin induction was induced by microneedling with vitamin C followed by microneedling only. In addition, there was a significant increase in the mean of collagen percentage by 24.1% to become $51.47 \pm 5.36\%$, elastin percentage by 100.5% to become $19.89 \pm 1.94\%$, increase in epidermal thickness by 20.3% to become $80.16 \pm 3.49 \mu\text{m}$ and rete ridges by 33.2% to become $81.05 \pm 20.70 \mu\text{m}$ ⁽¹⁷⁾.

With regard to satisfaction in our study, patients' satisfaction with the aesthetic results was assessed using a 5-point scale ranging from 1 (very unsatisfied) to 5 (very satisfied). Dermapen and ascorbic acid treatment was demonstrated to be associated with more satisfactory outcomes in comparison with cases using dermapen only. Such alteration among our study and **Abdelsamiea's** study ⁽¹⁷⁾ regarding statistical difference in clinical improvement between both types of treatment modalities may be due the fact that, they performed their study on a small sample size (30 patients only), while our study was conducted on a total of 45 cases. Also, our study included subjects suffering from both types of stretch marks where 62.8% were associated with stria rubra, while 37.8% only were associated with stria alba. We found that, rubra type was significantly associated with better improvement after treatment with dermapen only as well as with dermapen + ascorbic acid when compared to alba type. On the other hand, **Abdelsamiea's** study ⁽¹⁷⁾ included only one type of stretch marks, which is stria alba. Another reason is that we used topical ascorbic acid with concentration 20%, while **Abdelsamiea and her colleagues** ⁽¹⁷⁾ used topical ascorbic acid with lower concentration 15%.

In terms of adverse events, no significant association was found between side effects with type of treatment among both groups. Similarly in **Abdelsamiea's** study ⁽¹⁷⁾, which reported no significant difference among microneedling with vitamin C and microneedling only groups regarding side effects. This comes in accordance with **Casabona and Marchese** ⁽¹⁶⁾ who found that there is no serious adverse effects. However, **Abdelsamiea et al.** ⁽¹⁷⁾ reached a conclusion that, microneedling in combination with vitamin C is an effective, safe and low-cost therapy treatment modality for abdominal striae distensae alba where addition of vitamin C increases the treatment outcome.

Regarding basic criteria of stretch marks in our study, the mean age of studied patients was 27.3 ± 4.4 years old and all of them were females. According to the frequency of site of distribution of striae, abdomen was reported to be the most common affected site (40%), followed by LL (24.4%), then UL (20%), breast

(11.1%) and lastly back (4.4%). In addition to the frequency of possible causes of striae, rapid weight gain was reported to be the most common cause (66.7%) followed by previous pregnancy (28.9%), then steroid-induced (13.3%). This also was reported by **Hakim and his colleagues** ⁽¹⁸⁾ who displayed that, stretch marks are most commonly a result of pregnancy, obesity or corticosteroid excess and typical sites include the abdomen and lower back. **Yates** ⁽¹⁹⁾ explained stretch marks development as they formed in the dermis when the connective tissue is stretched over the elasticity limits as a result of rapid expansion or contraction of the skin as the skin cannot get back to normal form after a time of intense growth, after pregnancy, weight gain, weight loss.

Concerning association of improvement after treatment to baseline data, no significant association was found between improvement after treatment on both sides regarding age, cause (Previous pregnancy, rapid weight gain, steroid treatment), site and baseline MSS. By performing linear regression analysis for prediction of better improvement in the studied cases, the current study displayed that significantly better improvement (β has positive charge) was predicted by using dermapen. While, in another studies, it was demonstrated that, independent predictors of stretch marks in pregnancy were younger age, maternal and family history of stretch marks, increased pre-pregnancy and predelivery weight, increased birth weight, and the absence of chronic disease ^(20, 21).

CONCLUSION

The current study concluded that combination of vitamin C and dermapen was demonstrated to be a promising therapeutic modality with better satisfaction compared to dermapen alone in terms of stretch marks treatment with no adverse events. In addition, both dermapen combined with ascorbic acid, and rubra type could be used as significant predictors for better improvement.

RECOMMENDATIONS

Utilization of vitamin C + dermapen combination in the context of stretch mark treatment as it give better result with minimal side effects.

Financial support and sponsorship: Nil.

Conflict of interest: Nil.

REFERENCES

1. **Elsaie M, Baumann L, Elsaie L (2009):** Striae distensae (stretch marks) and different modalities of therapy: an update. *Dermatologic surgery: official publication for American Society for Dermatologic Surgery*, 35 (4): 563–573.
2. **Barankin B, Silver S, Carruthers A (2002):** The skin in pregnancy. *J Cutan Med Surg.*, 6 (3): 236–240.
3. **Singh G, Kumar L (2005):** Striae distensae. *Indian Journal of Dermatology, Venereology and Leprology*, 71 (5): 370–372.
4. **Liu L, Ma H, Li Y (2014):** Interventions for the treatment of stretch marks: a systematic review. *Exp Dermatol.*, 19 (4): 285–288.
5. **Al-Himdani S, Ud-Din S, Gilmore S et al. (2014):** Striae distensae: a comprehensive review and evidence-based evaluation of prophylaxis and treatment. *The British Journal of Dermatology*, 170 (3): 527–547.
6. **Park K, Kim H, Kim S et al. (2012):** Treatment of striae distensae using needling therapy: a pilot study. *Dermatologic Surgery: Official Publication for American Society for Dermatologic Surgery*, 38 (11): 1823–1828.
7. **Prausnitz M (2004):** Microneedles for transdermal drug delivery. *Advanced Drug Delivery Reviews*, 56 (5): 581–587.
8. **Hinek A, Kim H, Wang Y et al. (2014):** Sodium L-ascorbate enhances elastic fibers deposition by fibroblasts from normal and pathologic human skin. *J Dermatol Sci.*, 75 (3): 173–182.
9. **Stamford N (2012):** Stability, transdermal penetration, and cutaneous effects of ascorbic acid and its derivatives. *Journal of Cosmetic Dermatology*, 11 (4): 310–317.
10. **Abdel-Motaleb A, Zedan H, Mostafa M et al. (2020):** Combined microneedling with topical application of platelet-rich plasma versus microneedling alone in the treatment of stria distensae: clinicopathological analysis. *The Journal of Dermatological Treatment*, 20: 1–12.
11. **Seong G, Jin E, Ryu T et al. (2020):** Fractional Radiofrequency Microneedling Combined With Fractional Carbon Dioxide Laser Treatment for Striae Distensae. *Lasers Surg Med.*, 10: 1002-1007.
12. **Nusgens B, Humbert P, Rougier A et al. (2001):** Topically applied vitamin C enhances the mRNA level of collagens I and III, their processing enzymes and tissue inhibitor of matrix metalloproteinase 1 in the human dermis. *The Journal of Investigative Dermatology*, 116 (6): 853–859.
13. **Beausang E, Floyd H, Dunn K et al. (1998):** A new quantitative scale for clinical scar assessment. *Plast Reconstr Surg.*, 102 (6): 1954–1961.
14. **Yang Y, Lee G (2011):** Treatment of Striae Distensae with Nonablative Fractional Laser versus Ablative CO₂ Fractional Laser: A Randomized Controlled Trial. *Annals of Dermatology*, 23 (4): 481–489.
15. **McCrudden M, McAlister E, Courtenay A et al. (2015):** Microneedle applications in improving skin appearance. *Experimental Dermatology*, 24 (8): 561–566.
16. **Casabona G, Marchese P (2017):** Calcium Hydroxylapatite Combined with Microneedling and Ascorbic Acid is Effective for Treating Stretch Marks. *Plastic and reconstructive surgery. Global Open*, 5 (9): 1474-77.
17. **Abdelsamiea A, Abdel Fattah N, Nada O et al. (2021):** Microneedling With and Without Vitamin C versus Fractional CO₂LASER in Treating Abdominal Striae Distensae Alba: A Comparative Clinical and Histopathological Study. *The Medical Journal of Cairo University*, 89 (1): 209-219.
18. **Hakim A, Malfait F, De Paep A et al. (2010):** The heritable disorders of connective tissue: epidemiology, nosology and clinical features. *Hypermobility, Fibromyalgia and Chronic Pain*. Edinburgh: Churchill Livingstone/Elsevier, Pp: 3-17.
19. **Yates S (2018):** Pregnancy and Childbirth. Chapter 1: Western approach to pregnancy 2010, Pp: 7-61. <https://www.elsevier.com/books/pregnancy-and-childbirth/yates/978-0-7020-3055-0>
20. **Chikvaidze N, Kristesashvili J, Gegechkori M (2014):** Peculiarities of sexual development and reproductive function in young women with childhood onset weight problems. *Georgian Medical News*, 235: 11–16.
21. **Kasielska-Trojan A, Sobczak M, Antoszewski B (2015):** Risk factors of striae gravidarum. *International Journal of Cosmetic Science*, 37 (2): 236–240.