

PANFACIAL FRACTURE SURGICAL APPROACH, BOTTOM UP– OUTSIDE IN VERSUS TOP DOWN– INSIDE OUT. PROSPECTIVE CLINICAL STUDY

Shereen W. Arafat* and Mohamed A. Elbaz**

ABSTRACT

Objectives: The current study aim was to compare two surgery approaches, bottom-up outside-in and top-down inside-out, for the treatment of panfacial fracture.

Material & Methods: Twelve male panfacial fracture patients were randomly divided into two groups. Group 1 involved six patients treated in Bottom Up– Outside In sequence, and group 2 involved six patients treated in Top Down– Inside Out sequence. The treatment plan was set based on Computerized Tomography (CT) images. Clinical evaluation of final treatment outcome was reported postoperatively based on facial contour, occlusion, and maximal mouth opening. Data was collected and analysed statistically.

Results: The final treatment outcome in each group was 83.7% excellent, and 16.3% good. Insignificant difference resulted between the study groups after postoperative assessment regarding the final treatment outcome ($p=1.00$), and the postoperative assessment of Paraesthesia ($p=0.269$).

Conclusion: The current study found that both bottom-up outside-in and top-down inside-out sequences for the treatment of panfacial fracture have similar clinical outcomes.

INTRODUCTION

Panfacial fractures are fractures that simultaneously involve the upper, middle, and lower face. ^(1,2) patients with panfacial fractures are usually challenging and complicated with remarkable variation. The severe fragmentation and reference segments loss are the main reasons of the difficulty in restoring the original facial contour. ⁽³⁾ Moreover, there are several midface buttresses

that need to be approached in order to restore the midface height, projection, and width, and to restore the occlusal relationship as well. ⁽⁴⁾ Furthermore, Panfacial fractures are usually accompanied by soft tissue trauma and bony framework destruction, which causes in most cases malocclusion and/or facial deformities like increased facial width, disturbed facial height and/or projection. ⁽⁵⁾ The goal of panfacial fracture treatment is to reconstruct function, aesthetics and facial contours.

* Associate Professor of Oral and Maxillofacial Surgery, October University for Modern Sciences and Arts, Egypt.

Proper management of panfacial fractures usually starts with proper physical examination and accurate imaging. Examination of the face is performed visually and manually with careful detection of oedema and ecchymosis, facial asymmetry, trismus, and malocclusion. Bony step-offs, crepitation, areas of tenderness, and midfacial mobility are detected. Proper palpation of the naso-ethmoid region, the palate, and the orbit is mandatory. Visual evaluation by an ophthalmologic consultant is requested. Computed tomography is a valuable method in determining the treatment plan. Three-dimensional reconstructions play a major role in surgical planning.

With the beginning of 1980s and during 1990s, craniomaxillofacial surgeons suggested and applied the concept of broad exposure and visualization of the fracture which in turn affected the sequence of repair.⁽⁶⁾ Maxillofacial Surgeons usually follow the “bottom up- outside-in” or “top down- inside-out” approach.⁽⁷⁾ “Bottom up outside-in” approach starts the reduction and fracture fixation for the mandible then proceed to the frontal bone, and then to the zygomatico-maxillary complex, maxilla, and Naso-Orbital-Ethmoidal region (NOE). This approach is the most commonly used in the reduction of panfacial bone.^(8,9) While, “top down- inside-out” approach have proved good occlusion and mouth opening when compared to the “bottom up outside-in” approach. This approach starts with proper reduction of the maxillary alveolar ridge by reduction and repositioning of the facial buttress. Then, the maxillary alveolar ridge can act as a stable base to reposition and adjust the mandible in three dimensions.⁽¹⁰⁾

Facial reconstruction approaches and sequence of management have considerable controversy.⁽¹¹⁾ Therefore, In the current study we performed a prospective study for patients with panfacial fractures to compare the surgery approaches.

PATIENTS AND METHODS

Twelve male panfacial fracture patients aged from 23 to 48 years were selected for the current study and randomly divided into two groups. Group 1 involved six patients treated in Bottom Up– Outside In sequence, and group 2 involved six patients treated in Top Down– Inside Out sequence. Patients were selected from Dar El-Fouad Hospital Emergency Department where injuries resulted from road traffic accidents. Patients were included in the current study if they had multiple fractures involving mandible, maxilla, and zygomatico-maxillary complex. Fractures of the nasal-orbital-ethmoid (NOE) region and/or frontal bone may be involved as well. The selected patients provided written informed consent for involvement in the study and for the publication of their cases. The treatment plan was set based on Computerized Tomography (CT) images. The degree of facial deformities and malocclusions were evaluated, and the surgical incisions were planned preoperatively.

Within the 5 days post-injury, the patient went to the operating room of Dar El-Fouad Hospital for open reduction and internal fixation. Local incisions were applied in addition to the coronal incisions. For patients of group 1, treatment started with reduction and fixation of mandibular fractures to restore facial height and projection, then the zygomatic arches were reduced to act as guidance to the zygomas to be reduced and fixed together with the zygomaticomaxillary and spheno-zygomatic sutures. Both Zygomatic Complex and nasal-orbital-ethmoid (NOE) fractures were stabilized followed by maxilla and the orbital rims were realigned to adjust the transverse facial dimension.

Patients of group 2, after reduction and fixation of frontal sinus, nasal-orbital-ethmoid (NOE) fractures, and orbital rims were stabilized followed by repair of maxilla. Zygomatic Complex and nasal-orbital-ethmoid (NOE) fractures were stabilized followed

by the zygomatic arches. Finally, reduction and fixation of mandibular fractures were performed. For both groups, bony defects founded in the skull and orbital floor were reconstructed with titanium meshes. Wound closure and drainage were properly

performed. The patient started full liquid diet on postoperative day one and imaging was performed. Proper oral hygiene with chlorhexidine rinses and maxillary sinus precautions were performed. Hospital discharging was on postoperative day five.

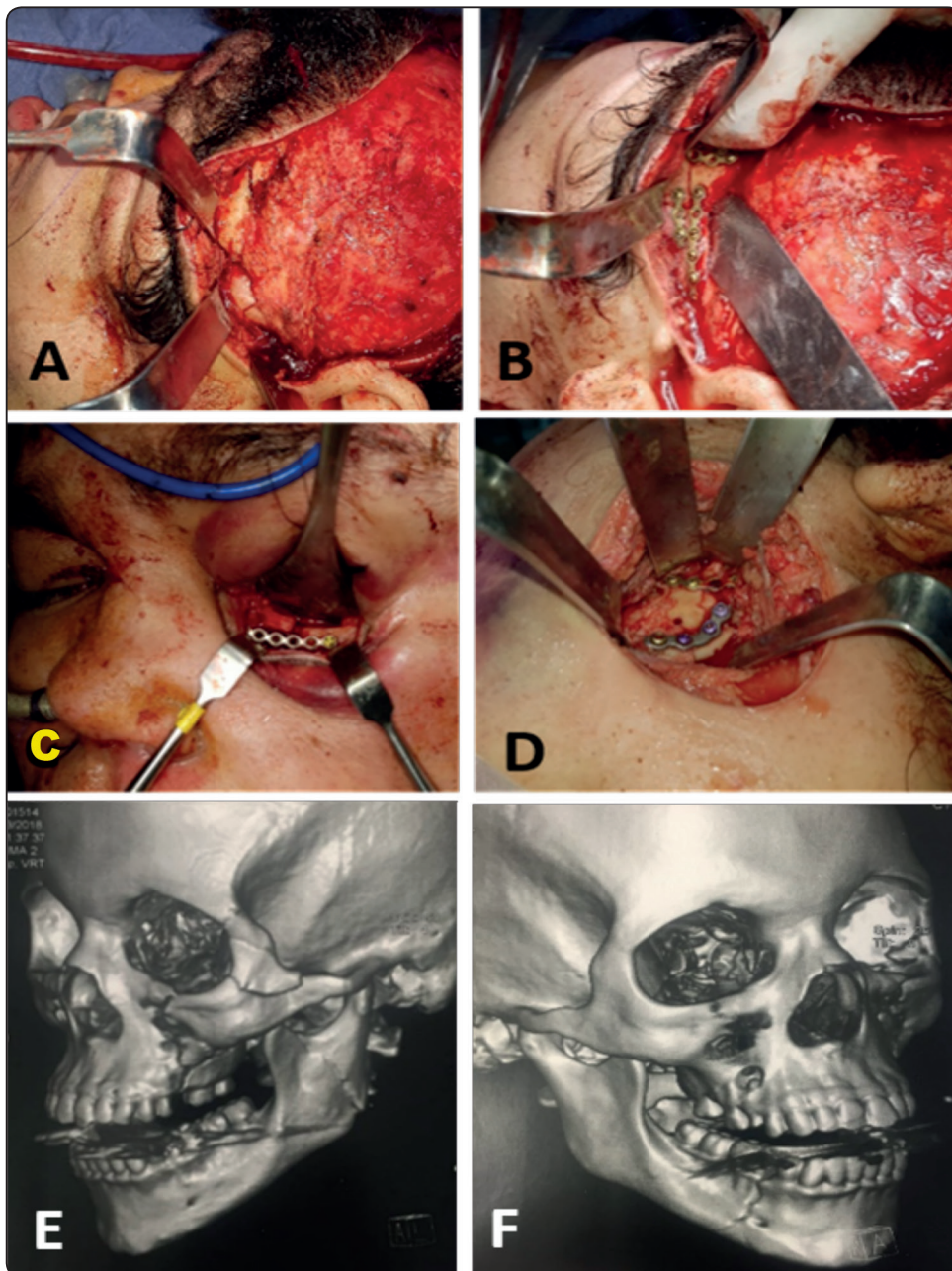


Fig. (1) Panfacial fracture case, A: Intraoperative photograph showing the coronal flap and fracture line. B: Intraoperative photograph showing the plate fixation of the fracture line. C: Intraoperative photograph showing inferior orbital rim plate fixation. D: Intraoperative photograph showing mandibular angle plate fixation. E& F: Pre-operative 3D CT images.

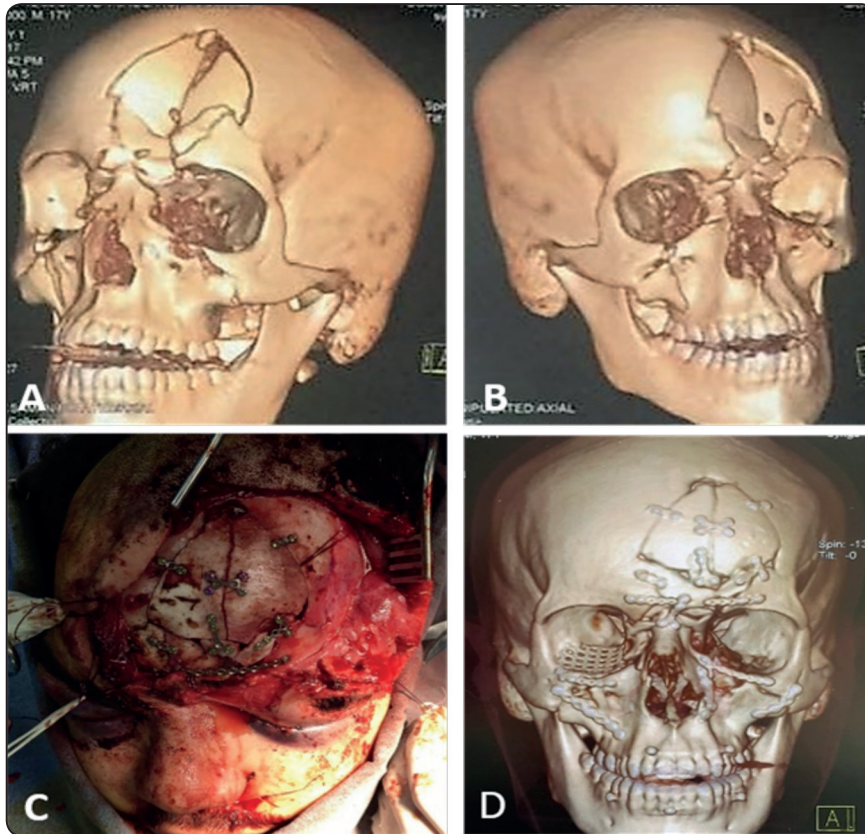


Fig. (2) Panfacial fracture case, A& B: Pre-operative 3D CT images. C: Intraoperative photograph showing comminuted fracture plate fixation. D: Post-operative 3D CT images showing the plate and titanium mesh fixation.

Clinical Evaluation

All clinical evaluations were performed by 2 well trained investigators based on the classification of face outline, occlusion, mouth opening, and local deformity: ⁽¹²⁾

Criteria (1) Face outline is found to be basically normal, with no need for additional surgical correction.

(2) Occlusion had returned to the pre-trauma status, with no need for additional surgery.

(3) The mouth opening is more than 35 mm with normal and stable temporo-mandibular joint function.

(4) No additional surgery is needed for secondary local deformity, such as deformities in the orbital

and naso-orbital ethmoidal regions, facial nerve injuries, and localized bone. Excellent: When all of the four criteria are applied.

Good: When three of the four criteria are applied.

Fair: When two of the four criteria are applied.

Poor: When one or none of the four criteria are applied.

Statistical Analysis

Data was collected and analysed statistically. MMO Data showed parametric distribution when checked for normality using Shapiro-Wilk test. Repeated measures ANOVA used to show the effect of groups, and follow-up. Multiple comparisons were performed with Tukey HSD. For Occlusal Derangement, Facial Asymmetry, and Paraesthesia

scores; Chi square test used to compare between the study groups and Friedman test used to compare between follow-up periods within each group. Significant level was set at $p=0.05$. Statistical analyses were performed using IBM SPSS software (ver 23, Armonk, NY, USA).

RESULTS

There were 12 male patients (six in bottom up outside in approach and six in top down inside out approach) ranging from 23-48 years. All panfacial fractures in the current study were caused by RTA ($n=12$, 100%) and no infection was reported in any of the study group.

Occlusal derangement was found preoperatively in 3 patients (50%) of group 1 (bottom up outside in) and in 4 patients (66.6%) of group 2 (top down inside out). All study patients have attained normal occlusion after 6 weeks postoperatively except for one patient in each group (16.6%) required orthodontic treatment.

The maximal mouth opening (MMO) mean was found preoperatively to be 14 ± 1.4 mm in group 1, and 13.8 ± 1.5 mm in group 2. At 6 weeks postoperatively, the MMO was found to be

41.8 ± 1.2 mm for group 1 and 42 ± 0.9 mm for group 2. (Table 1) For both groups; significant increase in MMO between all follow-up intervals at $p<0.001$ was found, and no significant difference resulted between the study groups for all follow-up intervals ($p>0.05$). (Fig. 3)

Mild facial Asymmetry was reported in one patient in each group (16.7%) postoperatively with no need for second surgery for all the study cases. Insignificant difference resulted between the study groups after postoperative assessment of facial asymmetry. Moreover, significant lower score for postoperative facial asymmetry resulted for both groups ($p=0.025$). (fig. 4)

Regarding the final treatment outcome, 5 out of 6 patients (83.7%) in each group showed excellent treatment outcome (score 4) while one patient (16.3%) in each group showed good treatment outcome (score 3). Insignificant difference resulted between the tested groups after postoperative assessment of final treatment outcome ($p=1.00$). (Fig. 5)

Insignificant difference resulted between the study groups after postoperative assessment of Paraesthesia at $p=0.269$. (Table 2)

TABLE (1): The MMO of the study groups at different intervals

	Group 1		Group 2		p-value
	Mean	SD	Mean	SD	
Preoperative	14.0 ^a	1.4	13.8 ^a	1.5	0.845 NS
1 day	19.0 ^b	0.9	19.0 ^b	0.9	1.00 NS
7 days	30.7 ^c	1.2	31.2 ^c	1.0	0.451 NS
21 days	37.0 ^d	1.4	37.0 ^d	0.9	1.00 NS
42 days	41.8 ^e	1.2	42.0 ^e	0.9	0.787 NS
p-value	<0.001*		<0.001*		

Different lowercase letter within each column indicates significant difference ($p<0.05$).

TABLE (2): Showing the finding of Paraesthesia for the study groups.

		Group 1		Group 2		p-value
		n	%	n	%	
Paraesthesia	Preoperative	0	0.0%	1	16.7%	0.269 NS
		1	100.0%	5	83.3%	
	42 days	0	100.0%	5	83.3%	0.269 NS
		1	0.0%	1	16.7%	
p-value		0.014*		0.102 NS		

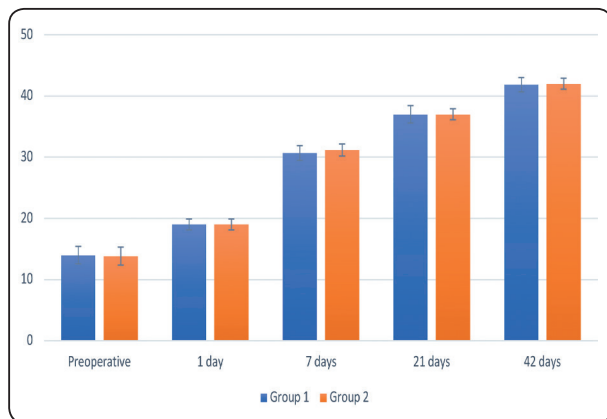


Fig. (3): Bar chart showing the MMO data for the study groups at different intervals

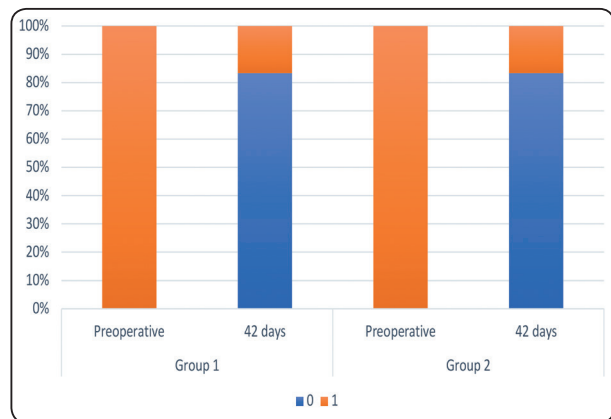


Fig. (4): Stacked bar chart showing the facial asymmetry score for the study groups. where 0 indicated no facial asymmetry, and 1 indicated facial asymmetry.

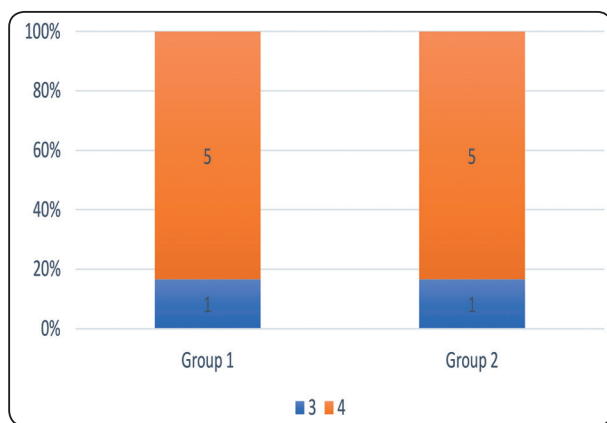


Fig. (5): Stacked bar chart showing the final treatment outcome score for tested groups (3, 4 refer to final treatment outcome scores).

DISCUSSION

Management of panfacial fractures represent a challenge to the craniomaxillofacial surgeon because of the lack of reliable landmarks.⁽¹³⁾ Recent advances in the management of panfacial fractures enable accurate restoration of facial contour, aesthetics, and function. Treatment planning of panfacial fractures requires proper knowledge of the 3-dimensional anatomical structures of facial components.⁽¹⁴⁾

Early management of panfacial fractures reduces the risks of postoperative infection. Moreover, the two weeks delay in treatment increases the difficulty in anatomic reduction of fractures.⁽¹⁵⁾ Carr and Mathog⁽¹⁶⁾ reported that after 3 weeks, the edges of bone start to remodel leading to very difficult

anatomic reduction which end in bone malunion, non-union, or delayed union. In the current study, all patients were treated within 5 days after Road Traffic Accident. There was no difference in the time of starting surgery in the study groups that could affect the final treatment outcome.

Surgical site postoperative infection could be referred to many factors as the surgical site, fracture mobility, hardware type, and technical errors.⁽¹⁰⁾ O'Connell and Murphy⁽¹⁷⁾ encountered 3% plate infections which were removed. Postoperative Infection was reported in 20 % of patients in top-down sequence, and 16.7% in bottom-up sequence, this was referred to the severely comminuted fractures and delayed treatment for 15 days in top-down sequence and 5 days in bottom-up sequence. In the current study, no postoperative infection was recorded in the study groups.

Patients of group 1 treated in Bottom Up- Outside In sequence showed postoperative normal occlusion (83.3%), normal MMO, only one patient (16.7%) had facial asymmetry with no need for 2nd surgery. This sequence is supported by the fact that the mandible is a strong bone and it can be anatomically reduced before the maxilla which in turn prevent the rotation of maxilla and anterior open bite.⁽¹⁸⁾ Moreover, it was recommended that starting by a known and stable area with less displacement or comminution and then working on the unknown comminuted area can provide meticulous reduction.⁽¹⁹⁾

On the other hand, it was recommended to start reconstruction by the NOE fracture, but many surgeons prefer to reconstruct the outer facial projection first through zygomatic body and arch reduction and then proceed to the NOE area as the NOE area with its comminuted or missing bone pieces has less trustworthy landmarks for realignment.⁽¹⁾ In another study, when NOE treated after restoring ZMC, it resulted in deformity in the nasal area and shift in the midline that contradicts with our finding.⁽¹⁰⁾

The patients of group 2 treated in Top Down- Inside Out sequence showed postoperative normal occlusion (83.3%), normal MMO, only one patient (16.7%) had facial asymmetry with no need for 2nd surgery. This sequence was supported by a study reported that the proper mandible and lower face width could be obtained by using the maxillary dental arch as a template for the realignment of the mandibular dental arch.⁽²⁰⁾ Moreover, Manson and Clark⁽⁶⁾ recommended that the maxillary bone should be fixed at the level of the palatal vault posteriorly, and then fixed at the level of the pyriform aperture anteriorly, to serve as a guide for reduction and fixation of the mandibular ridge.

Many surgeons prefer the top-down approach as they get very good results and proper occlusion with this sequence of treatment. This approach starts with a stable fronto-orbital frame and proceed inferiorly. Then horizontal projection and orbital frame could be reduced through the vertical pillars at the naso-frontal region and the lateral orbital rims.⁽¹³⁾ in the current study, the 2 study groups showed the same final treatment outcome which was excellent for 83.7% and good for 16.3%. this result is similar to the results of Degala et al⁽¹⁰⁾ who reported non-significant difference between the two treatment sequences regarding the final treatment outcome although it was excellent in (50 %), good in (16%) and fair in (32%) in topdown treatment sequence, and (60%) excellent and (40%) fair in bottom-up treatment sequence. This could be attributed to infection, nasal deformity, oronasal fistula, and facial asymmetry as reported in the study.

Finally, it was recommended that the surgeon should adjust to the fracture pattern variations instead of following pre-determined treatment sequence, starting from a stable area and proceeding to an unknown area to achieve proper occlusal, vertical and horizontal relationships in the face outline.⁽²⁰⁾ This could be guided by a systematic planning and meticulous application of the plan.

CONCLUSION

The current study found that both of the study groups, bottom-up outside-in and top-down inside-out have similar outcomes regarding the clinical parameters. However, further comparative studies are recommended to evaluate the final clinical outcome with larger sample size.

REFERENCES

- 1- Markowitz, B.L., and Manson, P.N.: Panfacial fractures: Organization of treatment. *Clin. Plast. Surg.*, 16:105-109, 1989.
- 2- Wenig, B.L.: Management of panfacial fractures. *Otolaryngol. Clin. North Am.*, 24:93-98, 1991.
- 3- Kim, J., Choi, J., Chung, Y.K., and Kim, S.W.: Panfacial Bone Fracture and Medial to Lateral Approach. *Arch Craniofac. Surg.*, 17(4): 181-185, 2016.
- 4- Gruss, J.S., and Mackinnon, S.E.: Complex maxillary fractures: role of buttress reconstruction and immediate bone grafts. *Plast. Reconstr. Surg.*, 78(1):9-22, 1986.
- 5- Gruss, J., Antonyshyn, O., Phillips, J.: Early definitive bone and soft-tissue reconstruction of major gunshot wounds of the face. *Plast. Reconstr. Surg.*, 87(3):436-50, 1991.
- 6- Manson, P.N., Clark, N., Robertson, B., Slezak, S., Wheatly, M., and Kolk, C.V.: Sub-unit principles in midface fractures: The importance of sagittal buttresses, soft tissue reductions, and sequencing treatment of segmental fractures. *Plast. Reconstr. Surg.*, 103(4): 1287-1307, 1999.
- 7- Tang, W., Feng, F., and Long, J.: Sequential surgical treatment for panfacial fractures and significance of biological osteosynthesis. *Dent. Traumatol.*, 25:171-178, 2009.
- 8- de Melo, W.M., Sonoda, C.K., Shinohara, E.H., and Garcia, I.R.: Using the "bottom-up and outside-in" sequence for panfacial fracture management: does it provide a clinical significance? *J. Craniofac. Surg.*, 24:479-81, 2013.
- 9- Yang, R., Zhang, C., Liu, Y., and Li, Z.: Why should we start from mandibular fractures in the treatment of panfacial fractures? *J. Oral Maxillofac. Surg.*, 70:1386-92, 2012.
- 10- Degala, S., Sundar, S.S., and Mamata, K.S.: A Comparative Prospective Study of Two Different Treatment Sequences i.e., Bottom Up-Inside Out and Topdown-Outside in, in the Treatment of Panfacial Fractures. *J. Maxillofac. Oral Surg.*, 14:986-94, 2015.
- 11- Louis, P.J. Management of pan facial fractures. In: Miloro M (ed) *Peterson's principles of oral and maxillofacial surgery*, chap 28, vol 1, 2nd edn. BC Decker Inc, Hamilton pp 547-559, 2004.
- 12- Zhang, Y.: Delayed pan-facial fractures—Injury patterns associated with deficient treatment results and clinical classification. *Zhonghua Kou Qiang Yi Xue Za Zhi*, 43:231, 2008.
- 13- Kelly, K.J., Manson, P.N., and Vander Kolk, C.A.: Sequencing Le Fort fracture treatment (organization of treatment for a panfacial fracture). *J. Craniofac. Surg.*, 1:168-178, 1990.
- 14- Clauser, L., Galie, M., and Mandrioli, S.: Severe panfacial fracture with facial explosion: integrated and multistaged reconstructive procedures. *J. Craniofac. Surg.*, 14:893-898, 2003.
- 15- He, D., Zhang, Y., and Ellis, E. Pan facial fracture: analysis of 33 cases treated late. *J. Oral Maxillofac. Surg.*, 06: 625-632, 2007.
- 16- Carr, R.M., and Mathog, R.H. Early and delayed repair of orbito-zygomatic complex fractures. *J. Oral Maxillofac. Surg.*, 55:253-259, 1997.
- 17- O'Connell, J., and Murphy, C.: The fate of titanium miniplates and screws used in maxillofacial surgery: a 10-year retrospective study. *Int. J. Oral Maxillofac. Surg.*, 38:731-735, 2009.
- 18- Tullio, A., and Sesenna, E.: Role of surgical reduction of condylar fractures in the management of pan facial fractures. *Br. J. Oral Maxillofac. Surg.*, 38:472-476, 2000.
- 19- Curtis, W., and Horswell, B.B. : Panfacial Fractures An Approach to Management. *Oral Maxillofac. Surg. Clin. N. Am.* 25: 649-660, 2013.
- 20- Ellis, E., and Throckmorton, G.: Facial symmetry after closed and open treatment of fractures of the mandibular condylar process. *J. Oral Maxillofac. Surg.*, 58:719-728, 2000.