

## Ischemic Preconditioning and/or Propofol Ameliorate Hepatic Injury in Experimental Rats

MOHAMED EL-SAYED MAHMOUD, M.D.\* and MOHAMED Sh. NEGM, M.D.\*\*

*The Departments of Medical Pharmacology\* and Pathology\*\*, Faculty of Medicine, Cairo University, Egypt*

### Abstract

**Background:** Ischaemic Preconditioning is an efficient maneuver to ameliorate liver injury by induction of endogenous defence against ischemia. Propofol is widely used in general anesthesia, and it has been reported to protect various organs against ischemia-reperfusion injury (IRI), including liver.

**Aim of Study:** To study hepatoprotective effects of ischemic preconditioning (IP) and/or propofol, and the possible underlying mechanisms in rats.

**Material and Methods:** 30 Male Spraguee Dawley rats were divided into 5 groups: Sham group (n 6), non-IP group (n 6; 45 minutes of hepatic ischemia followed by 2 hours of reperfusion), and IP group (n 6; IP applied as 10 minutes of hepatic ischemia followed by 15 minutes of reperfusion before 45 minutes of ischemia, propofol group (n 6) infused 800 µg/kg/min 45 minutes of hepatic ischemia followed by 2 hours of reperfusion, propofol and IP group n 6. Anesthesia was maintained with intraperitoneal xylazine. Liver enzymes, histopathological changes, and cytokine expression were assessed.

**Results:** The Ischaemic Preconditioning, propofol and Ischaemic Preconditioning-propofol groups showed significantly lower liver enzyme levels and reduced the histologic scoring of liver 2 hours after reperfusion compared to the non-IP group. Lactate dehydrogenase activity and interleukin-6 mRNA levels were significantly higher in the non-IP group than in the sham and IP groups.

**Conclusions:** Our results demonstrate that IP and propofol significantly attenuated hepatic IRI. The principal mechanism of the protective effects through reduced expression of the IL-6 pro-inflammatory cytokine and propofol antiapoptic effect with subsequent reduction of the degree of necrosis.

**Key Words:** *Ischaemic preconditioning – Propofol – Ischaemia reperfusion injury – Liver.*

### Introduction

**PRINGLE** maneuver is commonly done during hepatic surgery in which liver blood supply are

clamped. Total hepatic ischemia/reperfusion is commonly found in the central macrosection of the liver tumor or the liver area. Recent studies reported that hepatic ischemia-reperfusion injury (HIRI, I/RI) has local and general reaction which influence function of liver and damage for far organs [1-4]. The main mechanisms may be derived from increased oxygen radical and calcium overload in cells, and the former is the most important factor [5-7]. In our study we try to prevent and cure post-HIRI liver injury.

IRI is an important cause of morbidity and mortality in patients during liver surgery, and intermittent interruption of hepatic blood flow. Mechanisms of hepatic IRI include microcirculation dysfunction, reactive oxygen species (ROS), activation of Kupffer cells, and calcium overload, which cause liver dysfunction [3]. The main mechanisms may be increased oxygen radical and calcium over-load in cells, and the former is the most important factor [5].

Murry et al., [4] are the first that demonstrated the protective effects of ischemic preconditioning (IP) against myocardial IRI [4,5].

IP is an efficient maneuver to ameliorate liver injury by induction of endogenous defence against ischemia.

Propofol (2, 6-diisopropylphenol) is an intravenous (IV) anesthetic agent used to induce and maintain anesthesia. It has been demonstrated that IP with the commonly used volatile agents, isoflurane, and sevoflurane show protective effects against hepatic IRI in rats [6,7]. Propofol also ameliorate liver damage. Propofol has been widely applied in current clinical anesthesia, and it is the common drug to study protection of ischemia reperfusion injury. Propofol can protect far organs in liver ischemia reperfusion in rats [15].

**Correspondence to:** Dr. Mohamed El-Sayed Mahmoud,  
The Department of Medical Pharmacology,  
Faculty of Medicine, Cairo University, Egypt

## Material and Methods

### Chemicals and reagents:

Propofol Sandoz milky white liquid in a clear vial available as sterile emulsion (USA); Propofol Sandoz Emulsion for injection (S4) Propofol; glycerol, soya oil, egg lecithin; white; aqueous Xylazine (Solution, Adwia; Egypt); AST, ALT, LDH, Serum tumor necrosis factor- $\alpha$  (TNF- $\alpha$ ), interleukin-1 beta (IL-1 $\beta$ ) and interleukin-6 (IL-6) concentrations ELIZA kits (Sigma-Aldrich).

### Animals:

30 Male Sprague Dawley rats (weight, 280 to 320g; age, 7 to 8 weeks), purchased from animal house; Research Institute of Ophthalmology; Giza, Egypt. All experimental procedures will be performed according to The Recommendations from the Institutional animal care and use committee (IACUC) Cairo University. Before the commencement of any intervention, this study was approved by (IACUC). This study was carried out in the Pharmacology Department, Faculty of Medicine, Cairo University, 2021.

### Experimental protocol:

Male Sprague Dawley rats (weight, 280 to 320g; age, 7 to 8 weeks), maintained under standard laboratory conditions at 25 °C & normal photoperiod (12 hr dark/12 hr light) are used for the experiment.

### Experimental design:

Male Sprague Dawley rats (weight, 280 to 320g; age, 7 to 8 weeks) were used:

Thirty rats were randomly divided into the following 5 groups:

- Group I: Control group (sham, n 6).
- Group II: Hepatic ischemia-reperfusion (IR) group (non-IP, n 6).
- Group III: IP group (n 6).
- Group IV: Propofol group (n 6).
- Group V: IP and Propofol group (n. 6).

### Interventions:

Surgery was performed by the same researcher under aseptic conditions. The rats were anesthetized with xylazine 100mg/kg intraperitoneal. All rats were set on an electrical heating pad in a supine position, A 5mL saline solution were injected hourly into the intraperitoneum for hydration. Tracheal intubation was performed with cannula, and the lungs were ventilated mechanically at 50 to 65 breaths/min (Bioscience, United Kingdom).

The femoral artery was cannulated to monitor mean arterial blood pressure (MAP) and obtain blood samples. After stabilizations, a 4cm midline laparotomy were performed with local anesthesia using 1% lidocaine. When the abdominal cavity was exposed, the falciform ligament were resected. Depending on the assigned group, a microvascular clamp was applied at the portal triad to the median and left lateral liver lobes. The microvascular clamp was maintained during 45 minutes of ischemia in the non-IP group, and the rats were observed in the laparotomy state for 2 hours after reperfusion.

In the IP group, 10 minutes of IP were induced followed by 15min of reperfusion before 45 minutes of hepatic ischemia [8,9]. The duration of IP and sustained ischemia as previous studies [6,7]. In propofol group is infused at rat of 800  $\mu\text{g}/\text{kg}/\text{min}$ .

After this period, the surgical procedures were the same as those in the non-IP group. At 2 hours of reperfusion, all the rats were sacrificed.

### Biochemical measurements:

Serum levels of AST aminotransferase (AST, a nonspecific marker for hepatic injury) & ALT aminotransferase (ALT, a specific marker for hepatic parenchymal injury were measured initially (before hepatic ischemia, AST1, and ALT1) and 2 hours after reperfusion (AST2 and ALT2). Using ELIZA kits assay (Sigma-Aldrich; USA).

Serum Lactate Dehydrogenase (LDH) was measured using ELISA KITS (Sigma-Aldrich, St. Louis, Mo, United States).

Serum tumor necrosis factor- $\alpha$  (TNF- $\alpha$ ), interleukin-1 beta (IL-1 $\beta$ ), interleukin-6 (IL-6) and Bcl-2 concentrations were measured with ELISA kits that specifically designed for rat cytokines, and all measurements were performed in accordance with the manufacturer's instructions

Tumour necrosis factor  $\alpha$  (TNF $\alpha$ ) and interleukin-1  $\beta$  (IL-1  $\beta$ ) are pleiotropic mediators of biologic responses related to infection, immunity, and inflammation (Le and Vilcek, 1987). IL-1, TNF $\alpha$  and IL-6 are cytokines with overlapping biological properties which form a complex network of interactive signals. They are considered major mediators of fever and the production of acute phase proteins (Baumann and Gauldie, 1990).

### Tissue collection:

After the operation, liver samples were obtained from the anterior edge of the median lobe at the time of sacrifice.

**Histopathological:**

Presentative sections were sampled from dissected organs in cassettes and were fixed in formaline 10% for 24 hour then processed in tissue processor overnight. Paraffin blocks were prepared. One section was cut from each paraffin block by microtome at 5 microns thickness; then stained with hematoxylin and Eosin for routine histopathological examination.

**Haematoxylin and Eosin (H & E):** (1) Deparaffinise in xylene-2 changes. (2) Absolute alcohol. (3) 95% alcohol. (4) Rinse in tap water. (5) Harris haematoxylin-6 minutes. (6) Wash in tap water. (7) Decolorize with 1% acid-alcohol-quick dips. 8. Wash in tap water. (9) Blue in 1% lithium carbonate - 2-3 dips. (10) If lithium carbonate is not available, use ammonia water. (11) Wash with tap water (check under the microscope-nuclei should be distinct blue and the background light or colorless). (12) If it is not well stained, stain again in

Harris" haematoxylin for 2-3 minutes. (13) If over stained decolorize again with 1% acid alcohol - quick dips. (14) Wash with tap water. (15) Counter stain in 1% eosin-2-3 quick dips. (16) Wash quickly with tap water. (17) 95%, alcohol. (18) Absolute alcohol-2 changes. (19) Xylene - 2 changes. (20) Mount.

**Results:** Nuclei-Blue Cytoplasm-Pale pink.

**Photography:** The digital images of the selected tissue preparations were photographed using a Olympus DP26 digital net camera attached to a Olympus CX31 Microscope.

Concerning the liver biopsies, grading of inflammation according to ISHAK scoring system, these assign numbers to the severity of the necro-inflammatory features (interface hepatitis, confluent necrosis, parenchymal injury and portal inflammation) and add the numbers to arrive at a grade that can range from 0 to 18.

**ISHAK score.**

Periportal or periseptal interface hepatitis (piecemeal necrosis)	Confluent necrosis	Focal (spotty) lytic necrosis, apoptosis and focal inflammation	Portal inflammation
None	0 None	0 None	0 None
Mild (focal, few portal areas)	1 Focal confluent necrosis	1 One focus or less per 10• objective	1 Mild some or all portal tracts
Mild/moderate (focal, most portal areas)	2 Zone 3 necrosis in some areas	2 Two to four foci per 10• objective	2 Moderate some or all portal tracts
Moderate (continuous around <50% of tracts or septa)	3 Zone 3 necrosis in most areas	3 Five to ten foci per 10• objective	3 Moderate/marked in all portal tracts
Severe (continuous around >50% of tracts or septa)	4 Zone 3 necrosis + occasional portal-central bridging	4 More than 10 foci per 10• objective	4 Marked in all portal tracts
	5 Zone 3 necrosis + multiple portal-central bridging	5	
	6 Panacinar or multiacinar necrosis	6	

**Statistical analysis:**

Data was transferred to the Statistical Package of Social Science Software program, version 24 (SPSS) to be statistically analyzed.

Data was summarized using mean, and standard deviation for quantitative variables and frequency and percentage for qualitative ones.

Comparison between groups was performed using one way ANOVA with Tukey's post hoc test for quantitative variables and Chi square or Fissure exact test for qualitative ones.

p-values less than 0.05 were considered statistically significant, and less than 0.01 were considered highly significant.

**Results**

Group I: *Control group (sham, N 6):*

Mean arterial blood pressure: (MAP): Within normal range allthrough the experiment.

**AST and ALT:**

- Initial AST ALT: AST1 60±10; ALT1 40±8.
- Two hours after reperfusion: AST2: 55±9; ALT2: 60±8. Table (1).
- LDH activity two hours after reperfusion: 640 ±280mU/mL Table 2).
- Il-1 β, IL-6 TNF-α and Bcl-2 at 2 hours after reperfusion: Within normal range (Table 3).

*Histopathologically:* The portal tracts are within normal. The hepatocytes are within normal. ISHAK 0 (H&E, 100x) Fig. (1).

Group II: *Hepatic ischemia-reperfusion (IR) group (non-IP, N 6):*

Mean arterial blood pressure: (MAP): Within normal range allthrough the experiment.

*AST and ALT:*

- Initial AST ALT: AST1 50±10; ALT 1 36±8 U/L.
- Two hours after reperfusion: AST2: 600 ±86; ALT2: 580±18U/L. Which is significantly higher than group I (*p*-value <0.05) Table (1).
- LDH activity two hours after reperfusion: 2300±227mU/mL. Which is significantly higher than group I (*p*-value <0.05) Table (2).
- IL-1-β, IL-6; TNF-α and Bcl-2, at 2 hours after reperfusion: A significant high level. W is significantly higher than group I Table (3).

*Histopathologically:* Sections revealed liver tissue showing two foci of spotty necrosis. ISHAK 8 (H&E, 200x): Sections examined revealed liver tissue of rat. The hepatocytes showed minimal hydropic degeneration. The portal tract showed mild inflammatory cellular infiltrate including lymphocytes and plasma cells. Focal interface hepatitis seen. Fig. (2).

Group III: *IP Group (N 6):*

Mean arterial blood pressure: (MAP): Within normal range allthrough the experiment.

*AST and ALT:*

- Initial AST ALT: AST1 55 ±8; ALT1 30±10U/L.
- Two hours after reperfusion: AST2: 300 ±50; ALT2: 220±40U/L. Show significant lower level vs. non IP group Table (1).
- LDH activity two hours after reperfusion: 1450±222mU/mL. Show significant lower level vs. non IP group Table (2).
- IL-1 β ; IL-6 TNF-α and Bcl-2 at 2 hours after reperfusion: Show lower level than non IP group however IL6 significantly lower vs. non-IP group Table (3).

*Histopathologically:* Sections revealed liver tissue. The portal tracts are expanded by mixed inflammatory cellular infiltrate with focal interface hepatitis. The hepatocytes showed focus of spotty necrosis. ISHAK 4 (H&E, 100x) Fig. (3).

Group IV: *Propofol group (N 6):*

Mean arterial blood pressure: (MAP): Within normal range allthrough the experiment).

*AST and ALT:*

- Initial AST ALT: AST1 40±1 8; ALT1 40±10 U/L.
- Two hours after reperfusion: AST2: 240±48; ALT2: 200±40U/L show significant lower level vs. non IP Table (1).
- LDH activity two hours after reperfusion: 1360±130mU/mL. Show significant lower level vs. non IP Table (2).
- TNF-α, and IL-1 β at 2 hours after reperfusion: Within higher levels however IL6 and Bcl-2 significantly lower vs. non-IP group Table (3).

*Histopathologically:* Sections examined revealed liver tissue. A focus of spotty necrosis seen. ISHAK 3 (H&E, 200x) Fig. (4).

Group V: *IP and propofol (N 6):*

Mean arterial blood pressure: (MAP): Within normal range allthrough the experiment.

*AST and ALT:*

- Initial AST ALT: AST1 54±9; ALT1 46±9U/L.
- Two hours after reperfusion: AST2: 180±40; ALT2: 160±30U/L. Show significant lower level vs. non IP F. (1).
- LDH activity two hours after reperfusion: 1160±140mU/mL. Show significant lower level vs. non IP Fig. (2).
- TNF-α, and IL-1 β at 2 hours after reperfusion: Within normal range however IL6 and Bcl-2 significantly lower vs. non-IP group Table (3).

*Histopathologically:* Sections revealed liver tissue. The portal tracts are within normal. The hepatocytes are within normal. ISHAK 1 (H&E, 100x) Fig. (5).

Table (1): Serum levels of aspartate aminotransferase (AST) and alanine aminotransferase (ALT).

	Group I	Group II	Group III	Group IV	Group V
AST1	60±10	50±10	55±8	40±18	54±9
ALT 1	40±8	36±8	30±10	40±8	46±9
AST2	55±9#	600±86*#	300±50*	240±48*	180±40*
ALT2	60±8#	580±18*#	220±40*	200±40*	160±30*

A- AST1 : ALT1 levels before hepatic ischemia.  
 B- AST2 : ALT2 level at 2 hours after reperfusion.  
 ALT 2 : \**p*-value <0.05 group II vs other groups.  
 #*p*-value is 0.001 group II vs group I.  
 AST2 : \**p*-value <0.05 group II vs other groups.  
 #*p*-value is 0.001 group II vs group I.

Table (2): Lactate dehydrogenase (LDH) activity assay 2 hours after reperfusion. IP, ischemic preconditioning; Non-IP, non-ischemic preconditioning.

	Group I	Group II	Group III	Group IV	Group V
LDH	640±280*	2300±227* *#,##,###	1450±222#	1360±130##	1160±140###

\*Group II vs group I, *p*.001.

#Group II vs group III#.

IV##.

V###, *p*-value (< .005; 0.05; 0.001) respectively.

Table (3): Serum levels of interleukin 1 β ( IL-1 β ), interleukin-6 (IL-6), tumor necrosis factor- α (TNF-α) and Bcl-2.

	IL 1β	IL 6	TNF α	Bcl-2
Group I	26±4abc	25±10#	75±20	30±10
Group II	120±10a	130±14#	150±14	120±30*
Group III	110±12b	83±9	140±24	100±24
Group IV	100±14c	80±16	126±16	40±10
Group V	80±20d	54±11	104±12	28±8*

a Denotes significant difference between Group I vs Group II *p*-value 0.001

b Denotes significant difference between Group I vs Group III *p*-value <0.01

c Denotes significant difference between Group I vs Group IV *p*-value 0.01

d Denotes significant difference between Group I vs Group V *p*-value <0.05

# Denotes significant difference between Group I vs Group II *p*-value 0.001.

\* Denotes significant difference between Group II vs Group V *p*-value 0.001.

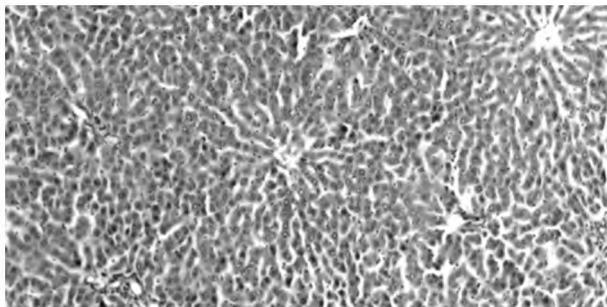


Fig. (1): Sections revealed liver tissue. The portal tracts are within normal. (H&E, 200x) Ishak score 0.

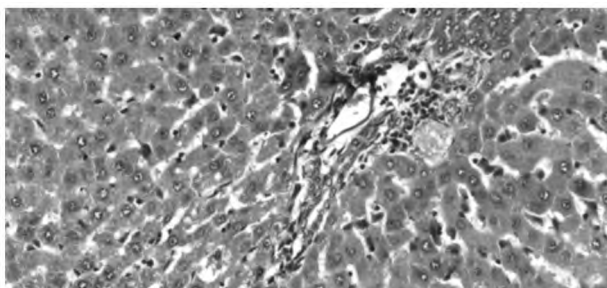


Fig. (2): Sections revealed liver tissue. The portal tracts are expanded by mixed inflammatory cellular infiltrate with focal interface hepatitis. The hepatocytes showed focus of spotty necrosis. ISHAK 8 (H&E, 200x).

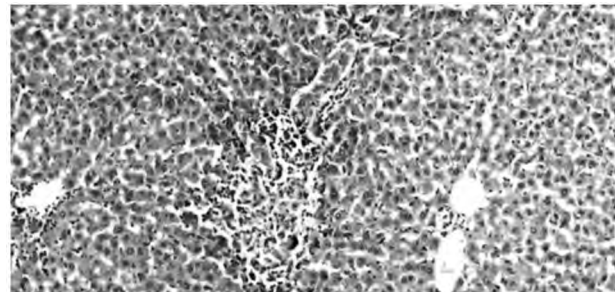


Fig. (3): Sections revealed liver tissue. The portal tracts are expanded by mixed inflammatory cellular infiltrate with focal interface hepatitis. The hepatocytes showed focus of spotty necrosis. ISHAK 4 (H&E, 100x).

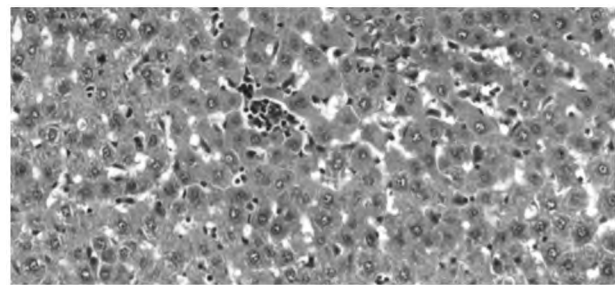


Fig. (4): Sections examined revealed liver tissue. A focus of spotty necrosis seen. ISHAK 3 (H&E, 200x).

### Discussion

Our study showed that IP and/or propofol attenuated hepatic IRI in rats where serum transaminases levels and histologic findings results showed. IP and propofol provide protection to the liver and far organs, by increasing tolerance against organ hypoxia [11,12].

Propofol and its lipid vehicles are metabolized mainly in the liver and eliminated by the liver and kidneys [13]. Yamada et al., [14] assessed the interaction between anesthetic conditioning (sevoflurane vs propofol) and IP on metabolic function after hepatic IRI in rabbits. They showed that galactose clearance, a surrogate marker for hepatocyte function, was increased in propofol group with IP, and it represented that application of IP may be selectively protective and propofol.

In contrast, the results of our study revealed that IP effectively attenuated hepatic IRI as shown by the lower level of LDH activity. LDH activity is a necrosis indicator and it was used as a direct marker of cell damage induced by hepatic IRI. Moreover, improved serum transaminase levels and less severe morphologic changes in hepatocytes were observed 2 hours after reperfusion by applying IP and propofol or both.

IL-6 plays a major role in host defense and inflammation, and it is produced by immune cells

at the injury site as a consequence of systemic insults [15]. Previous experimental study reported that IP reduces the expression of IL-6 accompanied by alleviated hepatic IRI in rats undergoing liver transplantation [16]. They suggested that IP alleviated hepatic IRI associated with suppressing IL-6 expression. In agreement to these results, the expression of IL-6, the pro-inflammatory cytokine, was significantly reduced after IP and propofol in our study. Thus, we suggest that the principle protective mechanism of IP under propofol anesthesia might be associated with reduction of inflammation and subsequent reduction of the degree of necrosis.

Bcl-2 is an indicator of apoptosis and decreased by administration of propofol which indicate an anti-apoptotic effect.

A previous study compared liver enzymes and histopathological results at different times after reperfusion [17]. The authors concluded that prolonged ischemia > 2 hours increases hepatocellular necrosis without increasing apoptosis. Longer periods of time after reperfusion might permit the detection of various changes in cytokine expression, leading to different outcomes.

In conclusion, the results of this study showed that IP and/or propofol significantly attenuated hepatic IRI as demonstrated by improved liver function tests, the principal mechanism underlying the protective effects of IP appeared to involve downregulation of LDH activity, IL-6 expression and Bcl-2 level.

### References

- 1- NAGINO M., KAMIYA J., ARAI T., NISHIO H., EBATA T. and NIMURA Y.: One hundred consecutive hepatobiliary resections for biliary hilar malignancy: Preoperative blood donation, blood loss, transfusion, and outcome. *Surgery*, 137: 148e55, 2005.
- 2- JAESCHKE H.: Mechanisms of reperfusion injury after warm ischemia of the liver. *J. Hepatobiliary Pancreat Surg.*, 5: 402e8, 1998.
- 3- CHOUKER A., SCHACHTNER T., SCHAUER R., et al.: Effects of Pringle manoeuvre and ischaemic preconditioning on haemodynamic stability in patients undergoing elective hepatectomy: A randomized trial. *Br. J. Anaesth.*, 93: 204e11, 2004.
- 4- MURRY C.E., JENNINGS R.B. and REIMER K.A.: Preconditioning with ischemia: A delay of lethal cell injury in ischemic myocardium. *Circulation*, 74: 1124e36, 1986.
- 5- PETROWSKY H., McCORMACK L., TRUJILLO M., SELZNER M., JOCHUM W. and CLAVIEN P.A.: A prospective, randomized, controlled trial comparing intermittent portal triad clamping versus ischemic preconditioning with continuous clamping for major liver resection. *Ann. Surg.*, 244: 921e8. discussion 8-30, 2006.
- 6- KO J.S., GWAK M.S., KIM G.S., et al.: The protective effect of ischemic preconditioning against hepatic ischemic-reperfusion injury under isoflurane anesthesia in rats. *Transplant Proc.*, 45: 1704e7, 2013.
- 7- JEONG J.S., KIM D., KIM K.Y., et al.: Ischemic preconditioning produces comparable protection against hepatic ischemia/reperfusion injury under isoflurane and sevoflurane anesthesia in rats. *Transplant Proc.*, 49: 2188e93, 2017.
- 8- CLAVIEN P.A., YADAV S., SINDRAM D. and BENTLEY R.C.: Protective effects of ischemic preconditioning for liver resection performed under inflow occlusion in humans. *Ann. Surg.*, 232: 155e62, 2000.
- 9- YADAV S.S., SINDRAM D., PERRY D.K., CLAVIEN P.A.: Ischemic preconditioning protects the mouse liver by inhibition of apoptosis through a caspase-dependent pathway. *Hepatology*, 30: 1223e31, 1999.
- 10- BEDIRLI N., OFLUOGLU E., KEREM M., et al.: Hepatic energy metabolism and the differential protective effects of sevoflurane and isoflurane anesthesia in a rat hepatic ischemia-reperfusion injury model. *Anesth. Analg.*, 106: 830e7, 2008.
- 11- VASDEKIS S.N., ATHANASIADIS D., LAZARIS A., et al.: The role of remote ischemic preconditioning in the treatment of atherosclerotic diseases. *Brain Behav.*, 3: 606e16, 2013.
- 12- LAZARIS A.M., MAHERAS A.N. and VASDEKIS S.N.: Remote ischemic preconditioning: Myth or reality? *J. Endovasc. Ther.*, 16: 694e5, 2009.
- 13- TAKIZAWA D., HIRAOKA H., GOTO F., YAMAMOTO K. and HORIUCHI R.: Human kidneys play an important role in the elimination of propofol. *Anesthesiology*, 102: 327e30, 2005.
- 14- YAMADA T., NAGATA H., KOSUGI S., SUZUKI T., MORISAKI H. and KOTAKE Y.: Interaction between anesthetic conditioning and ischemic preconditioning on metabolic function after hepatic ischemia-reperfusion in rabbits. *J. Anesth.*, 32: 599e607, 2018.
- 15- NORRIS C.A., HE M., KANG L.I., et al.: Synthesis of IL-6 by hepatocytes is a normal response to common hepatic stimuli. *PLoS One*, 9: e96053, 2014.
- 16- CUI L.Z., WANG B., CHEN L.Y. and ZHOU J.: The effect of ischemic preconditioning to IL-6 on rat liver ischemia-reperfusion injury in transplantation. *Asian Pac. J. Trop. Med.*, 6: 395e9, 2013.
- 17- GUJRAL J.S., BUCCI T.J., FARHOOD A. and JAESCHKE H.: Mechanism of cell death during warm hepatic ischemia-reperfusion in rats: Apoptosis or necrosis? *Hepatology*, 33: 397e405, 2001.

## التهية المسبقة I للكبد و / أو دواء البروبوفول يقلان من إصابة الكبد في جرذان التجارب

مقدمة: تهية الكبد هي طريقة فعالة لتخفيف إصابة الكبد عن طريق تحريض الدفاع الداخلي ضد نقص التروية. يستخدم البروبوفول على نطاق واسع في التخدير العام، وقد تم ذكره عنه حماية الأعضاء المختلفة من إصابة نقص التروية (IRI)، بما في ذلك الكبد.

الهدف من الدراسة: دراسة التأثيرات الوقائية الكبدية للتكييف المسبق الإقفارى و / أو البروبوفول، والآليات الكامنة المحتملة في الجرذان.

في هذه الدراسة تم تقسيم ٣٠ من ذكور جرذان إلى ٥ مجموعات كل مجموعة ستة جرذان مجموعة الأولى (ن ٦)، مجموعة غير تهية الجرذان (٤٥ دقيقة من نقص التروية الكبدى متبوعة بساعتين من ضخه)، ومجموعة تهية الكبد (مطبق ١٠ دقائق من نقص التروية الكبدى متبوعاً به ١٥ دقيقة من ضخه قبل ٤٥ دقيقة من نقص التروية، مجموعة البروبوفول (ن ٦)، مجموعة الأخيرة تهية وبروبوفول وتم تقييم انزيمات الكبد، والتغيرات النسيجية المرضية، والتعبير الخلوى.

نتائج: أظهرت مجموعات الثالثة والرابعة والخامسة انخفاضاً ملحوظاً في مستويات إنزيم الكبد وتقليل التسجيل النسيجي مقارنة بالمجموعة غير تهية الكبد كان نشاط نازعة هيدروجين اللاكتات و مستويات انترلوكين-٦ مرناً أعلى بشكل ملحوظ في المجموعة التى لا تنتمى إلى تهية الكبد.

الاستنتاجات: تظهر نتائجنا أن تهية الكبد والبروبوفول خففا بشكل كبير من إصابة الكبد من خلال تقليل التعبير عن السيتوكين المؤيد للالتهابات IL-6 وتأثير البروبوفول المضاد للالتهاب مع تقليل درجة النخر لاحقاً.