

IJMA



INTERNATIONAL JOURNAL OF MEDICAL ARTS

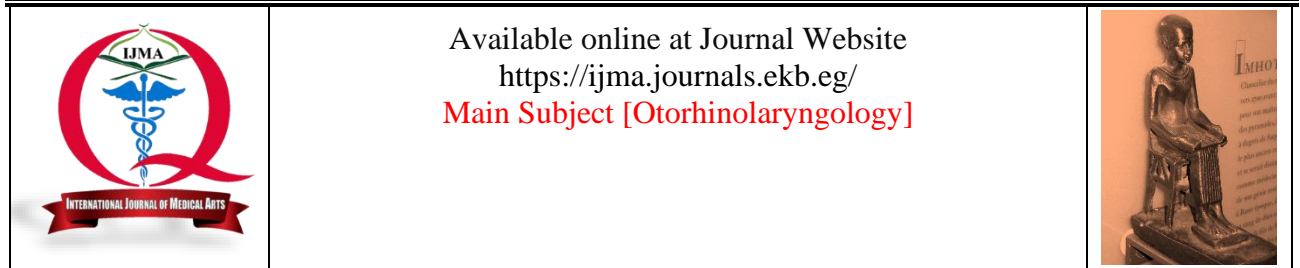
2/2022 (volume 4, Issue 2)



<http://ijma.journals.ekb.eg/>

Print ISSN: 2636-4174

Online ISSN: 2682-3780



Available online at Journal Website
<https://ijma.journals.ekb.eg/>
 Main Subject [Otorhinolaryngology]



Original Article

Incidence of Postoperative Complications following Coblation Tonsillectomy with and Without Sutures

Ezz Aleslam Abdelhakim Mohamed ^{[1]*}; Mohamed Abdelkawy Fathallah ^[1]; Ahmed Mohamed Ahmed Seleim ^[2]

¹ Department of Otorhinolaryngology, Damietta Faculty of Medicine, Al-Azhar University, Egypt.

² Department of Otorhinolaryngology, Faculty of Medicine, Al-Azhar University, Egypt.

ABSTRACT

Article information

Received: 08-12-2021

Accepted: 18-02-2022

DOI: 10.21608/ijma.2022.110132.1408

*Corresponding author

Email: ezzaleslamalmasry@gmail.com

Citation: Mohamed EA, Fathallah MA, Seleim AMA. Incidence of Postoperative Complications following Coblation Tonsillectomy with and Without Sutures. IJMA 2022 Feb; 4 [2]: 2176-2181. doi: 10.21608/ijma.2022.110132.1408

Background: Tonsillectomy is the commonest surgical procedure performed by otolaryngologists. Many surgical techniques and instruments are available and continually developed to reduce postoperative complications. However, no consensus exists regarding the standard technique.

The Aim of The Work: The current work aimed to compare the incidence of postoperative complications [bleeding and pain], after coblation tonsillectomy with and without sutures.

Patients and Methods: The study included 60 patients with chronic tonsillitis scheduled for elective tonsillectomy. They categorized to either coblation with or without sutures. All were preoperatively assessed by history taking, physical examination and laboratory investigations. After surgical intervention, the follow-up was continued for 4 weeks. Any complications [especially pain and hemorrhage] were documented and compared.

Results: Both groups were comparable regarding patient's age and sex. In addition, laboratory investigations, and pain at the fourth postoperative week were comparable between groups. Postoperative bleeding was reported in 5.0%, and was restricted to coblation without sutures [3 patients; represented 10.0% of the group]; it was mild and treated conservatively [no patient required secondary surgical intervention to control bleeding]. Pain was significantly reduced in coblation with suture than without sutures at the first, the second and the third postoperative weeks [6.40±0.70, 2.90±0.99 and 0.00±0.00 vs 8.8±0.79, 4.33±0.89, and 1.17±0.83, successively]. Pain was completely absent at the fourth postoperative week in both groups.

Conclusion: Coblation with sutures is superior than coblation with sutures for tonsillectomy. It is associated with lower postoperative pain and hemorrhage, which reflects the safety and efficacy of the procedure.

Keywords: Coblation; Sutures; Postoperative; Pain; Hemorrhage; Safety.



This is an open-access article registered under the Creative Commons, ShareAlike 4.0 International license [CC BY-SA 4.0] [<https://creativecommons.org/licenses/by-sa/4.0/legalcode>].

INTRODUCTION

Tonsillectomy is the curative therapeutic intervention for chronic tonsillitis, benign tumors and obstructive sleep apnea-hypopnea syndrome [OSAHS] due to hypertrophy of the tonsil and is considered the commonest surgery performed by otorhinolaryngologists [1].

Total tonsillar resection with the capsule [i.e., extracapsular tonsillectomy] is the commonest tonsillectomy technique done in the United States, irrespective of its drawback of increasing the bleeding risk than the intracapsular method [due to greater exposure of the tonsil's blood supply], but intracapsular TE is not routinely performed for adult patients [2,3].

Although tonsillectomy is frequently carried out in pediatric populations due to repeated inflammations and obstructive manifestations, it could be performed in adult patients with recurrent infections, obstructive symptoms, or tumors [4].

A study by Windfuhr *et al.* [5] compared coblation with conventional dissection of the tonsils, coblation revealed many advantages including shorter operative time, less intra-operative bleeding, lower accidental surrounding tissue injuries and lower pain postoperatively.

Bleeding is the commonest immediate post-tonsillectomy complication, regardless of surgical method, comprising coblation. Primary bleeding [within 24 h] reported in 0.2% - 10%, while secondary bleeding [after 24 h, often at 7-10 days] reported in 0.1% - 5% of the overall patients and increased to 53% in patients with bleeding diathesis. Unlikely, most researches about post-tonsillectomy bleeding in adults are infrequent and the amount and quality of the data are small [6].

The value of using sutures to reduce the incidence of post tonsillectomy bleeding [PTB] is debatable among otolaryngologists. An early trial demonstrated that the use of sutures with absorbable hemostat is associated with higher pain but reduced the bleeding incidence in the postoperative follow up. Another trial demonstrated that the use of sutures to close the tonsillar fossa did not decrease the bleeding risk, but increased postoperative pain. Nevertheless, the participants in these studies [previous two] underwent many techniques of surgery [7]. Therefore, the current study intended to assess the post-tonsillectomy rate of bleeding and severity of pain in patients who submitted to coblation with or without sutures. The expected results seem to add to available literature about the value of the suture with coblation tonsillectomy, or even elucidate the controversy about the procedure.

THE AIM OF THE WORK

This study aimed to compare the incidence of postoperative complications [bleeding and pain], following coblation tonsillectomy with and without sutures.

PATIENTS AND METHODS

The present work was a prospective, randomized comparative study. It had been completed at the department of otorhinolaryngology Head and Neck Surgery Department, Al-Azhar University Hospital [Damietta], during 8 months' duration, from February 2021 to September 2021. It included sixty patients who were scheduled to tonsillectomy and fulfill the inclusion criteria. We included patients of both sexes, who had chronic tonsillitis and tonsillar hypertrophy, provided that, their age ≥ 14 years old. On the extreme side, we excluded patients who refused surgery, pregnant women or those at menstrual period, patients with bleeding tendency, coagulation disorder or who had a contraindication to general anesthesia, patients with acute pharyngeal inflammation, and patients on aspirin treatment within one week before surgery or who had positive family history of coagulation diseases. Patients were randomized and divided into two equal groups according to their admission number, which first patient assigned by lottery.

Group A [Non-suture group] included 30 patients who submitted to coblation tonsillectomy without intra-operative suture. Group B [suture group] included 30 patients who submitted to coblation TE with intraoperative suture. Each patient was preoperatively evaluated by history taking, clinical examination and laboratory investigations [e.g., complete Blood Count [CBC], kidney function tests, liver function tests, and coagulation profile].

Surgical techniques: After preoperative preparations, the procedure had been explained for each patient and/or his/her guardians. Then, each patient signed an informed consent. All patients were operated under general anesthesia in roses position [supine with slight elevation of the shoulders by sandbags]. A mouth gag was introduced to expose the oropharynx. The type of used device for coblation was COBLATTOR II [ArthroCare ENT with serial number CE0Q000CYF manufactured in USA in 2007 by Smith & Nephew] [Figure 1]. The coblation tonsillectomy was performed by disposable scalpel low-temperature plasma surgical system. The ablation power was adjusted at the 7th intensity for the intraoperative resection, and hemostasis power was adjusted at the 3rd intensity.




Figure [1]: COBLATTOR II [ArthroCare ENT with serial number CE0Q000CYF manufactured in USA in 2007 by Smith & Nephew]

For the non-suture technique, the plasma knife was positioned adjacent to the capsule of tonsil to cut the mucosa. The tonsil was entirely dissected from the superior to the inferior poles. The tonsillar fossa was irrigated [rinsed] by normal saline after complete hemostasis by the plasma wand. The surface of the wound was inspected again to exclude any oozing of the blood. Then, the surgical technique was finalized.

For the coblation with suturing, the removal of the tonsil was completed as previously described. After complete hemostasis, a Vicryl 3-0 was used to produce three-spicule interrupted sutures, including the full-layer of palatopharyngeal and palatoglossal arches, tonsillar fossa from the inferior to the superior poles to close the surgical cavity. The tonsillar fossa was then irrigated by normal saline. The surgical cavity was inspected to exclude blood oozing, and then the surgery was completed. The surgical technique is depicted in figures [2] to [8]. All patients were instructed to fast for 6 hours directly after the surgery and then the soft diet was permitted for one week. Patients were advised to use mouth wash on a regular basis; analgesia and antibiotics were prescribed when indicated.

Regarding the type of post-tonsillectomy bleeding, bleeding within 24 hours after the operation was considered as primary post tonsillectomy bleeding, while bleeding that occur after 24 hours, postoperative was considered secondary post tonsillectomy bleeding. Any bloody secretions appearing within the four postoperative weeks was considered as post tonsillectomy bleeding. The incidence of post tonsillectomy bleeding included the incidence of primary post tonsillectomy bleeding and secondary post tonsillectomy bleeding. The post tonsillectomy bleeding incidence was estimated by dividing the number of cases with post tonsillectomy bleeding/total number of surgeries $\times 100\%$.

According to classification criteria instituted by Windfuhr, the amount of post *tonsillectomy bleeding*, it was categorized into five classes: 1] grade I, for spontaneously stopped bleeding. 2] grade II, for bleeding stopped by infiltration of adrenaline/prothrombin and lidocaine with topical anesthesia. 3] grade III, for hemostasis achieved by ligation, blood transfusion, or interventional techniques under general anesthesia. 4] grade IV, for hemorrhagic shock or patients required hemostasis by external carotid artery ligation. 5] for the failure of all treatment interventions, with death [6].

Regarding post tonsillectomy pain, patients were instructed how to express his pain sensation on the visual analogue scale and a score from 0 [no pain] to 10 [the worst pain].

Post-operative follow-up: All patients were observed for the postoperative first day. Then, follow-up completed in the outpatient clinic for the next 4 weeks [single visit each week unless there was a complication indicating urgent visit]. In each visit, patients were evaluated for the wound healing, bleeding status and pain.

Statistical Analyses: All data were recorded and fed to a statistical package on an IBM-compatible computer. All analyses were performed using SPSS [Statistical package for Social Science] version 23.0 [IBM@SPSS@ Inc., Chicago, USA]. Presented prevalence estimates [n, %] were calculated using the data and screening status to address different sampling probabilities and systematic nonresponse. Quantitative data were expressed as mean and standard deviation, while qualitative data were expressed as number and percentage. Chi square [or appropriate equivalent] test was used to assess association between groups, while Student "t" test was used to compare quantitative data between both groups. The significance level will be set at $\alpha = 0.05$.

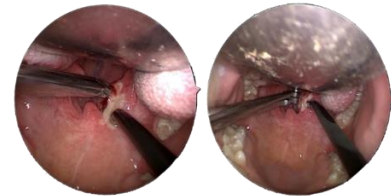


Figure [2]: Traction of the right tonsil to side with tonsillar forceps medially with use of coblation to expose supra-tonsillar fossa.

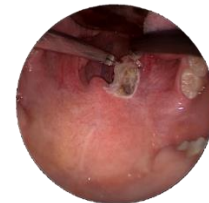

Figure [3] Exposure of supra-tonsillar fossa

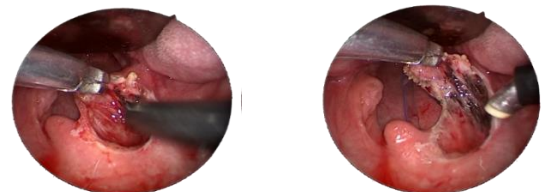


Figure [4]: Separation of right tonsil from its bed

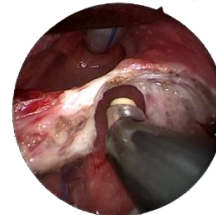


Figure [5]: Almost complete separation of right tonsil from its bed by ablation of its lower end

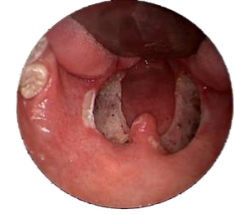

Figure [6]: Coblation tonsillectomy without sutures

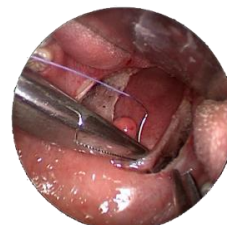

Figure [7]: Suturing of tonsillar bed by Vicryl 3/0.

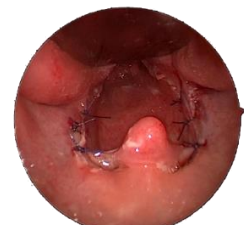

Figure [8]: Coblation tonsillectomy with 3 right and 3 left sutures

RESULTS

There were non-significant differences between the two groups regarding age and sex [Table 1]. Both groups showed non-significant difference regarding all

laboratory investigations [Table 2]. The occurrence of post tonsillectomy bleeding was obvious in the non-suture group in comparison with the suture group. The degree of

postoperative pain was significantly higher in the non-suture group than the suture group [Table 3].

Table [1] Comparison between both groups regarding age and gender distribution.

		Without Suture	With Suture	Test	P value
Sex	Age	22.8± 7.2	25.7± 10.6	1.23	0.22
	Male	8[26.7%]	3[10%]	2.78	0.18
	Female	22[73.3%]	27[90%]		

Table [2]: Comparison between both groups regarding preoperative laboratory investigations

	Without Suture	With Suture	"t"	P value
Hemoglobin	12.27±0.51; 11-13	12.34±0.49; 11.8- 13.2	0.57	0.57
RBCs x 10 ⁶	5.29±0.17; 4.8 -5.6	5.31±0.16; 5.13- 5.60	0.61	0.54
WBCs x 10 ³	5.05±1.02; 3.5-8.2	5.17±0.61; 4.40- 6.50	0.53	0.59
Platelets x 10 ³	265.3±48.7; 210-450	281.70±55.01; 214-421	1.22	0.23
INR	1.12±0.07; 1-1.2	1.09±0.08; 1.0- 1.20	1.37	0.18
ALT [IU/L]	27.07±5.24; 18-36	26.10±5.40; 18.0 – 38.0	0.70	0.49
AST [IU/L]	24.30±4.47; 18-35	25.67±5.44; 18.0- 40.0	1.06	0.29
Creatinine [mg/dl]	0.92±0.13; 0.7- 1.30	0.92±0.13; 0.70 – 1.30	0.10	0.92

Table [3] Comparison between both groups regarding post-operative pain according to [VAS]

Outcome	Time	Without Suture	With Suture	"t"	P value
Pain	The first week	8.8±0.79	6.40±0.70	11.96	<0.001*
	The second week	4.33±0.89	2.90±0.99	5.89	<0.001*
	The third week	1.17±0.83	0.00±0.00	7.66	<0.001*
	The fourth week	-	-	-	-
Bleeding	The first week	3[10.0%]	0[0.0%]	3.15	0.23
	The second week	0[0.0%]	0[0.0%]	-	-
	The third week	0[0.0%]	0[0.0%]	-	-
	The fourth week	0[0.0%]	0[0.0%]	-	-

DISCUSSION

Tonsillectomy is the commonest performed surgery all over the world by otorhinolaryngologists in pediatric and adult populations. The common indications are chronic recurrent tonsillitis, suspicious malignancy, and upper airway obstruction due to hypertrophy. Various surgical techniques and instruments continuedly introduced to aid tonsillectomy, and reduce postoperative complications. These include bipolar diathermy, harmonic scalpels, laser dissection, and, most recently, the coblation technique [8].

Coblation is controlled ablation popularized in 1997 with first commercial use in arthroscopy. Coblation is a unique technique of a quick and controlled tissue removal at a potentially lower temperature [typically 40°-70°C] with the preservation of the integrity of surrounding structures. "Coblation" is newly introduced synthetic term that stands for "cold "and "removal" [9]. The radio-frequency used in a bipolar manner with a conductive saline, coblation energizes the ions in the saline to create a small field of plasma. The field consists of high energy particles like ionized vapour layers, OH, H, Na, free radicals and electron. It has enough energy to break the

molecular bonds between tissues, creating an ablative path [10].

Regardless of surgical technique, there is controversy about the postoperative pain and bleeding. However, coblation, as the most recently introduced technique, received wide acceptance than conventional methods. But, the rate of complications had not yet sufficiently addressed. In addition, the effect of the use of sutures with coblation on postoperative complications had not been investigated in adequate manner [8]. Thus, the current study was designed aiming to address the effect of sutures with coblation on post-tonsillectomy complications [mainly, pain and hemorrhage]. Both groups [30 patients each] were assigned to coblation with and without sutures. Results revealed that, both groups were similar regarding patient demographics, and for results of laboratory investigations. Bleeding was confined to coblation without sutures and reported in 10% of patients [it was of grade I, occurred at the 6th and 7th days postoperatively, and treated conservatively]. The overall rate of post-tonsillectomy bleeding in the current work is 5%.

In recent years, the coblation has been widely used in clinical settings. It had several advantages like less tissue destruction, clear field, decreased wound, and less blood loss during surgery [11]. Therefore, this method had

become increasingly used in tonsillectomy. However, several prior trials demonstrated that the rate of post-tonsillectomy bleeding, specifically the secondary post-tonsillectomy bleeding, was still higher after tonsillectomy by coblation^[12].

The incidence of post-tonsillectomy bleeding in the current study is in line with the incidence reported in previous studies. For example, Windfuhr *et al.*^[5] reported that, although coblation is superior than conventional tonsil dissection, it is not devoid of postoperative bleeding and post-tonsillectomy bleeding continues to be the commonest complication of tonsillectomy. Primary bleeding reported in 0.2%-10%, while secondary bleeding reported in 0.1%–5% of the overall patients, which increased to 53% in adults with coagulopathic disorders.

In previous studies on coblation tonsillectomy, Kim JW *et al.*^[13] reported an overall bleeding rate of 2.9% in 1082 patients, Soderman *et al.*^[14] reported an overall bleeding rate of 13.8% in 1424 adult and pediatric patients, and He Y *et al.*^[15] reported an overall post-operative bleeding rate of 1.9% in 2045 children.

Whether adding sutures would decrease the incidence of post tonsillectomy bleeding is debatable among otorhinolaryngologists. Research by Matt *et al.*^[7] demonstrated that the use of suture to close the tonsillar fossa after tonsillectomy did not decrease the risk of postoperative hemorrhage and increased postoperative pain. These results are in contradiction to the current work, where using sutures was associated with reduction of postoperative bleeding. This contradiction could be explained by the use of different surgical techniques in their study, while we confined to only coblation.

In line with the current results, Zhang *et al.*^[16] retrospectively analyzed files of 5087 patients, 3348 [65.81%] males and 1739 [34.19%] females. 51.03% of these patients underwent tonsillectomy without suture, while 48.97% patients underwent tonsillectomy with suture. They observed non-significant difference between the two groups regarding patient's age and gender. However, secondary hemorrhage rate was statistically higher in the group without suture [1.96%, 51/2596] as compared with the group with suture [1.08%, 27/2491]. These benefits were registered irrespective of longer operative time in the group with than without suture [36.55±7.45 vs 31.50±6.23 minutes, respectively].

Of note, the rate of post-tonsillectomy hemorrhage reported by Zhang *et al.*^[16] is lower than the current study, and this could be attributed to different sample size and study design [retrospective vs prospective natures]. However, Francis *et al.*^[17] in a meta-analysis reported an incidence of 4.1%. This lower rate in comparison to the current work could be attributed to the fact that, they included only cases of severe hemorrhage required admission to operative room. Zhang *et al.*^[16] concluded that, the risk of severe secondary hemorrhage is decreased in coblation tonsillectomy with suture. Specifically in patients 18 to 49 years old group and on the 5th day after surgery.

Results of the current work also supports results of Zhou *et al.*^[18] who retrospectively analyzed files of 515 patients [300 in the coblation group and 215 in the coblation with sutures group]. Age, sex, primary diagnosis and surgical indication were similar between the two groups. 4.9% developed postoperative hemorrhage. The incidence postoperative hemorrhage in the coblation group without sutures was 7.3% compared to 1.4% in the coblation with sutures [$p < 0.05$]. Postoperative hemorrhage occurred at a mean of 7.8 ± 2.1 days after coblation tonsillectomy and 4.5 ± 0.85 days after coblation with sutures.

In the present study, we applied an intraoperative suture to add to the tonsillectomy coblation advantages and decrease the post- tonsillectomy bleeding risk and post tonsillectomy pain. This in line with Wulu *et al.*^[19], who reported that, a suture is an effective hemostatic method used in surgery, which closes the damaged vessels, to stop bleeding.

In agreement with the current results, Liu *et al.*^[20] reported that, the incidence of secondary post-tonsillectomy hemorrhage was lowered in the suture than the non-suture group [2.8% vs. 7.7%, $P = 0.016$].

In a large meta-analysis of 24 randomized controlled trials, data of 796 patients who had undergone coblation TE were analyzed. The total rate of bleeding for the coblation method was 4.1%. The meta-analysis showed that coblation is a safe and effective intervention for tonsillectomy with a lower rate of secondary bleeding^[21].

In the current work, postoperative pain was significantly lower in coblation with sutures than coblation without sutures in the first, the second and the third weeks after surgery. At the fourth week, pain was completely absent in both groups. Additionally, pain was completely absent in all patients in the coblation with sutures group from the third week onwards

The suture closes the tonsillar fossa wound with mucosa, thus decreasing the direct wound exposure, preventing the direct stimulation effect of foods, reducing the rate of infection, and reducing postoperative pain. Suturing not only prevents the postoperative hemorrhage but also help the fast wound recovery and decreased post-tonsillectomy pain. This explanation is in line with that of Liu *et al.*^[20].

Local pain after tonsillectomy is a major drawback. However, Wiltshire *et al.*^[22] showed amazing reduction in postoperative pain and rapid return to normal food intake with coblation. However, current results are in contradiction to Zhou *et al.*^[18] who reported significantly lower postoperative pain levels in coblation without sutures than those with sutures. They attributed the lower pain score in coblation with sutures to lower tissue destruction that increased with sutures.

On the other side, previous trial demonstrated that pain was similar or even worse with the use of sutures than with no sutures^[19], but the current study yielded the

opposite, i.e., lower pain in the suture's group in the first 3 postoperative weeks.

In agreement with the current results, Liu *et al.* [20] reported that, the post-operative pain was significantly lower in the suture than the non-suture coblation group.

In short, results of the present study revealed the superiority of coblation with sutures than coblation without sutures for tonsillectomy. It is associated with lower postoperative pain and hemorrhage reflecting the safety and efficacy of the procedure. Thus, we recommend the use of coblation with sutures as the standard technique for tonsillectomy. However, and due to small sample size of included patients. These results should be treated with caution until more solid evidence obtained from the future studies.

Conflict of interest

None

Financial disclosure:

The authors did not receive any fund from any organization and the fund of the research was provided only by authors.

REFERENCES

- Mitchell RB, Archer SM, Ishman SL, Rosenfeld RM, Coles S, Finestone SA, *et al.* Clinical Practice Guideline: Tonsillectomy in Children [Update]. *Otolaryngol Head Neck Surg.* 2019 Feb; 160 [1_suppl]: S1-S42. doi: 10.1177/0194599818801757.
- Murto KT, Zalan J, Vaccani JP. Paediatric adenotonsillectomy, part 1: surgical perspectives relevant to the anaesthetist. *BJA Educ.* 2020 Jun; 20 [6]:184-192. doi: 10.1016/j.bjae.2020.02.007.
- Zalan J, Vaccani JP, Murto KT. Paediatric adenotonsillectomy, part 2: considerations for anaesthesia. *BJA Educ.* 2020 Jun;20[6]:193-200. doi: 10.1016/j.bjae.2020.03.001.
- Bitners AC, Arens R. Evaluation and Management of Children with Obstructive Sleep Apnea Syndrome. *Lung.* 2020;198[2]:257-270. doi: 10.1007/s00408-020-00342-5.
- Windfuhr JP, Chen YS, Propst EJ, Güldner C. The effect of dexamethasone on post-tonsillectomy nausea, vomiting and bleeding. *Braz J Otorhinolaryngol.* 2011 Jun;77 [3]: 373-9. doi: 10.1590/s1808-86942011000300017.
- Windfuhr JP, Verspohl BC, Chen YS, Dahm JD, Werner JA. Post-tonsillectomy hemorrhage--some facts will never change. *Eur Arch Otorhinolaryngol.* 2015; 272 [5]: 1211-8. doi: 10.1007/s00405-014-3025-3.
- Matt BH, Krol BJ, Ding Y, Juliar BE. Effect of tonsillar fossa closure on postoperative pain and bleeding risk after tonsillectomy. *Int J Pediatr Otorhinolaryngol.* 2012 Dec; 76 [12]:1799-805. doi: 10.1016/j.ijporl.2012.09.004.
- Alsaif A, Alazemi M, Kahlar N, Karam M, Abul A, Al-Naseem A, Muhanna AA, Aldrees T. Tonsillectomy Outcomes for Coblation Versus Bipolar Diathermy Techniques in Adult Patients: A Systematic Review and Meta-Analysis. *Ear Nose Throat J.* 2021 Mar 15; 145561321994995. doi: 10.1177/0145561321994995.
- Pynnonen M, Brinkmeier JV, Thorne MC, Chong LY, Burton MJ. Coblation versus other surgical techniques for tonsill-ectomy. *Cochrane Database Syst Rev.* 2017; 8 [8]: CD004619. doi: 10.1002/14651858.CD004619.pub3.
- Burdio F, Güemes A, Burdío JM, Navarro A, Sousa R, Castiella T, Cruz I, Burzaco O, Lozano R. Bipolar saline-enhanced electrode for radiofrequency ablation: results of experimental study of in vivo porcine liver. *Radiology.* 2003;229[2]:447-56. doi: 10.1148/radiol.2292020978.
- El-Taher M, Aref Z. Coblation Versus Conventional Tonsillectomy: A Double Blind Randomized Controlled Trial. *Indian J Otolaryngol Head Neck Surg.* 2019 Oct;71[Suppl 1]:172-175. doi: 10.1007/s12070-017-1189-z.
- Hsueh WY, Hsu WC, Ko JY, Yeh TH, Lee CH, Kang KT. Postoperative hemorrhage following tonsillectomy in adults: Analysis of population-based inpatient cohort in Taiwan. *Auris Nasus Larynx.* 2019 Jun;46[3]:397-406. doi: 10.1016/j.anl.2018.10.008.
- Kim JW, Mun SJ, Lee WH, Mo JH. Post-tonsillectomy hemorrhage in children: a single surgeon's experience with coblation compared to diathermy. *Eur Arch Otorhinolaryngol.* 2013 Jan;270[1]:339-44. doi: 10.1007/s00405-012-2098-0.
- Soderman AC, Odhagen E, Ericsson E, Hemlin C, Hultcrantz E, Sunnergren O, Stalfors J. Post-tonsillectomy hemorrhage rates are related to technique for dissection and for haemostasis. An analysis of 15734 patients in the National Tonsil Surgery Register in Sweden. *Clin Otolaryngol.* 2015 Jun;40[3]:248-54. doi: 10.1111/coa.12361.
- He Y, Cai Z, Yang J. Revisit rates following pediatric coblation tonsillectomy. *Int J Pediatr Otorhinolaryngol.* 2019 Jul; 122:130-132. doi: 10.1016/j.ijporl.2019.04.013.
- Zhang HL, Yu KN, Jin P, Zhao L, Shi L. Significantly reducing post-tonsillectomy hemorrhage requiring surgery by double-layer suture: A retrospective analysis. *Am J Otolaryngol.* 2020 Nov-Dec;41[6]:102632. doi: 10.1016/j.amjoto.2020.102632.
- Francis DO, Fannesbeck C, Sathe N, McPheeters M, Krishnaswami S, Chinnadurai S. Postoperative Bleeding and Associated Utilization following Tonsillectomy in Children. *Otolaryngol Head Neck Surg.* 2017 Mar;156[3]:442-455. doi: 10.1177/0194599816683915.
- Zhou X, Xu A, Zhen X, Gao K, Cui Z, Yue Z, Han J. Coblation tonsillectomy versus coblation tonsillectomy with ties in adults. *J Int Med Res.* 2019 Oct;47[10]:4734-4742. doi: 10.1177/0300060519867822.
- Wulu JA, Chua M, Levi JR. Does suturing tonsil pillars post-tonsillectomy reduce postoperative hemorrhage? A literature review. *Int J Pediatr Otorhinolaryngol.* 2019 Feb; 117:204-209. doi: 10.1016/j.ijporl.2018. 12.003.
- Liu Q, Zhang Y, Lyu Y. Postoperative hemorrhage following coblation tonsillectomy with and without suture: A randomized study in Chinese adults. *Am J Otolaryngol.* 2021 Jan-Feb; 42[1]: 102760. doi: 10.1016/j.amjoto.2020.102760.
- Mösges R, Hellmich M, Allekotte S, Albrecht K, Böhm M. Hemorrhage rate after coblation tonsillectomy: a meta-analysis of published trials. *Eur Arch Otorhinolaryngol.* 2011 Jun; 268 [6]: 807-16. doi: 10.1007/s00405-011-1535-9.
- Wiltshire D, Cronin M, Lintern N, Fraser-Kirk K, Anderson S, Barr R, Bennett D, Bond C. The debate continues: a prospective, randomised, single-blind study comparing Coblation and bipolar tonsillectomy techniques. *J Laryngol Otol.* 2018 Mar;132[3]:240-245. doi: 10.1017/S0022215117002328.

2/2022

International Journal

<https://ijma.journals.ekb.eg/>

Print ISSN: 2636-4174

Online ISSN: 2682-3780

of Medical Arts