

The Role of Incisional Negative Pressure Wound Therapy in Improving the Outcome of Reduction Mammoplasty, An Egyptian Experience

HAMED M. KADRY, M.D.*; M. ASHRAF, M.D.*; MINA SAMIR NAN, M.Sc.** and OMAR EL-SHARKAWY, M.D.*

The Department of Plastic & Reconstructive Surgery, Faculty of Medicine, Cairo University and Um Masreen General Hospital***

ABSTRACT

Introduction: “T” junction dehiscence puts a burden on the reputation of breast reduction. A lot of methods have been described to solve this issue but still have their limitations. iNPWT is being popularized in different specialties as a preventive solution to problematic incisions (e.g. knee and hip replacements). It helps prevention of wound complications through reduction of edema decreasing tension on wound edges and increasing vascularity. iNPWT has always been advocated not only to help wound healing but it is also suggested it produces a better scar on the long term.

Patients and Methods: Twenty patients presenting seeking breast reduction were included in this study. The Bilateral nature of the breast allowed for the patient to be her own control with randomization of treatment modalities per side. iNPWT was used on one side while on the other side conventional dressing was used. The rate of wound healing complication as well as quality of the scar (using the Manchester score), were the main pillars of this study.

Results: This study showed that the incidence of dehiscence in iNPWT group was 35%, while it was 45% in the standard dressing. Though we felt there are numerical and clinical superiority in the incidence and even the depth of dehiscence between iNPWT & traditional dressing, there was no statically significance to support this observation. The Manchester scar score showed a significant higher number in the standard care group with a p -value of ($p=0.0114$).

Conclusion: iNPWT offers an alternative preventative measure for “T” junction problems in Wise pattern reduction mammoplasty. Though it was not statistically significant we still believe that it showed superior results. iNPWT showed improvement in the quality of the scar. Further national studies about its cost effectiveness in developing countries are recommended as well as its uses in other fields of plastic surgery.

Key Words: Pico – NPWT – Dehiscence – Scar – Reduction.

This study didn't receive any funding and no conflict of interest to disclose.

This study obtained ethical approval from the Kasr Al-Ainy Ethical Committee.

INTRODUCTION

Breast reduction is a centuries old procedure. It started as early as the 19th century and has been evolving ever since. The initial idea was just the reduction of the morbidity, the weight of the breast is causing, regardless of the outcome. Later in that century, a new concept of “natural breast” evolved and revolutionized the procedure [1].

Nowadays, the philosophy of breast reduction entails diminishing the size of the breast, while maintaining an appropriate size for every patient, proper skin envelope redraping & maintaining the viability and sensation and proper positioning of the nipple areola complex (NAC) [2].

Like any surgical procedure, breast reduction is a safe procedure yet it is not free of risks and complications. Complications can be local or general. The local complications can be subdivided further into early and late complications. The early local complications include: Hematoma, flap or nipple loss, fat necrosis, seromas and wound dehiscence [3].

The Wise pattern, adopted by most plastic surgeons, allows the surgeon to control both breast tissue and skin resection at ease. Yet it ends up with an inverted “T” scar. Wound dehiscence at “T” junction is common with some papers claiming that its incidence varies from 14% to 54% [4].

A lot of factors have been incriminated in “T” dehiscence. The search continues for a definitive etiology to reduce its incidence. The list of those factors includes yet not limited to: Smoking, age, obesity, weight of resection, degree of ptosis, operative time, medications and of course tension.

Even the involvement of the a junior surgeon or resident was incriminated & assessed [5].

The quest for a solution for the “T” junction is still on. Most of these ideas involve decreasing the tension on skin, borrowing properly vascularized tissues from adjacent area & removing glandular tension. Those methods include: Triangular lipodermal flaps [4], Inverted V flap [6], Crossed Dermal Flaps [7] and lastly but not least the use of the new Incisional Negative Pressure Wound Therapy (iNPWT).

Thirty years ago when NPWT (Negative Pressure Wound Therapy) debuted, it was met with a lot of skepticism. Since then NPWT managed to prove itself as a useful gadget in wound care management.

All surgeons are constantly haunted by surgical site infection (SSI), this fear lead to new indications and uses of NPWT. NPWT cannot be used on surgical incisions as it produces skin maceration and might disrupt the skin closure system. A new specialized type of NPWT has been invented specifically for surgical incisions it is called Incisional Negative Pressure Wound Therapy (iNPWT) with a promise that it will provide a preventive solution to surgical site infection [8].

iNPWT mechanism of action is outstandingly different than the well known NPWT mechanism. iNPWT reduces lateral tension & hematoma and seroma, improves lymphatic clearance helping the wound healing process [8]. Wilkes et al., concluded that “iNPWT decreased the lateral stress concen-

trations in the incision by approximately 50% not only around the closed incision but also in the fat layer and also normalized the direction of the stresses to homeostatic levels and to a distribution typical of intact tissue” [9]. Their results were criticized as they receive royalties from the manufacturing company.

iNPWT has been used in almost all branches of surgery. In orthopedics, the prophylactic use of iNPWT in primary hip and knee arthroplasties helped in decreasing both wound complications and hospital stay [10]. While in general surgery iNPWT significantly reduced SSI in both breast and colorectal patients compared with controls [11].

Plastic surgeons are always innovative, that is why iNPWT found new dimensions and uses in their hands. iNPWT was used to relieve congestion in a flap by wrapping it around the finger with the congested flap [12]. It also proved its effectiveness in minimizing donor site morbidity in free radial forearm flap [13]. 'T' junction of breast reduction was then tackled, the use of iNPWT showed improvement in the healing of the “T” junction [14,15].

PICO™ system (Smith & Nephew, Hull, UK) is a tiny NPWT system that works without the need for a canister. It consists of 2 components: A pump that is battery driven (up to 80mmHg) and a special dressing. This dressing eliminates the need for a canister as it is formed of 4 layers that interact together allowing one way transpiration, removal of exudates, airlock and minimizing pain at time of removal of the dressing [16] Fig. (1).

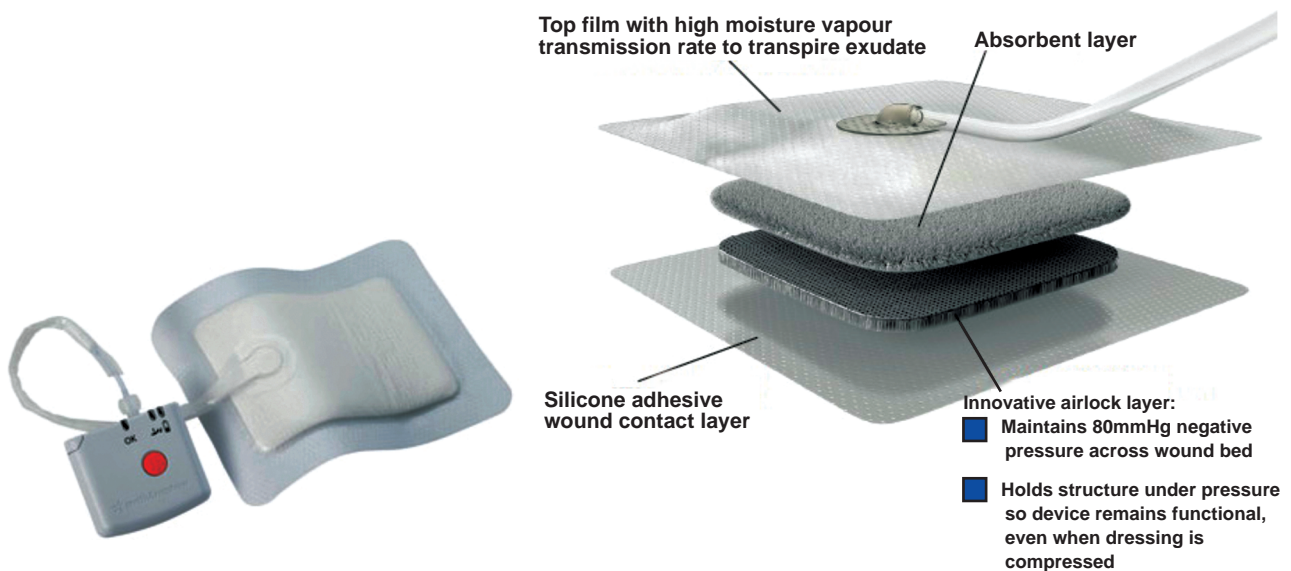


Fig. (1): Pico device showing the battery powered pump and the special 4 layers dressing [16].

PATIENTS AND METHODS

A Randomized prospective self-controlled study was conducted on 20 patients presenting to Kasr Al-Aini outpatient clinic with macromastia seeking breast reduction during the period between December 2017 & May 2018. Patients seeking breast reduction were included while the exclusion criteria were: Patients with active intertrigo, uncontrolled diabetes, corticosteroids treatment and oncoplastic breast reduction. Though a lot of studies suggest an age limit or BMI limit in reduction patients, this study being concerned with complications didn't set those limits. The study started after obtaining approval of Kasr Al-Aini Ethical Committee.

After proper preoperative assessment and recordings, all patients underwent a Wise pattern reduction mammoplasty with a superomedial pedicle. All patients were done under the supervision of the main author. The bilateral nature of the breast allowed for the patient to be her self control unifying almost all variables except the studied one.

After proper closure of the breast, the "T" junction dressing was chosen randomly by lottery method. Right and left breast were written on two separate small papers, putting them in small bowl then mixed together. One of the personnel in the operating room picked one of the papers. The picked side will be dressed immediately postoperative with incisional negative pressure single use free canister (PICO) (Smith and Nephew Healthcare, Hull, United Kingdom) for 7 days, while standard dressing was applied to the other side in each patient. Pico was used as it was the available device at our institute without any conflict of interest. The dressing was applied with the silicon adhesive side towards the wounds (to minimize pain while removing it) and the moisture evaporating layer is outside. The port of the dressing was always away from the most exudation part of the wound.

Opsite strips (Smith and Nephew Healthcare, Hull, United Kingdom) were applied to the edge of the dressing for more adhesion and prevention of leakage, and then the device was switched on. Green light means good air sealing while orange light in the device means that there is air leakage. Elevations in the opsite strips were checked to avoid any air leakage. If any leakage site was found, additional adhesive strips were added. Then the device is switched again by pressing the orange button. The pump was fixed to the patient's abdomen by adhesive tape. Fig. (2).

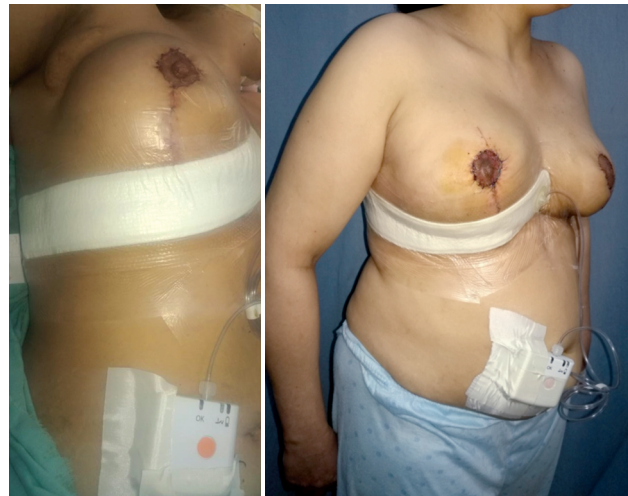

Fig. (2): iNPWT (Pico) application on the T junction.

On the other side standard dressing was applied. This included draping of incisions with povidine iodine and application of adhesive skin closures (steristrips) along the wounds. A sterile dressing (steripad size 10x30 cm) was then applied. Finally a medical brassiere was applied to keep breast in position.

The first postoperative dressing was done on the conventional side on day 3 and repeated every other day as long as there are no signs of infection. The iNPWT side was left intact for 7 days then removed and left the wound exposed.

To standardize the definition, dehiscence was defined as wound separation and gaping regardless how small it is. It includes superficial wound dehiscence and deep wound dehiscence. Surgical site infection (SSI) was defined as presence of any signs of inflammation in the wounds 30 days post-operatively.

The primary outcome of this study was to compare the postoperative complication rates in both sides mainly highlighting incidence of dehiscence rather than any general or local breast reduction complications.

Manchester score¹⁷ was used to compare scarring in both sides after 6 months of the operation. It includes 4 main items (color, contour, distortion and texture) each item (4 points). The lower of total score the better the scar quality.

Pain was also assessed during the period of application using numerical rating scale (NRS) 18. The score was from 0 (indicating zero or no pain) to 10 (worst pain ever). For interpretation and to remove any subjective factor, those scores were further grouped into 4 categories: No Pain (0),

Mild pain (1-3), Moderate pain (4-7) and severe pain (8 -10).

Each patient filled a survey (specifically designed for this study) about iNPWT dressing. The questionnaire as shown in Fig. (3) included the

following, did application of device caused pain or not? Did it cause itching or not? Did the device affect your sleep or not? Did you feel any abnormal vibrations or not? Did the device affect your normal life style in the house or in the work? Are you satisfied with the device or not?


		[Healthcare facility name] Kasr Al Ainy St. Cairo, Egypt Post Code: 11562 Tel./Fax: (202) 23682030
How Are We Doing?		
Please take a few minutes to fill out this survey on the timeliness and quality of the service you received today. [Healthcare facility name] welcomes your feedback and your answers will be kept confidential. Thank you for your participation.		
Personal Information		
Name	Age	BMI
Left Breast Median	Right Breast Median	
General Patient Information		
	١- هل كانت هناك شعور بالوجع من إستخدام الجهاز؟	
<input type="checkbox"/> لا	<input type="checkbox"/> نعم	
	٢- هل كان هناك شعور بالهرش من إستخدام الجهاز؟	
<input type="checkbox"/> لا	<input type="checkbox"/> نعم	
	٣- هل كان الأحساس بالألم أقل من الناحية الأخرى؟	
<input type="checkbox"/> لا	<input type="checkbox"/> نعم	
	٤- هل تسبب لك الجهاز قلق أو أثر عليكى أثناء النوم؟	
<input type="checkbox"/> لا	<input type="checkbox"/> نعم	
	٥- هل شعرتى بأى إهتزازات شديدة أثرت عليكى؟	
<input type="checkbox"/> لا	<input type="checkbox"/> نعم	
	٦- هل أثر الجهاز على حياتك اليومية فى المنزل أو فى العمل؟	
<input type="checkbox"/> لا	<input type="checkbox"/> نعم	
	٧- هل أنت راضية عن استخدام الجهاز؟	
<input type="checkbox"/> لا	<input type="checkbox"/> نعم	
Additional Feedback		
Thank you for taking the time to fill out our survey. We rely on your feedback to help us improve our services. Your input is greatly appreciated.		

Fig. (3): The post-operative survey about iNPWT.

RESULTS

Twenty patients completed this study with a total of 40 breasts. Twenty breasts treated with iNPWT and 20 breasts treated with traditional dressing. The age of the included patients showed a minimum of the 21 years & a maximum of 44 years (mean 30.94 ± 6.4). Body mass index showed a minimum of 25 & a maximum of 41 (mean 32.28 ± 4.06). Suprasternal notch (SSN) to NAC (nipple areola complex) distance on both sides were also analyzed. Right SSN NAC minimum distance 28cm and maximum distance 41cm (mean $33.57 \text{cm} \pm 4.1$), while the reciprocal number of Left SSN were 26cm & 44cm (mean 33.78 ± 4.3).

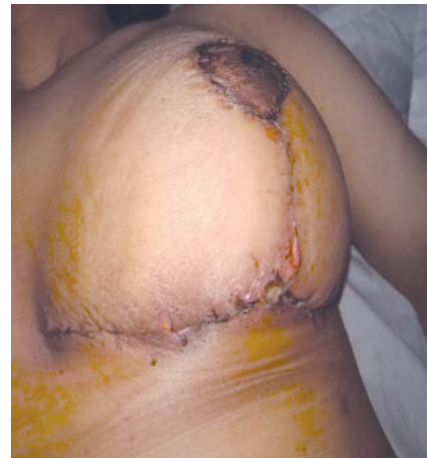
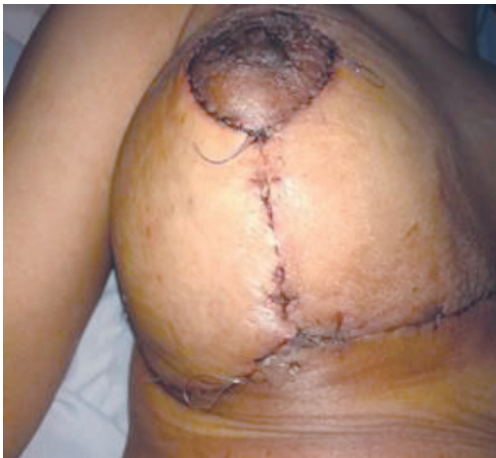
Fig. (4): Pictures on the 14 days post-operative of the same patient. Left side using iNPWT with no wound dehiscence while the right side shows superficial wound dehiscence on traditional dressing.

Statistical analysis of any correlation between: Age or BMI and wound dehiscence was not statistically significant. Though we felt there are numerical and clinical superiority in the incidence and even the depth of dehiscence between iNPWT & traditional dressing, there was no statically significance to support this observation.

Manchester scar score in iNPWT was 9.26 ± 1.7 (Minimum 5 & max 13), on the other hand the mean value of scar score in standard group was 10.10 ± 1.41 with (Minimum 7 & max 13).

Comparison between scar score at standard care group and scar at iNPWT group was significant, the scar score was higher in the standard side than the iNPWT side ($p=0.0114$).

The idea of iNPWT being a solution for post-operative seromas was studied. Yet the incidence of seroma in both groups showed no statistical significant ($p=0.333$). Only 1 patient developed seroma, measuring 1x2cm by ultrasound, that didn't need an intervention.

The study focused on wound complications rather than the whole spectrum of complications of breast reduction. The results of this study showed that the incidence of dehiscence in iNPWT group was 35%. Dehiscence in this group occurred in 6 patients (30%) with superficial dehiscence in 5 patients and deep dehiscence in 1 patient (5%).

The incidence of dehiscence in standard group was 45%, divided into 7 patients (35%) with superficial dehiscence and 2 patients (10%) with deep dehiscence. Following wound dehiscence some form of surgical site infection always occurred. (SSI being just any kind of inflammation) (30% in iNPWT group & 45% in standard group).

The mean of pain score in iNPWT group was 5.31 ± 1.15 with minimum score 3 and maximum score 7, while in standard group the mean value is 5.36 ± 1.3 with minimum score is 3 and maximum score 7. Comparison between both groups showed no statistically significant ($p=0.91$). Overall satisfaction (75%) was also interpreted yet we don't see it of any value as the main concern of the patient was directed to satisfaction from the breast reduction procedure not the variables this study is trying to assess.

There were also complications related iNPWT. Six patients had leakage problems and required re-application of extra adhesive tape or removal of the dressing once the leakage was discovered and applied another one. The specific nature of the included dressing lead to more air leaks in early cases till we got the 'know how' of it. Two patients developed adhesive tape reactions with skin blistering which resolved spontaneously after removal of iNPWT.

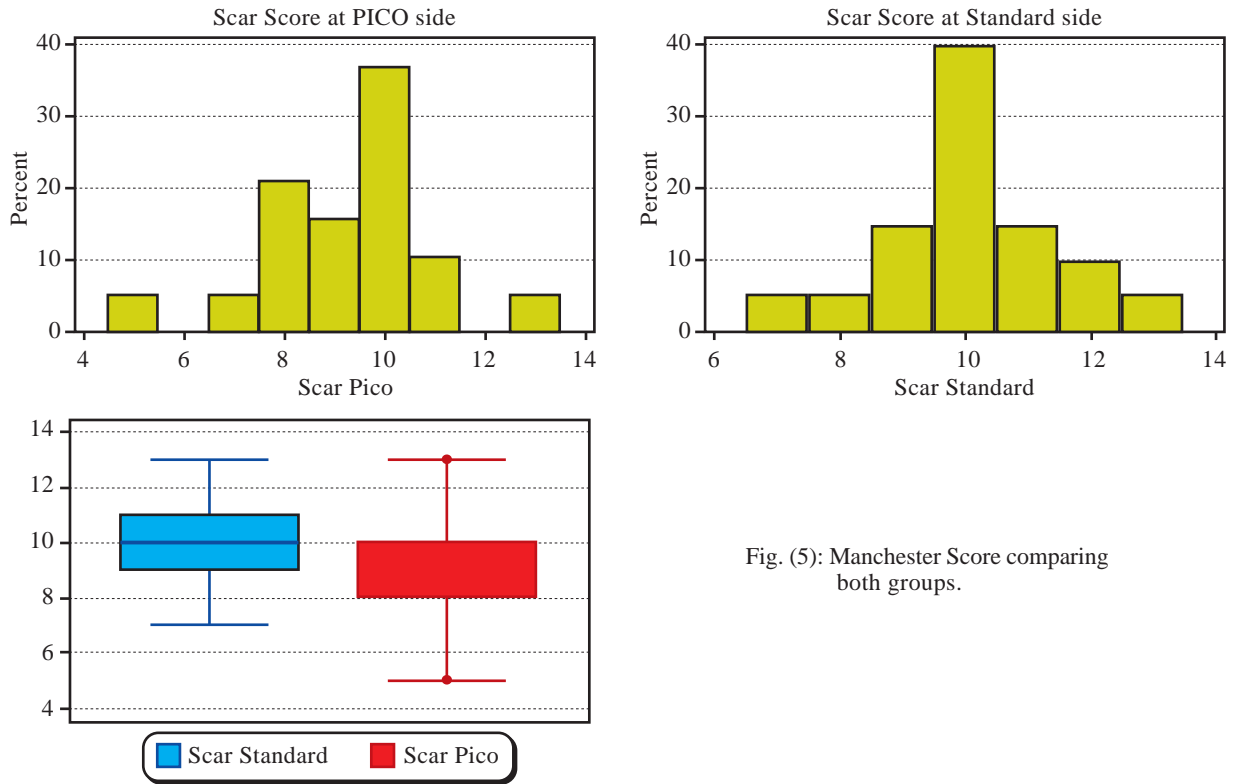


Fig. (5): Manchester Score comparing both groups.

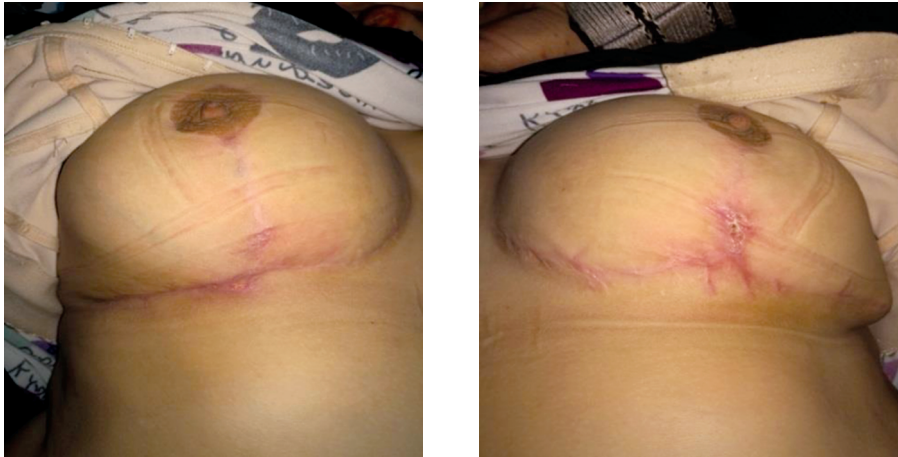


Fig. (6): 3 months post-operative results comparing the scars. Notice the difference between the iNPWT on the left side versus conventional dressing on right side.

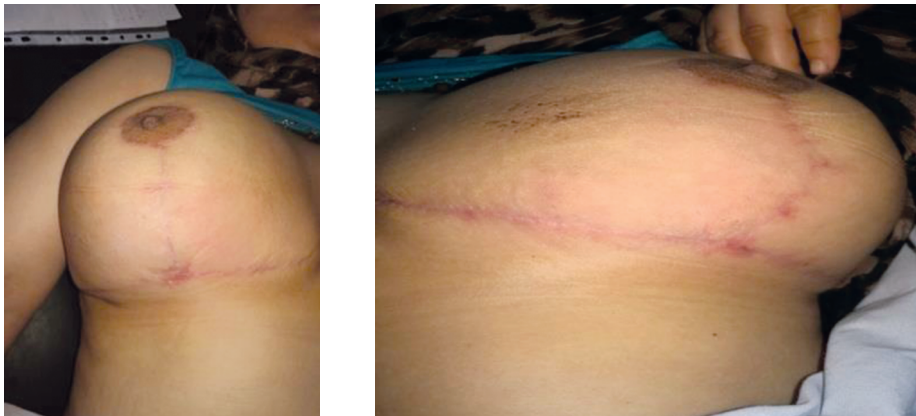


Fig. (7): 6 months post-operative results comparing the scars. Notice the secondary outcome improving the vertical scar between the iNPWT on the left side versus conventional dressing on right side.

DISCUSSION

The debates in breast reduction are almost endless. Which pedicle is better? Which pedicle is safer? Which pedicle preserves the nipple sensation more? With each group advocates claiming the superiority of their technique. Will you ever be able to convince one from the inferior pedicle group that the superior pedicle has its merits? We think never. But if you start and search for something they will all agree on, it is that: Wise pattern comes with a high cost of "T" junction healing problems. The hunt for an ideal method to prevent "T" junction dehiscence is still on.

Mammary hypertrophy comes with a very high burden on the patient both physically and mentally. The physical burden includes back and neck pain, shoulder pain and bra grooving. In a period where physical activities are becoming the norm, huge breasts can lead to shyness and reduction of physical activity & exercise. The best way to eradicate this entire burden is a breast reduction procedure [19].

Breast reduction entails a combination of decisions that are independent from one another. The most important question is which pedicle and which skin resection pattern. Wise pattern resection is preferred by many surgeons as it allows for better control of both the skin resection as well as parenchymal control. Yet the wise pattern ends with an inverted "T" shaped scar [20].

Though, breast reduction is associated with one of the highest level of satisfaction in plastic surgery, it comes with a hidden cost of high rates of complications more than any breast procedure. Those complications include wound gapping, infections and seroma. The "T" junction has been incriminated for increasing the rate of complications for up to 54% [4].

NPWT has revolutionized the wound care service since its invention gaining new indications every day. The last addition to armamentarium of wound management is the iNPWT. It differs from its predecessors that it is used on closed surgical wounds especially in problematic area to decrease the complications rate. iNPWT showed superiority in reduction of surgical site infection and wound gapping than other dressing techniques [21].

Hoping to decrease the complications rates, this study suggested the use of the technological advances of iNPWT. Twenty female patients underwent superomedial reduction mammoplasty with wise pattern resection. The patient herself

served as a control with randomization of which breast to receive a treatment with iNPWT and which to receive the traditional dressing technique. The idea behind it is that iNPWT will alleviate the tension and increase vascularity.

Although this study showed less incidence of dehiscence in iNPWT group compared with standard group (35%, 45%) respectively, however it didn't reach statistically significance ($p=0.83$). It is believed by observation and numbers that the iNPWT might be superior. These incidences are within the same range of dehiscence of previous studies in which rate of dehiscence ranged from 8.6% to 36.4% in the iNPWT groups versus 16.5% to 39% in the standard care groups [22].

On the other hand, this current study showed higher incidence of dehiscence in both groups compared with previous study done by Galiano et al., [14] which showed statistically significant decrease in dehiscence with total incidence 16.2% in iNPWT and 26.4% in standard group". Healing complications (for the primary endpoint) were defined as delayed healing (incision not 100% closed by 7 days) and occurrence of dehiscence or infection within 21 days" [14]. This definition leads to wound healing complications at 21 days as high as 56.8% in iNPWT & 61.8% in the steristrips group.

The explanation of the discrepancy in numbers is multi-factorial: Sample size, residents' involvement and most important the definition used for dehiscence.

As for the sample size, this study didn't receive any funding or royalties. It was conducted at a public governmental hospital with the resources available. Being a teaching hospital, this necessitated the involvement of the residents in wound closure that some papers attribute this as a reason for wound healing problems. Last but not least the definition set for wound dehiscence was too broad encompassing even the mildest acceptable form of wound gapping.

It is believed that one of the mechanisms iNPWT can help in reducing wound healing problem is by its support of the lower pole of the breast. This support will help through various mechanisms in decreasing edema and healing. We couldn't come up with a way to study this effect but it merits further studies.

One of the immense advantages of iNPWT is that it comes in a compact form. The pump system is a tiny, pocket size, device almost smaller than

most smart phones (less than 70gms in weight). The system works without pump and without the noise the classical NPWT produce. This offers a higher level of acceptance by the patients. Most patients like new gadgets and new technologies, hence almost all patients showed higher satisfaction on the side where iNPWT was used.

Impact of age on breast reduction patients particularly as a candidate for surgery has been increasingly focused in literature. In this study, patients with mean age 36.5 were associated with more major dehiscence events ($p=0.048$), this was in harmony with a study done by Roehl et al., who concluded that age group from 30 to 39 were common associated with more complications in reduction mammoplasty [23].

The relation between BMI and complications of breast reduction is not yet well understood. Several studies suggest that the higher the BMI the higher the incidence of complications [5]. The current study showed similar results with numerical trend in iNPWT groups where the patients with no dehiscence had lower BMI (mean=30.7) and those with major dehiscence had higher BMI (mean=33.5), however it didn't reach statistical significance ($p=0.52$).

Whether we like it or not, the medical practice in the world is being driven by financial factors. One of the financial loads that can be prevented is surgical site infections (SSIs). iNPWT can help decrease SSIs through various mechanisms either obliteration of the dead space, removing blood & fluids thus decreasing the formation of hematoma & seroma, or enhancing blood flow. The use of iNPWT (Pico) decreased the incidence of SSI up to 30 days when used in clean and contaminated abdominal surgeries [24].

In the current study although the incidence of SSI in iNPWT group was less than the incidence in standard group (30%, 45%) respectively, however it didn't reach significance ($p=0.161$). Which were the same results as concluded by Green et al of no statistically significance is SSI compared between standard dressing and iNPWT in abdominal wall reconstruction operations [25].

When this study started in 2017, the idea of the use of iNPWT to improve the quality of long term scar was a novelty. The study assessed scars hoping to reach a breakthrough new use of iNPWT in improving scars. Unfortunately due to many limitations multiple studies have been published. Tanaydin et al., in 2018, [15] compared the effect of iNPWT versus fixation strips on the quality of the

scar. They depended on the visual analogue scale (VAS) and Patient and Observer Scar Assessment Scale (POSAS). Both these scales showed significant improvement in the iNPWT group on 42 and 90 days.

The Manchester scar assessment scale was used in this study. Both iNPWT and steristrips were compared to each other. Though it is a different scale it showed similar results to the work done by Tanaydin et al., [15] with a significant p -value of =0.0114. It was also noticed an improvement of the area of the vertical limb that was covered by the iNPWT. This was not studied but was a well noted observation.

Post-operative pain is a novel factor to be assessed. Using numerical rating score (NRS) for evaluating post-operative pain up to 7 days post-operative in standard and INPWT groups. Although 9 patients in INPWT group had less pain score but this values don't reach the statistical significant ($p=0.91$).

The question that came to our mind during working on this study is the cost effectiveness of the iNPWT. Yes iNPWT is an expensive gadget. Yet if all factors are put into consideration it might be cost effective. Those factors include the frequency of the dressings, hospital stay, the materials used, the wound dehiscence, even the need for scar management later on. We believe, though we didn't calculate it due to technical limitation, that if all costs are put into consideration, iNPWT will still be more expensive but might be financially comparable.

Conclusion:

iNPWT offers an alternative preventative measure for "T" junction problems in Wise pattern reduction mammoplasty. Though it was not statistically significant we still believe that it showed superior results over the conventional dressings. The Trade off of plastic surgery is the scar. iNPWT showed improvement in the quality of the scar over traditional methods. We recommend further national studies about its cost effectiveness in developing countries as well its uses in different fields of plastic surgery.

REFERENCES

- 1- Purohit S.: Reduction mammoplasty. Indian J. Plast. Surg., Oct. 41 (Suppl): S64-79. PMID: 20174545; PMCID: PMC2825129, 2008.
- 2- Renó W.T.: Reduction mammoplasty with a circular folded pedicle technique. Plast. Reconstr. Surg., Jul. 90 (1): 65-74; discussion 75-6. PMID: 1615094, 1992.

- 3- Saleem L. and John J.R.: Unfavourable results following reduction mammoplasty. *Indian J. Plast. Surg.*, May 46 (2): 401-7. doi: 10.4103/0970-0358.118620. PMID: 24501476; PMCID: PMC3901921, 2013.
- 4- Khalil H.H., Malahias M. and Shetty G.: Triangular lipodermal flaps in Wise pattern reduction mammoplasty (superomedial pedicle): A novel technique to reduce T-junction necrosis. *Plast. Surg. (Oakv)*. Fall, 24 (3): 191-194. doi: 10.4172/plastic-surgery.1000975. Epub 2016 Aug 19. PMID: 28439509; PMCID: PMC5395051, 2016.
- 5- Fischer J.P., Cleveland E.C., Shang E.K., Nelson J.A. and Serletti J.M.: Complications following reduction mammoplasty: a review of 3538 cases from the 2005-2010 NSQIP data sets. *Aesthet. Surg. J.*, Jan. 1; 34 (1): 66-73. doi: 10.1177/1090820X13515676. Epub 2013 Dec 13. PMID: 24334499, 2014.
- 6- Chao J.W., Taylor E.M. and Rohde C.H.: Reducing wound healing complications of Wise pattern breast reduction with the inverted "V" modification. *J. Plast. Reconstr. Aesthet. Surg.*, Mar. 67 (3): 421-2. doi: 10.1016/j.bjps.2013.09.032. Epub 2013 Oct 3. PMID: 24120419, 2014.
- 7- De la Plaza R., de la Cruz L., Moreno C. and Soto L.: The crossed dermal flaps technique for breast reduction. *Aesthetic Plast Surg.*, Nov-Dec. 28 (6): 383-92. doi: 10.1007/s00266-004-0370-4. Epub 2005 Jan 6. PMID: 15633020, 2004.
- 8- Strugala V. and Martin R.: Meta-Analysis of Comparative Trials Evaluating a Prophylactic Single-Use Negative Pressure Wound Therapy System for the Prevention of Surgical Site Complications. *Surg. Infect (Larchmt)*, Oct. 18 (7): 810-819. doi: 10.1089/sur.2017.156. Epub 2017 Sep 8. PMID: 28885895; PMCID: PMC5649123, 2017.
- 9- Wilkes R.P., Kilpad D.V., Zhao Y., Kazala R. and McNulty A.: Closed incision management with negative pressure wound therapy (CIM): biomechanics. *Surg. Innov.*, Mar. 19 (1): 67-75. doi: 10.1177/1553350611414920. Epub 2011 Aug 25. PMID: 21868417, 2012.
- 10- Karlakki S.L., Hamad A.K., Whittall C., Graham N.M., Banerjee R.D. and Kuiper J.H.: Incisional negative pressure wound therapy dressings (iNPWTd) in routine primary hip and knee arthroplasties: A randomised controlled trial. *Bone Joint Res.*, Aug. 5 (8): 328-37. doi: 10.1302/2046-3758.58.BJR-2016-0022.R1. PMID: 27496913; PMCID: PMC5013893, 2016.
- 11- Pellino G., Sciaudone G., Candilio G., De Fatico G.S., Landino I., Della Corte A., Guerniero R., Benevento R., Santoriello A., Campitiello F., Selvaggi F. and Canonico S.: Preventive NPWT over closed incisions in general surgery: Does age matter? *Int. J. Surg.*, 12 (Suppl 2): S64-S68. doi: 10.1016/j.ijsu.2014.08.378. Epub 2014 Aug 23. PMID: 25159226, 2014.
- 12- Niimi Y., Mori S. and Takeuchi M.: A New Procedure for Wrapped-Negative Pressure Wound Therapy for Congestion After Arterialized Venous Flap Surgery. *Clin. Med. Insights Case Rep.*, Dec. 13 (10): 1179547617747279. doi: 10.1177/1179547617747279. PMID: 29270041; PMCID: PMC5731612, 2017.
- 13- Ray E., Mitchell S.L. and Cordeiro P.G.: Miniature Negative Pressure Dressings on Forearm Donor Sites after Radial Forearm Flap Harvest. *Plast. Reconstr. Surg. Glob Open*, Jun. 15; 6 (6): e1838. doi: 10.1097/GOX.00000000001838. PMID: 30276061; PMCID: PMC6157936, 2018.
- 14- Galiano R.D., Hudson D., Shin J., van der Hulst R., Tanaydin V., Djohan R., Duteille F., Cockwill J., Megginson S. and Huddleston E.: Incisional Negative Pressure Wound Therapy for Prevention of Wound Healing Complications Following Reduction Mammoplasty. *Plast Reconstr Surg Glob Open*, Jan. 12; 6 (1): e1560, 2018. doi: 10.1097/GOX.0000000000001560. Erratum in: *Plast Reconstr Surg Glob Open*, Mar. 23; 6 (2): e1720. PMID: 29464150; PMCID: PMC5811280, 2018.
- 15- Tanaydin V., Beugels J., Andriessen A., Sawor J.H. and van der Hulst R.R.W.J.: Randomized Controlled Study Comparing Disposable Negative-Pressure Wound Therapy with Standard Care in Bilateral Breast Reduction Mammoplasty Evaluating Surgical Site Complications and Scar Quality. *Aesthetic Plast. Surg.*, Aug. 42 (4): 927-935, 2018. doi: 10.1007/s00266-018-1095-0. Epub 2018 Feb. 13. Erratum in: *Aesthetic Plast Surg. Apr. 2*. PMID: 29442143; PMCID: PMC6097780, 2018.
- 16- Holt R. and Murphy J.: PICO™ incision closure in oncologic breast surgery: A case series. *Br. J. Hosp. Med. (Lond)*, Apr. 76 (4): 217-23. doi: 10.12968/hmed.2015.76.4.217. PMID: 25853353, 2015.
- 17- Beausang E., Floyd H., Dunn K.W., Orton C.I. and Ferguson M.W.: A new quantitative scale for clinical scar assessment. *Plast. Reconstr. Surg.*, Nov. 102 (6): 1954-61. doi: 10.1097/00006534-199811000-00022. PMID: 9810991, 1998.
- 18- Karcioğlu O., Topacoglu H., Dikme O. and Dikme O.: A systematic review of the pain scales in adults: Which to use? *Am. J. Emerg. Med.*, Apr. 36(4):707-714. doi: 10.1016/j.ajem.2018.01.008. Epub 2018 Jan 6. PMID: 29321111, 2018.
- 19- Manahan M.A., Burette K.J., Chang D., Mithani S.K., Mallalieu J. and Shermak M.A.: An outcomes analysis of 2142 breast reduction procedures. *Ann. Plast. Surg.*, Mar. 74 (3): 289-92. doi: 10.1097/SAP.0b013e31829d2261. PMID: 25668497, 2015.
- 20- Kemaloglu C.A. and Özocak H.: Comparative Outcomes of Inferior Pedicle and Superomedial Pedicle Technique with Wise Pattern Reduction in Gigantomastic Patients. *Ann. Plast. Surg. Mar.* 80 (3): 217-222. doi: 10.1097/SAP.0000000000001231. PMID: 28984653, 2018.
- 21- Hudson D.A., Adams K.G., Van Huyssteen A., Martin R. and Huddleston E.M.: Simplified negative pressure wound therapy: Clinical evaluation of an ultraportable, no-canister system. *Int. Wound J.*, Apr. 12 (2): 195-201. doi: 10.1111/iwj.12080. Epub 2013 May 7. PMID: 23647737; PMCID: PMC7950749, 2015.
- 22- Scalise A., Calamita R., Tartaglione C., Pierangeli M., Bolletta E., Gioacchini M., Gesuita R. and Di Benedetto G.: Improving wound healing and preventing surgical site complications of closed surgical incisions: a possible role of Incisional Negative Pressure Wound Therapy. A systematic review of the literature. *Int. Wound J.*, Dec. 13 (6): 1260-1281. doi: 10.1111/iwj.12492. Epub 2015 Oct 1. PMID: 26424609; PMCID: PMC7950088, 2016.
- 23- Roehl K., Craig E.S., Gómez V. and Phillips L.G.: Breast reduction: Safe in the morbidly obese? *Plast. Reconstr. Surg.*, Aug. 122 (2): 370-378. doi: 10.1097/PRS.0b013e31817d60f4. PMID: 18626352, 2008.

24. O'Leary D.P., Peirce C., Anglim B., Burton M., Concannon E., Carter M., Hickey K. and Coffey J.C.: Prophylactic Negative Pressure Dressing Use in Closed Laparotomy Wounds Following Abdominal Operations: A Randomized, Controlled, Open-label Trial: The P.I.C.O. Trial. *Ann. Surg.*, Jun. 265 (6): 1082-1086. doi: 10.1097/SLA.0000000000002098. PMID: 27926575, 2017.
- 25- Condé-Green A., Chung T.L., Holton L.H. 3rd, Hui-Chou H.G., Zhu Y., Wang H., Zahiri H. and Singh D.P.: Incisional negative-pressure wound therapy versus conventional dressings following abdominal wall reconstruction: A comparative study. *Ann. Plast. Surg.*, Oct. 71 (4): 394-7. doi: 10.1097/SAP.0b013e31824c9073. PMID: 22868327, 2013.