

## Anatomical Characteristics And Variant Of Prostatic Artery By Digital Subtraction Angiography Relevant To Prostatic Artery Embolization

Ahmed Makram Mahmoud<sup>1,2\*</sup>M.B.B.Ch; Amr Mahmoud Zayed<sup>1</sup>MD; Hussein Montaser Roshdy<sup>2</sup>MD

### \*Corresponding Author:

Ahmed Makram Mahmoud  
[ahmedmakram93@gmail.com](mailto:ahmedmakram93@gmail.com)

Received for publication October 29, 2021; Accepted February 20, 2022; Published online February 20, 2022.

**Copyright** The Authors published by Al-Azhar University, Faculty of Medicine, Cairo, Egypt. Users have the right to read, download, copy, distribute, print, search, or link to the full texts of articles under the following conditions: Creative Commons Attribution-Share Alike 4.0 International Public License (CC BY-SA 4.0).

doi: 10.21608/aimj.2022.101974.1620

<sup>1</sup>Radio Diagnosis Department, Faculty of Medicine, Al-Azhar University, Cairo, Egypt.

### ABSTRACT

**Background:** Embolization of the prostatic artery in patients with benign prostatic hyperplasia (BPH) is a new treatment, understanding the architecture of the artery supplying the prostatic is crucial to success.

**Aim of The Work:** Is using digital subtraction angiography (DSA) to define the anatomical features and variations of the PA.

**Patients and Methods:** This research were performed on thirty patients presented to the Interventional Radiology Unit, Sayed Galal university hospital using, DSA, Dyna-CT and 3D reconstruction.

**Results:** The thirty patients age ranged from 53 to 75 years with mean  $\pm$  SD equaled  $63.17 \pm 5.78$ , the prostatic volume of patients ranged from 40 to 80 ml, and its mean  $\pm$  SD was  $55.00 \pm 11.14$ , International Prostate Symptom Score (IPSS) mean  $\pm$  SD was  $21.83 \pm 6.16$ , where the minimum was 10 and the maximum was 32. Right PA classification was distributed as follows, 7(23.3%) were type I, 6(20%) type II, 5(16.7%) type III, 9(30%) type IV, and 3(10%) type V. Left PA classification was distributed as follows, 7(23.3%) were type I, 6(20%) type II, 5(16.7%) type III, 9(30%) type IV, and 3(10%) type V. Some anastomoses of the PA with the surroundings are noted, including the bladder in one patient (3.3%), Contralateral Prostatic artery in 4(13.3%), rectum in 2(6.7%), penis in 2(6.7%) and seminal vesicles in 3(10%).

**Conclusion:** Four main patterns matched with about 95 percent of the anatomical variants of the PA, using a systematic categorization, will change the PAE process into a quicker, cleaner, and more successful technique.

**Keywords:** Variant of prostatic artery; embolization of the artery supplying the prostatic; digital subtraction angiography.

**Disclosure:** The authors have no financial interest to declare in relation to the content of this article. The Article Processing Charge was paid for by the authors.

**Authorship:** All authors have a substantial contribution to the article.

### INTRODUCTION

Symptoms of the lower urinary tract resulting from BPH are recently being treated using PAE by a rising prevalence of interventional radiologists across the world.

After it was first introduced in<sup>1</sup>, several research stated that the PAE technique is safe and successful in patients who are resistant to the medication, as well as those who have limitations to or refuse surgical intervention, with considerable decreases in symptoms of lower urinary tract in the absence of incontinence or sexual problems.<sup>2</sup>

BPH is widespread and responsible for LUTS. PAE is a new technique for BPH. It has been shown to have a therapeutic benefit and being safe in treating LUTS as well as decreasing prostatic volume.<sup>3</sup>

The key to the success in the process of prostatic artery embolization is to recognize the PA anatomy, however the PA varies greatly in number and location of origin. Several studies agree that the origin of PA is quite different and unpredictable in male postmortem examinations.<sup>2</sup>

Because the PA has a complicated anastomosis with the adjacent structures like penis, rectum, seminal vesicle, and bladder, the danger of embolizing of

these tissues through the embolization is considerable.<sup>4</sup>

Identifying and navigating the PA origin, anatomical variant and anastomosis with the surroundings is the most difficult aspects of PAE. There is no common pathological profile linked with BPH. PA origin associated with PAE varies widely from person to person and bilaterally in the same individual, nonetheless four groups are found repeatedly.<sup>2</sup>

The PAE procedure is not an easy process, due to multiple anatomical origins that take much time, as a result, both patients and medical staff are exposed to significant dose of radiation.<sup>5</sup>

Some studies reported cases of two or even three PAs within the same side of the male pelvis.<sup>6</sup>

Similar findings were found in recent research on the PA origin by DSA.<sup>2</sup>

In many patients, one PA was detected on each pelvic side, dual vascularization was uncommon.<sup>7</sup>

Internal iliac artery (IIA) anterior division branches, such as the internal pudendal artery, the common origin with the superior vesical artery (SVA), and the obturator artery, are most prevalent sources of the

artery supplying the prostate. While middle rectal artery, the accessory obturator artery, the gluteal artery, and the accessory pudendal artery all have a small fraction of PA.<sup>4</sup>

Many studies classify the prostatic artery origin into 5 different groups.<sup>2</sup>

### PATIENTS AND METHODS

Our research was done on thirty patients admitted to the “Interventional Radiology Unit” of the Radiology Department, Sayed Galal university hospital for establishment of Trans arterial chemoembolization (TACE) and before the end of the session the catheter directed to internal iliac artery (IIA) bilaterally and serial images were taken for the prostatic artery (PA).

Male patients over 50 years old with symptoms of low urinary tract due to gland hyperplasia and a prostate volume greater than 30 cc were included in the study.

Bladder diverticula, stone in the bladder, renal insufficiency, and suspicion of prostate cancer are all excluded from study.

Relative contraindications are Patients with bleeding tendency, hypertension, or disturbed conscious level, also patients with respiratory distress preventing them from lying supine as well as patients not fit for procedure or with infection at insertion site.

Pre-procedure assessment & preparation was done.

Clinical history was taken, physical examination including an assessment of vital signs. Explanation of the complications to the patient was done. A written consent was taken from all patients

for contrast media admission and catheter insertion. Patients were required to fast for four to six hours before the intervention, except the medications. One peripheral intravenous line was placed for I.V. medication.

Laboratory results in the form of blood work was done and revised (CBC, liver function tests, kidney function tests, PT, PTT, and INR).

All previous radiological investigations including pelvi-abdominal ultra-sound, CT and MRI studies of the patients were reviewed.

Technique we used was siemens artis zee flat panel detector (40 x 30 cm) device with capability of DYNA CT and 3D reconstruction, local anesthetic was used throughout the procedure, then by puncturing the femoral artery unilaterally, angiogram of the internal iliac artery on both sides were done with ipsilateral and contralateral oblique projection of 35 to 45 degrees, also caudal and cranial angulations of 10 degrees were helpful. Angiographic findings from 30 patients were reviewed.

Post-procedural care & follow up was done. The patient was kept at bed rest in a flat position for 1-2 hours. Post-procedural medical management was prescribed according to the condition of the patient. Clinical follow up was done following the procedure, to detect any clinical complication related to the catheter placement.

### RESULTS

Our research was completed on thirty patients admitted to the “Interventional Radiology Unit” of the Radiology Department, Sayed Jalal university hospital for establishment of Trans arterial chemoembolization (TACE) and before the end of the session, the catheter directed to internal iliac artery (IIA) bilaterally and serial images were taken for the prostatic artery (PA).

The thirty patients suffered from Lower urinary tract symptoms, and all of them had previous treatment.

	Mean	Std. Deviation	Minimum	Maximum
Age	63.17	5.784	53	75
Prostatic volume (By U/S)	55.00	11.142	40	80
International Prostate Symptom Score (IPSS)	21.83	6.159	10	32

Table (1): The age, prostatic volume, and International Prostate Symptom Score indices of the patients.

The thirty patients age ranged from 53 to 75 years with mean  $\pm$  SD equaled  $63.17 \pm 5.78$ , the prostatic volume of patients ranged from 40 to 80 ml, and its mean  $\pm$  SD was  $55.00 \pm 11.14$ , International Prostate Symptom Score (IPSS) mean  $\pm$  SD was  $21.83 \pm 6.16$ , where the minimum was 10 and the maximum was 32.

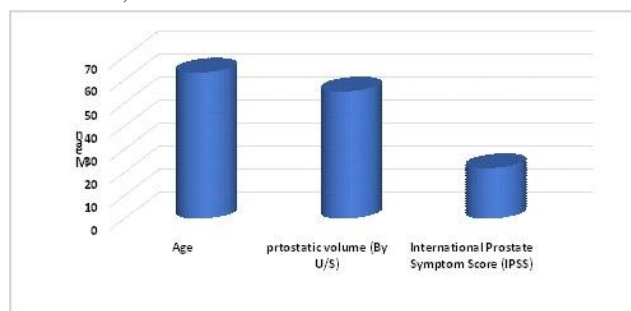


Fig. 1: The age, prostatic volume, and International Prostate Symptom Score indices of the patients.

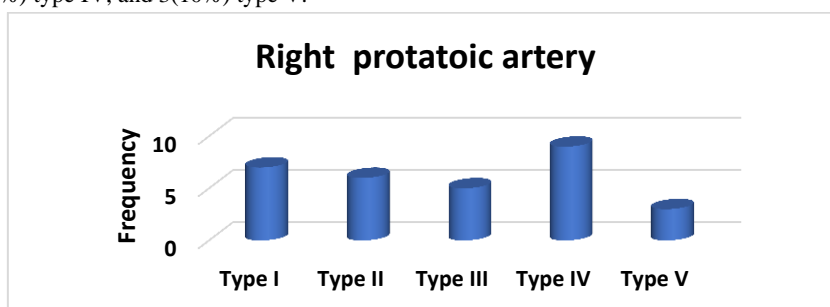
Type	1	2	3	4	5
Origin of PA	Common trunk with SVA	The anterior division of IIA, inferior to SVA	Obturator artery	Internal pudendal artery	Less common origins

**Table 2:** Classification of PA by.8

Right prostatic artery	Frequency	Percent
Type I	7	23.3
Type II	6	20.0
Type III	5	16.7
Type IV	9	30.0
Type V	3	10.0
<b>Total</b>	<b>30</b>	<b>100.0</b>

**Table 3:** The distribution Right prostatic artery anatomical classification of the patients.

Right prostatic artery classification was distributed as follows, 7(23.3%) were type I, 6(20%) type II, 5(16.7%) type III, 9(30%) type IV, and 3(10%) type V.

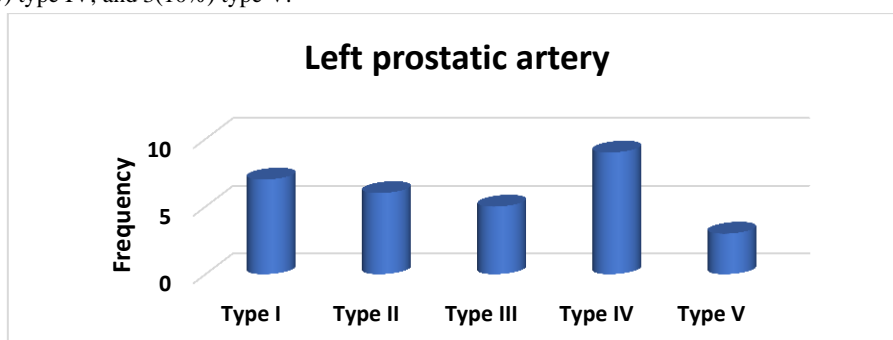


**Fig. 2:** The distribution Right prostatic artery anatomical classification of the patients

Left prostatic artery	Frequency	Percent
Type I	7	23.3
Type II	6	20.0
Type III	5	16.7
Type IV	9	30.0
Type V	3	10.0
<b>Total</b>	<b>30</b>	<b>100.0</b>

**Table 4:** The distribution left prostatic artery anatomical classification of the patients.

Left prostatic artery classification was distributed as follows, 7(23.3%) were type I, 6(20%) type II, 5(16.7%) type III, 9(30%) type IV, and 3(10%) type V.

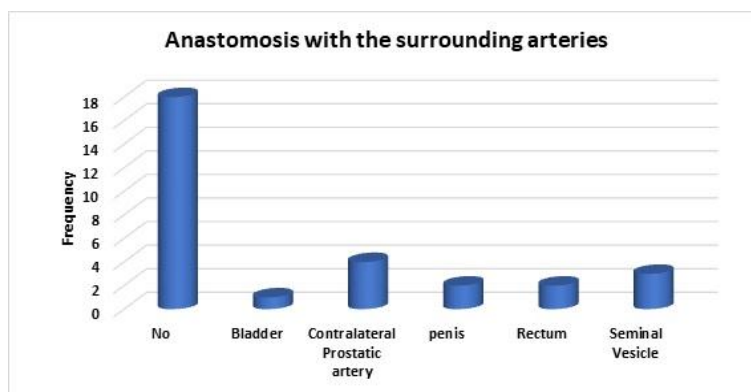


**Fig. 3:** The distribution left prostatic artery anatomical classification of the patients

Anastomosis of prostatic arteries with the surrounding structures	Frequency	Percent
No	18	60.0
Bladder	1	3.3
Contralateral Prostatic artery	4	13.3
penis	2	6.7
Rectum	2	6.7
Seminal vesicles	3	10
<b>Total</b>	<b>30</b>	<b>100.0</b>

**Table 5:** The distribution of anastomosis of prostatic arteries with the surrounding structures of the patients.

Anastomoses of the PA with structures of clinical interest including the bladder in one patient(3.3%), Contralateral Prostatic artery in 4(13.3%), rectum in 2(6.7%), penis in 2(6.7%), seminal vesicles in 3(10%).



**Fig. 4:** The distribution of anastomosis of prostatic arteries with the surrounding structures of the patients

### DISCUSSION

PAE nowadays is considered magical solution for symptoms of lower urinary tract resulting from gland hyperlasia.<sup>1</sup>

The success of PAE, and avoidance of nontarget embolization, is closely attached to that the anatomical pattern of the prostate arteries being correctly identified.<sup>6</sup>

The PAE procedure is not an easy process, mostly due to different anatomical origins that resulting in increasing the procedure time and both patients and medical staff are exposed to significant amounts of radiation.<sup>5</sup>

Identification and catheterization of the IVA and the PA arising from it is very hard and take a long time.<sup>5</sup>

PAE is a new fewer intrusions way for BPH that relieves LUTS and reduces prostate volume (PV) without causing sexual problems.<sup>9</sup>

locating the prostatic arteries is the most technically hard element of PAE, which increases radiation time. Understanding the structure of the male pelvic arteries can assist practitioners avoid issues like nontarget embolization of nearby organs (such as the bladder, rectum, or penis), save time, lowering the exposure time, achieving the best therapeutic outcomes possible.<sup>10</sup>

The origins of PA differ on the left and right sides. Besides this, recent reports on its anatomy are limited and primarily focused on DSA and multidetector computed tomographic (CT) angiography, otherwise those reports are inconsistent in some ways. PAs originating from the internal pudendal artery were seen to be 34 percent to 56 percent of the time, and two PAs per pelvic side were reported to be 24 percent to 43 percent of the time. PAs are small arteries that are difficult to detect using DSA alone.<sup>4</sup>

Our goal was to use DSA to describe the structural features and variations of PA.

Our work was done on thirty patients referred to the "Interventional Radiology Unit" of the Radiology Department, Sayed Galal university hospital for establishment of Trans arterial chemoembolization (TACE) and before the end of the session, the catheter directed to internal iliac artery (IIA) bilaterally and serial images were taken for the prostatic artery (PA).

The thirty patients suffered from Lower urinary tract symptoms, and all of them had previous treatment.

As regarding the age, prostatic volume, and International Prostate Symptom Score indices of the patients. The thirty patient's age ranged from 53 to 75 years with mean  $\pm$  SD equaled  $63.17 \pm 5.78$ , the prostatic volume of patients ranged from 40 to 80 ml, and its mean  $\pm$  SD was  $55.00 \pm 11.14$ , International Prostate Symptom Score (IPSS) mean  $\pm$  SD was  $21.83 \pm 6.16$ , where the minimum was 10 and the maximum was 32.

Prostate cancer (PC) is Egypt's 4<sup>th</sup> most prevalent cancer kind, with a 4.5 percent incidence rate among male cancer patients. In contrary to the low fatality rate, prostate cancer has a serious influence on the patients quality of life.<sup>11</sup>

PAE has showed good results for symptomatic reduction of LUTS problems in people with BPH. One of the hardest things of PAE is to recognize the PAs and distinguishing them from the nearby vasculature.<sup>9</sup>

An anatomical categorizing of prostatic artery sources was proposed, including five categories. This type of sorting is crucial to boosts general confidence during PAE, which leads to good results, fewer problems, and decreasing procedure times as well as radiation exposure.

In our study, as regarding the distribution Right prostatic artery anatomical classification of the patients, right prostatic artery classification was distributed as follows, 7(23.3%) were type I, 6(20%) type II, 5(16.7%) type III, 9(30%) type IV, and 3(10%) type V. Also Left prostatic artery classification was distributed as follows, 7(23.3%) were type I, 6(20%) type II, 5(16.7%) type III, 9(30%) type IV, and 3(10%) type V.

Similar to our results<sup>2</sup> concluded that, a total of 286 pelvic sides were examined, with 267 (93.3%) being categorized as I-IV types. Type IV was the most prevalent origin (n = 89, or 31.1 percent), followed by type I (n = 82, or 28.7%), type III (n = 54, or 18.9%), and type II (n = 42, or 14.7%). In 16 cases, Type V was seen (5.6 %).

In 2012<sup>4</sup> showed us a study in 150 pelvic sides. The study concentrated on describing the anatomy of the prostatic arteries by multi-slice CT and angiography prior to the PAE. they showed that, the commonest origin of the IVA was the internal pudendal artery

(34.1 %). This is a quite similar type IV in our cohort study of (30 %), while type II (IVA originating from the anterior division of the IIA) was seen in 17.8 % of Bilhim's patients, compared to 20 % of the cases in our study, and a common trunk with the SVA (type I) in their study VS our study was (20.1 vs. 23.3 %), also origin from the obturator artery (type III) was (12.6 VS 16.7 %). Collectively, the incidence of different anatomic patterns was similar, despite the different number of pelvic sides reviewed (286 VS 60).

In our study, as regarding the distribution of anastomosis of prostatic arteries with the surrounding structures of the patients, some anastomoses between the prostatic region and clinically relevant important organs including the bladder in one patient, Contralateral Prostatic artery in 4(13.3%), rectum in 2(6.7%), penis in 2(6.7%), and seminal vesicles in 3(10%).

In a study by <sup>12</sup>, reducing the prostatic volume is linked to the amount of prostate embolization.

For such circumstances, we assume that embolization of both the core gland and the capsular branches may be required to produce optimal prostatic ischemia, albeit this needs to be confirmed in more research.<sup>6</sup>

In the study of <sup>7</sup>, the PA origin of the PA was assessed using cone-beam CT in combination with DSA. Only one PA was found on 274 (92.6%) of the 296 pelvic sides. The common gluteo pudendal trunk with the superior vesicular artery was the most prevalent PA origin in 118 (37.1%), then the anterior division of the internal iliac artery in 99 (31.1%), internal pudendal artery in 77 (24.2%) pelvic sides. Communication with the nearby vasculature were found in 67 (22.6%) of the pelvic sides. Cone-beam CT found considerably more PA origins and anastomoses than DSA (301 of 318 (94.7 %) and 65 of 67(97.0 %) VS 237 (74.5 %) and 39(58.2%). In 90 of 148 (60.8 %) patients, cone-beam CT revealed critical information that DSA did not.

Also like our results regarding variations and anastomosis <sup>13</sup> concluded that in 110 hemipelves, a total of 114 PAs were discovered. In 96.4 % (n=106) of the hemipelves, there was only one PA, and in the remaining 3.6 % (n=4), there were two separate PAs. In 39.5 % of instances (n=45), the PA was determined to arise from the anterior trunk of the internal iliac artery, from the superior vesical artery in 32.6 % (n=37), and 27.9% (n=32) from the internal pudendal artery. Extra-prostatic anastomoses (n=43) were identified in 39.1% of hemipelves. A total of 61.8 % of hemipelves (n=68) had intra-prostatic anastomoses between PAs and contralateral prostatic branches. The prostate was predominantly supplied by a unilateral PA at 67.3 % (n=37) of this study.

In the study of <sup>7</sup> According to their findings, the occurrence of anastomoses between PAs and neighboring vasculature ranges from 32% to 60%, according to the method used (e.g., DSA, CT angiography, or cadaveric dissection). The rate of anastomoses to adjacent arteries was observed in

40% of pelvic sides in our research, which was similar to prior data.

From all the aforementioned data we can conclude that, despite the huge number of structural variations in the male pelvis, four primary patterns accounted for about 95% of the cases. PAE will be a quicker, cleaner, and more effective process if the anatomy is evaluated in a systematic way, using a standard classification.

### CONCLUSION

Despite the huge number of structural variations in the male pelvis, four primary patterns accounted for about 95% of the cases. PAE will be a quicker, cleaner, and more effective process if the anatomy is evaluated in a systematic way, using a standard classification.

### REFERENCES

- 1- Carnevale FC, Soares GR, de Assis AM, Moreira AM, Harward SH, Cerri GG. Anatomical variants in prostate artery embolization: a pictorial essay. *Cardiovascular and interventional radiology*. 2017;40(9):1321-37.
2. De Assis AM, Moreira AM, de Paula Rodrigues VC, Yoshinaga EM, Antunes AA, Harward SH, Srougi M, Carnevale FC. Prostatic artery embolization for treatment of benign prostatic hyperplasia in patients with prostates[90 g: a prospective singlecenter study. *J Vasc Interv Radiol*. 2015;26:87–93.
3. Christidis D, Clarebrough E, Ly V, Perera M, Woo H, Lawrentschuk N, Bolton D. Prostatic artery embolization for benign prostatic obstruction: assessment of safety and efficacy. *World journal of urology*. 2018 Apr;36(4):575-84.
- 4- Bilhim T, Pisco JM, Tinto HR, Fernandes L, Pinheiro LC, Furtado A, Casal D, Duarte M, Pereira J, Oliveira AG, O'Neill JE. Prostatic arterial supply: anatomic and imaging findings relevant for selective arterial embolization. *Journal of Vascular and Interventional Radiology*. 2012; 23(11):1403-15.
- 5- Laborda A, De Assis AM, Ioakein I, Sa'ñchez-Ballestrín M, Carnevale FC, De Gregorio MA. Radiodermatitis after prostatic artery embolization: case report and review of the literature. *Cardiovasc Intervent Radiol*. 2015.
- 6- Garcia-Monaco R, Garategui L, Kizilevsky N, Peralta O, Rodriguez P, Palacios-Jaraquemada J. Human cadaveric specimen study of the prostatic arterial anatomy: implications for arterial embolization. *Journal of Vascular and Interventional Radiology*. 2014; 25(2):315-22.
- 7- Wang MQ, Duan F, Yuan K, Zhang GD, Yan J, Wang Y. Benign prostatic hyperplasia: cone-beam CT in conjunction with DSA for identifying prostatic arterial anatomy. *Radiology*. 2017:282.
- 8- Carnevale FC, Antunes AA, da Motta Leal Filho JM, de Oliveira Cerri LM, Baroni RH, Marcelino AS, Freire GC, Moreira AM, Srougi M, Cerri GG. Prostatic artery embolization as a primary treatment for benign prostatic hyperplasia: preliminary results in two patients. *Cardiovascular and interventional radiology*. 2010 Apr;33(2):355-61.

- 9- Pisco JM, Bilhim T, Pinheiro LC, Fernandes L, Pereira J, Costa NV, Duarte M, Oliveira AG. Medium- and long-term outcomes of prostate artery embolization for patients with benign prostatic hyperplasia: results in 630 patients. *J Vasc Interv Radiol*. 2013;27:1115–22.
  
- 10- Moreira AM, Marques CF, Antunes AA, Nahas CS, Nahas SC, de Gregorio Ariza MA, Carnevale FC. Transient ischemic rectitis as a potential complication after prostatic artery embolization: case report and review of the literature. *Cardiovasc Intervent Radiol*. 2013;36:1690–4.
  
- 11- Mohamed H, Sherif MM, Ragheb AM, Lotfi AM, Mikhail MI, Ali RS, Hamed MK, El Magdoub H, Anan i. pcn487 cost of prostate cancer and quality of life in egypt-a patient perspective study. *Value in Health*. 2019;22:S531-2.
  
- 12- Frenk NE, Baroni RH, Carnevale FC, Gonçalves OM, Antunes AA, Srougi M, Cerri GG. MRI findings after prostatic artery embolization for treatment of benign hyperplasia. *American Journal of Roentgenology*. 2014;203(4):813-21.
  
- 13- Zhang G, Wang M, Duan F, Yuan K, Li K, Yan J, Chang Z, Wang Y. Radiological findings of prostatic arterial anatomy for prostatic arterial embolization: preliminary study in 55 Chinese patients with benign prostatic hyperplasia. *PLoS One*. 2015;10(7):e0132678.