

*Research Article***Survival assessment and function of heterotopic auto-transplanted thyroid tissue after total thyroidectomy**

Lamis H. Mohamed El Hadad*, Amr A. Mohsen**,
Mostafa N. El Sanadeky* and Khaled Mahran*

* Department of General Surgery; Faculty of medicine; Minia university; Egypt

**Department of General and Laparoscopic Surgery; Faculty of medicine; Cairo University; Egypt

Abstract

Background/Objective: Limited animal and human studies have shown function, albeit inadequate, of implanted thyroid tissue in muscles. This work aimed to ascertain results in a larger number of patients, finding practical method for implantation, studying the effect of changing weight of implant and effect of passage of time on its function. **Methods:** Forty patients had total thyroidectomy for simple multinodular goiters. A piece of the excised gland was finely minced, mixed with saline as emulsion, and injected in thigh muscles. Twelve patients had 5-g implants, while 28 patients had 10-g implants. Four parameters were studied at 2 months, 6 months, and 12 months: technetium isotope uptake by the implant; thyroid stimulating hormone (TSH); free T3 (FT3); and free T4 (FT4). **Results:** All autotransplanted thyroid tissue survived and functioned. After 12 months, mean values (standard deviation) of isotope uptake, TSH, FT3, and FT4 of the 5-g implants were 0.44 ± 0.16%, 27.74 ± 30.4 UI/mL, 3.07 ± 1.10 pg/mL, and 1.01 ± 0.3 ng/dL, respectively. Those for the 10 g implants were 0.71 ± 0.20%, 22.78 ± 19.7 UI/mL, 3.92 ± 1.2 pg/mL, and 1.05 ± 0.3 ng/dL, respectively. Ten-gram implants showed significantly higher isotope uptake than 5-g. TSH, FT3, and FT4 significantly improved over the period of 1 year. **Conclusion:** Injection of thyroid tissue suspension is a simple method for thyroid autotransplantation. TSH was elevated in the majority to maintain normal or near normal thyroid hormones. Ten-gram implants showed higher isotope uptake than 5-g, although this difference was not reflected by thyroid hormone profile. The implant seemed to function better with the passage of time from 2 months to 12 months.

Key words: multinodular goiter; thyroid autotransplantation; thyroidectomy

Introduction

Whenever surgery is indicated for a simple multinodular goiter, the current trend is to do total thyroidectomy.^{1,2} Inevitably this makes the patient dependent on replacement therapy for life. Although it seems relatively easy to control hypothyroidism by levo-thyroxine, from the patient's point of view, a daily dependence on it and regular visits to hospital to check hormone levels are burdensome. Other problems that may interfere with reaching a euthyroid status using replacement therapy are malabsorption³ and noncompliance of patients.⁴ The clinical application of transplantation in the endocrine field, by autotransplantation of endocrine organs for hormone replacement has already been established in the field of parathyroid surgery. Before applying the same principles on the thyroid gland in humans, studies have been done on animals. Autologous transplantations were found to be successful in 70% of cases

and histological examinations showed normal thyroid architecture.⁵⁻⁸ Very few studies have addressed this issue in humans. The number of patients in each study was very small,⁹⁻¹² the largest study including only 15 patients.¹² Furthermore, the study methodology was not consistent.

The aims of the current work were to ascertain these results in a larger number of patients, find a practical method of transplanting sizable thyroid tissue, and study the effects of changing weight of implant and passage of time on its function.

Patients and methods

This case series study was conducted at Minia University Hospital and included 40 patients with simple multinodular goiters who were indicated for total thyroidectomy because of compression manifestations, and where nodu-

larity extended to both lobes. Children, unwilling patients, and those who had any clinical or ultrasound suspicion of malignancy were excluded. Similarly, those with a family history of thyroid cancer and history of neck irradiation were excluded because they constitute a high risk of developing thyroid cancer. The study included 36 women and four men. Written informed consent was obtained from all patients, stressing the importance of regular follow up. Preoperative evaluation followed the same standard protocol and included a thorough history, examination, thyroid function tests, neck ultrasound, and fine-needle aspiration cytology of a dominant or suspicious nodule.

Total thyroidectomies were performed under general anesthesia. During postexcision hemostasis and closure a member of the operating team performed the autotransplantation preparation at a side table. The healthiest looking part of the thyroid was chosen. The slightest gross suspicion of malignancy led to termination of the implantation procedure. Intraoperatively, two patients were excluded from the study on

gross picture suspicion of malignancy. Neither showed cancer on histological examination of postoperative paraffin sections.

The initial 12 patients received 5-g implants, while the remaining 28 received 10-g implants. The tissues to be transplanted were very finely divided using a pair of scissors and made into an emulsion by adding them to saline in a 20-mL syringe. This was attached to a 2.4 mm-caliber needle. A 3-mm incision was made in the anterolateral aspect of the middle third of the thigh. Through this incision the thyroid tissue emulsion was injected in 8e10 sites in the thigh muscles by changing the direction and depth of needle introduction.

Results

Apart from minor complications, postoperative courses were uneventful. Temporary recurrent laryngeal nerve occurred in one patient and resolved spontaneously in 4 weeks. Temporary hypoparathyroidism occurred in 11 patients and was controlled by oral calcium and vitamin D. The condition resolved within 3e7 weeks. There were no complications related to the autotransplantation site. None of the excised thyroids showed histological evidence of malignancy.

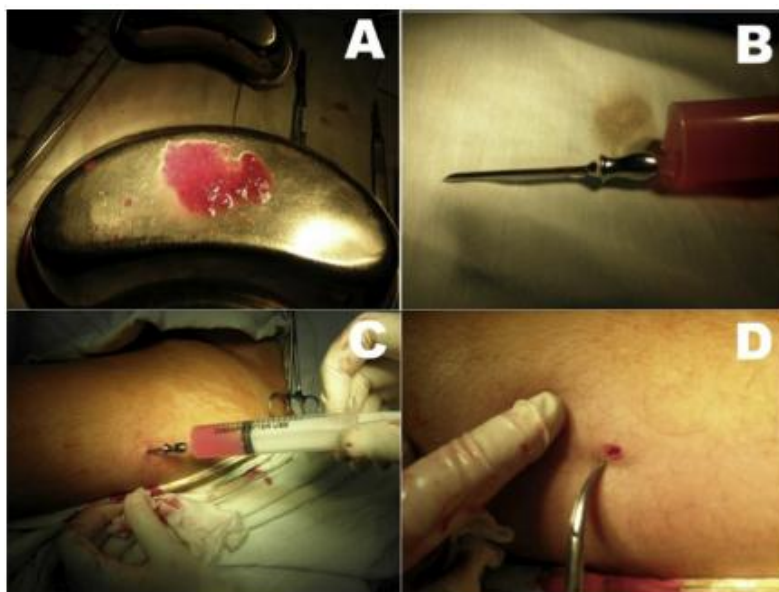


Figure 1 (A) Finely-minced thyroid tissue. (B) Emulsified thyroid tissue in saline, ready for injection. (C) Injection of the emulsion in the thigh. (D) The 3-mm incision after injection.

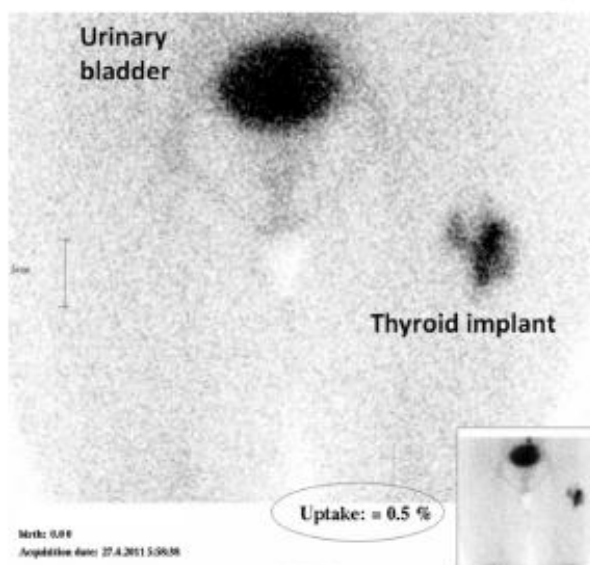


Figure 2 Normal isotope uptake (0.5%) by the implanted thyroid tissue in the left thigh

Table 1 ^{99m}Tc Uptake by the implant (n = 0.5–2%).

	5-g implants (12 patients)		10-g implants (28 patients)	
	Mean ± SD	% Patients achieving normal values	Mean ± SD	% Patients achieving normal values
2 mo	0.28 ± 0.16	8.3	0.44 ± 0.35	37
6 mo	0.28 ± 0.15	16.6	0.59 ± 0.27	73
12 mo	0.44 ± 0.16	41.6	0.71 ± 0.20	88

SD = standard deviation.

Table 2 Thyroid stimulating hormone levels (n = 0.4–4 UI/mL).

	5-g implants (12 patients)		10-g implants (28 patients)	
	Mean ± SD	% Patients achieving normal values	Mean ± SD	% Patients achieving normal values
Preop	2.26 ± 1.15		2.89 ± 1.22	
2 mo	49.56 ± 32	0	46.0 ± 26.2	0
6 mo	37.14 ± 29.6	0	37.04 ± 26.4	0
12 mo	27.74 ± 30.4	16.6	22.78 ± 19.7	3

SD = standard deviation.

Discussion

The purpose of heterotopic thyroid autotransplantation is to leave thyroid tissue in the body that might be able to avoid or reduce severity of post-thyroidectomy hypothyroidism in noncompliant patients. In the meantime, if recurrence occurs it would not be in the neck, thus avoiding compression on the trachea and avoiding dangerous reoperation in the neck. Reports on its clinical application are very scarce in the literature, with few patients in each study. Furthermore, none of these studies focused on simple multinodular goiters; the majority were directed to Graves' disease. The

only well documented study that addressed this issue with a few multinodular cases was that of Roy et al.,¹² who included eight multinodular goiters among their studied 15 patients.

In the best documented technical description, that of Shimizu et al.,¹¹ the workers implanted 2.5e3.5g per patient with Graves' disease. For the current work, the implanted tissue was expected to be less active and hence at the start of the study 5-g implants were implanted for the first 12 patients. As functional results of these patients were found to be suboptimal, the weight of implanted tissue was raised to 10 g.

The problem with implanting such sizable amount of tissue was that many muscle pockets are made; they would be over-packed with the implanted thyroid tissue, a factor that may hinder the graft take. The procedure would also take an unacceptably long time. In 2000, Gauger et al.,¹³ described the technique of injecting parathyroid emulsion in the sternomastoid. Their technique was adopted in this work for thyroid tissue implantation using a 20-mL syringe with saline. This technique simplifies the implantation of sizable tissues, in a short time (w15 minutes), and leaves a small, barely visible scar. With this technique all implants survived and functioned.

In the literature there is no previous mention of the effect of time passage on the function of thyroid autotransplant. In the current work, however, this point was investigated. Analysis of variance showed that the levels of FT3 and FT4 increased with time, and likewise TSH showed significant move towards normalization, i.e., reduction of its levels. Even though isotope uptake showed also a tendency towards elevation, it did not reach statistical significance.

Conclusion

Injection of thyroid tissue suspension is a simple method for thyroid autotransplantation. TSH was elevated in the majority to maintain normal or near normal thyroid hormones. Ten-gram implants showed higher isotope uptake than 5-g, although this difference was not reflected by thyroid hormone profile. The implant seemed to function better with the passage of time from 2 months to 12 months

References

1. Moalem J, Suh I, Duh Q. Treatment and prevention of recurrence of multinodular goiter: an evidence-based review of the literature. *World J Surg.* 2008; 32:1301 e1312.
2. Agarwal G, Aggarwal V. Is total thyroidectomy the surgical procedure of choice for benign multinodular goiter? An evidence-based review. *World J Surg.* 2008; 32:1313e1324.
3. Lips DJ, van Reisen MT, Voigt V, Venekamp W. Diagnosis and treatment of levothyroxine pseudomalabsorption. *Neth J Med.* 2004;62:114e118.
4. Sethi MJ, Parr M, Bhatia V. Management strategies for hypothyroidism in noncompliant patients: a case report and review of literature. *S. D Med.* 2008;61:368e369.
5. Shimizu K, Nagahama M, Kitamura Y, Igarashi T, Aida N, Tanaka S. Improvement of thyroid function after autotransplantation of cryopreserved thyroid tissue in rats: clinical application of the procedure to patients with persistent hypothyroid Graves' disease after thyroidectomy. *Thyroidol Clin Exp.* 1996;8:55e62.
6. Papaziogas B, Antoniadis A, Lazaridis C, et al., Functional capacity of the thyroid autograft: an experimental study. *J Surg Res.* 2002;103:223e227.
7. Ga'1 I, Miko' I, Furka I, Nagy D. Autotransplantation of cryopreserved thyroid tissue in dogs. *Magy Seb.* 2005; 58:93e99 [in Hungarian].
8. Dobrinja C, Trevisan R, Trevisan G, Liguori G. Autotransplantation of thyroid tissue in rats. An experimental study. *Ann Ital Chir.* 2008;79:389e395.
9. Pushkar' NS, Makedonskaia VA, Utevskii AM, Chuiko VA, Karpenko LG. Autoimplantation of cryopreserved (-196 degrees C) thyroid gland parenchyma as a treatment method in postoperative hypothyroidism. *Probl Endokrinol (Mosk).* 1984; 30:42e46 [in Russian].
10. Okamoto T, Fujimoto Y, Obara T, Ito Y, Kodama T, Kusakabe K. Trial of thyroid autotransplantation in patients with Graves' disease whose remnant thyroid has unintentionally been made too small at subtotal thyroidectomy. *Endocrinol Jpn.* 1990;37: 95e101.
11. Shimizu K, Kumita S, Kitamura Y, et al., Trial of autotransplantation of cryopreserved thyroid tissue for postoperative hypothyroidism in patients with Graves' disease. *J Am Coll Surg.* 2002;194:14e22.
12. Roy PG, Saund MS, Thusoo TK, Roy D, Sankar R. Fate of human thyroid tissue autotransplants. *Surg Today.* 2003;33: 571e576.
13. Gauger PG, Reeve TS, Wilkinson M, Delbridge LW. Routine parathyroid autotransplantation during total thyroid-ctomy: the influence of technique. *Eur J Surg.* 2000;166:605e609.