

Modified Sinotomy Versus Modified Limberg Flap In Treatment Of Pilonidal Sinus

Mahmoud Ali Khodery Ali ^{1,*} M.B.B.CH, Ashraf Abd El Hameed Abd El Monaem ² MD,

Mohammed Shaaban Nassar ² MD

General Surgery

*Corresponding Author:

Mahmoud Ali Khodery Ali

drmahmoudalikhodery@gmail.com

Received for publication October 24, 2021; Accepted February 21, 2022; Published online February 21, 2022.

Copyright The Authors published by Al-Azhar University, Faculty of Medicine, Cairo, Egypt. Users have the right to read, download, copy, distribute, print, search, or link to the full texts of articles under the following conditions: Creative Commons Attribution-Share Alike 4.0 International Public License (CC BY-SA 4.0).

doi: 10.21608/aimj.2022.101416.1615

¹General Surgery Department, Almonira Hospital, Cairo, Egypt.

²General Surgery Department, Faculty of Medicine, Al-Azhar University Cairo, Egypt.

ABSTRACT

Background: There is still no consensus about treatment of pilonidal sinus disease, as it is actually a rather controversial disease, with high probability of its recurrence, and its care takes a long time. Ideally, therapy should be associated with short hospital stay, less painful postoperative time, rapidly healing and return to work, short term wound care and a low recurrence rate. No technique fulfills all of these criteria.

Aim of the work: To compare the efficiency and results between modified sinotomy and modified limberg flap in management of pilonidal sinus.

Patients and methods: In this prospective randomized, study 30 patients with chronic pilonidal sinus disease (less than 4 years history), were randomly allocated to either modified sinotomy with marsupialization or modified Limberg flap.

Results: Using visual analogue scales (VAS), to measure postoperative pain for both group. The average score for the modified sinotomy group was 6.2±1.47, while in modified Limberg flap group was= 5.6±1.05. VAS was also used to measure patient's satisfaction. In sinotomy group, the recorded degree of satisfaction of the end scar has an average 7.6±1.06. In the flap group, the average is 6.16±1.45. The result found to be significantly more satisfaction for sinotomy group (p value < 0.0001).

Conclusion: Sinotomy with marsupialization give much less time of operation, less postoperative complication and hospital stay together with more satisfaction of the patients. However, modified Limberg flap show much less healing time and early time to return to work.

Keywords: Modified Limberg flap; Modified Sinotomy; Pilonidal Sinus.

Disclosure: The authors have no financial interest to declare in relation to the content of this article. The Article Processing Charge was paid for by the authors.

Authorship: All authors have a substantial contribution to the article.

INTRODUCTION

Sacrococcygeal pilonidal sinus disease is a common disorder among young adults, with a 3:1 male-to-female ratio. Usually presented as painful sinus tract of the natal cleft, or as an abscess ¹.

The etiology of pilonidal disease has been surrounded by controversy. In the 1950s the predominant thinking was that this was a congenital condition; however, current theories focus on predisposing factors and it has long been thought to be an acquired condition. Therefore, modifying natal cleft together with lateralization of the midline is of utmost importance to help eliminate the causative factors of this condition ².

Although flap techniques have been practiced at many centers with considerable success, recurrence is still encountered more often than predicted. Lately, the Karydakis and Limberg flap techniques have had low recurrence rate and complication rate compared with other flap techniques ³.

The ideal approach for treating pilonidal disease should be simple technique with minimal postoperative pain, have the best chance for a cure

with the least local recurrence rate. Return to workperiod should be as short as possible because of the economic impacts ⁴.

The aim of this prospective study was to compare between modified sinotomy and modified limberg flap in management of pilonidal sinus.

PATIENTS AND METHODS

This study was planned as a prospective, randomized comparative study. The study patients were 30 consecutive patients with chronic pilonidal sinus (PSD) admitted to Almonira Hospital between April 2021 and June 2021.

Only patients with simple chronic PSD (history less than 4 years) were included in the study, who were defined by having minimal inflammation with easily visualized midline pits and secondary openings over a limited area of the natal cleft. While, those with acute pilonidal abscesses, diseases acknowledged to have an effect on wound healing such as diabetes and immunodeficiency, previous surgery in the sacrococcygeal region for pilonidal sinus, psychic disorders, or apparently poor hygiene were excluded.

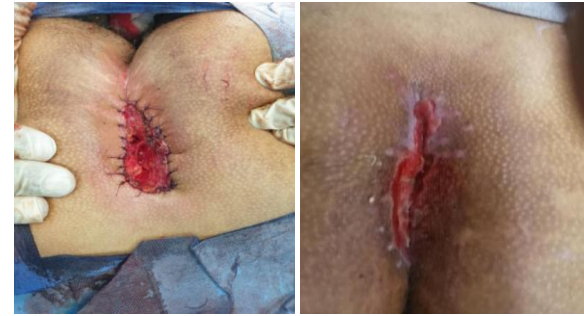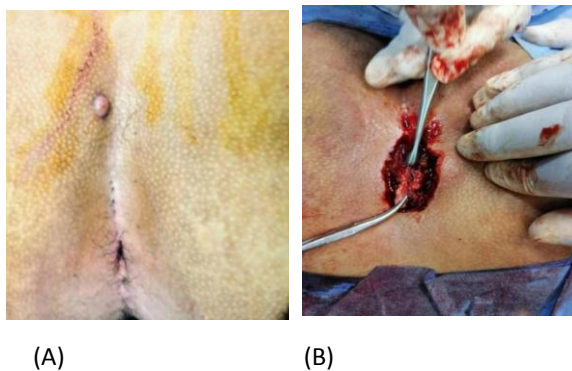
Patients were classified into two groups of 15 patients each through a randomized closed envelope technique. Group (A), was treated by modified sinotomy. Group (B) was treated with modified Limberg flap (MLF).

All eligible patients gave informed consent to participate in the study. The protocol was submitted to and approved by an ethics committee.

Preoperative preparation: Full history is taken and all patients will be examined for signs of acute inflammation, and presence of previous midline or lateral scars. Routine pre-operative investigations were done for each patient.

Surgical technique: These patients were allowed a fluid only in the afternoon before the surgery. Meticulous shaving of hair of the lower back and both gluteal regions was performed the evening before the day of the surgery. The type of anesthesia was justified according to the anesthesiologist and patient preference. Intravenous antibiotic prophylaxis of 1.5 g ampicillin-sulbactam, and 500 mg of metronidazole were given at the time of induction to be continued for 5 days postoperatively. The patients were positioned in the prone position and the trunk was slightly jackknifed at the hips. The buttocks were strapped apart by an adhesive tape to allow wide exposure of the operative field. The surgical area was disinfected with 10% povidone iodine solution.

Group A (sinotomy and marsupialization): Methylene blue 0.5–1 ml is injected through the most prominent opening of the pilonidal sinus to help define the margins of the diseased tissue. If there was just one opening, electrocautery was used to make a vertical incision in the midline. When numerous holes were discovered, the incision was created by vertically joining them all. All chronically infected granulation tissue, hairs, and debris in the cavity were removed after the sinus was opened. The skin margins and the top third of the lateral borders enclosing the hollow were "beveled" sharply at a 45° angle after the base of the sinus was curetted. After hemostasis, a continuous lock stitch or interrupted simple sutures of absorbable suture were used to approach the margins of the skin and the top margin of the fibrous boundary of the sinus cavity (Monocryle, Ethicon,) in order to perform marsupialization to narrow the open area. The wound was covered with povidone-iodine gauze. fig: 1, (A, B, C, D).



(C) (D)
Fig. 1: illustrations of sinotomy operation (A) before operation., (B) all tracts are laid down and connected together, then curettage of the floor of sinuses tract is done with with excision of the lateral wall of the sinus (C) marsupialization of the skin edge .(d) 3 weeks after operation.

Group B (modified limberg flap): Using a sterile skin-marking pen, the pathologic area to be excised and the flap design were mapped on the skin. The flap technique was carried out according to described method by Singh et al.⁵. During the procedure, a rhomboid incision was made, accompanied by removal of the affected region plus a rim of healthy tissue surrounding the cyst and sinuses en bloc. The lower corner of the excised rhomboid region changed into located 1.5 cm lateral to the midline as shown in (Fig. 2). A fascio-lipocutaneous Limberg flap was prepared at the gluteal area contralateral to the asymmetric lower corner of the defect incorporating the gluteal fascia, completely mobilized on its inferior edge and transferred medially to correct the rhomboid defect without causing tension. A vacuum drain was placed, and the Limberg flap was secured with deep, interrupted 2/0 vicryl sutures passing through the flap and the edges of the defect. The subcutaneous layer was approximated with 3/0 vicryl interrupted sutures, as demonstrated in Fig. 2. (A, B, C, D)

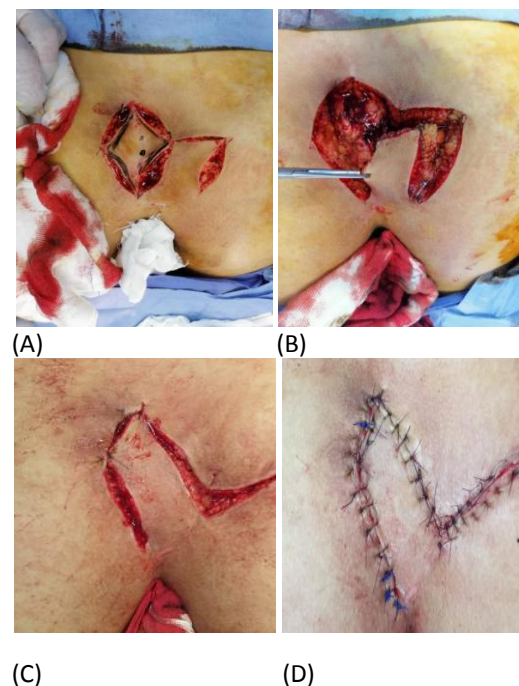


Fig (2): Modified Limberg flap (A): planning the shape, size, site that will be excised and the flap (B): rotation of the flap (C): The inferior angle is just lateral to the middle line (D): Closure with interrupted sutures.

Postoperative care and follow-up

As regard group A; the patient is without drain which may lead to less postoperative pain. However analgesia and antibiotics are given as mentioned above. He (she) may take baths or showers after the third day. The dressing is changed daily by the patient or relative after the first dressing done in the hospital before discharge. Usually trials to return to work in less than 2 weeks after the operation.

As regard the patients with MLF (group B), the wound was exposed on the first postoperative day to check for flap viability. When the output is less than 10 ml in 24 hours, the suction drain is removed. On the 14th postoperative day, the stitches were removed. The patients were allowed to return to normal activities after the removal of stitches, with avoiding prolonged sitting, excessive physical strain for the following 3–4 weeks.

Patients in both groups were followed up on weekly basis for the first month, then on monthly basis for the following 3 months. All patients were assessed

for the following: Duration of the operation, postoperative pain and complications, hospital stay, time of return to work, patient satisfaction of the cosmetic appearance.

The visual analogue scales (VAS); which are psychometric response scales used to measure subjective characteristics or attitudes of the patients. VAS has scale from 1 to 10, was used in order to assess the postoperative pain and cosmetic conditions.

Data were collected by examining the patients during postoperative dressing in the clinic, weekly until three months. The duration from the date of the surgery to the date when the wound was entirely closed in Group A and the date when skin sutures were removed in Group B patients was called "healing time." The term "recurrence" was used when symptoms of the disease recurred after an interval following complete wound healing.

Statistical analysis: All results, measurements will be collected and shown as mean and median ranges \pm standard Deviations and will be tabulated and discussed in a simple manner in numbers and percentages. The significances of differences between the groups were compared using Student's t-test.

RESULTS

Number of patients participated in this study were 30 (n=30). Male patients were 20 (66.6%) and females were 10 (33.3%) with an overall male to female ratio of 2:1.

Age range for group A from 17-33, with an average age of 24.06 ± 4.25 years old, while the age range in group B from 18-28 (22.73 ± 2.86) years. There were no statistically significant differences with respect to age between the two groups ($P=0.323$). The age range for both group is between 17- 33. The (average 23.4 ± 3.56). Only 5 patients of the 30 are working as drivers (16.6%), while the others have different jobs other than driving a car.

Operative duration in the group A, having a range of 25 – 55 minutes (38.8 ± 8.4) (chart 1). Operative time of group B have a range of 50- 85 minutes (68.06 ± 8.97) (chart 1) (table 1). This results yield a significantly less operative time in the sinotomy and marsupialisation group (P value <0.001).

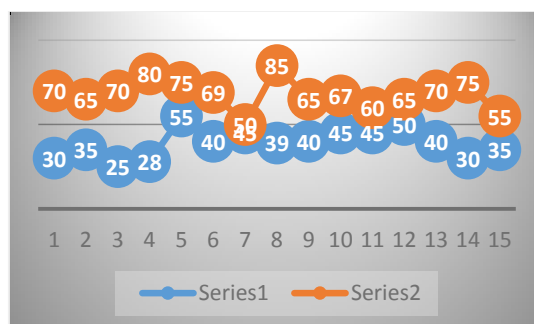


Chart 1: Operative time chart: group A (blue color) group B (brown color)

According to the use of visual analogue scales (VAS) In the group A the recorded pain score range from 4 to 9 (6.2 ± 1.47) while the score in group B has a range of 4-7 (5.6 ± 1.05). p value is >0.05 which is not significant (chart 2).

In group A 2 patients has mild pain, 10 with moderate pain, 3 with severe pain while in group B 3 patients with mild pain and 12 with moderate pain while there was no patient with severe pain.

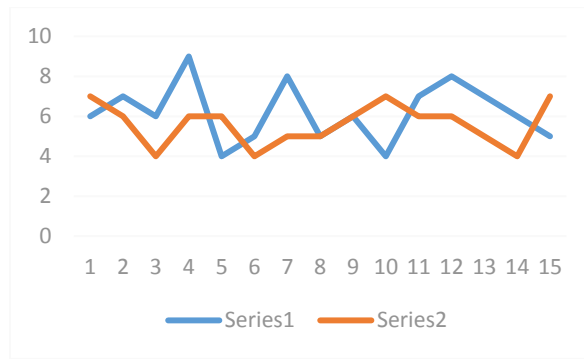


Chart 2: Postoperative pain illustrated in curves, A is blue curve while B is brown

The hospital stay for group A range from 1 to 3 days (1.3 ± 0.63), while for group B, the hospital stay have range of 2-5 days (2.86 ± 1.06), which is found to be not significant (p value 0.0827).

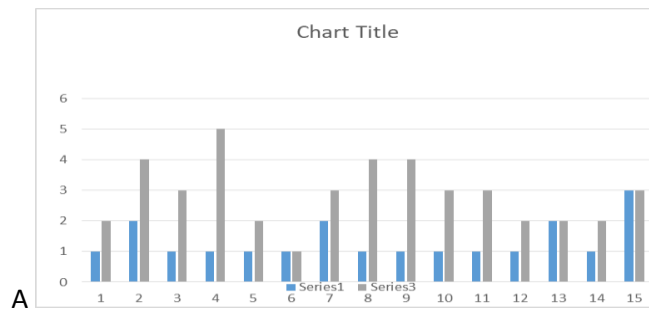


Chart3: Hospital stay, group A is in blue colour while group B in gray

Item to be discussed	Group A Modified sinotomy	Group B Modified limberg flap	P value
Gender	11 male 4 female	9 male and 6 female	
Age	Range 17-33 average 24.06 ± 4.25	Range 18-28 average 22.73 ± 2.86	P value 0.323 Insignificant
Operative time	Range 25-55 minutes average 38.8 ± 8.4	Range 50- 85 minutes Average 68.06 ± 8.97 .	P value <0.001 Significant
Postoperative pain according to VAS score	Range 4 to 9 Average score of 6.2 ± 1.47	Range 4-7 Average 5.6 ± 1.05	p value <.05 Insignificant
Hospital stay	Range 1 to 3 days Average 2.06 ± 0.73 ,	Range 1 to 3 days Average 1.73 ± 0.59	p value 0.089 non significant

Table 1: The clinical outcome for both group

As shown in the table (2), only one of 15 in the group A have postoperative complications after the discharge from the hospital, in the form of wound infection, while in the group B, there are 2 cases with seroma, 2 wound infection, and 1 with wound break down. For both group, There was no bleeding or hematomas in post-operative period during the hospital stay, also there was no recurrence as the time of follow up in the study is only 3 months which is too short to discover this complication,

Postoperative complications	Group A (sinotomy & marsuplization)	Group B (modified limberg)
Bleeding or hematoma	0	0
Seroma	0	2
Wound infection	1	2
Wound break down	0	1

Table 2: Postoperative complication

In the group A, time to complete healing was ranging from 38 - 60 days (average 45.3 ± 56) while for the group B, time to healing has the range of 27-33 (30.13 ± 3.2) days, which is significantly less in favour of modified Limberg flap (p value <.001) (chart 4).

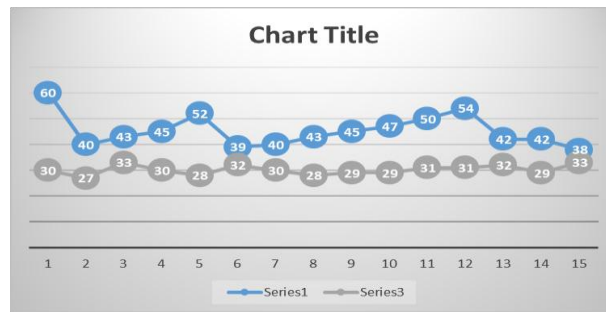


Chart 4: Time to complete healing

Group A, the time to return to work is 3- 8 weeks (average 4.86 ± 1.50), while in Group B, the time to return to work was ranging from 2 -6 weak (of 3.86 ± 1.24), which is not significant (p value is 0.057).

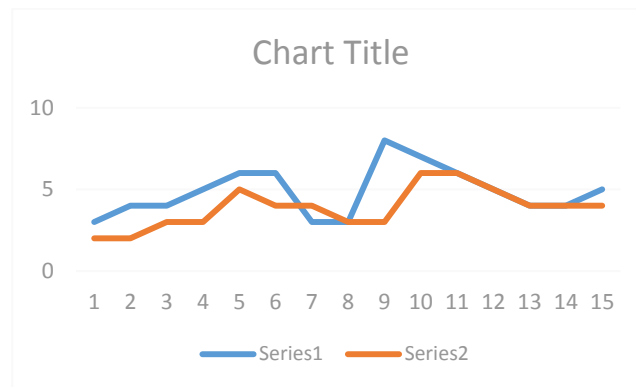


Chart 5: Time to return to work

To measure patient's satisfaction about the end scar after wound healing, VAS was also used, from 0 (not satisfied at all) to 10 (completely satisfied). In case of group (A), the recorded degree of satisfaction of the end scar is ranging from 7 to 10 (7.6 ± 1.06), while in the group B, it has the range between 5 to 9 (6.16 ± 1.45). This result show more significant satisfaction for the scar in the sinotomy (p value < 0.0001) (chart 6).

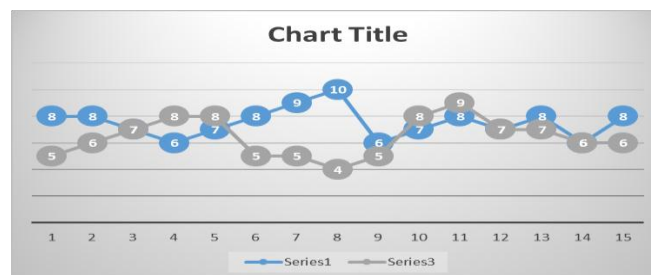

Chart 6: Cosmetic appearance and patient satisfaction

DISCUSSION

Operative time in the group of modified sinotomy of the present study, have a range of 25–55 minutes with average time 38.8 ± 8.4 which is more similar to the results of Grag et al. ⁶ in their meta-analysis which include 13 studies (n=1445) describing laying open (not excision) of sinus with curettage of the tract to treat pilonidal disease (simple and complicated). They recorded mean time for procedure average from 15 to 53 minutes (average 34.6 minutes). Also similar to the results of other authors ⁷. However, it takes much more operative time than that of other randomized prospective study ⁸, that recorded operative time range between 20-35 minutes (average 27.17 ± 4.29).

The operative time for modified Limberg flap range between 50- 85 minutes (average 68.06 ± 8.97). This result of the current study show less time than that obtained by Karakayali, et al. ⁹ study which give Duration of operation for Limberg flap with the average 89.3 ± 31.0 minutes (range 45-165), and for sinotomy and marsupialization, average time of 53.1 ± 20.4 minutes (range 20-120).

From all the above results sinotomy with marsupialization has significantly shorter time of operation than that of modified limberg flap.

According to the use of visual analogue scales (VAS): The patients of the group A, recorded pain score range from 4 to 9 (6.2 ± 1.47) while the score in group B has a range of 4-7 with average score of 5.6 ± 1.05 . p value is <.05, yet is lower pain in

sinotomy group but it is not significant. This results agree with the results of other authors¹⁰ which compare flap reconstruction vs the laying open technique or excision and direct suture for pilonidal sinus disease which showed no big distinction among flap and different approaches in terms of postoperative pain. Karakayali et al.⁹ found that pain score were significantly lower for unroofing and marsupialization than for Limberg flap reconstruction.

In the meta-analysis that done by Brethier et al¹⁰, it found that the flap approach required more inpatient time than the laying open technique, with a mean difference of 0.98 (0.28-1.68) days (P =.006). The results of the current study, group A (modified sinotomy) has hospital stay range from 1 to 3 day (average 1.3±0.63), while with group B (modified limberg flap), the hospital stay have the range from 2 to 5 days (average 2.86±1.06). The p value is 0.0827.

In the current study only one case of the modified sinotomy group has infection, with no wound breakdown or bleeding. While in the group of modified Limberg there are 2 cases (13.3%) of infection, another 2 cases (13.3%) with seroma accumulation and one case of wound breakdown. This result is much similar to that recorded by Ekici et al.⁴, as they recorded wound site infection in 5 cases (9.4%) in lay open group while 23 cases of wound site infection (20.2%) in modified Limberg group. This result is completely different of that obtained by Karaca et al¹¹ which has no infection and only one patient with postoperative seroma despite of the larger number of cases in Karaca et al study. Alvandipour et al¹² reported one case of Limberg flap group with flap necrosis and wound dehiscence, which is similar to the current study.

Karakayali et al.⁹ reported 11.2± 5.8 days as an average time for work return in cases with unroofing and marsupialization and an average of 17.9 ± 9.3 days for the limberg flap.

While in the current study, Group A, has the range of return to work between 3- 8 weeks (4.86±1.50), while in Group B, the time to return to work was ranging from 2 -6 weak (3.86±1.24). This results show that the patients in the current study need much more time to return to work in comparison to that of the other studies

In case of group (A) group of modified sinotomy, the recorded degree of satisfaction of the end scar and quality of life has average 7.6±1.06, while in the group B of modified Limberg flap, the average was 6.16±1.45. The result is significantly more satisfaction for the scar of sinotomy (p value < 0.0001). Berthier et al.¹⁰ The meta-analysis determined no distinction in patient satisfaction among the flap and the laying open approach (P =.32), with the records pointing to a superior quality of lifestyles and patient satisfaction with the flap.

Garg et al.⁶ after their systematic review concluded that that deroofting the pilonidal sinus and curettage of the cavity should be the first-line treatment for all forms of pilonidal sinus disease. It has a number of advantages: it can be used to treat a variety of diseases (both simple and complex), it has a low

complication rate, it can be performed as an outpatient procedure under local anesthesia, it is simple and quick, it preserves body contours, it requires little or no hospitalization, it causes less pain, and it allows patients to return to their normal routine and work sooner, low cost and can be easily done again in case of a failure.

Nessar et al¹³ concluded that marsupialization seems to offer a more rational approach to the problem. It has simple technique and low recurrence rate.

CONCLUSION

Both procedure give good results, but sinotomy with marsupialization give much less time of operation, less postoperative complication and hospital stay together with more satisfaction of the patients. However, modified Limberg flap show much less healing time and early time to return to work.

REFERENCES

- 1- Doll D, Matevossian E, Hoenemann C, Hoffmann S. Incision and drainage preceding definite surgery achieves lower 20-year longterm recurrence rate in 583 primary pilonidal sinus surgery patients. *J Dtsch Dermatol Ges* 2013; 11:60–4.
- 2- Milone M, Velotti N, Manigrasso M, Anoldo P : Long-term follow-up for pilonidal sinus surgery: A review of literature with metanalysis. *The Surgeon*; 2018; 16(5):315-20.
- 3- Akinci OF, Bozer M, Uzunköy A, Düzqün SA : Incidence and aetiological factors in pilonidal sinus among Turkish soldiers. *Eur J Surg*. 2011; 165:339–42
- 4- Ekici U, Kanho M, Ferhatoglu MF. A comparative analysis of four different surgical methods for treatment of sacrococcygeal pilonidal sinus. *Asian Journal of Surgery*. 2019 ; 42: 907e913
- 5- Singh PK, Gohil RK, Saxena N. Limberg flap procedure for sacrococcygeal pilonidal sinus: a prospective study. *International Surgery Journal*. 2017; 4(7):2238-42.
- 6- Garg p, Menon GR, Gupta V. Laying open (deroofting) and curettage of sinus as treatment of pilonidal disease: a systematic review and meta-analysis. *ANZ J Surgery*.2016; 86: 27–33
- 7- Gencosmanoglu R, Inceoglu R Modified lay-open (incision, curettage, partial lateral wall excision and marsupialization) versus total excision with primary closure in the treatment of chronic sacrococcygeal pilonidal sinus: a prospective, randomized clinical trial with a complete two-year follow-up. *Int. J. Colorectal Dis*.2015; 20: 415–22.
- 8- Abdeer AF, Elhefny AM, Boshra Gerges WB. Modified Sinotomy with Marsupialization versus Excision with Lay Open in Treatment of Pilonidal Sinus Disease. *Biomedicine and Nursing*.2021; 7(1): 80-6.

- 9- Karakayali F, Erdal Karagulle E, Karabulut Z, Oksuz E. Unroofing and Marsupialization vs. Rhomboid Excision and Limberg Flap in Pilonidal Disease: A Prospective, Randomized, Clinical Trial. *Diseases of the Colon & Rectum*.2011; 52 (3): 496-502
- 10- Berthier C, Bérard E, Meresse T, Grolleau J A comparison of flap reconstruction vs the laying open technique or excision and direct suture for pilonidal sinus disease: A meta-analysis of randomised studies. *Int Wound J*.2019; 16:1119–35.
- 11- Karaca T, Yoldaş Ö, Bilgin BÇ, Özer S. Comparison of short-term results of modified Karydakis flap and modified Limberg flap for pilonidal sinus surgery. *Int J Surg*. 2012; 10 (10):601-6.
- 12- Alvandipour M, Zamani MS, Ghorbani M, Jamshid “Comparison of Limberg Flap and Karydakis Flap Surgery for the Treatment of Patients with Pilonidal Sinus Disease: A Single-Blinded Parallel Randomized Study”. *Annals of Coloproctology*. 2019; 35(6): 313- 8.
- 13- Nessar G Marsupialization: Salvage Surgery for the Recurrence of Flap Techniques Used in the Treatment of Pilonidal Disease. *Clin Surg*. 2021;6.;3166.