

Histopathological and Biochemical Study of Toxic Effects of the Chronic Administration of Bisphenol A on The Pituitary and Thyroid Glands of Adult Albino Rats

Abdo Y. Hamed^{1*} MSc, Fouad H. El dabbah¹ MD, Ashraf I. Hassan¹ MD, Ahmed I. Elshoura² MD and Nasser A. Omar³ MD.

* *Corresponding Author:*

Abdo Y. Hamed

drabdoyoussef9@gmail.com

Received for publication October 29, 2021; Accepted February 21, 2022; Published online February 22, 2022.

Copyright The Authors published by Al-Azhar University, Faculty of Medicine, Cairo, Egypt. Users have the right to read, download, copy, distribute, print, search, or link to the full texts of articles under the following conditions: Creative Commons Attribution-Share Alike 4.0 International Public License (CC BY-SA 4.0).

doi: 10.21608/aimj.2022.101454.1616

¹Department of Forensic Medicine & Clinical Toxicology, Faculty of Medicine, Al-Azhar University, Cairo Egypt.

²Department of Forensic Medicine & Clinical Toxicology, Faculty of Medicine, Damietta, Al-Azhar University, Cairo, Egypt.

³Department of Pathology, Faculty of Medicine, Al-Azhar University, Cairo, Egypt.

ABSTRACT

Background: Bisphenol A (BPA) is one of the highest production volume chemicals that is frequently used in consumer products based on polycarbonate plastic and epoxy resins including children's toys, plastic bottles, plastic food containers, and medical equipment.

Aim of the work: To demonstrate the possible chronic toxic effect (biochemical & histopathological) of bisphenol A on pituitary and thyroid glands of adult albino rats.

Material and Methods: One hundred adult healthy albino rats weighing 180 – 220 g were acquired from the animal house, Assiut University, Egypt. The animals were classified into five groups; group (1): ten adult albino rats, received normal feeding for three months, group (2): fifteen rats received 1 ml of the corn oil for three months, group (3): Twenty-five rats received BPA at a dose 80mg/kg/day orally for 3 months, Group (4): Twenty-five rats received BPA at a dose 160 mg/kg/day orally for 3 months, Group five: Twenty-five rats received BPA a dose 320mg/kg/day orally for 3 months.

Result: Bisphenol A has deleterious effects on the biochemical and histological structure of the pituitary and thyroid glands of albino rats. TSH, T4, and T3 demonstrated marked reduction in rats following 3 months of BPA exposure in comparison with non-BPA exposed rats. Bisphenol-treated group stained with H and E showed loss of normal thyroid architecture.

Conclusion: The current study demonstrated that BPA exposure seemed to have potentially toxic effects on thyroid as well as pituitary functions in terms of biochemical as well as histopathological levels.

Keywords: Bisphenol A; Pituitary; Thyroid.

Disclosure: The authors have no financial interest to declare in relation to the content of this article. The Article Processing Charge was paid for by the authors.

Authorship: All authors have a substantial contribution to the article.

INTRODUCTION

Endocrine disruptors are environmental chemicals that mimic, block, or interfere with hormones, neurotransmitters or receptors in the body. The matter of concern is that exposure to such chemicals in the environment seems to be unavoidable as they have been found in air, water, dust, and soil as well as in a wide range of household products. One of the most frequently utilized and comprehensively studied endocrine disruptors is bisphenol A (BPA).¹

Bisphenol A is one of the highest production volume chemicals that is frequently used in consumer products based on polycarbonate plastic and epoxy resins including children toys, plastic bottles, plastic food containers, water pipes, food can linings, dental sealants, and medical equipment and tubing. It is also found in thermal papers as cash register receipts.²

Bisphenol A could be discharged from consumer products and deposited in the environment creating potential for human exposure via oral route (diet), inhalation, and dermal contact.³

Noteworthy, impairment of neurological functions including hyperactivity was observed in experimental animals after BPA exposure.⁴ In addition, there is evidence linking childhood behavioral disorders with BPA exposure.⁵

The present study will be conducted to demonstrate the possible chronic toxic effect (biochemical & histopathological) of BPA on pituitary and thyroid glands, of adult albino rats.

MATERIAL AND METHODS

One hundred (100) adult healthy albino rats western strain weighing 180 – 220 g were acquired from the

animal house, Faculty of Medicine, Assiut University, Egypt and housed in a clean spacious macro-lane cages (5 per cage which was 60x40x25 cm) under standard laboratory situations such as good aerated room with adequate temperature, relative humidity, maintained at good light with normal light/dark cycles. All rats were given normal rat diet during the experimental period with free access to water.

Drugs and chemicals: Bisphenol A compound 99.9 % purchased from Sigma Company.

Kits for determination of serum (TSH), (T4), (T3), (FSH), (LH), (GH), (ACTH) purchased from Pishtaz Teb Diagnostics Company, Iran .

Experimental design: The animals were classified into five groups:

Group one (Negative control group): Ten (10) adult albino rats, received nothing except normal feeding for three months (90 days).

Group two (Positive control group or vehicle control): Fifteen (15) adult albino rats. Each animal received 1 ml of the vehicle which is (corn oil) once daily orally by a curved needle-like oral tube introduced in a direct manner into stomach (gavage process) for three months (90 days).

Group three: Twenty five (25) adult albino rats. Each animal received BPA compound dissolved in corn oil at a dose 80mg/kg/day orally by gavage (which represent 1/40 LD50) for 3 months (90 days). The oral LD50 of BPA in rats is estimated to be about 3200 mg/kg body weight.⁶

Group four: Twenty five (25) adult albino rats. Each animal received BPA compound dissolved in corn oil at a dose 160 mg/kg/day orally by gavage (which represent 1/20 LD50) for 3 months (90 days).

Group five: Twenty five (25) adult albino rats. Each animal received BPA compound dissolved in corn oil at a dose 320mg/kg/day orally by gavage (which represent 1/10 LD50) for 3 months (90 days).

All groups are weighing before and after the experiment and the mean weight are tabulated .

At the end of this period and after exclusion of dead rats, the biochemical and histopathological examination were done on 100 rats.

All animals were sacrificed by decapitation using light ether anesthesia after 24 hours of the last dose .

Biochemical analysis: Two sets of three ml blood sample was collected from each rat of control and treated rat groups at the start and after 3 months (90 days) in glass vial (Vacutainer tube) without anticoagulant (5ml capacity).

Blood samples were held on ice and serum was acquired by centrifugation of samples at 2000 r.p.m for 15 minute within one hour of collection. Serum samples were stored at -20 °C until the day of analysis.

Light microscopic examination : The Pituitary and thyroid glands, of all rat groups were fixed in 10% Formalin. After fixation, the specimens were dehydrated through ascending grades of ethanol, cleared and then embedded in paraffin. Paraffin sections of 5 µm thickness were prepared and stained with haematoxylin and eosin. The stained specimens were examined using light microscope.

Statistical Analysis: Information was evaluated for normality by utilizing the Anderson-Darling test and for homogeneity variances before additional statistical analysis. Continuous variables defined by mean and standard error (Mean, SE). Comparison between continuous variables was performed by student t-test. The two-tailed $p < 0.05$ value was considered statistically significant. Entire analyses were conducted with the IBM Statistical Package for Social Sciences (SPSS) program version 20.0 software.

RESULTS

Biochemical study

There were no statistically significant difference between positive control group versus negative control, LD50 1/20, and LD50 1/40 groups, $P > 0.05$, whereas there was statistically significant difference between positive control group versus negative control, LD50 1/10, $P \leq 0.05$ (Table 1).

Studied groups	Weight (gm)	<i>P-Value*</i>	
	Mean±SD		
Positive control, N=15	252.3±2.82	p>0.05	
Negative control, N=10	248.3±1.36		
LD50 1/40, N=25	244.27±2.49	P<0.05	
LD50 1/20, N=25	241.32±1.67	p>0.05	
LD50 1/10, N=25	232.3±1.03	p>0.05	
<i>P-Value**</i> Among all groups		P<0.05	

Table 1: comparison of body weight of positive control group versus negative control and three BPA administered groups after 3 month of BPA.

Concerning positive control and negative control groups, there were no statistical significant differences at baseline and after 3 months of treatment. Whereas there were statistical significant differences among the 3 administered BPA groups between baseline and after three months of BPA administration (Fig.1).

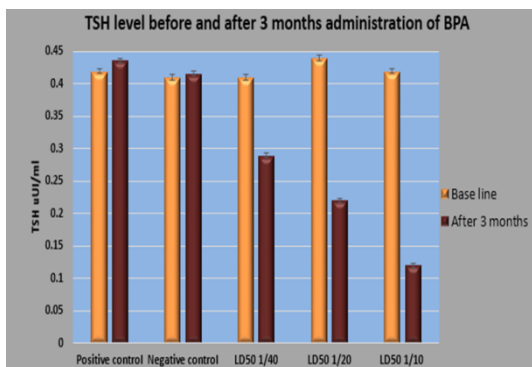


Fig. 1: comparison of serum TSH (nmol/L) before and after 3 months administration of the studied groups.

Concerning positive control and negative control groups there were no statistical significant differences at baseline and after 3 months of treatment, whereas there were statistical significant differences among the 3 administered BPA groups between baseline and after three months of BPA administration (Fig.2).

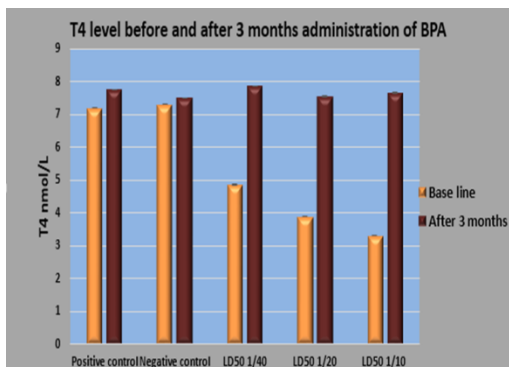


Fig. 2: comparison of serum T4 (nmol/L) before and after 3 months administration of the studied groups.

Histopathological results:

Thyroid

Group III (Bisphenol A treated group 1/40):

Bisphenol-treated group stained with H and E showed loss of normal thyroid architecture. The acini showed irregular shape and size with microcystic follicles with absent and scanty amount of colloid and some of the follicles appeared degenerated (Fig.3).

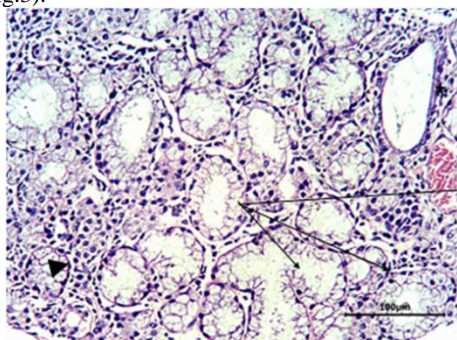


Fig. 3: a section in the thyroid gland of a control (group) rat showing follicles of various sizes (stars). Its walls are lined by follicular cells. Hand E, X40

Group IV (Bisphenol A treated group1/20):

Bisphenol-treated group stained with H and E showed follicular loss of normal architecture with lymphocytic inflammatory infiltrate. Some appeared degenerated, others appeared with exfoliated desquamated cells in the lumen and some appeared fused (Fig.4).

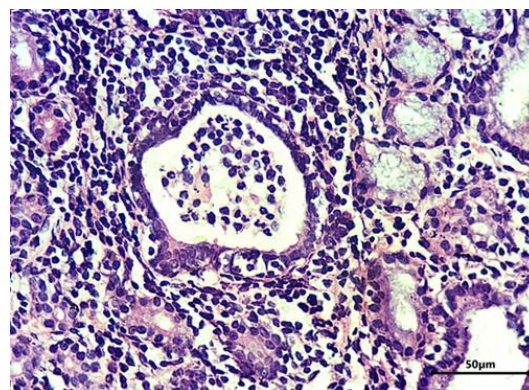


Fig. 4: a section in the thyroid gland of a control (group) rat showing of showing follicular loss of normal architecture with lymphocytic inflammatory infiltrate. H and E, X40

Group V (Bisphenol A treated group 1/10):

Bisphenol-treated group stained with H and E showed follicular loss of normal architecture, Extensive lymphocytic infiltrate and edema. The acini showed clearing of follicular cells and condensed chromatin with increased vascularity (Fig.5).

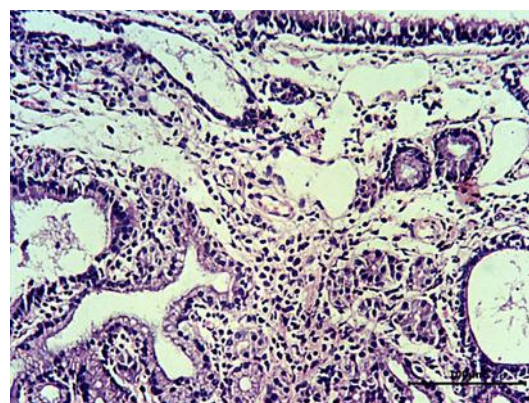


Fig. 5: a section in the thyroid gland of a control (group) rat showing of showing follicular loss of normal architecture with lymphocytic inflammatory infiltrate. H and E, X40.

Pituitary :

Group III (Bisphenol A treated group):

The pituitary showed hyperplasia of acidophil cells (Fig.6).

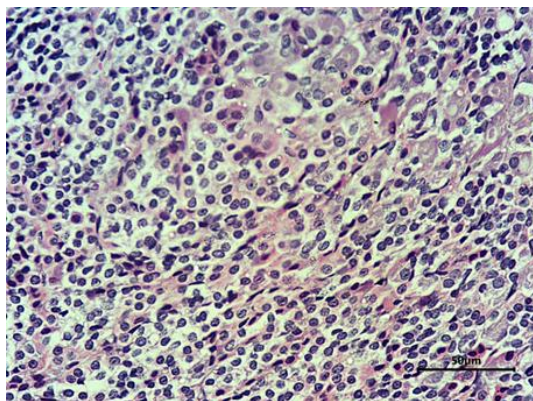


Fig. 6: a section in the Pituitary gland showed hyperplasia of acidophilic cells (thick black arrow) H and E, X40 .

Group IV (Bisphenol A treated group):

The pituitary showing marked degeneration mostly of basophilic cells with clearing and lymphocytic inflammatory infiltrate, increased vascularity, chromatin condensation (Fig.7).

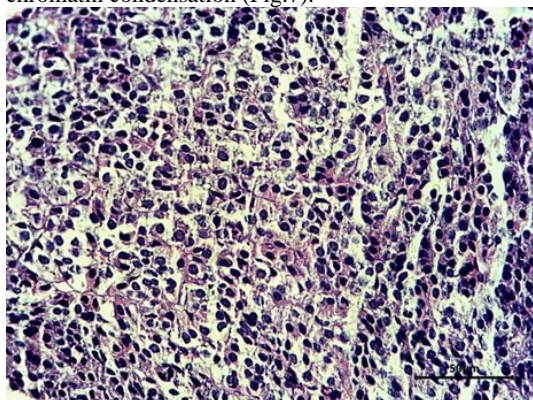


Fig. 7: a section in the Pituitary gland showed marked degeneration of basophilic and acidophils with clearing and lymphocytic inflammatory infiltrate, H and E X200.

Group V (Bisphenol A treated group):

The pituitary showing edema, necrosis, condensed chromatin (Fig.8).

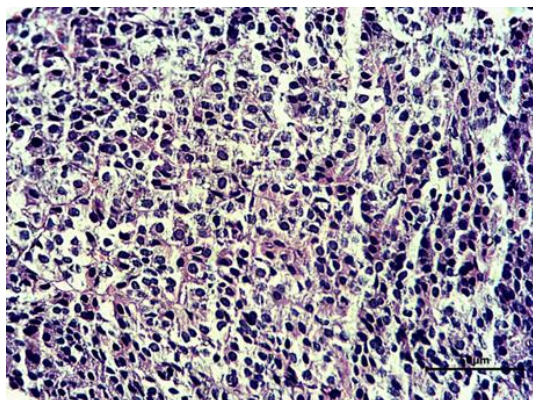


Fig. 8: a section in the Pituitary gland showed Oedema, apoptosis (black arrow head) condensed chromatin and increased vascularity (red arrow), H and E X20

DISCUSSION

BPA is a common endocrine-disrupting material, and its estrogenic activity was reported in the initial stages of its usage (1960s). In the context of its major use and serious side effects on human health, particularly on reproduction, the usage of BPA was controlled. The United States Environmental Protection Agency has established a reference dosage of 50µg/kg/day. In addition, the European Food Safety Authority has set a temporary tolerable daily intake of 4µg/kg/day.⁷

Of note, BPA was prohibited from baby bottles in several nations. Since worries about human health, regulations restricting BPA utilization have increased, the use of the remaining bisphenols as BPA substitutes has become more common. In recent years, researches on BPA have increased, demonstrating that BPA has other endocrine-disturbance features together with its estrogenic action.⁸

As regards serum T3, the current study demonstrated that there were no significant differences among all studied groups in terms of T3 level before BPA administration, while there were highly statistically significant reductions after 3 months of the studied groups after administration of BPA ($P<0.001$). In addition, there was a significant negative association between BPA and serum T3.

This came in accordance with Mohamed and Rateb, who demonstrated that, statistical analysis of T3 and serum level in bisphenol-treated group revealed T3 decrease in this group which was demonstrated to be highly significant ($P<0.001$) in comparison with the control group.⁹

Moreover, Manal and Ibrahim, demonstrated that, a significant reduction of T3 was recorded compared to the control and such change was reversible after stoppage of BPA exposure.¹⁰

As regards serum T4, the current study demonstrated that, there were no significant differences among all studied groups as regards T4 level before BPA administration, while there were highly statistically significant reductions after 3 months of the studied groups after administration of BPA ($P<0.001$). In addition, there was a significant negative correlation between BPA and serum T4.

In accordance, Alkalby demonstrated that, there was a significant ($P\leq 0.05$) reduction in serum levels of T4 in (50, 100 and 200) mg/kg bw BPA-treated groups in comparison with the control group.¹¹

As regards pituitary function in terms of TSH, the current study displayed that there were no significant differences among all studied groups as regards TSH level before BPA administration, while there were highly statistically significant reductions after 3 months of the studied groups after administration of BPA ($P<0.001$). In addition, there was a significant negative correlation between BPA and serum TSH.

An important note has to be considered, under normal physiological conditions reduction in T4 and T3 levels are usually associated with marked elevation in TSH level, thus Xenobiotic chemical induces a reduction in circulating levels of T4 with a subsequent increase in serum TSH.¹²

As regard histopathological changes the present study demonstrated that bisphenol-treated group stained with H and E showed loss of normal thyroid architecture with lymphocytic inflammatory infiltrate and edema.

In agreement with, Alkalby study who reported that, pathological alterations were detected in thyroid glands of male rats with various BPA dosages. Microscopic examination of thyroid gland of control group demonstrated normal structure of thyroid follicles of various sizes, whereas the thyroid glands of adult male rats treated with 50,100 and 200mg/kg/bw daily of BPA demonstrated thyroid follicles with vacuolated colloid and thickening of Parafollicular cells of different sizes.¹¹

Manal and Ibrahim, study showed that, BPA treated group demonstrated vacuolated follicular cells, exfoliation of epithelial cells within the colloid and congested capillaries in the interfollicular spaces. Significant reduction of colloidal PAS reaction and the Bcl2 immunoreaction with increase of collagen fibers amount of were noticed.¹⁰

CONCLUSION

The current study demonstrated that, BPA exposure seemed to have potential toxic effects on thyroid as well as pituitary functions in terms of biochemical as well as histopathological levels.

REFERENCES

1. Wang F, Hua J, Chen M, et al. High urinary bisphenol A concentrations in workers and possible laboratory abnormalities. *Occupational and Environmental Medicine*. 2012;69(9):679-84.
2. Geens T, Neels H and Covaci A. Distribution of bisphenol-A, triclosan and n-nonylphenol in human adipose tissue, liver and brain. *Chemosphere*. 2012;87(7):796-802.
3. Michałowicz J. Bisphenol A – Sources, toxicity and biotransformation. *Environmental Toxicology and Pharmacology*. 2014;37(2):738-58.
4. Komada M, Itoh S, Kawachi K, et al. Newborn mice exposed prenatally to bisphenol A show hyperactivity and defective neocortical development. *Toxicology*. 2014;323:51-60.
5. Harley KG, Gunier RB, Kogut K, et al. Prenatal and early childhood bisphenol A concentrations and behavior in school-aged children. *Environ Res*. 2013;126:43-50.
6. Preethi S, Sandhya K, Lebonah DE, et al. Toxicity of Bisphenol a on Humans: A Review. *International Letters of Natural Sciences*. 2014;27:32-46.
7. Gore AC, Chappell VA, Fenton SE, et al. Executive Summary to EDC-2: The Endocrine Society's Second Scientific Statement on Endocrine-Disrupting Chemicals. *Endocr Rev*. 2015;36(6):593-602.
8. Kim MJ and Park YJ. Bisphenols and Thyroid Hormone. *Endocrinol Metab (Seoul)*. 2019;34(4):340-8.
9. Mohamed H and Rateb A. Histological and Biochemical Study on the Toxic Effects of Bisphenol A on the Thyroid Gland of Adult Male Albino Rats and the Possible Protection by Selenium. *Egyptian Journal of Histology*. 2019;42(3):667-85.
10. Manal, M. Morsy and Ibrahim, H. Ibrahim. Hazards of Bisphenol A on the Thyroid Gland of Adult Male Albino Rats and Possibility of Recovery after its Withdrawal. *The Medical Journal of Cairo University*, 2019, 87.September: 2945-2953.
11. M. A. Alkalby J. Effect of bisphenol a on thyroid, liver and testicular functions in adult male rats. *Basrah Journal of Veterinary Research*. 2015;14(1):187-206.
12. Miller MD, Crofton KM, Rice DC, et al. Thyroid-disrupting chemicals: interpreting upstream biomarkers of adverse outcomes. *Environmental health perspectives*. 2009;117(7):1033-41.