

Comparative Study on The Hepato-Protective Effect of Carvedilol and Nebivolol in Carbon Tetrachloride-Induced Liver Fibrosis in Normotensive and Hypertensive Albino Rats

Ali Foli Abd El-salam*, Ahmed M. M. El-Sherbiny, Ali A. El-Salam A. Attia, Ramadan Hassan Ibrahim Thabet, Sherief Motwie Abdelfadeel

Department of Pharmacology, Faculty of Medicine, Al-Azhar University (Assiut), Egypt

*Corresponding author: Ali Foli Abd El-salam, Mobile: (+20) 01015151344, E-Mail: alifoli361987@yahoo.com

ABSTRACT

Background: Liver fibrosis is one of the main complications of chronic liver disease and is the main reason for increased mortality in affected patients. Fibrosis is characterized by excess deposition of extracellular matrix components including different collagens and non-collagenous proteins such as laminin, fibronectin and undulin.

Objective: This study aimed to: (1) Evaluate the possible hepatoprotective effect of nebivolol and carvedilol on carbon tetrachloride (CCl₄)-induced liver fibrosis. (2) Compare between hepatoprotective effect of nebivolol and carvedilol on CCl₄-induced liver fibrosis on normotensive and hypertensive rats.

Materials and Methods: This study was conducted on 110 male albino rats. Animals were obtained from the animal house of Faculty of Medicine, Assiut University. Their weight ranged between 160-200 grams each at the beginning of the experiment. Rats were housed in 11 groups with 10 rats each in clean capacious macrolane cages under standard laboratory conditions including good aerated room with suitable temperature (25 ± 5°C) and maintained at good light. Standard rodent food and water were available ad libitum.

Results: Subcutaneous injection of CCl₄ for 8 weeks caused hepatic pathological damage and significantly increased the levels of serum AST, ALT, ALP, hepatic malondialdehyde and hydroxyproline content. Moreover, it decreased the activities of superoxide dismutase and glutathione. Treatment with silymarin, carvedilol and nebivolol decreased significantly the AST, ALT, and ALP levels in plasma, MDA and hydroxyproline in liver tissues, and increased the activities of SOD and glutathione in liver tissue.

Conclusion: The biochemical and histopathological changes induced by administration of CCl₄ were improved under the effect of the used drugs in variable degrees. The most efficient drug was silymarin followed by carvedilol then nebivolol.

Keywords: Hypertensive albino rats, Carbon tetrachloride, Liver fibrosis, Silymarin, Carvedilol, Nebivolol.

INTRODUCTION

In Egypt, hepatic fibrosis and subsequently cirrhosis are believed to be a national problem. The Egyptian liver has been struggling with many causative agents leading to its damage; of which, both hepatitis C-infection and bilharzial-infection that are believed to be the two most outstanding causes of liver fibrosis/cirrhosis. The liver has metabolic, excretory and synthetic functions⁽¹⁾. A fibrotic/cirrhotic liver fails to perform such important physiological functions essential for human body. Up to date, patients suffering from hepatic fibrosis/cirrhosis are treated in such a way to compensate such impaired hepatic functions; treatment of complications; without receiving actual antifibrotic agents⁽²⁾.

Search for new, effective and safe antifibrotic agents is still in progress. Oxidative stress, resulting from an imbalance in generation of free radicals and antioxidant defense molecules, affects biological macromolecules causing their structural alterations that lead to cell damage and its death⁽³⁾. Oxidative stress is considered to be a major factor in pathogenesis of a variety of liver diseases. In this regard, reduction of oxidative stress may be a good target for prevention and treatment of hepatic fibrosis. Liver fibrosis is an important public health concern which can progress to cirrhosis, portal hypertension, and hepatocellular

carcinoma (HCC), leading to increased morbidity and mortality⁽⁴⁾.

Among all reasons inducing liver injury and fibrosis, toxic reagents are one that cannot be ignored. The causes of drug-induced liver injury are multifactorial, including toxic effects caused by reactive metabolites, reactive oxygen species, inflammatory reactions, and imbalances between cellular damage and protective responses, which will lead to inflammation, oxidative stress induction and fibrosis in the liver⁽⁵⁾.

This study aimed to: (1) Evaluate the possible hepatoprotective effect of nebivolol and carvedilol on CCl₄-induced liver fibrosis. (2) Compare between hepatoprotective effect of nebivolol and carvedilol on CCl₄-induced liver fibrosis on normotensive and hypertensive rats. (3) Search for possible mechanisms of hepatoprotective effect of nebivolol and carvedilol.

MATERIALS AND METHODS

1-Experimental Animals:

This study was conducted on 110 male albino rats. Animals were obtained from the animal house of Faculty of Medicine, Assiut University. Their weight ranged between 160-200 grams each at the beginning of the experiment. Rats were housed in 11 groups with 10 rats each in clean capacious macrolane cages under standard laboratory conditions including good aerated

room with suitable temperature ($25\pm 5^{\circ}\text{C}$) and maintained at good light. Standard rodent food and water were available ad libitum.

Ethical approval:

All the experimental procedures were carried out according to the principles and guidelines of the Ethics Committee of the Faculty of science, Assiut University, Egypt conformed to "Guide for the care and use of Laboratory Animals" for the use and welfare of experimental animals, published by the US National Institutes of Health (NIH publication No. 85–23, 1996).

2-Drugs and their sources:

- **CCL₄**: El-Naser Pharmaceuticals Chemical Company, Egypt
- **Silymarin**: Sigma, Aldrich.
- **Nebivolol**: was purchased from Marcyrl Pharmaceuticals Industries, Cairo, Egypt.
- **Carvedilol**: was purchased from Egyptian Int. Pharmaceutical Industries Co.
- **Saline**: El-Naser Pharmaceuticals Chemical Company, Egypt.
- **Phosphate buffered saline (PBS)**: Hi-media- Lab. Pvt. Inc., USA.
- **SOD kit**: Biodiagnostic, Egypt.
- **Glutathione reduced kit**: Biodiagnostic, Egypt.
- **Malondialdehyde**: Biochemical Enterprise, Italy
- **ALT, AST and ALP kit**: Vitro scient., Egypt.

I- Experimental Design:

Animal grouping and design of the work:

Animals in this study were randomly divided into eleven groups each contain ten rats:-

Group (1) Normal untreated rats that was given a vehicle (olive oil) 2 ml/kg body weight by intraperitoneal (i.p) twice a week for 8 weeks (control).

The rest of rats in all the following groups was treated with carbontetrachloride (CCl₄) (2ml/kg body weight, dissolved in olive oil [1:9(v/v)]) by intraperitoneal (i.p) injection twice a week for 8 weeks ⁽⁶⁾.

Group (2): (CCl₄intoxicated model): rats treated with carbontetrachloride (CCl₄) (2 ml/kg body weight, dissolved in olive oil [1:9(v/v)]) by intraperitoneal (i.p) injection twice a week for 8 weeks ⁽¹²⁾.

Group (3): Rats treated with carvedilol (10 mg/kg/day / kg orally) for 8 weeks ⁽⁷⁾.

Group (4): Rats treated with nebivolol (5mg| kg |day. orally) for 8 weeks ⁽⁸⁾.

Group (5): Rats treated silymarine (100 mg/kg/day, orally) for 8 weeks ⁽⁹⁾.

Group (6): Rats treated with silymarine and carvedilol. They received carvedilol (10 mg/kg/day / kg, orally) and Silymarine (100 mg/kg/day, orally) for 8 weeks.

Group (7): Rats treated with silymarine and nebivolol. They received nebivolol (5mg| kg |day orally) and Silymarine (100 mg/kg/day, orally) for 8 weeks.

Group (8): (hypertensive untreated): Rats treated by sub-cutaneous injection of dexamethasone (10 µg/kg/d) for 2 weeks to induce hypertension ⁽¹⁰⁾.

Group (9): Rats treated with dexamethasone and silymarine. They received sub-cutaneous injection of dexamethasone (10 µg/kg/day) for 2 weeks, and silymarine (100 mg/kg/day, orally) for 8 weeks.

Group (10): Rats treated with dexamethasone and nebivolol. They received sub-cutaneous injection of dexamethasone (10 µg/kg/d) for 2 weeks, nebivolol (5mg| kg |day orally) for 8 weeks.

Group (11): Rats treated with dexamethasone and carvedilol. They received sub-cutaneous injection of dexamethasone (10 µg/kg/d) for 2 weeks, carvedilol (10 mg/kg/day / kg, orally) for 8 weeks.

II- Procedures:

Blood Pressure measurement procedure (the last 4 groups)

Rats were trained daily for the measurement of blood pressure (B P) by indirect rat tail cuff method (Harvard apparatus 52-0338). The system is an electronic version of the traditional sphygmomanometer cuff method used to determine blood pressure by non-invasive technique. Rat was placed (9 AM) in maintenance cages for 2 hours. Afterward, systolic BP was measured in untrained animals. Once the rats were considered to be trained and not susceptible to stress from the tail-cuff procedure, systolic BP measurements were performed. And at eighth week, systolic BP was measured on 2 consecutive days at the same time of the day (11 AM).

Blood sampling:

Forty-eight hours after the last CCl₄ injection, rats were sacrificed and blood samples were collected, centrifuged and the serum from each animal was kept in Eppendorf tubes in the deep freezer at (-80°C) until analyzed for liver functions.

Preparation of liver homogenate:

After animals were sacrificed livers were immediately excised, rinsed from blood in ice cold saline and blotted dry by filter papers. Small piece of each liver was fixed in 10% phosphate-buffered formalin for histological examination. About 0.5 gm of each liver was homogenized by ultra-sonic homogenizer in 5 ml ice-cold phosphate buffered saline (PBS) to obtain ultimately 10% (w/v) whole liver homogenate ⁽¹¹⁾. The homogenate was centrifuged at 15000 rpm for 15 min and the resultant supernatant was stored at -20°C until used for determination of reduced glutathione (GSH), malondialdehyde (MDA), and superoxide dismutase (SOD) concentration.

Determination of liver function:

- Determination of alanine aminotransferase (ALT) (IU/L).
- Determination of aspartate aminotransferase (AST) (IU/L).
- Determination of alkaline phosphatase (ALP) (IU/L).

Determination of hepatic reduced glutathione mg/g tissue:

- Determination of hepatic superoxide dismutase U/g tissue.

- Determination of hepatic lipid peroxide (malondialdehyde) nmol/g tissue.
- Determination of hepatic hydroxyproline nmol/g tissue.

Statistical analysis

Statistical analysis was done using the computer program (SPSS). The quantitative data were presented in the form of mean ± standard error (S.E). Statistical analysis of the difference between groups was performed using one-way analysis of variance (ANOVA) followed by Tukey-Kramer test for differences between means. A value of P ≤ 0.05 was used as the limit for statistical significance.

RESULTS

Effect of silymarin, carvedilol, nebivolol, combination of (silymarin + carvedilol) and combination of (silymarin + nebivolol) treatments on serum ALT, AST and ALP in rats with CCl₄-induced fibrosis.

There was a significant decrease (P<0.05) in enzymes level (ALT, AST and ALP) in groups treated with silymarin, carvedilol and nebivolol compared to model (CCl₄) group.

Silymarin was the most effective treatment in reducing these markers when compared to other drugs (P<0.01). There was no significant difference between nebivolol and carvedilol (p>0.05) in reducing liver enzymes of rats with CCl₄-induced liver fibrosis.

There was a significant decrease (P<0.05) in ALT, AST and ALP enzymes by combination of (silymarin + carvedilol) and combination of silymarin + nebivolol treatment as compared to CCl₄ group.

There was significant difference between combination of silymarin + carvedilol-treated group and carvedilol-treated group alone in reducing liver enzymes of rats with CCl₄-induced liver fibrosis.

There was significant difference between combination of silymarin + nebivolol-treated group and nebivolol-treated group alone in reducing liver enzymes of rats with CCl₄-induced liver fibrosis (**Table 1**).

Table (1): Effect of silymarin, carvedilol, nebivolol, combination of silymarin + carvedilol and combination

of silymarin + nebivolol treatments on serum ALT, AST and ALP in rats with CCl₄-induced fibrosis

Group	ALT (U/L)	AST (U/L)	ALP (U/L)
Control	36±1.9	103.33±1.7	99±2.8
CCL4	355.76±40.47**	698.11±30.05**	921.11±49.7**
Silymarin	125.6±10.81##	362±16.9##	507±24.9##
Nebivolol	200.7±36.1#	495±45.92#	588±61.74#
Carvedilol	178±13.79 #	495±7.38#	598±11.66 #
Silymarin+ carvedilol	123±11.04 # Ø	360±20.91 # Ø	515±22.74# Ø
Silymarin+ nebivolol	132±12.04 # Ø	375±25.91 # Ø	520±26.74 # Ø

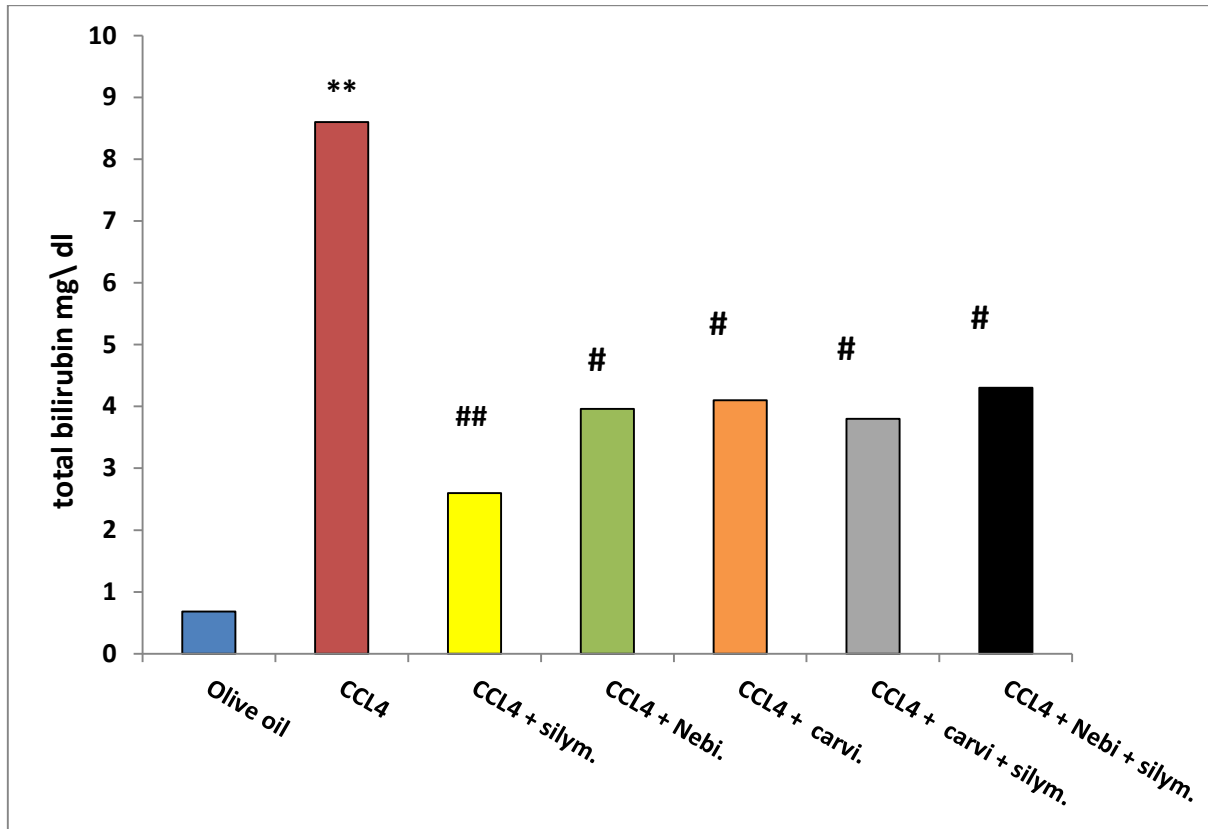
Data represent mean of 7-10 rats ± S.E ** significant (P<0.01) differences from control group.

Significant (P<0.05) differences from CCL4 group.

Ø significant (P<0.05) differences from nebivolol & carvedilol treated group

Effect of silymarin, carvedilol, nebivolol, combination of silymarin + carvedilol and combination of silymarin + nebivolol treatments on serum bilirubin in rats with CCl₄-induced fibrosis

There was highly significant decrease in serum bilirubin level (P<0.01) in silymarin-treated group compared to CCl₄ group. And there was significant decrease in serum bilirubin level (P<0.01) in carvedilol and nebivolol-treated groups compared to CCl₄ group. There was significant decrease in serum bilirubin level (P<0.01) in combination-treated groups compared to CCl₄ group. There was no significant difference between group treated with combination of silymarin+ carvedilol (P> 0.05) and carvedilol-treated group in reducing bilirubin level. And there is no significant difference between group treated with combination of silymarin+ nebivolol (P> 0.05) and nebivolol-treated group in reducing bilirubin level (Figure 1).



Data represent mean of 7-10 rats \pm S.E. **significant ($P < 0.01$) difference from control group
#significant ($P < 0.05$) difference from CCL4 group

Fig. (1): Effect of silymarin, carvedilol, nebigolol, combination of (silymarin + carvedilol) and combination of (silymarin + nebigolol) treatments on serum bilirubin in rats with CCl₄-induced fibrosis.

Effect of silymarin, carvedilol, nebigolol, combination of silymarin + carvedilol and combination of silymarin + nebigolol treatments on hepatic MDA, GSH and SOD in rats with CCl₄-induced liver fibrosis:

Highly significant decrease ($P < 0.01$) in MDA content in livers of the treated rats with silymarin, nebigolol and carvedilol and combined silymarin + carvedilol, silymarin + nebigolol when compared to fibrotic non treated group.

There was no significant difference between Silymarin and each of the other drugs separately ($P > 0.05$) for all of them in reducing the hepatic MDA content of rats with liver fibrosis.

There was significant decrease ($P < 0.05$) in MDA content in livers of the treated rats that were treated with combination of silymarin + carvedilol and both of carvedilol alone and silymarine alone.

There was significant decrease ($P < 0.05$) in MDA content in livers of the treated rats that were treated with combination of silymarin + nebigolol and both of nebigolol alone and silymarine alone.

There was highly significant increase in GSH level ($P < 0.01$) in rats with liver fibrosis co-treated with silymarin. Other drugs caused significant increase ($P < 0.05$) in GSH hepatic level of model group.

There was no significant difference ($P > 0.05$) in GSH content in livers of the treated rats with combination of silymarin + carvedilol and carvedilol alone and there was no significant difference ($P > 0.05$) in GSH content in livers of the treated rats with combination of silymarin + nebigolol and nebigolol alone.

As regards SOD, there was highly significantly increase ($P < 0.01$) in fibrotic rats treated with silymarin, nebigolol when compared to fibrotic (CCl₄) non-treated group. Carvedilol treatment led to significant increase ($P < 0.05$) in hepatic SOD compared to fibrotic (CCl₄) non-treated group.

There was no significant difference ($P > 0.05$) in SOD content in livers of the treated rats with combination of silymarin + carvedilol and carvedilol alone.

There was no significant difference ($P > 0.05$) in SOD content in livers of the treated rats with combination of silymarin + nebigolol and nebigolol alone (Table 3).

Table (3): Effect of silymarin, carvedilol, nebivolol, combination of silymarin + carvedilol and combination of silymarin + nebivolol treatments on hepatic MDA, GSH and SOD in rats with CCl₄-induced liver fibrosis

Group	MDA (nmol/gm/dry tissue)	GSH (mg/gm/dry tissue)	SOD (U/gm dry tissue)
Control	45.36±0.9	11.05±0.47	25.37±1.8
CCL4	97.93±2.66**	4.44±0.39**	10.78±0.90**
Silymarin	52.22±1.37##	8.1±0.36##	19.96±0.62##
Nebivolol	67.22±2.29#	7.32±0.37#	17.88±0.96##
Carvedilol	76.42±3.42#	6.37±0.32#	15.98±0.96#
Silymarin + carvedilol	48.22±1.32# Ø	7.52±0.33#	17.56±0.62#
Silymarin + nebivolol	54.22±1.35# Ø	8.43±0.38#	18.96±0.82#

Data represent mean of 7-10 rats ± S.E. ** significant (P<0.01) difference from control group # significant (P<0.05) difference from CCL4 group, Ø significant (P<0.05) differences from nebivolol & carvedilol treated groups.

Effect of silymarin, nebivolol, and carvedilol treatments on serum ALT, AST and ALP in hypertensive rats with CCl₄-induced fibrosis:

Highly significant decrease (P<0.01) was noticed in serum ALT, AST and ALP in rats treated by silymarin compared to non-treated hypertensive fibrotic rats. In carvedilol and nebivolol-treated groups significant decrease (P<0.05) was noticed in serum ALT, AST and ALP compared to non-treated hypertensive fibrotic rats (Table 5).

Table (5): Effect of silymarin, nebivolol, and carvedilol treatments on serum ALT, AST and ALP in hypertensive rats with CCl₄-induced fibrosis

Group	ALT (U/L)	AST (U/L)	ALP (U/L)
Control	36±1.9	103.33±1.7	99±2.8
Hypertensive fibrosed	375.76±40.47**	758.11±30.05**	980.11±49.7**
Hypertensive fibrosed +Silymarin	135.6±11.8##	382±18.9##	517±26.9##
Hypertensive fibrosed +nebivolol	220.76±5.8#	499±15.53#	598±19.8#
Hypertensive fibrosed +carvedilol	198±13.79#	505±7.58#	604±11.66#

Data represent mean of 7-10 rats ± S.E. **Highly significant (P<0.01) difference from control group, #significant (P<0.05) difference from hypertensive fibrosed group

Effect of silymarin, nebivolol, and carvedilol treatments on hepatic MDA, GSH and SOD in hypertensive rats with CCl₄-induced fibrosis:

There was highly significant increase (P<0.01) of MDA content in livers in hypertensive CCl₄-induced liver fibrosis group compared to control group

Treatment with silymarin, produced highly significant decrease (P<0.01) in MDA content in livers of rats with hypertensive liver fibrosis compared to hypertensive fibrotic non-treated group.

Treatment with nebivolol and carvedilol was produced significant decrease (P<0.05) in MDA content in livers of rats with hypertensive liver fibrosis compared to hypertensive fibrotic non-treated group.

There was highly significant decrease (P<0.01) in GSH level in hypertensive CCl₄-induced liver fibrosis group compared to control group.

Treatment with silymarin produced significant increase in GSH level (P<0.05) in rats with hypertensive liver fibrosis compared to hypertensive fibrotic non-treated group. Other drugs (nebivolol and carvedilol) caused no significant difference (P > 0.05) in GSH hepatic level compared to hypertensive fibrotic non-treated group. There was no significant difference in GSH level (P > 0.05) between Silymarin and both nebivolol and carvedilol-treated groups.

As regards SOD, there was highly significant decrease (P<0.01) in hepatic SOD in hypertensive CCl₄-induced liver fibrosis group compared to control group

There was significantly increase in hepatic SOD (P<0.05) in hypertensive fibrotic rats treated with silymarin, carvedilol and nebivolol compared to hypertensive fibrotic non-treated group. There was no statistically significant difference (P >0.05) between silymarin and both nebivolol and carvedilol treated groups (Table 7).

Table (7): Effect of silymarin, nebivolol, and carvedilol treatments on hepatic MDA, GSH and SOD in hypertensive rats with CCl₄-induced fibrosis

Group	MDA (nmol/gm/dry tissue)	GSH (mg/gm/dry tissue)	SOD (U/gm dry tissue)
Control	45.36±0.9	11.05±0.47	25.37±1.8
hypertensive fibrosed	98.93±2.66**	5.44±0.39**	10.78±0.90**
hypertensive fibrosed +Silymarin	58.32±1.77##	9.1±0.36#	19.96±0.62#
hypertensive fibrosed +nebivolol	77.42±2.39#	7.32±0.37	15.88±0.96#
hypertensive fibrosed + carvedilol	79.42±3.42#	6.37±0.32	14.98±0.96#

Data represent mean of 7-10 rats ± S.E. ** significant (P<0.01) difference from Control group

Significant (P<0.05) difference from hypertensive fibrosed group

Effect of silymarin, nebivolol, and carvedilol treatments on hepatic hydroxyproline in hypertensive rats with CCl₄-induced fibrosis

There was highly significant increase (P<0.01) in hydroxyproline content in hypertensive CCl₄-induced liver fibrosis group compared to control group

Treatment with silymarin, nebivolol and carvedilol produced highly significant decrease (P<0.01) in hydroxyproline content in rats with hypertensive fibrotic liver compared to hypertensive fibrotic non-treated group. There was a highly statistically significant difference (P < 0.05) between silymarin and both carvedilol and nebivolol groups (Figure 2).

** significant (P<0.01) difference from Control group

significant (P<0.05) difference from hypertensive rats with CCl₄-induced fibrosis group

Figure (2): Effect of silymarin, nebivolol, and carvedilol treatments on hepatic hydroxyproline in hypertensive rats with CCl₄-induced fibrosis

Effect of silymarin, nebivolol, and carvedilol treatments on systolic blood pressure in hypertensive rats with CCl₄-induced fibrosis:

Highly significant increase (P<0.01) was noticed in systolic blood pressure on group treated by CCl₄ + dexamethasone compared to control group.

Treatment with silymarin produced no significant difference in systolic blood pressure compared to hypertensive fibrosed non-treated group.

Highly significant decrease (P<0.01) was noticed in systolic blood pressure in groups treated by carvedilol and nebivolol compared to hypertensive fibrosed non-treated group. There was no significant difference in systolic blood pressure on group treated by carvedilol compared to group treated by nebivolol (Table 8).

Table (8): Effect of silymarin, nebivolol, and carvedilol treatments on systolic blood pressure in hypertensive rats with CCl₄-induced fibrosis

Group	Systolic blood pressure (mmhg)
Control	109 ± 2.98
Hypertensive fibrosed	189 ± 3.2 **
Hypertensive fibrosed +Silymarin	185 ± 3.2
Hypertensive fibrosed +nebivolol	155 ± 2.4##
Hypertensive fibrosed +carvidelol	152 ± 3.4##

Data represent mean of 7-10 rats ± S.E. ** highly significant (P<0.01) difference from Control group

highly significant (P<0.01) difference from hypertensive fibrosed group

DISCUSSION

In the present study, induction of liver fibrosis in Wistar male albino rats was done by injection with carbontetrachloride (CCl₄) (2 ml/kg body weight, dissolved in olive oil [1:9(v/v)] by intraperitoneal (i.p) injection twice a week for 8 weeks ⁽¹²⁾.

The results of the present study showed that the levels of ALT, AST ALP, and serum bilirubin level were increased in CCl₄-treated group as compared to the control group indicating the induction of liver injury. This is in agreement with **Reyes-Gordillo et al.** ⁽¹³⁾, who recorded a significant increase in liver enzymes (ALT, AST and ALP) post- CCl₄ administration. **Shankar et al.** ⁽¹⁴⁾ explained that serum enzymes elevation is due to the increase in hepatic cell membrane fluidity that led to enzyme leakage and release of large quantities into circulation. So they are considered the most sensitive markers of liver injury ⁽¹⁵⁾.

Our results showed that the level of MDA was increased in CCl₄-treated group. Our results are supported by **Lee et al.** ⁽¹⁶⁾ who reported that the rise of MDA levels in the liver is indicative of an enhanced peroxidation that causes tissue damage.

GSH is a major endogenous antioxidant which counterbalances free radical-mediated damage. It is well known that GSH is involved in the protection of normal cell structure and function by maintaining the redox homeostasis, quenching of free radicals and by participating in detoxification reactions ⁽¹⁷⁾. In the present study, there was a highly significant reduction of hepatic GSH content in CCl₄-treated group confirming the finding of **Srivastava and his colleagues** ⁽¹⁸⁾ who suggested that enhancement of lipid peroxidation is a consequence of depletion of GSH to certain critical levels. Insufficiency in non-enzymatic antioxidant GSH following CCl₄ intoxication could be the consequence of increased utilization for trapping free radicals. In addition, hepatic transulphuration pathway is impaired in fibrosis hindering the conversion of methionine to cysteine, which is necessary for GSH synthesis as described by **Chawla and his colleagues** ⁽¹⁹⁾. In consonance with our study, **Kim et al.** ⁽²⁰⁾ have reported depletion in GSH level in the liver of CCl₄ intoxicated rats.

In the present study, CCl₄-treated group exhibited a marked increase in content of ECM and displayed bundles of collagen surrounding the lobules, which resulted in a large fibrous septae and distorted tissue architecture, fatty changes, ballooning degeneration, cell necrosis and centrilobular inflammatory infiltrate. The collagen fibers in the present study extended and destroyed the architecture of liver samples. This is in coincidence with prior investigations of CCl₄ conducted by **Doh et al.** ⁽²¹⁾.

In the present work, CCl₄ contributed in pushing the cell towards “apoptosis”, affecting only individual cells, leaving adjacent cells intact. The condensed chromatin, fragmentation and shrinking of

nucleus were seen as evidence for apoptosis. This in agreement with **Doon and Cotter** ⁽²²⁾. They revealed that CCl₄ induced liver fibrosis, which produces cell body shrinkage and loss of contact to its neighboring cells, chromatin in nucleus condenses and migrates to the nuclear membrane, and finally the cell is fragmented into compact membrane-enclosed structures, called „apoptotic bodies“ which contain cytosol, condensed chromatin, and organelles. The apoptotic bodies are engulfed by macrophages and thus are removed from the tissue without causing an inflammatory response.

Our results revealed that the plasma level of ALT, AST and ALP was decreased in CCl₄ + silymarin-treated group. These results are in agreement with **Cacciapuoti et al.** ⁽²³⁾ who showed that the use of silymarin extract, silybum marianum, in 72 patients with non-alcoholic fatty liver disease on a restricted diet significantly reduced the levels of alanine aminotransferase (ALT) and aspartate aminotransferase (AST). **El-Lakkany et al.** ⁽²⁴⁾ stated that silymarin restored the elevated level of serum ALT in CCl₄-intoxicated rats by preventing liver damage through maintaining the integrity of the plasma membrane, thereby suppressing the leakage of enzymes. Similarly **Abdel-Salam et al.** ⁽²⁵⁾ reported that silymarin decreased leakage of hepatocellular enzymes ALT and AST into plasma, and lessened the development of liver necrosis and fibrosis caused by carbon tetrachloride (CCl₄).

In the present study, the hepatoprotective effect of silymarin was determined in CCl₄-induced liver cirrhosis of rats. In the CCl₄ with silymarin-treated group, total hepatic collagen contents were significantly lower than in the CCl₄-treated group especially at 8 and 12 weeks. Additionally histopathological findings of fibrosis/cirrhosis revealed a significant reduction in the CCl₄-treated group. Similar experiments by **Favari and** ⁽²⁶⁾ reported the reduction of lipid peroxidation, Na⁺, K⁺, and Ca²⁺-ATPase levels and increase of collagen content.

Moreover, our results showed that silymarin significantly decreased liver MDA contents. These results are in agreement with **Clichici et al.** ⁽²⁷⁾. This is due to that silymarin has antioxidant and scavenge free radicals (ROS) activities, thus protecting against oxidative stress. Furthermore, silibinin exhibits membrane protective properties and it may protect blood constituents from oxidative damage ⁽²⁸⁾. Also, this comes in agreement with **El-Maddawy and Gad** ⁽²⁹⁾ who reported that administration of silymarin to CCl₄-treated rats was significantly able to reduce the hepatic MDA.

In the present study, carvedilol co-treatment with CCl₄-treated group non-significantly counteracted the GSH depletion and significantly counteracted increase MDA level induced by CCl₄ that agrees with **Hamdy and El-demerdash** ⁽³⁰⁾. The carvedilol and silymarin co-treatment each alone or in combination efficiently ameliorated the CCl₄-induced

hepatotoxicity, which is indicated by restoration of disturbed hepatic function tests, with reduction of the elevated serum ALT, AST, ALP and BIL levels. In addition, it effectively restored the anti-oxidant activities of hepatic tissue, by elevating the reduced hepatic SOD activity and GSH level, along with its reduction of the elevated hepatic MDA. Subsequently, the hepatic collagen content was reduced that proved by reduction of hepatic hydroxyproline content and apparent preservation of normal hepatic architecture. Although silymarin treatment improved the previous parameters greatly, carvedilol treatment was superior to silymarin in improving MDA level. Yet, silymarin is better than carvedilol in reduction of the elevated serum AST level. Moreover, the combination of carvedilol and silymarin showed an upper hand in amelioration of the CCl₄-induced hepatotoxicity than each alone.

In this study we observed that treatment with **nebivolol** was found to produce a significant decrease in liver enzyme activities, bilirubin level compared to positive control (CCl₄ group). We also demonstrated that treatment with nebivolol significantly decreased MDA and increased GSH in hepatic tissue. Our observations are consistent with previous studies, which showed that nebivolol attenuates lipid peroxidation and enhances anti-oxidant capacity ⁽³¹⁾. A reasonable explanation is the direct free radical scavenging effect, antioxidant properties and the β-blocker effect of nebivolol ⁽³²⁾. Nebivolol has antioxidant properties and marked ameliorating effect on oxidative stress induced in different models of hepatic injury ⁽³³⁾. In current study, nebivolol reversed oxidative stress induced by CCl₄, which is evidenced by reduction in MDA and elevation of SOD activity. According to our study, nebivolol administration improved CCl₄-induced hepatotoxicity that is due to different mechanisms. Nebivolol could significantly decrease the increased blood pressure and preserve vascular endothelium so maintain normal blood supply, maintain the required oxygen supply to organs, and protect blood vessels from harmful effect of increasing blood pressure including vessel damage that increases oxidative stress, apoptosis and inflammation. Systemic increase in blood pressure is associated with portal hypertension that leads to liver damage. These finding are supported by **Sumer et al.** ⁽³⁴⁾. **Sumer et al.** ⁽³⁴⁾ explained the protective effect of nebivolol in liver that NEB is metabolized in the liver and its metabolites increase NO production in vascular endothelium leading to vasodilatation.

In our study, nebivolol and carvedilol demonstrated similar efficacy on systolic blood pressure reduction. This result is in agreement with several comparative studies that found a similar reduction in 24-hour ambulatory blood pressure with nebivolol compared to other beta blockers, such as atenolol, and drugs of other groups, such as lisinopril, enalapril, and nifedipine ⁽³⁵⁾. This result is in line with its vasodilator properties related to nitric oxide production at the endothelial level.

Our results showed that carvedilol and nebivolol decreased serum ALT, AST, ALP and serum bilirubin level compared to non-treated hypertensive fibrotic rats. Our results show that treatment with nebivolol and carvedilol produced significant decrease in MDA content in livers of rats with hypertensive liver fibrosis compared to hypertensive fibrotic non-treated group. There was significantly increase in hepatic SOD in hypertensive fibrotic rats treated with silymarin, carvedilol and nebivolol compared to hypertensive fibrotic non-treated group.

CONCLUSION

The biochemical and histopathological changes induced by administration of CCl₄ were improved under the effect of the used drugs in variable degrees. The most efficient drug was silymarin followed by carvedilol then nebivolol. It is possibly due to their antioxidant effect, free radical scavenging properties and the reduction of oxidant-dependent activation and proliferation of HSCs. So these antihypertensive can be a promising drugs candidate for ameliorating liver fibrosis.

Financial support and sponsorship: Nil.

Conflict of interest: Nil.

REFERENCES

1. **El-Zanaty F, Way A (2009):** Egypt demographic and health survey, 2008. Ministry of Health and Population. <https://dhsprogram.com/pubs/pdf/fr220/fr220.pdf>
2. **Ismail M, Pinzani M (2009):** Reversal of liver fibrosis. *Saudi Journal of Gastroenterology*, 15 (1): 72-78.
3. **Parola M, Robino G (2001):** Oxidative stress-related molecules and liver fibrosis. *Journal of Hepatology*, 35 (2): 297-306.
4. **Enomoto M, Morikawa H, Tamori A et al. (2014):** Noninvasive assessment of liver fibrosis in patients with chronic hepatitis B. *World Journal of Gastroenterology*, 20 (34): 12031-36.
5. **Xuan J, Chen S, Ning B et al. (2016):** Development of HepG2-derived cells expressing cytochrome P450s for assessing metabolism-associated drug-induced liver toxicity. *Chemico-Biological Interactions*, 255: 63-73.
6. **Ohyama T, Sato K, Kishimoto K et al. (2012):** Azelnidipine is a calcium blocker that attenuates liver fibrosis and may increase antioxidant defence. *British Journal of Pharmacology*, 165 (4): 1173-1187.
7. **Massart P, Donckier J, Kyselovic J et al. (1999):** Carvedilol and lacidipine prevent cardiac hypertrophy and endothelin-1 gene overexpression after aortic banding. *Hypertension*, 34 (6): 1197-1201.
8. **Nada S, Omara E, Abdel-Salam O et al. (2010):** Mushroom insoluble polysaccharides prevent carbon tetrachloride-induced hepatotoxicity in rat. *Food and Chemical Toxicology*, 48 (11): 3184-3188.
9. **Shaker E, Mahmoud H, Mnaa S (2010):** Silymarin, the antioxidant component and *Silybum marianum* extracts prevent liver damage. *Food and Chemical Toxicology*, 48 (3): 803-806.
10. **Zhang Y, Croft K, Mori T et al. (2004):** The antioxidant tempol prevents and partially reverses dexamethasone-induced hypertension in the rat. *American Journal of Hypertension*, 17 (3): 260-265.
11. **Fahmy S, Hamdi S (2011):** Curative effect of the Egyptian marine *Erugosquilla massavensis* extract on carbon tetrachloride-induced oxidative stress in rat liver and erythrocytes. *European Review for Medical and Pharmacological Sciences*, 15 (3): 303-312.
12. **Onalan A, Tuncal S, Kilicoglu S et al. (2016):** Effect of silymarin on oxidative stress and liver histopathology in experimental obstructive jaundice model. *Acta Cirurgica Brasileira*, 31 (12): 801-806.
13. **Reyes-Gordillo K, Segovia J, Shibayama M et al. (2007):** Curcumin protects against acute liver damage in the rat by inhibiting NF- κ B, proinflammatory cytokines production and oxidative stress. *Biochimica et Biophysica Acta (BBA)-General Subjects*, 1770 (6): 989-996.
14. **Shankar N, Manavalan R, Venkappayya D et al. (2008):** Hepatoprotective and antioxidant effects of *Commiphora berryi* (Arn) Engl bark extract against CCl₄-induced oxidative damage in rats. *Food and Chemical Toxicology*, 46 (9): 3182-3185.
15. **Motawi T, Hamed M, Shabana M et al. (2011):** Zingiber officinale acts as a nutraceutical agent against liver fibrosis. *Nutrition & Metabolism*, 8 (1): 40-46.
16. **Lee K, Choi J, Khanal T et al. (2008):** Protective effect of caffeic acid phenethyl ester against carbon tetrachloride-induced hepatotoxicity in mice. *Toxicology*, 248 (1): 18-24.
17. **Pushpakiran G, Mahalakshmi K, Anuradha C (2011):** Protective effects of taurine on glutathione and glutathione-dependent enzymes in ethanol-fed rats. *Pharmazie*, 59 (11): 869-872.
18. **Srivastava S, Das M, Seth P (1983):** Enhancement of lipid peroxidation in rat liver on acute exposure to styrene and acrylamide a consequence of glutathione depletion. *Chem Biol Interact*, 45 (3): 373-380.
19. **Chawla R, Lewis F, Kutner H et al. (1984):** Plasma cysteine, cystine, and glutathione in cirrhosis. *Gastroenterol.*, 87: 770-775.
20. **Kim H, Kim J, Choi J et al. (2010):** Hepatoprotective effect of pinoreosinol on carbon tetrachloride-induced hepatic damage in mice. *J Pharmacol Sci.*, 112 (1): 105-112.
21. **Doh K, Jung H, Moon I et al. (2008):** Prevention of CCl₄-induced liver cirrhosis by ribon antisense to transforming growth factor- β 1. *International Journal of Molecular Medicine*, 21 (1): 33-39.
22. **Doonan F, Cotter T (2008):** Morphological assessment of apoptosis. *Methods*, 44 (3): 200-204.
23. **Cacciapuoti F, Scognamiglio A, Palumbo R et al. (2013):** Silymarin in non-alcoholic fatty liver disease. *World Journal of Hepatology*, 5 (3): 109-113.
24. **El-Lakkany N, Hammam O, El-Maadawy W et al. (2012):** Anti-inflammatory/ anti-fibrotic effects of the hepatoprotective silymarin and the schistosomicide praziquantel against *Schistosoma mansoni*-induced liver fibrosis. *Parasites & Vectors*, 5 (1): 5-9.
25. **Abdel-Salam O, Sleem A, Morsy F (2007):** Effects of biphenyldimethyl-dicarboxylate administration alone or combined with silymarin in the CCl₄ model of liver fibrosis in rats. *The Scientific World Journal*, 7: 1242-1255.

26. **Favari L, Perez-Alvarez V (1997):** Comparative effects of colchicine and silymarin on CCl₄-chronic liver damage in rats. *Arch Med Res.*, 28: 11-17
27. **Clichici S, Olteanu D, Nagy A et al. (2015):** Silymarin inhibits the progression of fibrosis in the early stages of liver injury in CCl₄-treated rats. *Journal of Medicinal Food*, 18(3): 290-298.
28. **Ajay K, Deepa I, Purnima A et al. (2009):** Silymarin: a comprehensive review. *Pharmacognosy Reviews*, 3 (5): 116-124.
29. **El-Maddawy Z, Gad S (2012):** Hepato-renal protection of silymarin in comparison with vitamin E in rats. *Glob J Pharmacol.*, 6 (3): 236-244.
30. **Hamdy N, El-Demerdash E (2012):** New therapeutic aspect for carvedilol: antifibrotic effects of carvedilol in chronic carbon tetrachloride-induced liver damage. *Toxicology and Applied Pharmacology*, 261 (3): 292-299.
31. **Filomena N, Mancini F, Balestrieri M et al. (2008):** Therapeutic dose of nebivolol, a nitric oxide-releasing β -blocker, reduces atherosclerosis in cholesterol-fed rabbits. *Nitric Oxide*, 19: 57-63.
32. **Matthias A, Brandes R, Hortmann M et al. (2006):** Nebivolol inhibits superoxide formation by NADPH oxidase and endothelial dysfunction in angiotensin II-treated rats. *Hypertension*, 48 (4): 677-684.
33. **Ulger B, Erbis H, Turkcu G et al. (2015):** Nebivolol ameliorates hepatic ischemia/ reperfusion injury on liver but not on distant organs. *J Invest Surg.*, 28: 245-252.
34. **Sumer F, Colakoglu M, Ozdemir Y et al. (2017):** Effect of nebivolol on liver regeneration in an experimental 70% partial hepatectomy model. *Asian J Surg.*, 40: 375-379.
35. **McNeely W, Goa K (1999):** Nebivolol in the management of essential hypertension. *Drugs*, 57 (4): 633-651.