

A COMPARATIVE STUDY BETWEEN IMMEDIATE FUNCTIONAL AND NON FUNCTIONAL LOADING OF DENTAL IMPLANTS IN THE POSTERIOR ALVEOLAR MANDIBULAR REGION (A RANDOMIZED CLINICAL TRIAL)

Aly A.Ramadan ^{1*} BDS, Samraa A. El Sheikh ² PhD, Marwa G. Noureldin ³ PhD.

ABSTRACT

INTRODUCTION: Patients increasingly demand immediate prosthetic rehabilitation. In response to their demands Not only are implants placed immediately, but often loaded immediately within 72 hours. Therefore, the question arises whether implants should be loaded instantly in functional or non-functional occlusion.

AIM: Is to compare between immediate functional and non-functional loaded implants in the posterior mandibular region by using cone beam computed tomography to evaluate changes in bone density and crestal bone loss.

MATERIALS AND METHODS: In this study 16 patients with partially edentulous mandibles were divided randomly into two groups, all received implants that were immediately loaded either functionally (Group A) or nonfunctionally (Group B). Standardized CBCT were made at immediate postsurgical and 4 months postsurgical to evaluate changes in crestal bone loss and bone density.

RESULTS: Both groups were successful with no implant failure. Mean crestal bone loss for group A and group B was (0.29 ± 0.07) and (0.32 ± 0.14) respectively ($P = 0.553$). Mean values of bone density for group A and group B were (540.1 ± 90.06) and (515.1 ± 125.4) respectively ($P = 0.676$).

CONCLUSION: Both immediate functional and nonfunctional loading of dental implants are successful treatment options and have the same effect on crestal bone loss and bone density.

KEYWORDS: Immediate functional loading, immediate nonfunctional loading, posterior mandible.

RUNNING TITLE: Immediate functional and non-functional loading of implants in posterior mandible.

¹ Bachelor of Dental Surgery, Faculty of Dentistry, Alexandria University, Alexandria, Egypt.

² Professor of Oral and Maxillofacial Surgery Alexandria University, Alexandria, Egypt.

³ Lecturer at the Oral and Maxillofacial Surgery Department, Faculty of Dentistry, Alexandria University, Alexandria, Egypt.

**corresponding author:*

E-Mail: dr.al.y.ramadan@gmail.com

INTRODUCTION

Today, dental implants are a safe and effective option for the recovery of single tooth loss, documented in scientific literature in the short (1), medium (2) and long term (3).

The function and esthetic performance of the prosthetic implant restoration is considered the main key of success of dental implants in the oral cavity (4,5).

Supported by commercial merchandising from dental implant manufacturers, patients increasingly demand immediate prosthetic rehabilitation after implant insertion. Eventually, the dentist is compelled to decrease the healing time of restoring a lost tooth or teeth to meet the patients mentioned needs (6,7). That's why immediate placement (6,8,9) and immediate loading are essential treatment skills for the dentist and available options for the patient (6, 10, 11). An immediately placed functional dental implant in conjunction with a provisional restoration placed within 48 to 72 hours after surgery delivers a significant reduction in treatment time (6,9-11).

In immediate functional loading, the prosthetic restoration, transmits physiological occlusal loads to the

fixture part of the implant generated by the muscular apparatus (e.g., tongue and cheeks) (6,9,12).

However, in immediate nonfunctional loading, the prosthesis is disconnected from occlusal forces and only chewing forces are introduced to the healing bone-implant interface to provide a better immobilization compared to full functional loading (12-14). Histological and histomorphometric studies have shown that immediate loaded implants osseointegrate as good as implants with prosthetic loading only after full osseointegration, provided primary stability is sufficient for immobilization of the implant throughout the healing time which is the same for loaded and not loaded implants by the evolutionary biological principles of bone-healing and osseointegration of any biocompatible foreign body. Moreover, it was found that the bone formation process around dental implants is more activated in case of immediate loading leading to a stable fixture offering an absolute final restoration (15,16).

Since the benefits of instant loading are well recognized in the literature (6, 9-11) and in different clinical

settings, this protocol can now be considered reliable and effective (6,9-11,13,17,18), the safe achievement of primary stability (i.e. mechanical stabilization of the fixture at the time of positioning) as well as secondary stability (i.e. biological stabilization of the fixture during the first healing period) as fundamental and evolutionary biological principles of bone-healing is mandatory in immediate loading procedures to prevent failure (19-21). Lacking primary stability of the inserted dental implant will lead the forces transmitted from occlusion and tissues through the prosthesis to cause mobility, failure of osteointegration and loss of fixture as described in literature (4,6,9-11,17-20). In fact, failure of osteointegration of a dental implant is considered to be caused by excess of micromotions at the bone implant interface (13,19,20,22,23).

To our knowledge the evidence in the literature on the quantitative assessment of crestal bone loss around the functionally and non-functionally loaded implants was found to be deficient. Moreover, it is essential to evaluate them on radiographic bases using cone beam computed tomography (CBCT) (24, 25).

The aim of the study was to investigate if immediately functional loaded implants and immediately non-functional loaded implants in posterior mandible might reveal any radiographic differences in CBCT-investigation regarding bone density and crestal bone loss.

MATERIALS AND METHODS

This study has been accepted by the Ethics research board, Faculty of Dentistry, Alexandria University. The study has been registered at clinicaltrials.gov with ID number: NCT04521530

Study design: two-arm randomized clinical trial with equal allocation ratio 1:1.

Setting and location: sixteen Patients with missing posterior mandibular tooth or teeth with molar alveolar ridge with length not less than 10 mm and width not less than 4 mm, patients were chosen from the ambulatory clinic of the Oral and Maxillofacial Surgery Department, Faculty of Dentistry, Alexandria University and the study was carried out in the same department.

Sample size estimation: A minimum total sample size of 16 patients was needed to detect an assumed average difference of bone functional healing compared to the null hypothesis at 95% confidence level and at 80% power using z test. Drop out estimate was calculated to avoid sampling errors according to oxford statistical standards to be +2 added to each estimated sample group (about 20 % of the overall estimated sample size) (pass program version 20)

Inclusion criteria: All candidates were adult patients aged (20–40) years old of both genders with missing posterior tooth or teeth, indicated for implant placement and residual alveolar ridge of minimum ten mm high and four mm wide.

Exclusion criteria: Systemic diseases that will contraindicate the surgery (ex: osteoporosis, uncontrolled diabetes) (26), poor oral hygiene assessed by The

Simplified Oral Hygiene Index (27) and parafunctional habits.

Randomization technique and allocation: A convenient sample complying with the inclusion and exclusion criteria was allocated from the ambulatory clinic of Oral and Maxillofacial Surgery Department Faculty of Dentistry Alexandria University.

Patients were allocated randomly by using computerized method (www.randomizer.org) into two equal groups:

Group (A): Consisted of eight patients rehabilitated with immediate functionally loaded implants.

Group (B): Consisted of eight patients rehabilitated with immediate non-functionally loaded implants.

Implants:

The implant system the clinical trial was two stage titanium dental implants (BioInfinity, Manufactured by Avrupa Implant / Istanbul-Turkey) is characterized by having their surface roughened with biphasic calcium phosphate, abutment-implant connection is provided with 11-degree conical hexagonal interlocking, hybrid design with an ideal combination of conical and cylindrical forms, platform switch, mini threads, reverse buttress thread design and decreased thread pitch in the neck region.

A surgical kit with length marked drills, counter sink drills, graded torque wrench (>35Ncm), manual driver and screw driver were used.

Clinical trial protocol - timeline

Presurgical phase

1- Patient assessment

Detailed anamnesis and intraoral examination were done to determine the oral hygiene of the patients using The Simplified Oral Hygiene Index (27).

2- Radiographic examination

A CBCT - investigation was performed for all candidates presurgical to assess the molar alveolar bone in terms of height and width according to the inclusion criteria. (Figure 1)

3-Presurgical therapy

It included scaling and root planning as it was directed towards obtaining optimal oral hygiene for the patient.

Surgical protocol

All candidates underwent surgery local anesthesia using Articaine 40.00 mg hydrochloride, Epinephrine 0.01 mg (Artinibsa, manufactured in Spain), Crestal incision was performed according to each case by using blade number 15 and reflection using periosteal elevator was done to expose the crest of the alveolar ridge. Drilling was done for implant placement according to manufacturer requirements, with drilling sequence matching the size of implant to be placed.

Implants were placed with minimum of 35 Newton centimeter insertion torque value with the graded torque wrench (21). Then abutments were immediately placed their height adjusted and Suturing was done using 3/0 black silk sutures.

Temporary crowns in functional occlusion were cemented to group (A) while group (B) received non-functional temporary crowns with no occlusal contact with

opposing tooth or teeth, both immediately after surgery. (Figure 2)

Postsurgical protocol

The patients were given postoperative instructions, including oral hygiene instructions.

Postoperative medications including:

Amoxicillin clavulanate (Augmentin, Manufactured by GlaxoSmithKline Group) 1gm: 1 tablet every 12 hours for 5 days.

Non-steroidal anti-inflammatory drug Ibuprofen (Brufen, Kahira Pharm. & Chem. Ind. Co., under license from: Abbott Laboratories) 600 mg: 1 tablet 3 times daily after meals for 4 days.

Clinical evaluation

All patients were evaluated for the presence of pain using Visual Analogue Scale (VAS) (28) and any other complication was recorded.

Radiographic evaluation

CBCT (24, 25) was obtained immediately after implant placement and 4 months postoperatively to assess crestal bone loss and bone density under same conditions for all patients by J. Morita CBCT machine (Manufactured in Japan) with standard 8 milliamper and 90 kilovolt settings, one-minute exposure time. Standard automated artifact reduction, standard automated micromotion error correction and field of view 80*80 millimeter.

The level of alveolar bone around each implant was evaluated by taking measurements exactly in the same position in each CBCT by using a fixed reference line that marked tangent to apical tip of implant, then a line drawn from crest of bone buccal and lingual perpendicular to the horizontal tangent. This line will represent the level of the bone in the sagittal view (2D), therefore two measurements will be taken one buccal and one lingual at 4 months post-operative CBCT to reflect the difference in crestal bone level around implant between both groups (29).

Readings buccal and lingual were analyzed for each patient to obtain mean value for each patient then the mean value for each patient was allocated to their preassigned group and statistical analysis was done to get the mean value of each group.

Using OnDemand software in cross sectional view (2D) extracted from immediate postoperative and 4 months post-operative CBCT to examine the alveolar bone density around the implants this was accomplished by taking measurements by making 3 rectangles with the same size being 5*20, one was placed at the middle implant length buccally, one was at the middle implant length lingually and one apically at the same position in each CBCT, by which bone density was measured in Hounsfield units for all patients (30).

Hounsfield values for each patient were analyzed to get mean value for each patient then the mean value for each patient was allocated to their preassigned group and values were statistically analyzed to get the mean value of each group.

Prosthetic Protocol

First stage temporary crowns in functional occlusion were cemented to group (A) with eugenol free temporary cement immediately after surgery, group (B) whom had non-functional temporary crowns cemented with eugenol free temporary cement immediately after surgery.

Second stage porcelain fused to metal crowns were inserted at four months post operatively.

Statistical analysis of the data

Data were fed to the computer and analyzed using IBM SPSS software package version 20.0. (Armonk, NY: IBM Corp) The Kolmogorov-Smirnov test was used to verify the normality of distribution. Quantitative data were described using range (minimum and maximum), mean, standard deviation, median and interquartile range (IQR). Significance of the obtained results was judged at the 5% level.

Student t-test

For normally distributed quantitative variables, to compare between two studied groups.

ANOVA with repeated measures

For normally distributed quantitative variables, to compare between more than two periods or stages, and Post Hoc test (Bonferroni adjusted) for pairwise comparisons

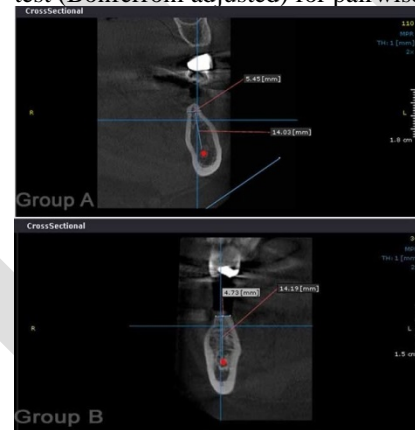


Figure (1): showing preoperative CBCT for both groups with measurements of width and height

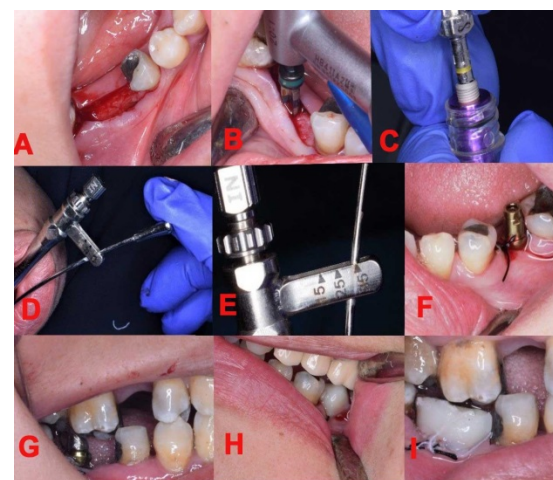


Figure (2): showing (A) Insertion and reflection,(B) Drilling of osteotomy, (C) Implant, (D, E) Graded torque wrench showing 35NCM, (F) Abutment placement and

height adjustment for group A, (G) Abutment placement and height adjustment for group B, (H) Temporary crown in functional occlusion group A, (I) Temporary crown in non-functional occlusion group B

RESULTS

In this study all patients were females with average age of 30 years, there were no failed implants along the evaluation period nor post-operative complications.

Presurgical patient's assessment

All candidates had no systemic diseases.

The Simplified Oral Hygiene Index was used to determine the oral hygiene of the patients by calculating the index value of each patient in their allocated group to get the mean value of each group on a scale from 0 to 6

Group A had mean value of 1.2

Group B had mean value of 1.1

Clinical evaluation

Pain (Table 1, Figure 3)

Immediate postoperative the mean postsurgical pain for both groups was 9.06 with a minimum of 7 and a maximum of 10

After 24 hours the mean after 24 hours pain for both groups was 5.78 with a minimum of 4 and a maximum of 7.5

After 48 hours No pain was recorded in any of the patients.

Radiographic evaluation

Crestal bone loss (Table 2, Figure 4,5)

Using cone beam computed tomography (CBCT) software "On Demand 3D App" data was collected regarding crestal bone loss 4 months after implant placement showing that:

Group A minimum average bone loss was 0.17mm and the maximum was 0.36 mm with Mean \pm SD 0.29 ± 0.07 and Median (IQR) $0.33(0.25 - 0.33)$.

Group B minimum average bone loss was 0.13mm and the maximum was 0.59 mm with Mean \pm SD 0.32 ± 0.14 and Median (IQR) $0.30(0.29 - 0.34)$.

After statistical analysis of the data comparing crestal bone loss after 4 months for groups A&B, it showed an insignificant value ($p > 0.05$).

Bone density

Using cone beam computed tomography (CBCT) software "On Demand 3D App" immediate postoperative and 4 months postoperative to implant placement data were collected regarding mean peri-implant bone density values to evaluate bone density around the implant.

Group A (Table 3, Figure 4,5)

Immediate post-operative, the average minimum bone density value was 309 HU and the maximum value was 524.2 HU with Mean \pm SD 417.2 ± 88.93 and Median (IQR) $394.0 (351.5 - 495.0)$, Four-month postoperative, the average minimum bone density value was 375 HU and the maximum value was 644 HU with Mean \pm SD 540.1 ± 90.06 and Median (IQR) $550.0(509.0 - 597.0)$.

The difference in bone density preoperative, immediate postoperative and 4month after implant placement was statistically significant ($p \leq 0.05$).

Group B (Table 4, Figure 4,5)

Immediate post-operative the average minimum bone density value was 300 HU and the maximum value was 522 HU with Mean \pm SD 399.3 ± 87.05 and Median (IQR) $400.0(327.5 - 458.9)$, Four-month postoperative the average minimum bone density value was 374 HU and the maximum value was 704 HU with Mean \pm SD value 515.1 ± 125.4 and Median (IQR) $480.0(425.0 - 599.0)$.

The difference in bone density immediate postoperative and 4month of implant placement was statistically significant ($p \leq 0.05$).

Comparing between group A&B according to bone density after 4 months (Table 5, Figure 4,5)

Four months post-operative group A the average minimum bone density value was 375 HU and the maximum was 644 HU with Mean \pm SD 540.1 ± 90.06 and Median (IQR) $550.0(509.0 - 597.0)$.

Four months post-operative group B the average minimum bone density was 374 HU and the maximum was 704 HU with Mean \pm SD 515.1 ± 125.4 and Median (IQR) $480.0(425.0 - 599.0)$ Although there was a remarkable difference when comparing bone density values in each group separately, but when comparing the difference in bone density in group A & B 4 month postoperative, it was found to be insignificant ($P > 0.05$).

Prosthetic evaluation

First stage temporary crowns

All patients from group (A) were successfully loaded by functionally occluding temporary crown and all patients from group (b) were successfully loaded by non-functionally occluding temporary crown. (figure 6)

Second stage Porcelain fused to metal crowns

The final crowns were cemented after 4 months postoperatively for both groups (A & B). (figure 6)

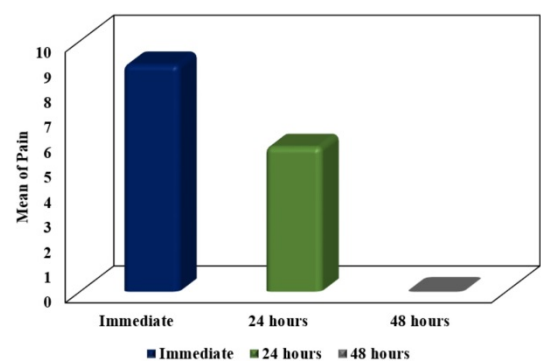


Figure (3): Comparison between the different study periods according to pain (n=16)

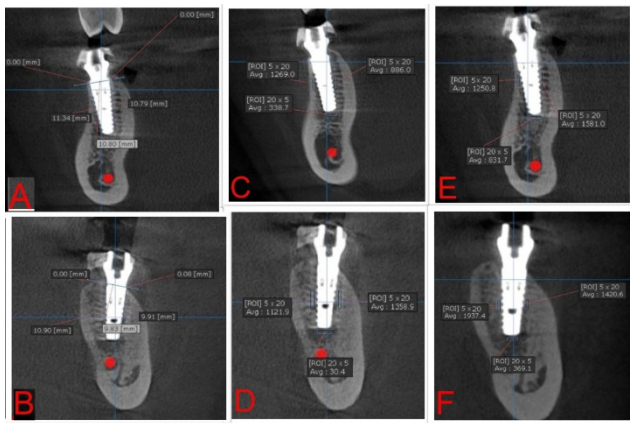


Figure (4): showing (A) Group A crestal bone loss after 4 months, (B) Group B crestal bone loss after 4 months, (C) Group A bone density (HU) immediate post-operative, (D) Group B bone density (HU) immediate post-operative, (E) Group A bone density (HU) 4 months post-operative, (F) Group B bone density (HU) 4 months post-operative

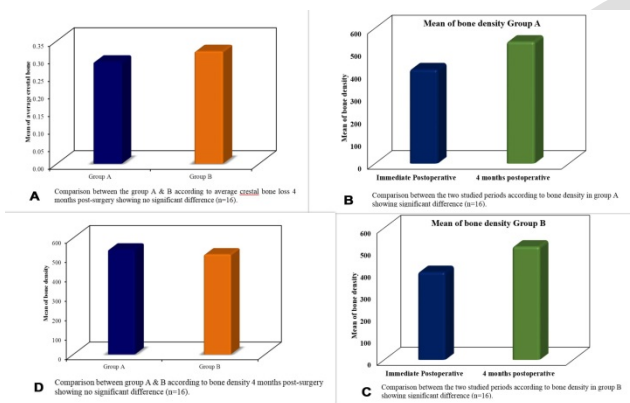


Figure (5) : showing A comparison between the group A&B according to the crestal bone loss 4 months post-surgery showing no significant difference (n=16), B comparison between the two studied periods according to bone density in group A showing significant difference (n=16) ,C comparison between the two studied periods according to bone density in group B showing significant difference (n=16), D comparison between group A&B according to bone density 4 months post-surgery showing no significant difference (n=16).

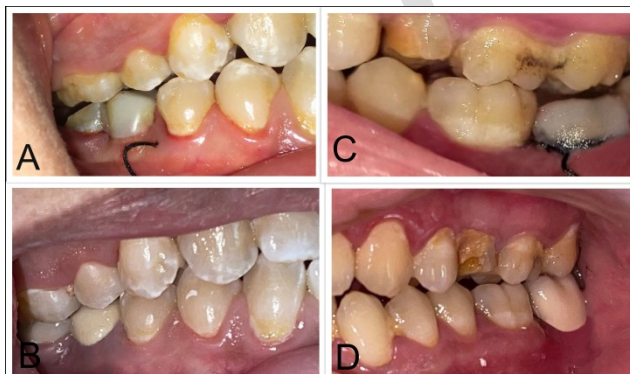

Figure (6): showing (A) Group A with temporary crown in functional occlusion, (B) Group A with Final porcelain

fused to metal crown, (C) Group B with Temporary crown in nonfunctional occlusion, (D) Group B with final porcelain fused to metal crown.

Table (1): Comparison between the different study periods according to pain (n=16)

Patients	Immediate post-operative	24 hours	48 hours
1	8	6	0
2	10	6	0
3	9	5	0
4	10	7	0
5	10	7	0
6	10	6	0
7	10	5	0
8	9	5	0
9	9.5	5	0
10	8	6	0
11	10	4	0
12	9	6	0
13	9	4	0
14	7	7	0
15	8	7.5	0
16	8.5	6	0
mean	9.06	5.78	0

Table (2): Comparison between the group A & B according to average crestal bone loss (n=16).

Average crestal bone	Group A (n = 16)	Group B (n = 16)	t	p
Min. – Max.	0.36 – 0.17	0.59 – 0.13	0.610	0.553
Mean ± SD.	0.29 ± 0.07	0.32 ± 0.14		
Median (IQR)	-0.33(0.25 – 0.33)	-0.30(0.29 – 0.34)		

t: Student t-test

p: p value for comparing between the studied groups Statistically significant at $p \leq 0.05$

Table (3): Comparison between the three studied periods according to bone density in group A (n=16).

Bone density	Functional immediate loading		F	P
	Immediate Postoperative	4 months postoperative		
Min. – Max.	309.0 – 524.2	375.0 – 644.0	6.732*	0.016*
Mean ± SD.	417.2 ± 88.93	540.1 ± 90.06		
Median (IQR)	394.0(351.5 – 495.0)	550.0(509.0 – 597.0)		

F: F test (ANOVA) with repeated measures, Sig. bet.
 periods were done using **Post Hoc Test (Bonferroni)**
 p: p value for comparing between **Immediate postoperative** and **4 months postoperative**
 *: Statistically significant at $p \leq 0.05$

Table (4): Comparison between the three studied periods according to bone density in group B (n=16).

Bone density	Nonfunctional immediate loading		F	p
	Immediate Postoperative	4 months postoperative		
Min. – Max.	300.0 –522.0	374.0 –704.0	4.736*	0.053*
Mean ± SD.	399.3 ± 87.05	515.1 ± 125.4		
Median (IQR)	400.0(327.5 – 458.9)	480.0(425.0 – 599.0)		

F: F test (ANOVA) with repeated measures, Sig. bet.
 periods were done using **Post Hoc Test (Bonferroni)**
 p: p value for comparing between **immediate postoperative** and **after 4 months**
 *: Statistically significant at $p \leq 0.05$

Table (5): Comparison between group A & B according to bone density after 4 months.

Bone density	Group A (n = 16)	Group B (n = 16)	t	p
After 4 months postoperative				
Min. – Max.	375.0 –644.0	374.0 –704.0	0.428	0.676
Mean ± SD.	540.1 ± 90.06	515.1 ± 125.4		
Median (IQR)	550.0(509.0 – 597.0)	480.0(425.0 – 599.0)		

t: Student t-test
 p: p value for comparing between the studied groups
 Statistically significant at $p \leq 0.05$

DISCUSSION

This study was aiming to answer the question whether to immediately load dental implants in functional occlusion or non-functional occlusion and whether the load falling on the implants show a significant difference in bone density and crestal bone loss or will they both be the same.

Within the limitations of our study, we had no failed implants in both immediate functional loaded (IFL) and immediate nonfunctional loaded (INFL) groups and there were no postoperative complications or infection recorded. This was aided by a systemic review and meta-analysis made by Chrcanovic et al. (14) in 2014 whom concluded that differences in occlusal loading between INFL and IFL might not affect the survival of these dental implants.

A study by Degidi M et al. (31) in 2003 recorded 1.4% failed IFL implants and 0.9 % INFL dental implants. In our opinion, their results differ from ours due to having male candidates within their study and since male candidates can have more forceful occlusal forces than

females. In our study all candidates were females which in our opinion aided in our results.

We were also challenged by Degidi M et al. (32) in 2009 when they had 3 failed immediately loaded implants in the scope of their study but this was clear that it was because of poor oral hygiene of one of the patients. One of the key success to having no failed implants and all authors agree upon regardless to the final result is ensuring that the implants had high primary stability to be immediately loaded. So, implants had to be placed with minimum insertion torque of 30-35 Ncm as previously discussed in other researches (21, 33-36), and following the footsteps of Meloni et al., whom inserted implants in healed healthy posterior mandibular bone with an insertion torque between 35 and 45 Ncm (35). This range was found to be enough to immediately load the dental implants. In Our study implants were placed in to the osteotomies made following the manufacturer’s protocol making sure that the insertion torque value was above 35 Newton centimeter which was confirmed using graded torque wrench (21, 36), which in our opinion helped to ensure our results (37). Other key factors were excluding patients with systemic diseases, alcohol, drug users and poor oral hygiene.

Within the limits of our study when comparing the data for crestal bone loss that was analyzed after 4 months postoperatively, Group A showed minimum bone loss of average 0.17mm and the maximum average was 0.36mm while, Group B minimum average bone loss was 0.13mm and the maximum was 0.59mm after comparing both groups, the statistical analysis was found to be insignificant.

These results were aided by Mantena et al. (38), Chrcanovic et al. (14) whom concluded in their study that Both IFL and INFL implants showed similar radiographic results. Mean bone loss was not statistically significant between the two groups.

On the other hand, this was opposed by the conclusion of Ramachandran et al.(39), Singh et al. (37) in which immediate functional loading of implants resulted in a significantly greater degree of bone demineralization compared immediate nonfunctional loading. The difference between their studies and ours is that we had shorter follow up time which might be one of the limitations of our study, different brands of implants were used and different tools of interpretation, but the same inclusion and exclusion criteria were the same within the three studies.

After data analysis of bone density values 4 month postoperatively for group A and group B, a significant increase in bone density values was found when comparing immediate post-operative and four-month postoperative for each group separately our interpretation was that that the physiological load stimulated bone formation which improved bone density values throughout these periods.

These results were aided by Singh et al., in which the aim of their study was to determine if there is a difference in crestal bone loss and the bone density changes around dental implants subjected to IFL and INFL. They

concluded that both functional as well as nonfunctional immediate loading of implants resulted in an improvement of alveolar bone density around the lateral and apical portions of the implant body with no significant difference between both groups (37).

In this study the data analysis of bone density values 4 month postoperatively comparing between groups A and B, it was found that the p value was ($P>0.05$) which meant that there was no significant difference in bone density between both groups.

This was in agreement with by Al-Helou et al. in 2014 whose study was to evaluate the changes that occur in the bone density around implants in the posterior mandibular region as a result of IFL and INFL protocols and concluded that there is an increase in bone density around the implants for both immediate loading protocols functional and non-functional without statistically significant differences between them. (40)

From the results of this study, it was concluded that immediate functional and nonfunctional loading of dental implants are successful treatment options for replacing mandibular posterior teeth and both techniques have the same effect on crestal bone loss and bone density. It is recommended that further research including a larger sample size of both genders (male and female) with longer follow up period.

CONCLUSION

It has been inferred from the findings of this analysis that immediate functional and nonfunctional loading of dental implants are successful treatment options for replacing mandibular posterior teeth and both techniques have the same effect on crestal bone loss and bone density. It is recommended that further research including a larger sample size and a traditional loading group is to be added.

Conflict of Interest

The authors declare that they have no conflict of interest.

Funding

The authors received no specific funding for this work.

REFERENCE

- Zarandi A, Novin M. Marginal bone loss around platform-switched and non-platform switched implants after two years of placement: a clinical trial. *J Dent Res Dent Clin Dent Prospects*. 2017;11:26-9.
- Yan Q, Xiao LQ, Su MY, Mei Y, Shi B. Soft and Hard Tissue Changes Following Immediate Placement or Immediate Restoration of Single-Tooth Implants in the Esthetic Zone: A Systematic Review and Meta-Analysis. *Int J Oral Maxillofac Implants*. 2016;31:1327-40.
- Mangano FG, Shibli JA, Sammons RL, Iaculli F, Piattelli A, Mangano C. Short (8-mm) locking-taper implants supporting single crowns in posterior region: a prospective clinical study with 1-to 10-years of follow-up. *Clin Oral Implants Res*. 2014;25:933-40.
- Turkyilmaz I, McGlumphy EA. Influence of bone density on implant stability parameters and implant success: a retrospective clinical study. *BMC Oral Health*. 2008;8:32.
- Insua A, Monje A, Wang HL, Miron RJ. Basis of bone metabolism around dental implants during osseointegration and peri-implant bone loss. *J Biomed Mater Res A*. 2017;105:2075-89.
- Mangano FG, Mastrangelo P, Luongo F, Blay A, Tunchel S, Mangano C. Aesthetic outcome of immediately restored single implants placed in extraction sockets and healed sites of the anterior maxilla: a retrospective study on 103 patients with 3 years of follow-up. *Clin Oral Implants Res*. 2017;28:272-82.
- Mello CC, Lemos CAA, Verri FR, Dos Santos DM, Goiato MC, Pellizzer EP. Immediate implant placement into fresh extraction sockets versus delayed implants into healed sockets: A systematic review and meta-analysis. *Int J Oral Maxillofac Surg*. 2017;46:1162-77.
- Mangano F, Mangano C, Ricci M, Sammons RL, Shibli JA, Piattelli A. Single-tooth Morse taper connection implants placed in fresh extraction sockets of the anterior maxilla: an aesthetic evaluation. *Clin Oral Implants Res*. 2012;23:1302-7.
- Moraschini V, Porto Barboza E. Immediate versus conventional loaded single implants in the posterior mandible: a meta-analysis of randomized controlled trials. *Int J Oral Maxillofac Surg*. 2016;45:85-92.
- Han CH, Mangano F, Mortellaro C, Park KB. Immediate Loading of Tapered Implants Placed in Postextraction Sockets and Healed Sites. *J Craniofac Surg*. 2016;27:1220-7.
- Kern M, Att W, Fritzer E, Kappel S, Luthardt RG, Mundt T, et al. Survival and Complications of Single Dental Implants in the Edentulous Mandible Following Immediate or Delayed Loading: A Randomized Controlled Clinical Trial. *J Dent Res*. 2018;97:163-70.
- Kinaia BM, Shah M, Neely AL, Goodis HE. Crestal bone level changes around immediately placed implants: a systematic review and meta-analyses with at least 12 months' follow-up after functional loading. *J Periodontol*. 2014;85:1537-48.
- Mangano F, Pozzi-Taubert S, Zecca PA, Luongo G, Sammons RL, Mangano C. Immediate restoration of fixed partial prostheses supported by one-piece narrow-diameter selective laser sintering implants: a 2-year prospective study in the posterior jaws of 16 patients. *Implant Dent*. 2013;22:388-93.
- Chrcanovic BR, Albrektsson T, Wennerberg A. Immediate nonfunctional versus immediate functional loading and dental implant failure rates: a systematic review and meta-analysis. *J Dent*. 2014;42:1052-9.
- Piattelli A, Paolantonio M, Corigliano M, Scarano A. Immediate loading of titanium plasma-sprayed screw-shaped implants in man: a clinical and histological report of two cases. *J Periodontol*. 1997;68:591-7.
- Degidi M, Scarano A, Piattelli M, Piattelli A. Histologic evaluation of an immediately loaded

- titanium implant retrieved from a human after 6 months in function. *J Oral Implantol.* 2004;30:289-96.
17. Mangano FG, Caprioglio A, Levrini L, Farronato D, Zecca PA, Mangano C. Immediate loading of mandibular overdentures supported by one-piece, direct metal laser sintering mini-implants: a short-term prospective clinical study. *J Periodontol.* 2015;86:192-200.
 18. Al-Sawai AA, Labib H. Success of immediate loading implants compared to conventionally-loaded implants: a literature review. *J Investig Clin Dent.* 2016;7:217-24.
 19. Romanos GE. Biomolecular Cell-Signaling Mechanisms and Dental Implants: A Review on the Regulatory Molecular Biologic Patterns Under Functional and Immediate Loading. *Int J Oral Maxillofac Implants.* 2016;31:939-51.
 20. Zita Gomes R, de Vasconcelos MR, Lopes Guerra IM, de Almeida RAB, de Campos Felino AC. Implant Stability in the Posterior Maxilla: A Controlled Clinical Trial. *Biomed Res Int.* 2017;2017:6825213.
 21. Sarfaraz H, Johri S, Sucheta P, Rao S. Study to assess the relationship between insertion torque value and implant stability quotient and its influence on timing of functional implant loading. *J Indian Prosthodont Soc.* 2018;18:139-46.
 22. Lioubavina-Hack N, Lang NP, Karring T. Significance of primary stability for osseointegration of dental implants. *Clin Oral Implants Res.* 2006;17:244-50.
 23. Ryu HS, Namgung C, Lee JH, Lim YJ. The influence of thread geometry on implant osseointegration under immediate loading: a literature review. *J Adv Prosthodont.* 2014;6:547-54.
 24. Singh K, Ramachandran A, Rao J, Mishra N. A Prospective Study To Compare Crestal Bone Loss And Radiographic Bone Density Of Different Implant Systems Subjected To Immediate Functional Or Non Functional Loading. *IOSR-JDMS.* 2018;17:48-53.
 25. Triches DF, Alonso FR, Mezzomo LA, Schneider DR, Villarinho EA, Rockenbach MI, et al. Relation between insertion torque and tactile, visual, and rescaled gray value measures of bone quality: a cross-sectional clinical study with short implants. *Int J Implant Dent.* 2019;5:9.
 26. Gómez-de Diego R, Mang-de la Rosa Mdel R, Romero-Pérez MJ, Cutando-Soriano A, López-Valverde-Centeno A. Indications and contraindications of dental implants in medically compromised patients: update. *Med Oral Patol Oral Cir Bucal.* 2014;19:e483-9.
 27. Greene JC, Vermillion JR. The simplified oral hygiene index. *J Am Dent Assoc.* 1964;68:7-13.
 28. Boonstra AM, Schiphorst Preuper HR, Reneman MF, Posthumus JB, Stewart RE. Reliability and validity of the visual analogue scale for disability in patients with chronic musculoskeletal pain. *Int J Rehabil Res.* 2008;31:165-9.
 29. Saad N, Osman E, Abdelhamid AM, Shokry M, Farghaly EA. Radiographic evaluation of crystal bone level of immediate loaded implant restored with two different CAD-CAM materials. *Egypt Dent J.* 2020;66:1749-55.
 30. Pauwels R, Jacobs R, Singer SR, Mupparapu M. CBCT-based bone quality assessment: are Hounsfield units applicable? *Dentomaxillofac Radiol* 2015;44:20140238.
 31. Degidi M, Piattelli A. Immediate functional and non-functional loading of dental implants: a 2- to 60-month follow-up study of 646 titanium implants. *J Periodontol.* 2003;74:225-41.
 32. Degidi M, Iezzi G, Perrotti V, Piattelli A. Comparative analysis of immediate functional loading and immediate nonfunctional loading to traditional healing periods: a 5-year follow-up of 550 dental implants. *Clin Implant Dent Relat Res.* 2009;11:257-66.
 33. Dos Santos MV, Elias CN, Cavalcanti Lima JH. The effects of superficial roughness and design on the primary stability of dental implants. *Clin Implant Dent Relat Res.* 2011;13:215-23.
 34. Elias CN, Rocha FA, Nascimento AL, Coelho PG. Influence of implant shape, surface morphology, surgical technique and bone quality on the primary stability of dental implants. *J Mech Behav Biomed Mater.* 2012;16:169-80.
 35. Meloni SM, De Riu G, Pisano M, De Riu N, Tullio A. Immediate versus delayed loading of single mandibular molars. One-year results from a randomised controlled trial. *Eur J Oral Implantol.* 2012;5:345-53.
 36. Testori T, Del Fabbro M, Szmukler-Moncler S, Francetti L, Weinstein RL. Immediate occlusal loading of Osseotite implants in the completely edentulous mandible. *Int J Oral Maxillofac Implants.* 2003;18:544-51.
 37. Singh K, Ramachandran A, Rao J, Mishra N. A prospective study to compare crestal bone loss and radiographic bone density of different implant systems subjected to immediate functional or non functional loading. *IOSR-JDMS.* 2018;17:48-53.
 38. Mantena SR, Sivagami G, Gottumukkala SN. Evaluation of crestal bone loss and stability of immediate functional loading versus immediate non-functional loading of single-mandibular posterior implants: A pilot randomized controlled clinical trial. *Dent Res J (Isfahan).* 2014;11:585-91.
 39. Ramachandran A, Singh K, Rao J, Mishra N, Jurel SK, Agrawal KK. Changes in alveolar bone density around immediate functionally and nonfunctionally loaded implants. *J Prosthet Dent.* 2016;115:712-7.
 40. Al-Helou H, Al-sharan F, Jafo MH. Evaluation of bone density around immediately functional and nonfunctional loaded implants. *J Indian Dent Assoc.* 2014;8: 14-20.