

*Research Article***Correlation of Multidetector 64 CT Pulmonary Angiography and Well's Clinical Score in Pulmonary Embolism**

Ibrahem E. Ali*, **Mohamed F. Amin****, **Maha K. Ghanem*****,
and Housney S. Abdelghany*

* Departement of Radiodiagnosis, Elminia University

** Department Chest , Assuit University

*** Departement Radiodiagnosis, Assuit University

Abstract

Objective: to correlate the findings of 64 MDCT Pulmonary angiography & Well's clinical scoring system in cases of pulmonary embolism. **Patients and methods:** The study was done between April 2010, and May 2012, 50 patients with suspected clinical pulmonary embolism (31 women, 19 men; age range 19-73 years) underwent 64- Multislice CT pulmonary angiography. CT angiography was used in examination and evaluation for patients suspected of having PE with Correlation with clinical Well's scoring system. The 50 patients were divided into two groups: Group I included 40 patients with high risk (where pulmonary embolism is likely & highly suspicious). Groups II included 10 patients with low risk (where pulmonary embolism is unlikely). **Results:** Images from "41 of 50" thoracic CT pulmonary angiography examination revealed clots within pulmonary arteries, which equals a prevalence of PE of 82%, overall (10 of 41 at pulmonary trunk, 8 of 41 at segmental pulmonary arteries and 18 of 41 at subsegmental pulmonary arteries, of 24%, 19.5% and 43.9% respectively, 5 of 41 at multiple central/segmental and segmental/subsegmental arteries of 12%). Patients with positive DVT was 34% (17 of 50) & 66% (33 of 50) wasn't having DVT prior to the CT Pulmonary angiographic study. Patients with low Well's score probability confirmed to have very low incidence of pulmonary embolism, while patients with both medium & high Well's score probability having high incidence of pulmonary embolism in CT Pulmonary angiography in our study. **Conclusion:** Correlation of Both 64-MDCT Pulmonary Angiography & Clinical Scoring Well's systems showing high relation in-between, considering that group having low clinical probability to have PE, MDCT was at the lest positive level, with the other group with high clinical possibility to have PE, MDCT findings are at the high level of positive results

Key words: Multidetector CT, Pulmonary Embolism, MRI.

Introduction

The development of multidetector CT has opened a wide range of recent applications. It has allowed the development of new imaging techniques such as CT angiography, which has become a reliable noninvasive technique for vascular imaging (Schoepf et al., 2003).

MDCT technique allows increase in gantry speed and acquisition of contiguous sections with a section thickness of 1 mm or less throughout the thorax, with a reduced acquisition time. The reduced acquisition time yields optimal contrast enhancement on all acquired sections, and the narrow collimation increases spatial resolution and reduces partial volume averaging (Revel et al., 2005).

This progress has extended the assessment of the pulmonary vasculature with improved Visualization of the segmental and subsegmental vessels increasing its accuracy in diagnosis of different vascular diseases (Schoepf and Costello, 2004).

A variety of congenital and acquired pulmonary vascular disorders can be diagnosed using pulmonary CT angiography (PCTA) including pulmonary embolism, pulmonary artery aneurysm, pulmonary hypertension, pre-therapeutic management of bronchial carcinoma, post-operative incidents, AVM, primary pulmonary artery sarcoma, and pulmonary arterial and venous anomalies (Castaner, et al., 2006).

The introduction of PCTA into the diagnostic work-up of pulmonary embolism has considerably modified the diagnostic algorithms, as it is now the imaging modality of choice in pulmonary embolism and has replaced other investigations as scintigraphy and conventional angiography in many institutes (Goodman, 2005).

PCTA plays a role in detecting pulmonary artery hypertension where dilatation of the pulmonary artery suggests increased pressure in the pulmonary system. In addition, evaluation of the lung windows helps in detection abnormalities of perfusion. It is also of great value in detecting pulmonary obstruction in the most common cases of secondary pulmonary hypertension (Oliaro et al., 2000).

Patients & Methods

The study was done in between April 2010, and may 2012, 50 patients with suspected clinical pulmonary embolism (31 women, 19 men; age range 19-73 years, mean age 40 years) were recruited from Assuit university hospital, included patients presenting to the emergency, coronary, general ICU & surgical inpatients at the time of diagnosis presenting with signs & symptoms of suspected pulmonary embolism.

The 50 patients divided into two groups:

Group I included 40 patients with high risk

Groups II included 10 patients with low risk Division & groups were done according to the clinical Well's scoring system

Also group I was reclassified according to heart rate into tachycardiac group with HR >100 and normal heart rate group with HR <100

Group I was divided according RV / LV ratio measured on computed tomographic (CT) angiography into 2 groups with no RVD (RV/LV<1) and with RVD (RV / LV > 1) "CT feature".

Inclusion criteria

Any patients coming to emergency room with symptoms of clinically suspected pulmonary embolism such as:

- Sudden onset of dyspnea sudden deterioration of existing dyspnea sudden onset of pleuritic chest pain without another apparent cause.
- Any other symptoms like haemoptysis, syncope or unilateral leg pain.

Exclusion criteria

- Pregnancy
- Allergy to intra-venous contrast agents
- Renal insufficiency (creatinine clearance < 30 mL/min (<0.5mL/s).

Methods:

All patients were examined and subjected to the following:

I- Full history taking: from the patients or their relatives with special emphasis to:-

- Age, sex, Special habits
- Risk factors for venous thromboembolism as
- Surgery and related conditions:
- Surgical procedures, especially those involving the hip, pelvis or knee.
- Medical conditions or medications as:
- Cancer
- immobilization (including neurologic paralysis from a stroke, bed rest, and prolonged periods in the hospital)
- Previous DVT or PE
- Increased age
- Obesity
- Pregnancy
- Certain medications (eg, birth control pills, hormone replacement therapy, tamoxifen, thalidomide
- Smoking
- Heart failure
- Kidney problems, such as nephrotic syndrome

• **Presenting symptoms including:**

Dyspnea, Chest pain, Hemoptysis, Fainting, cough, leg pain or swelling.

• **Associated co-morbidity including:**

Ischemic heart disease, Hypertension, Diabetes, mellitus, Stroke, Malignancy, Chronic lung disease

II) Referred clinician Clinical examination:

General examination with emphasis on:

Vital signs including blood pressure, heart rate, respiratory rate and temperature for detection of maximum HR, maximum temperature and lowest systolic BP

Examination of extremities either upper or lower limbs to detect signs of DVT as hotness or redness and lax or tense

Local examination

Local examination (chest and heart) with emphasis on signs of pulmonary hypertension as accentuated second heart sound also presence of signs of consolidations, Pleural effusion

Assessing clinical likelihood

Different probability scores for pulmonary embolism were calculated for each patient.

Wells Prediction Rule

Score	Clinical Characteristic
+1.5	Previous pulmonary embolism or deep vein thrombosis
+1.5	Heart rate >100 beats per minute
+1.5	Recent surgery or immobilization (within the last 30 d)
+3	Clinical signs of deep vein thrombosis
+3	Alternative diagnosis less likely than pulmonary embolism
+1	Hemoptysis
+1	Cancer (treated within the last 6 mo)
Score	<u>Clinical Probability of Pulmonary Embolism</u>
0-1	Low
2-6	Intermediate
≥ 6	High

P.S. Wells et al., 2000

III) Imaging

CT Pulmonary Angiography (CTPA):

All patients underwent 64 Multislice CT pulmonary angiography. CT angiography was used in examination and evaluation for patients suspected of having PE.

CTPA diagnostic criteria for acute

Pulmonary embolism included:

- Complete arterial occlusion with failure to opacify the entire lumen and the artery may be enlarged in comparison with the pulmonary arteries of the same order of branching
- Central arterial filling defect surrounded by IV contrast material
- Peripheral intraluminal filling defect that makes an acute angle with an arterial wall. (Reena Mathur et al., 2016)

Results

The proportion of dyspnic patients was 74% (37 of 50), patients with chest pain was 40% (20 of 50) and patients with positive DVT was 34% (17 of 50).

The proportion of acute presentation of PE on the obtained CT findings was 80.5% (33 of 50), and chronic presentation was 19.5% (8 of 50) with (9 of 50) patients with normal CT pulmonary angiography with no evident embolism with average percentage of 19.5% (table 8 & figure 48)

Images from “41 of 50” thoracic CT pulmonary angiography examination revealed clots within pulmonary arteries, which equals a prevalence of PE of 82%, overall (10 of 41 at pulmonary trunk, 8 of 41 at segmental pulmonary arteries and 18 of 41 at subsegmental pulmonary arteries, of 24%, 19.5% and 43.9% respectively, 5 of 41 at multiple central/segmental and segmental/subsegmental arteries of 12%).

In eight patients referred for suspicion of acute pulmonary embolism PE, thoracic CT angiography showed abnormalities typical of chronic PEs, with marginal clots or arterial retraction, which was combined in three patients with pulmonary trunk enlargement (range 3.2 – 3.8-cm). Marginal clots were seen in labor arteries in two patients, and were associated with chronic obstruction, which in the other three patients marginal clots were present only at segmental levels. All patients with chronic clots had mosaic attenuation of the pulmonary parenchyma at lung window settings.

The mean age and SD of all patients was 41.9 ± 14.8 in whom age ranged from 19 to 73. Male patients (19 cases) represented 48.3% of cases, while female patients (31 cases) represented 51.7% of cases.

The proportion of dyspnic patients was 74% (37 of 50), means most of our patients presented with dyspnea representing that it is of great clinical significance, only (13 of 50) patients not presented with dyspnea

The proportion of patients with chest pain was 40% (20 of 50) with (30 of 50) not presented

with chest pain, representing that chest pain is not of great clinical value

Patients with positive DVT was 34% (17 of 50) & 66% (33 of 50) wasn't having DVT prior to the CT Pulmonary angiographic study

Well's score categories (Total n=50).

N (%)	Groups
9(18%)	Low probability
14(28%)	Medium probability
27(54%)	High probability

P-Value	CT +ve N=41		CT -ve N=9		Well's score
	%	N	%	N	
<0.001 HS	31.9	1	91.3	8	Low probability
	48.9	13	7.7	1	Medium probability
	91.1	27	0.0	0	High probability

Incidence of pulmonary embolism in Well's score (Total n=50).

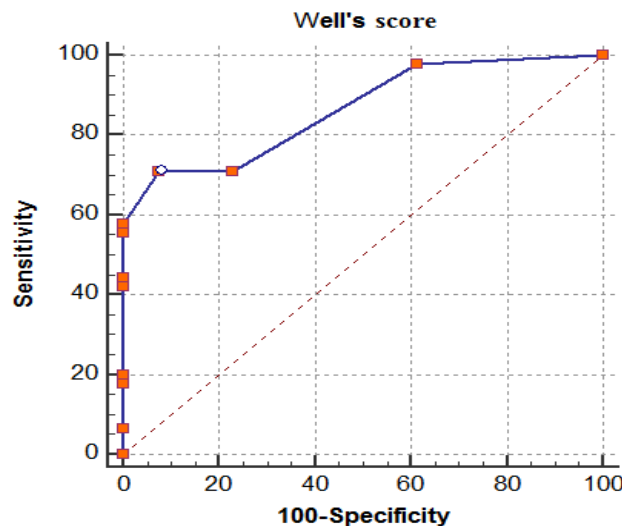
*Fisher's exact tests was used, statistically significant difference, P<0.05.

Incidence of pulmonary embolism in Well's score (Total n=50).

Patients with low Well's score probability confirmed to have very low incidence of pulmonary embolism, while patients with both medium & high Well's score probability having high incidence of pulmonary embolism in CT Pulmonary angiography in our study

Table : ROC curve for results of Well's score in diagnosis of pulmonary embolism.

NPV	PPV	Specificity	Sensitivity	Cutoff	Significance	Area under the Curve (95% CI)	Well's score
48%	97%	92.3%	71.11%	>1.5	<0.001 HS	0.864(0.75 – 0.94)	Well's score



ROC curve for results of Well's score in diagnosis of pulmonary embolism. Illustrated percentage of PE presentation according to the findings of thoracic CT angiography. Most of patient in our study presented with acute presentation of pulmonary embolism about 33 (80.5%) of overall 41 patients with only 8 patients representing about only 19.5 % were presented with Chronic PE. Most of our patients were presented with Subsegmental pulmonary embolism (18 of 41 positive patients) representing about (43.9%) with the second common findings were in the pulmonary trunk (10 of 41 patients) about 24%, 8 patients were diagnosed to had segmental PE with 19.5% & 5 patients (12%) were diagnosed to had mixed site of the emboli.

There were several risk factors for pulmonary embolism within study population. DVT was present in 34% of patients while immobility was present in 50% of patients, estrogen use was present in 8%, surgery was present in 24% of patients while malignancy was equal 6%, 4% of patients was in the postpartum period and 14% of patients had no identifiable risk factor.

Therefore Immobility is the most common risk factor for PE, followed with DVT In the present study table 13 shows comparison between the two groups group I was 41 patients in whom mean age was 44 ± 13 ranging from 19 to 73, median 55 and IQR 33:62.

Male patients was 35% and Female was 65%, the most frequent co morbidity was hypertension represent 27% followed by ILU & COPD 19% and 17% of cases have more than one co morbidity while no co morbidity was found in 29% of cases.

Group II was nine patients in whom mean age was 50 ± 16 ranging from 21 to 73, with median 57 and IQR 33:63.

Male patients was 55% while Female patients was 45%, the most frequent co morbidity was diabetes, ILD & COPD 22% for each followed by hypertension in 11% of cases and 33% of cases have more than one co morbidity while no co-morbidity was present in 66% of cases

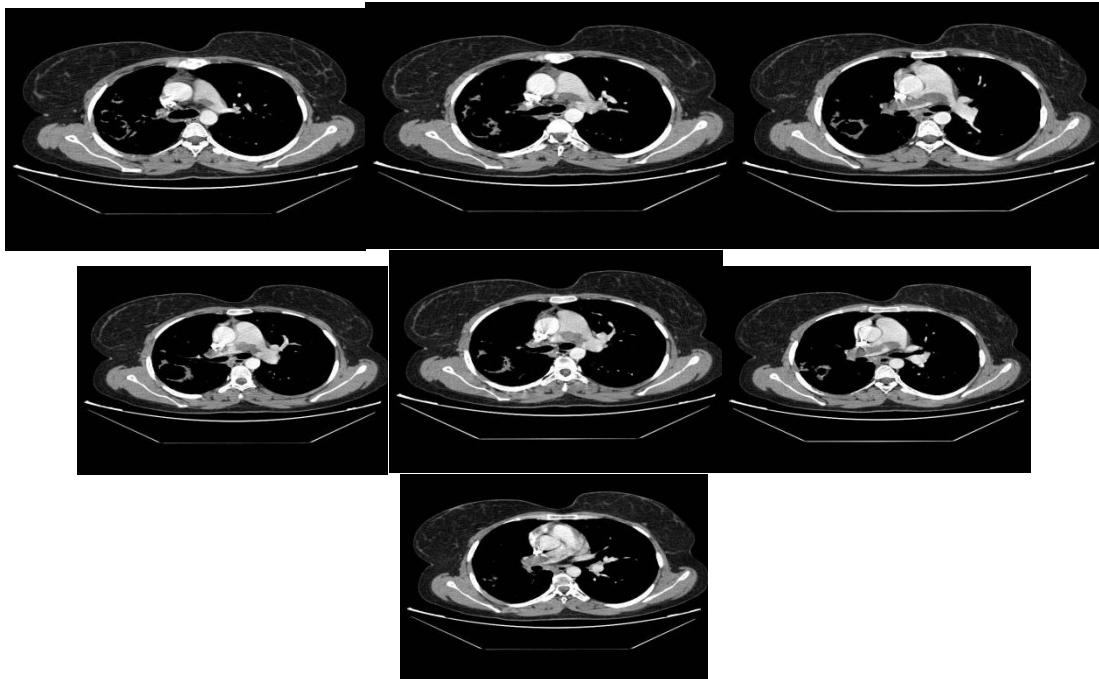
The study representing dyspnea in 82% in group I and 33% in group II followed by haemoptysis 48% in group I and 22% in group II, haemoptysis Was 48% in group I and 22% in group II and syncope was 17% in group I with no cases of syncope in group II.

Clinical probability score wells score was in group I 6.5 ± 2 and in group II was 2.5 ± 1 the sensitivity and specificity of well's clinical probability score in CT diagnosing pulmonary embolism showing that it has Sensitivity 90.00% and Specificity 50% (it seems to be of high sensitivity & moderate specificity)

Group II had 9 patients with low clinical probabilities according to Wells scoring system and 3(37.5%) patient was confirmed to be -ve according to PERC rules CT finding in cases of pulmonary embolism there was no associated parenchymal abnormality in 22 cases (54%), 8 cases (19%) with pulmonary consolidation, 4 cases (10%) with interstitial lung disease, 6 cases (14%) with pleural effusion, peripheral wedge shaped density (Humpton's Hump), pleural thickening was 5 cases (12%) & 2 cases with 5% show mediastinal LNs. The most common finding is pulmonary consolidation, followed by pleural effusion with no parenchymal abnormalities were detected in more than 50% of patients

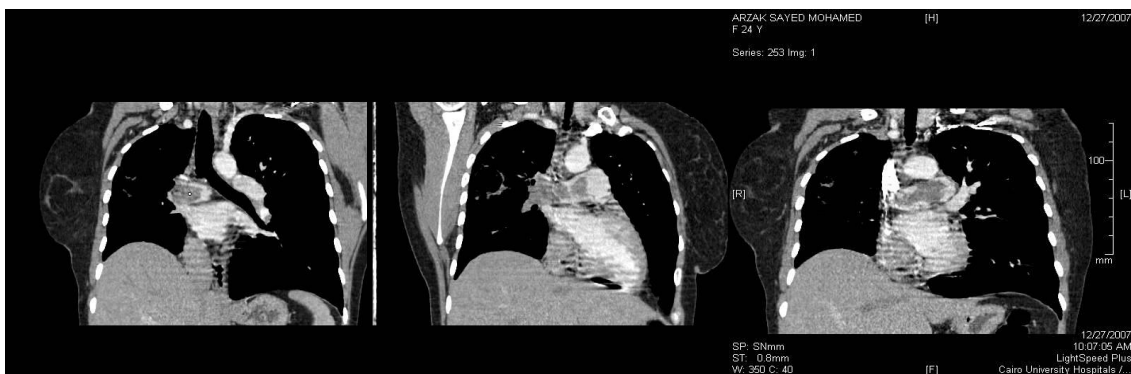
Conflict of Interest

The authors declare that there are no conflict of interests.



Axial CT cuts showing a large hypodense filling defect seen at the lower aspect of the pulmonary trunk and extending to the proximal portions of both main pulmonary arteries more on the right side occluding it with a thin rim of contrast at its periphery.

An irregular thick walled cavitary lesion is seen at the apical segment of the right lower lobe.



Oblique coronal images showing the hypodense filling defect within the main, right pulmonary artery and the proximal portion of the left one.

Diagnosis:

Saddle pulmonary embolism involving the bifurcation of the pulmonary trunk and mainly the right pulmonary artery.

Discussion

Diagnosing pulmonary embolism can be difficult. Problems may arise not only because symptoms and signs can be nonspecific or occult, but because in assessing the accuracy of any diagnostic test for PE there is no universally accepted reference standard (S. Iles, et al., 2013).

Both underdiagnosis and overdiagnosis are associated with substantial morbidity and mortality rates. Untreated pulmonary embolism can be fatal, and overtreatment exposes the patient who does not have pulmonary embolism to an unjustified risk for major bleeding. The BTS guidelines for the management of suspected acute pulmonary embolism in 2003 recommended that all patients with possible PE should have clinical probability assessed and documented (S. Iles, et al., 2013).

On correlating the results of the current study regarding PE with other studies using 64MDCT scanners, we found that lower percentages were detected by Revel et al., (2005) detected PE in only 24.5% (in a study population of 220 patients), this could be attributed to wide variation of risk patient in that study involving high percentage of low risk group compared with our study

A larger percentage was seen in a study by Patel et al., (2003) in which 3 consecutive groups of patients, 20 each using a 64-MDCT scanner, 27% showed evidence of acute PE.

Regarding isolated subsegmental PE in our study, it was seen in 18 patients (43.9%) of the cases diagnosed with PE. In two studies by Coche et al., (2003) and Musset et al., (2002) using 64-MDCT scanners, lower results were detected showing subsegmental PE in only 4.2% and 3% of cases respectively, while higher percentages were recorded in the Revel et al., (2005) study as it was seen in 15% of their cases.

Variable results were found using 16-MDCT scanners, Kluge et al., (2006) showed isolated subsegmental PE in 12 of 65 patients (18.4) and in another retrospective study examining

1435 patients by Eyer et al., (2005) as it was seen in 5.4%.

The difference of the results in our study in some entities compared to other studies can be attributed to the fact that PCTA is being nowadays a routine investigation, so the referred patients were those highly suspected of having PE. Also, the available scanner in our study is a 64-MDCT which relatively provides more accurate data compared to other studies using a lower scanners.

All patients in our study showed variable degrees of pulmonary artery dilatation, but, only some of them showed other CT signs of pulmonary hypertension.

The range of dilatation of the main pulmonary artery in our study is from 3 to 3.9cm. We found that lower percentages were detected by (Van Rossum, 2010) study showing that only 5 cases (10%) having main pulmonary trunk PE, compared with about 10 cases (24%) in our study

A larger percentage was seen in a study by Van Rossum, 2014 in which, 80 patients were examined using a 64-MDCT scanner, 34% showed evidence of Trunk PE.

According to (S. Iles, et al., 2013), with 70 Patient examined with 64-MDCT 60% were female & 40% were males, with also similar high percentage In our study where we found 51.7 PE in female patients & 48.3 in Males

Regarding pulmonary parenchymal signs in our study, emphysema was seen in four patients, mosaic attenuation in three, bronchiectatic changes in three, peribronchial thickening in one, and a large area of right perihilar consolidation in one patient.

Similar findings were seen in the Resten et al., (2012) where honeycombing and bronchiectasis were seen in one patient each. Compared with study population of 120 patients in Castaner, et al., 2016, that shows high percentage of chronic presentation of PE. (43% 52 patient of 120) were found, compared with 8 patients (19.5%) in our study; this is attributed to larger volume of patients

Compared with Goodman, 2015 study that show large volume of patients having DVT

associated with PE in a study of 210 population volume (90 of 210 patients about 42%), compared with about 17 of 50 patients in our study (34%); this is could be seen as small sample volume in our study

Compared with Maki et al., 2011 study that show low percentage of patients presented with dyspnea (70 patient of total 120 study population, 58%), compared with (37 patient from 50 total population study, 74%); this could be seen as a result of being most of our study population are in-patients & admitted to intensive care unit

Conclusion

Two categories were seen (low & high risk groups) according to the risk factors. Considering Well's clinical scoring system, three categories were seen, low, intermediate & high probability for having PE. Correlation of Both 64-MDCT Pulmonary Angiography & Clinical Scoring Well's systems showing high relation in-between, considering that group having low clinical propability to have PE, MDCT was at the lest positive level, with the other group with high clinical possibility to have PE, MDCT findings are at the high level of positive results

64-MDCT Pulmonary Angiography has as great correlation with the clinical probability Well's scoring system

64-MDCT is the first imaging modality of choice in cases suspecristted with pulmonary embolism

Other radiological imaging modalities involving X-ray chest & MRA may be of great value

REFERENCES

1. Addis KA, Hopper KD, Iyriboz TA, et al., CT angiography: In vitro comparison of five reconstruction methods. *Am J Roentgenol* 2001; 177:1171–1176.
2. Baddi L, Ray D. An unusual nosocomial pneumonia. *Chest* 2002; 122:1077-1079.
3. Baque-Juston MC, Wells AU & Hansell DM. Pericardial thickening or effusion in patients with pulmonary artery hypertension: a CT study. *AJR Am J Roentgenol* 1999; 172:361–364.
4. Barst RJ, Langleben D, Frost A, et al., Sitaxsentan therapy for pulmonary arterial hypertension. *Am J Respir Crit Care Med* Feb 15 2004; 169(4):441-7.
5. Brown MD, Rowe BH, Reeves MJ, et al., The accuracy of the enzyme-linked immunosorbent assay D-dimer test in the diagnosis of pulmonary embolism: a meta-analysis. *Ann Emerg Med* 2002;40:133-134.
6. Coche EE, Muller NL, Kim K, et al., Acute pulmonary embolism: ancillary findings at spiral CT. *Radiology* 1998; 207:753-758.
7. Edwards PD, Bull RK, Coulden R. CT measurement of main pulmonary artery diameter. *Br J Radiol* 1998; 71:1018–1020.
8. Goo HW, Park I, Ko JK, et al., CT of Congenital Heart Disease: Normal Anatomy and Typical Pathologic Conditions. *Radiographics* 2003; 23:S147-S165.
9. Heinrich M, Uder M, Tscholl D, et al., CT scan findings in chronic thromboembolic pulmonary hypertension: predictors of hemodynamic improvement after pulmonary thromboendarterectomy. *Chest* 2005; 127:1606-1613.
10. Lell MM, Anders K, Uder M, et al., New Techniques in CT Angiography. *Radio Graphics* 2006; 26:S45-S62.
11. Oliaro E, Grosso MW, Orzan F. Primary pulmonary hypertension. *Minerva Cardio-angiol* 2000; 48(11):361-378.
12. Quiroz R, Kucher N, Schoepf UJ, et al., Right ventricular enlargement on chest computed tomography: prognostic role in acute pulmonary embolism. *Circulation* 2004; 109:2401–2404.
13. Remy-Jardin M, Duhamel A, Deken V, et al., Systemic collateral supply in patients with chronic thromboembolic and primary pulmonary hypertension: assessment with multi-detector row helical CT angiography. *Radiology* 2005; 235:274–281.
14. Remy-Jardin M, Remy J, Mayo JR, et al., Pulmonary hypertension. In: *CT angiography of the chest*. Philadelphia, Pa: Lippincott Williams & Wilkins, 2001; 70–71