

Research Article

The superiority of the Three Dimensional Ultrasound over the conventional Two Dimensional Ultrasound as diagnostic modalities in uterine structural anomalies

Abdulrahman Y. Elkashef, Mohamed A. Quodi and Ahmad E. Mahran

Department of Obstetrics and Gynecology, Minia University Maternity Hospital, Minia, Egypt.

Abstract

The aim of this pilot study was to investigate the potential value of three dimensional ultrasound for the evaluation of normal uterine anatomy and the diagnosis of congenital uterine anomalies when compared to the two dimensional ultrasound. **Material and Methods:** This pilot study was conducted in the Department of Obstetrics and Gynecology, Faculty of Medicine, Minia University Maternity Hospital in Egypt, from April. 2014 to Feb. 2015. A total number of 53 patients were recruited after being suspected to have uterine structural anomalies by the HSG. Patients with primary infertility were 34.98% while patients with secondary infertility were 65.02%.

Keywords: Infertility, Three Dimensional Ultrasound, uterine anomalies, Mullerian duct anomalies, Two Dimensional Ultrasound

Introduction

Uterine malformations are secondary to a failure in development, canalization or fusion of Müllerian ducts. Around the sixth week of the embryogenesis, an invagination of the coelomic lining epithelium forms a depression creating a sulcus, whose borders fuse to form the lateral Müllerian ducts (or paramesonephric ducts). The Müllerian ducts initially are formed in the upper dorsal wall of the coelomic cavity and progress caudally to enter the pelvis where they incline towards the center, fusing medially. Then, the caudal progress results in a contact of these fused ducts with the urogenital sinus. The proximal segments of the uterovaginal canal originated from coelomic epithelium remain unfused and open into the peritoneal cavity to form the Fallopian tubes. The upper portion of the vagina is, therefore, considered to have Müllerian origin, and the lower portion as originating from the urogenital sinus. The whole lining epithelium (uterus and tubes) originates from the coelomic epithelium. This is the reason for uterine malformations being denominated Müllerian malformations or anomalies⁽¹⁾.

In the past, the uterus only could be clinically evaluated by means of a physical examination. Several methods have been introduced for gynecological evaluation. As an example, we

can mention; radiological examinations⁽²⁾ by means of hysterosalpingography⁽³⁻⁵⁾ surgical procedures— laparotomy, laparoscopy, and most recently, videolaparoscopy and hysteroscopy⁽⁶⁾ Unquestionably, ultrasound is the method that has brought the greatest contribution as non-invasive method for evaluation of the uterus and its attachments⁽⁷⁾, initially as a two-dimensional (2D) modality with an abdominal approach, and later with a transvaginal approach. Most recently, ultrasonography has been added of the three-dimensional (3D) processing⁽⁸⁻¹¹⁾ in both modalities — the multiplanar and the volumetric ones. Magnetic resonance imaging also has been utilized in many services⁽¹²⁾.

Discussion

2D ultrasound, and 3D ultrasound are crucial diagnostic tools for evaluation of uterine malformations, with high accuracy, most of times more specific than a simple description of a septate uterus, characterizing the abnormality and providing information to assist in the definition of therapeutic regimen and reproductive prognosis⁽¹²⁻¹⁶⁾.

A better evaluation with 2D ultrasound is achieved by the association between trans-abdominal and transvaginal approaches. The first one allows a better visualization of the

uterine fundus, and analysis of the bladder and ureteral jets. The second allows a more detailed analysis of the cervix and endometrial cavity.

3D ultrasound showed high sensitivity and specificity 96 and 94 respectively when compared to the 2D ultrasound; 82, 91 respectively.

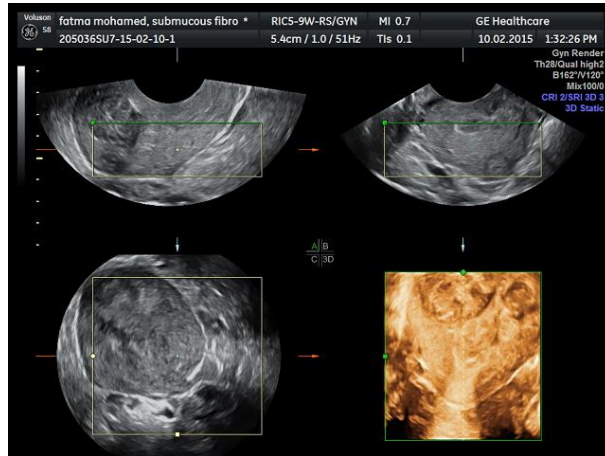


Figure (1)

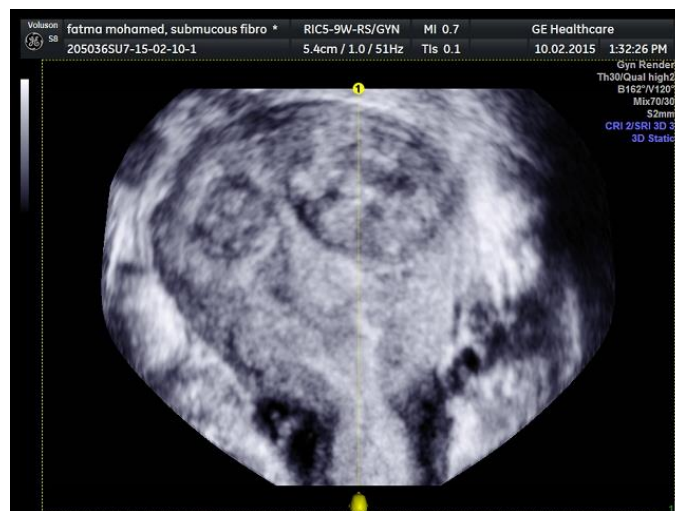


Figure (2)

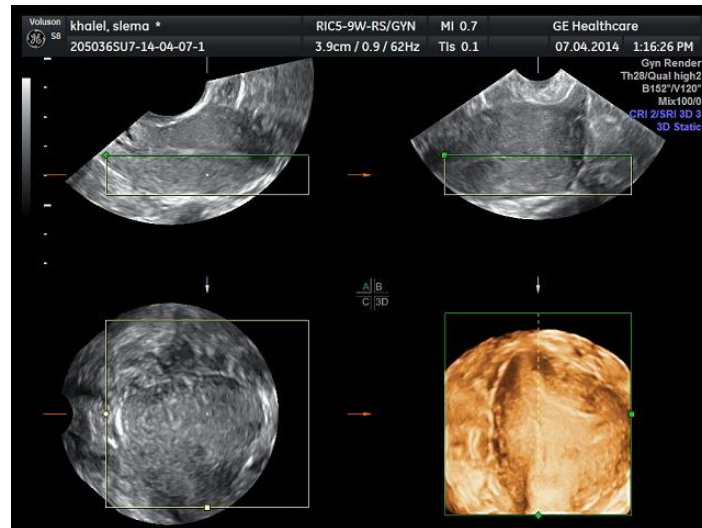


Figure (3)

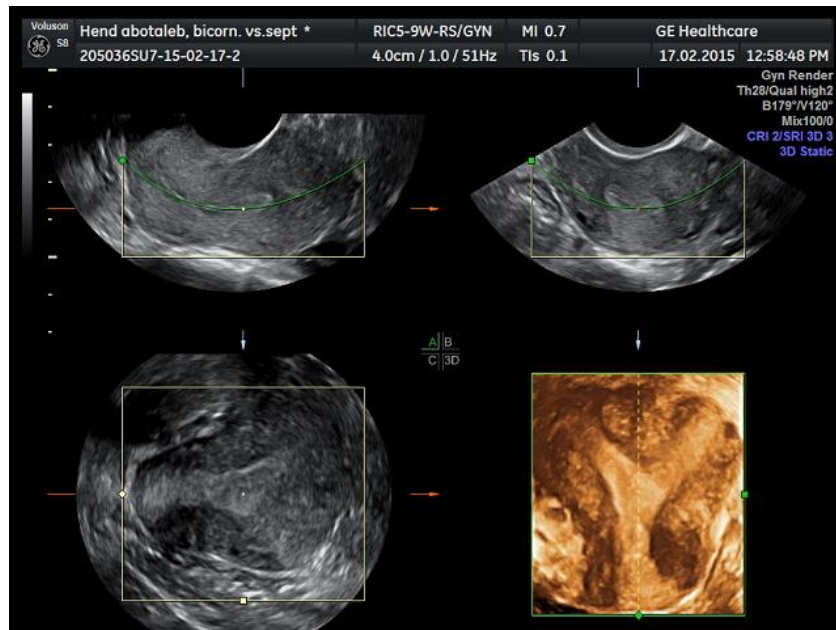


Figure (4)

References

1. Ben-Rafael Z, Seidman DS, Recabi K, Bider D, Mashiach S. Uterine anomalies. A retrospective, matched-control study. *J Reprod Med* 1991;36: 723–727.
2. Bracci M, Busilacchi P, Ciccognani G, Lorenzoni A, Serri L. Abnormalities of the female genital tract. Comparison of radiographic and echographic pictures. *Radiol Med (Torino)* 1988; 75:181–191.
3. Matheus M, Franceschini AS, Sala MA, Barrionovo N. Histerossalpingografia: estudo retrospectivo de 535 casos. *J Bras Ginecol* 1986;96:123–127.
4. Goldberg JM, Falcone T, Attaran M. Sonohysterographic evaluation of uterine abnormalities noted on hysterosalpingography. *Hum Reprod* 1997; 12:2151–2153.

5. De Meo I. Hysterosalpingography in the diagnosis of uterine malformations. *Mine-rva Ginecol* 1983;35:127–130.
6. Valli E, Zupi E, Marconi D, et al. Hysteroscopic findings in 344 women with recurrent spontaneous abortion. *J Am Assoc Gynecol Laparosc* 2001;8:398–401.
7. Grimbizis GF, Camus M, Tarlatzis BC, Bontis JN, Devroey P. Clinical implications of uterine malformations and hysteroscopic treatment results. *Hum Reprod Update* 2001;7:161–174.
8. Jurkovic D, Gruboeck K, Tailor A, Nicolaidis KH. Ultrasound screening for congenital uterine anomalies. *Br J Obstet Gynaecol* 1997;104:1320–1321.
9. Raga F, Bonilla-Musoles F, Blanes J, Osborne NG. Congenital mullerian anomalies: diagnostic accuracy of three-dimensional ultrasound. *Fertil Steril* 1996;65: 523–528.
10. Chan L, Uerpaiojkit B, Reece EA. Diagnosis of congenital malformations using two-dimensional and three-dimensional ultrasonography. *Obstet Gynecol Clin North Am* 1997;24:49–69.
11. Lev-Toaff AS, Pinheiro LW, Bega G, Kurtz AB, Goldberg BB. Three-dimensional multiplanar sonohysterography: comparison with conventional two-dimensional sonohysterography and x-ray hysterosalpingography. *J Ultrasound Med* 2001;20:295–306.
12. Fedele L, Dorta M, Brioschi D, Massari C, Candiani GB. Magnetic resonance evaluation of double uteri. *Obstet Gynecol* 1989;74:844–847.
13. Nicolini U, Bellotti M, Bonazzi B, Zamberletti D, Candiani GB. Can ultrasound be used to screen uterine malformations? *Fertil Steril* 1987;47:89–93.
14. Woodward PJ, Sohaey R, Wagner BJ. Congenital uterine malformations. *Curr Probl Diagn Radiol* 1995;24:178–197.
15. Heinonen PK, Savolainen A, Pystynen P. Septate uterus and habitual abortion: a case report illustrating successful outcome of pregnancy after second metroplasty. *Eur J Obstet Gynecol Reprod Biol* 1986;23:233–238.
16. Fedele L, Ferrazzi E, Dorta M, Vercellini P, Candiani GB. Ultrasonography in the differential diagnosis of "double" uteri. *Fertil Steril* 1988;50: 361–364.