

# RADIOGRAPHIC ASSESSMENT OF BONE LEVEL CHANGES AROUND FOUR IMPLANTS SUPPORTING IMMEDIATELY LOADED MANDIBULAR SCREW-RETAINED PROSTHESIS

Yara A. Kammoun, MSc<sup>1\*</sup>, Ahlam M. El-Sharkawy, PhD<sup>2</sup>,  
Mohamed M. Khamis, PhD<sup>3</sup>, Rania A. Fahmy, PhD<sup>4</sup>

## ABSTRACT

**INTRODUCTION** Immediate restoration of the edentulous mandible with implant-supported fixed screw-retained restorations was extensively studied. When deciding to insert 4 implants to retain a fixed prosthesis; tilting the distal implants determines the anteroposterior distribution and, therefore, the distal cantilever span. The probability of distal implant tilting, however, is significantly affected by mandibular atrophy and the location of the mental foramen dictating the posterior implant axial positioning.

**OBJECTIVES:** Measuring the amount of marginal bone changes around immediately loaded two anterior axial implants and two subsequently tilted implants versus four axially installed implants that retain screw-retained restoration.

**MATERIALS AND METHODS:** In the present research, fourteen edentulous patients were randomly allocated to 2 equal groups. For each participant four implants were installed with either an axial or with axial anterior and tilted posterior implant alignment. All participants received a fixed detachable metal acrylic definitive restoration after 3 months of loading. A baseline, 6, and 12 month follow-up protocol was scheduled to assess marginal changes in bone levels using cone beam computed tomography.

**RESULTS:** Over the follow-up duration of 1 year, none of the interim or definite prostheses were lost. The mean bone loss did not reach 2 mm after 1 year. There were no statistically significant differences between the two evaluated groups ( $P > .05$ ) and the anterior and posterior implants ( $P > .8$ ) in marginal bone loss.

**CONCLUSION:** For immediately loaded 4-implant supported mandibular restorations with distal cantilevers, comparable marginal bone level changes were obtained whether the posterior implants were tilted or not.

**KEYWORDS:** Edentulous mandible, computer-guided flapless technique, tilted implants, axial implants, screw-retained prosthesis.

**RUNNING TITLE:** Bone Level Changes of Axial and Tilted Implants

<sup>1</sup>Assistant Lecturer, Prosthodontic Department, Faculty of Dentistry, Damanhour University, Damanhour City, Egypt.

<sup>2</sup>Professor of Prosthodontics, Faculty of Dentistry, Alexandria University, Alexandria City, Egypt

<sup>3</sup>Professor and Chairman, Prosthodontic Department, Faculty of Dentistry, Alexandria University, Alexandria City, Egypt.

<sup>4</sup>Assistant Professor, Oral Medicine and Periodontology, Faculty of Dentistry, Alexandria University, Alexandria City, Egypt

\*Corresponding author:

E-mail: [yara\\_kammoun@yahoo.com](mailto:yara_kammoun@yahoo.com).

## INTRODUCTION:

Rehabilitation of the edentulous mandible with fixed screw-retained implant-supported restorations has been described in the literature (1-4). Numerous researches have suggested high implant and prosthodontic success rates for interforaminal implants retaining fixed screw-retained prostheses (4-7).

Eventually, 5-6 implants placed in the interforaminal area have been regarded as a gold standard to support a full arch mandibular fixed removable restoration (8,9). Interests had been centered on decreasing the number of implants used to hold fixed implant prosthesis for clinical, technical, and financial considerations (2-7). Clinical conditions such as insufficient bone width and /or length, inferior quality of the residual alveolar bone, and need for bone grafting create difficult conditions for implant placement in edentulous subjects especially in the posterior mandibular region(10-14).

For these compromised situations, the all-on-4 protocol has been recommended as an alternative modality utilizing tilted posterior implants to enhance the anterior-posterior spread of dental implants, decreased distal cantilever length, and improve successful long-term outcomes (10,13).

Unfortunately, distal implant placement and the opportunity of distal implant tilting are markedly influenced by mandibular atrophy. When there is no adequate bone to insert 10 mm length implants (15), the critical location of the inferior alveolar nerve, the mental foramina, and the mental loop; make the distal implant tilting not possible and necessitating axial alignment of distal implants (15-17).

Alfadda (5) concluded that the immediately loaded 4 axial interforaminal implants with a fixed prosthesis in the edentulous mandible was a practical rehabilitation modality that leads to enhancement of oral health status. Furthermore, in a randomized clinical trial (6), authors concluded that the immediately loaded

implants in the anterior mandible that retain a full-arch fixed implant provisional restoration altered from a pre-existing appropriate fabricated complete denture revealed similar outcomes after 5-year observation when compared to delayed loaded implants.

It was recommended by finite element analysis (FEA) researches (18-21) that there is elevated stress concentration around necks of the tilted implant. The tilted inclination subjected implants to the risk of bending and consequently induces the opportunity of elevated marginal bone stress (20). The results of a computed tomography-based three-dimensional FEA (21) confirmed that 4 axial straight implants assisting fixed prosthesis promoted the lowest stress values within implant/prosthetic elements and supporting tissues.

Clinical investigations have been conducted to evaluate full-arch fixed prostheses supported by either axial and/or tilted implants in the rehabilitation of the edentulous mandibles. (4,7, 22-24). Krennmair et al (4) in a retrospective study and another prospective study (7) reported insignificant differences regarding crestal bone loss of distally cantilevered 4-implant-supported fixed mandibular prostheses with posterior implants either in axial or distally tilted direction. However, those studies conducted a different protocol; flap was reflected surgically, and delayed loading protocol was performed. Furthermore, crestal bone loss was assessed by the means of the two-dimensional (2d) radiographs. Measurement of vertical bone level changes over time is a precise indicator in evaluating the overall clinical performance of implants; as the gradual loss of marginal bone finally ends with implant failure (22-26). Cone-beam computed tomography (CBCT) was used to evaluate marginal bone level changes as it provides an accurate three-dimensional (3D) image, with a minimal dose of radiation, less expense, and limited scan time when compared to traditional computed tomography (27). There is a developing body of evidence that supports the use of flapless implant placement protocol; as this treatment modality reduces treatment time, cost, surgical morbidity significantly, and causes minimal disruption to the periosteum; consequently maintaining the bone level around the implants (12,23). Moreover, flapless protocol facilitates immediate prosthetic loading with provisional restorations.

The present day challenge is to immediately restoring edentulous patients with a full arch restoration supported by a minimal number of implants that are placed by the means of the computer-guided flapless protocol (12). This can be carried out with high degrees of success using computer-guided therapy planning and computer-generated surgical guides that enhancing the standard rehabilitation process (23).

The aim of the present clinical trial was to evaluate the marginal bone level changes associated with mandibular fixed four implant-supported rehabilitations with different distal implant inclinations and cantilevers over one year of function. The null hypothesis was that there would be no significant difference in bone level changes between two anterior

axial implants and two posteriorly tilted implants versus four axially placed immediately loaded implants retaining screw-retained mandibular restoration after one year.

## MATERIAL AND METHODS

This prospective clinical trial was conducted after receiving approval of the Ethical Committee (IRB NO: 00010556 - IORG 0008839) at the Faculty of Dentistry, Alexandria University, Egypt. The protocol for this trial was registered in the Pan African Clinical Trial Registry ([www.pactr.org](http://www.pactr.org)) database (Cochrane South Africa) with a special identification number (PACTR201811913815126). All participants accepted the study protocol and signed informed consent.

A sample of 14 healthy edentulous members was enrolled to conduct the present study. The sample size was determined by the means of PASS software version 20, in reference to Ibrahim et al, (28) and it was found to be adequate to estimate the expected scores wanted for this study. The inclusion criteria considered patients having skeletal class I maxillo-mandibular relationship, being edentulous for at least 6 months in the mandible, and the use of complete dentures however having issues in retention and stability of mandibular dentures. Participants had a minimum bone height in the mandibular interforaminal area of 15 mm, and a minimum of 6 mm bone width as established by using CBCT (Scanora 3DX; Soredex). Exclusion criteria involved systemic diseases that may compromise osseointegration and heavy smokers.

All participants received 4 implants (Dentium superline; Dentium Co Ltd, South Korea) that were positioned in the interforaminal region. They had been randomly divided into two groups. Tilted group (n=7) where anterior implants have been axially aligned (12 mm in length and 3.6 mm in diameter) and posterior implants (14 mm in length and 3.6 mm in diameter) were placed just anterior to the mandibular mental foramina and tilted at a 45-degree angle. Axial group (n=7) all implants (12 mm in length and 3.6 mm in diameter) had been axially aligned. Based on a randomization list generated employing an independent party, distribution concealment was performed via the use of sequentially numbered, sealed envelopes. Patients had been assigned in order of their admission (29).

Prior to implant placement, all participants received newly fabricated maxillary, and mandibular complete dentures. The dual-scan technique (30) was used to fabricate a computer-generated surgical guide. Mandibular dentures were duplicated in clear acrylic resin to be used as radiographic guides. An interocclusal record (radiographic index) was also made by using an occlusal registration material (polyvinyl siloxane; Anyflex bite). Every participant was subjected to a CBCT scan while wearing the maxillary denture, mandibular radiographic guide, and index. A second CBCT was performed for the radiographic guide alone (30). The 2 data sets of both scans were subsequently superimposed, guided by the radiopaque fiducial markers. The acquired images were loaded into a 3-dimensional image treatment planning software (Blue Sky Plan; Blue Sky

Bio), where every participant's surgery was virtually planned. Figure (1) and (2) Subsequently an individualized 3D printed, fully guided, tissue-supported surgical template (Form 2; Formlabs) was constructed.

All implants were positioned using the computer-guided flapless approach Figure (3) through the same operator following the manufacturer's instructions. Implant primary stability was measured with the aid of resonance frequency analysis (RFA) (Osstell Mentor; Osstell AB). Implant stability quotient (ISQ) values had been recorded immediately after implant insertion. Smart pegs have been attached to the implants and four readings have been recorded while placing the transducer on the buccal, lingual, mesial, and distal aspects of the peg then their mean was calculated. The ISQ values for all implants had been at the beginning above 60 indicating suitable primary stability and permitting immediate loading of the implants (31).

After implant placement and surgical guide removal, straight (0 degree) multiunit abutments with appropriate collar heights were attached to the 2 anterior axial implants in the tilted group and all implants in the axial group. Angulated (30 degree) multiunit abutments were connected to the posterior implants in the tilted group to achieve a proper alignment with the anterior implants.

Temporary metal cylinders had been connected to the abutments, and the mandibular complete denture was modified and transformed into a transitional screw-retained prosthesis, with access holes (6). All the artificial denture teeth distal to the second premolar had been eradicated (5,6). Occlusion was adjusted to balanced occlusion without interferences, ensuring very gentle dynamic moves (32). The 10 unit provisional resin-based, screw-retained prosthesis was inserted on the same day of the implant surgery. Post-operative instructions for oral hygiene were given to participants who have been further enrolled in a maintenance program for oral hygiene reinforcement on an individual basis

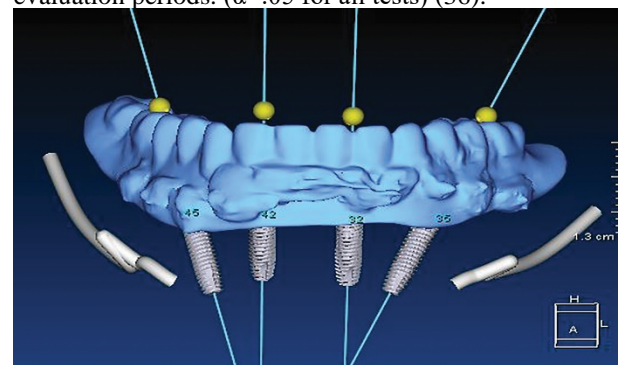
The acrylic transitional restoration was used by participants for 3 months after which the final prosthetic work was started. For all participants, a cast framework (cobalt-chromium) superstructure splinting all 4 implants was constructed having a posterior cantilever extended to the first molar tooth (6). The frameworks were I-shaped with acrylic wraparound design and at least 4 mm thick vertically and four mm wide buccolingually (33). The passivity of the metallic framework was validated intraorally by means of using the single screw test (6,33). The non-passive fit was corrected by sectioning and soldering. The veneering of the metal superstructure was made by means of heat-polymerizing acrylic resin processed onto the framework following standard laboratory procedures combined with prefabricated teeth made of acrylic resin (Acry Rock; Ruthinium). The occlusion for the definitive prostheses included 20° posterior acrylic resin teeth. All prostheses were screw-retained and included 12 resin-veneered units in balanced occlusion without

interferences and with light central point contacts on the cantilever teeth (32).

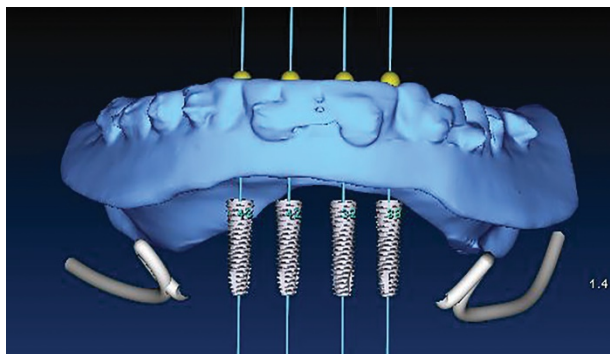
Radiographic assessment was made via utilizing CBCT that was scheduled right away after the surgical operation (baseline), then after 6, and 12 months. The exposure parameters have been standardized (26,34) and slice thickness of 0 mm had been used and the photographs were saved as digital imaging and communications in medicine (DICOM) files. The implants were bisected mesiodistally and buccolingually in the axial pictures of the reconstructed CT. The resultant images provide a panoramic view of every implant (to evaluate mesial and distal bone loss) and cross-sectional images (to consider buccal and lingual bone loss) (26). By using the software program (OnDemand3DApp Software, South Korea), both contrast and brightness of the images were standardized and images were saved on compatible discs (34).

Marginal bone loss used to be evaluated according to the approach described by Elsyad et al (26). The peri-implant marginal vertical bone level was measured on the buccal, lingual, mesial, and distal surfaces of every implant, as the distance between implant-abutment connection and bone-implant contact. Figure (4) Vertical bone loss used to be calculated through subtracting vertical bone height values at 6, and 12 months from values at baseline. One expert investigator made all measurements to ensure standardization (26,34).

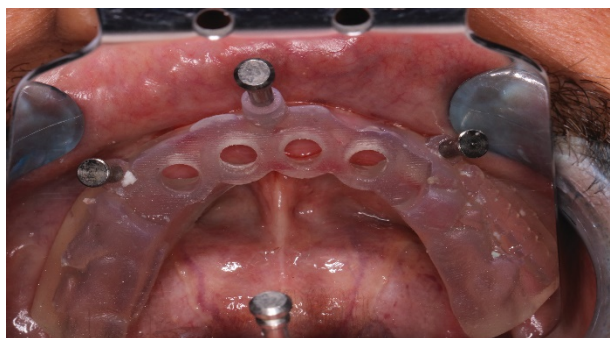
Data were analyzed through an external statistician blinded to the study groups using both patient and implant as the statistical unit. Data were collected and statistically analyzed by using a statistical software program (IBM SPSS package v 21; Armonk, NY: IBM Corp) (35). The Kolmogorov-Smirnov test was used to verify the normality of distribution of variables Student t-test was used to compare two groups for normally distributed quantitative variables, while repeated measures ANOVA with a Bonferroni adjusted post hoc test was assessed for comparison between evaluation periods. ( $\alpha=.05$  for all tests) (36).



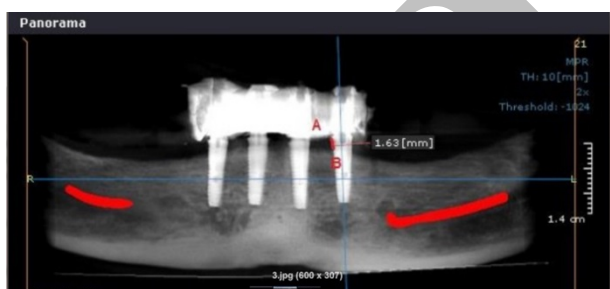**Figure 1:** Virtual planning of tilted group.



**Figure 2:** Virtual planning of axial group.



**Figure 3:** Surgical guide fixed using the fixation screws.



**Figure 4:** Peri-implant marginal vertical bone level measurements.

**RESULTS**

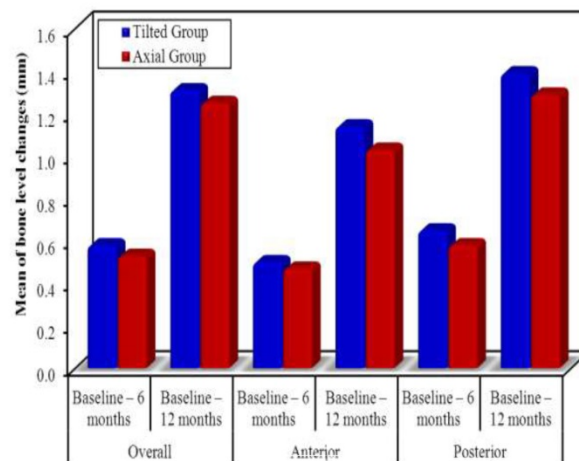
Fifty-six implants were placed in 14 edentulous participants (10 males and 4 females) with a mean age of 48 years (range, 40 to 65 years). The patients' characteristics are listed in Table 1. Each participant received 4 implants and was followed up for 12 months.

The tilted-group consisted of 7 patients (2 female / 5 male; mean age:  $47.29 \pm 4.75$  years; mean months of being edentulous: 19 months; mean distal cantilever:  $13.21 \pm 1.68$  mm) with a total of 28 implants (14 anterior axial implants: 3.6mm in diameter and 12 mm in length, and 14 tilted distal implants: 3.6mm in diameter and 14 mm in length). Axial-group comprised 7 patients (2 female / 5 males; mean age:  $50.29 \pm 7.72$  years; mean months of being edentulous: 12 months; mean distal cantilever:  $15.40 \pm 1.0$  mm) with a total of 28 implants (3.6mm in diameter and 12 mm in length) placed in an axial direction. No participants were lost during follow-up. No implant failures were detected with a survival rate of 100%. None of the definitive prostheses

or the framework fractured throughout the follow-up period.

Table (2) and Figure (5) show mean peri-implant marginal bone level change differences (mm) for axial-group and tilted-group along with anterior and posterior implants from baseline to 12 months evaluation. After 1 year, the mean bone loss was 1.3 mm ( $\pm 0.1$ ) and  $1.25 \pm (0.08)$  for tilted and axial groups respectively. After 6 months, there were no statistically significant differences in marginal bone level changes between the two studied groups ( $P=.116$ ), and anterior implants ( $p=.197$ ) as well as posterior implants ( $P=.069$ ). After 12 months, there were also no statistically significant differences in marginal bone level changes between the two studied groups ( $P=.084$ ), and anterior implants ( $p=.057$ ) as well as posterior implants ( $P=.085$ ).

Furthermore, there was no significant difference ( $P>.05$ ) between anterior and posterior implants when comparing bone level changes within the same group after 6 and 12 months (Table 3).



**Figure 5:** Bar graph of peri-implant marginal bone level changes through during follow up examination.

**Table (1):** The patients', implants', and prosthodontics' characteristics



	Tilted group (n = 7)	Axial Group (n = 7)	Test of Sig.	p
Age	47.29 ± 4.75	50.29 ± 7.72	t=0.876	0.398
Gender				
Male	5 (71.4%)	5 (71.4%)	$\chi^2=0.000$	FE p=1.000
Female	2 (28.6%)	2 (28.6%)		
Distal cantilever	13.21 ± 1.68	15.40 ± 1.0	t=2.957*	0.015*
Smoking habit				
Non smoker	5 (71.4%)	4 (57.1%)	$\chi^2=0.773$	MC p=1.000
Light Smoker <10 sig. per day	1 (14.3%)	1 (14.3%)		
Former smoker	1 (14.3%)	2 (28.6%)		
Months edentulous prior to implant surgery	19 (6 – 48)	12 (6 – 48)	U=21.500	0.710
Implant	(n = 28)	(n = 28)		
Length (12,14mm)	14/14	28/-	$\chi^2=18.667^*$	<0.001*
CL./Ap ratio	0.7 (0.1 – 0.7)	1.5 (1.3 – 1.5)	U=0.000*	0.001*

$\chi^2$ : Chi square test    MC: Monte Carlo  
 FE: Fisher Exact t: Student t-test    U: Mann Whitney test  
 p: p value for comparing between the studied groups  
 \*: Statistically significant at p ≤ 0.05

**Table (2):** Comparison between the two studied groups according to bone level in each period

Bone level		Tilted Group (n = 7)	Axial Group (n = 7)	t	p
Overall	Baseline – 6 months				
	Min. – Max.	0.45 – 0.64	0.50 – 0.57	1.693	0.116
	Mean ± SD.	0.58 ± 0.06	0.53±0.02		
Baseline – 12 months					
Min. – Max.	1.28 – 1.37	1.11 – 1.35	1.883	0.084	
Mean ± SD.	1.31 ± 0.04	1.25±0.08			
Anterior implants	Baseline – 6 months				
	Min. – Max.	0.43 – 0.57	0.41 – 0.54	1.365	0.197
	Mean ± SD.	0.50 ± 0.05	0.47±0.05		
Baseline – 12 months					
Min. – Max.	1.01 – 1.35	1.0 – 1.06	2.316	0.057	
Mean ± SD.	1.14 ± 0.12	1.03 ± 0.02			
Posterior implants	Baseline – 6 months				
	Min. – Max.	0.47 – 0.70	0.55 – 0.60	1.995	0.069
	Mean ± SD.	0.65 ± 0.08	0.58±0.02		
Baseline – 12 months					
Min. – Max.	1.25 – 1.55	1.20 – 1.39	1.875	0.085	
Mean ± SD.	1.39±0.13	1.29±0.08			

Data was expressed by using (Mean ± SD.)

t: Student t-test  
 p: p value for comparing between the studied groups  
 \*: Statistically significant at p ≤ 0.05

**Table (3):** Comparison between the anterior and posterior implants regarding marginal bone loss through different intervals within the same group

Evaluation	Tilted Group (n = 7)		t	p	Axial Group (n = 7)		t	p
	Anterior Implants	Posterior Implants			Anterior Implants	Posterior Implants		
Marginal bone loss (mm)								
Baseline –6 months	0.36 ± 0.03	0.34 ± 0.01	1.875	0.110	0.41 ± 0.05	0.38 ± 0.05	1.884	0.109
Baseline–12 months	1.09 ± 0.07	1.03 ± 0.02	1.909	0.105	1.12 ± 0.07	1.12 ± 0.14	0.000	1.000

Data was expressed by using (Mean ± SD.)

t: Paired t-test

p: p value for comparing between Anterior and Posterior Implants in the same group

\*: Statistically significant at p ≤ 0.05

## DISCUSSION

The null hypothesis was accepted as the clinical outcome of implants in both groups was comparable. There was insignificant crestal bone loss between the axial and tilted group after one year of follow-up.

An overall implant survival of 100% was achieved in the present study, which is in agreement with similar studies on immediate loading in the edentulous mandible. (5,6). The high implant success rate reported in the present study can be attributed to strict inclusion and exclusion criteria.

Computer-generated treatment planning and surgical guide construction were used in the current study to ensure standardization of implant positioning and alignment, reducing operator personal variability (12,27). They also facilitated flapless implant placement with minimal risk of complications especially with posterior implants that were placed in close vicinity to the mental foramina (12,30).

Cone beam computed tomography was used for assessment of vertical bone level changes as it affords information about bone resorption on buccal and lingual aspects of the implants as well as mesial and distal aspects due to its three-dimensional nature. On the other hand, panoramic and periapical radiographs are 2 dimensional only (26,37). Several trials reported acceptable accuracy of CBCT for the assessment of vertical bone level changes around dental implants (26,27,37).

Statistical analysis of the radiographic results of the current trial revealed that vertical bone level changes increased insignificantly after one year in the two studied groups. This may be due to bone remodeling which occurs after implant placement and bone response to healing combined with functional stresses (37).

For both groups, the mean marginal bone level change did not exceed 2 mm after one year of immediate loading that was comparable with the values found in previous studies and within the normal range reported in the literature (5-9). The reduced vertical bone resorption could be credited to the flapless placement technique of the implants that preserves the bone height around the

implants after surgery (12,23), the splinting effect of both the provisional prosthesis and the cast substructure of the definite restoration, and the better quality as well as the density of the basal bone in the interforaminal region (12,27,30).

The posterior tilted implants in the tilted group showed an insignificant increase of marginal bone level changes when compared to both the posterior axial implants in the axial group and the anterior axial implants in the same group. Similar to these findings, a 3-year prospective clinical study showed that there were no statistically significant differences between axial and tilted groups regarding peri-implant marginal bone loss with 100% implants and prostheses survival rates (9). Also, Francetti et al (24) concluded that the rehabilitation of the edentulous jaws with immediately loaded tilted implants is safe and is not associated with a greater marginal bone loss as compared to axially placed implants. Similarly, Agnini et al (38) in a single cohort study demonstrated no significant difference in marginal bone loss between tilted and axial implants in both jaws at a 1-year evaluation.

In contrast with this observation, the findings of the current study disagree with Omori et al (25) who reported that implants supporting angulated abutments yielded significantly more marginal bone loss than those supporting straight abutments, after 1 year of follow-up. In the present study comparable vertical bone level changes for the anterior and posterior implants as well as tilted and axial implants through different intervals in each group were reported; this could be the result of committing to a cantilever length of a maximum of 1.5 times the A-P spread. Another explanation may be due to computer-guided flapless implant placement that leads to the preservation of intact periosteum maintained a better blood supply; thus reducing the likelihood of early bone resorption, with no negative influence on implant survival rate (2,3). Moreover, the shock absorption effect of acrylic teeth together with the reduced masticatory and biting force of the opposing conventional denture could be responsible for the lack of difference in bone loss between the two studied groups as well as anterior and posterior implants (13,32).

Limitations of the current study include the limited number of participants and study duration. Future randomized controlled trials are needed with a greater sample size to confirm the current results. Long-term observations are needed to confirm the superiority of one treatment modality over another.

## CONCLUSIONS

Based on the findings of the present clinical trial, the following conclusions were drawn:

1. Comparable values of marginal bone loss were obtained for immediately loaded 4-implant supported distally cantilevered mandibular restorations whether the posterior implants were tilted or not.
2. Placing 4 flapless immediately loaded interforaminal implants in mandibular edentulous patients to support a full arch fixed restoration provides high implant and prosthodontic success rates.

3. Metal acrylic cantilevered screw-retained prosthesis within a definite cantilever range and distal implant tilting did not negatively affect peri-implant vertical bone level changes.

## CONFLICT OF INTEREST

The authors declare no potential conflict of interest with concerning the authorship and/or publication of this article.

## REFERENCES

1. Storelli S, Del Fabbro M, Scanferla M, Palandrani G, Romeo E. Implant-supported cantilevered fixed dental rehabilitations in fully edentulous patients: Systematic review of the literature. Part II. *Clin Oral Implants Res.* 2018;29:275-94.
2. Eliasson A, Palmqvist S, Svenson B, Sondell K. Five-year results with fixed complete-arch mandibular prostheses supported by 4 implants. *Int J Oral Maxillofac Implants.* 2000;15:505-10.
3. Gallucci GO, Doughtie CB, Hwang JW, Fiorellini JP, Weber HP. Five-year results of fixed implant-supported rehabilitations with distal cantilevers for the edentulous mandible. *Clin Oral Implants Res.* 2009;20:601-7.
4. Krennmair G, Seemann R, Weinländer M, Krennmair S, Piehlslinger E. Clinical outcome and peri-implant findings of four-implant-supported distal cantilevered fixed mandibular prostheses: five-year results. *Int J Oral Maxillofac Implants.* 2013;28:831-40.
5. Alfadda SA. A randomized controlled clinical trial of edentulous patients treated with immediately loaded implant-supported mandibular fixed prostheses. *Clin Implant Dent Relat Res.* 2014;16:806-16.
6. Jokstad A, Alkumru H. Immediate function on the day of surgery compared with a delayed implant loading process in the mandible: a randomized clinical trial over 5 years. *Clin Oral Implants Res.* 2014;25:1325-35.
7. Krennmair S, Weinländer M, Malek M, Forstner T, Krennmair G, Stimmelmayer M. Mandibular full-arch fixed prostheses supported on 4 implants with either axial or tilted distal implants: A 3-year prospective study. *Clin Implant Dent Relat Res.* 2016;18:1119-33.
8. Brånemark PI, Adell R, Breine U, Hansson BO, Lindström J, Ohlsson A. Intra-osseous anchorage of dental prostheses. I. Experimental studies. *Scand J Plast Reconstr Surg.* 1969;3:81-100.
9. Brånemark PI, Svensson B, van Steenberghe D. Ten-year survival rates of fixed prostheses on four or six implants ad modum Brånemark in full edentulism. *Clin Oral Implants Res.* 1995;6:227-31.
10. Maló P, Rangert B, Nobre M. "All-on-Four" immediate-function concept with Brånemark System implants for completely edentulous mandibles: a retrospective clinical study. *Clin Implant Dent Relat Res.* 2003;5:2-9.
11. Malo P, Rangert B, Nobre M. All on 4 immediate-function concept with Branemark System implants

- for completely edentulous maxillae: a 1-year retrospective clinical study. *Clin Implant Dent Relat Res.* 2005;7:88-94.
12. Malo P, de Araujo Nobre M, Lopes A. The use of computer guided flapless implant surgery and four implants placed in immediate function to support a fixed denture: Preliminary results after a mean follow-up period of thirteen months. *J Prosthet Dent.* 2007;97:26-34.
  13. Maló P, Araújo Nobre MD, Lopes A, Rodrigues R. Double full-arch versus single full-arch, four implant-supported rehabilitations: a retrospective, 5-year cohort study. *J Prosthodont.* 2015;24:263-70.
  14. Malo P, de Araújo Nobre M, Lopes A, Moss SM, Molina GJ. A longitudinal study of the survival of all-on-4 implants in the mandible with up to 10 years of follow-up. *J Am Dent Assoc.* 2011;142:310-20.
  15. Jensen OT, Adams MW, Cottam JR, Parel SM, Phillips WR. The all on 4 shelf: Mandible. *J Oral Maxillofac Surg.* 2011;69:175-81.
  16. Jensen O, Cottam J, Adams M, Adams S. Buccal to lingual transalveolar implant placement for all on four immediate function in posterior mandible: report of 10 cases. *J Oral Maxillofac Surg.* 2011;69:1919-22.
  17. Di P, Lin Y, Li JH, Luo J, Qiu LX, Chen B, et al. The All-on-Four implant therapy protocol in the management of edentulous Chinese patients. *Int J Prosthodont.* 2013;26:509-16.
  18. Canay Ş, Hersek N, Akpınar I, Aşık Z. Comparison of stress distribution around vertical and angled implants with finite-element analysis. *Quintessence Int.* 1996;27:591-8.
  19. Watanabe F, Hata Y, Komatsu S, Ramos TC, Fukuda H. Finite element analysis of the influence of implant inclination, loading position, and load direction on stress distribution. *Odontology.* 2003;91:31-6.
  20. Rangert BR, Sullivan RM, Jemt TM. Load factor control for implants in the posterior partially edentulous segment. *Int J Oral Maxillofac Implants.* 1997;12:360-70.
  21. Barão VA, Delben JA, Lima J, Cabral T, Assunção WG. Comparison of different designs of implant-retained overdentures and fixed full-arch implant-supported prosthesis on stress distribution in edentulous mandible-A computed tomography-based three-dimensional finite element analysis. *J Biomech.* 2013;46:1312-20.
  22. Agliardi E, Clerico M, Ciancio P, Massironi D. Immediate loading of full-arch fixed prostheses supported by axial and tilted implants for the treatment of edentulous atrophic mandibles. *Quintessence In.* 2010;41:285-93.
  23. Browaeys H, Dierens M, Ruyffelaert C, Matthijs C, De Bruyn H, Vandeweghe S. Ongoing crestal bone loss around implants subjected to computer-guided flapless surgery and immediate loading using the All-on-4® concept. *Clin Implant Dent Relat Res.* 2015;17:831-43.
  24. Francetti L, Romeo D, Corbella S, Taschieri S, Del Fabbro M. Bone level changes around axial and tilted implants in full-arch fixed immediate restorations. Interim results of a prospective study. *Clin Implant Dent Relat Res.* 2012;14:646-54.
  25. Omori Y, Lang NP, Botticelli D, Papageorgiou SN, Baba S. Biological and mechanical complications of angulated abutments connected to fixed dental prostheses: A systematic review with meta-analysis. *J Oral Rehabil.* 2020;47:101-11.
  26. Elsyad MA, Khirallah AS. Circumferential bone loss around splinted and nonsplinted immediately loaded implants retaining mandibular overdentures: A randomized controlled clinical trial using cone beam computed tomography. *J Prosthet Dent.* 2016;116:741-8.
  27. Liedke GS, Spin-Neto R, da Silveira HE, Schropp L, Stavropoulos A, Wenzel A. Accuracy of detecting and measuring buccal bone thickness adjacent to titanium dental implants-a cone beam computed tomography in vitro study. *Oral Surg Oral Med Oral Pathol Oral Radiol.* 2018;126:432-8.
  28. Ibrahim W, Kaddah A, ElKhadem A. Maintenance requirements of screw- retained implant prosthesis versus telescopic overdenture: A randomized controlled trial. *Int J Sci Res.* 2016;12:1818-23.
  29. Kim J, Shin W. How to do random allocation (randomization). *Clin Orthop Surg.* 2014;6:103-9.
  30. Sanna AM, Molly L, van Steenberghe D. Immediately loaded CAD-CAM manufactured fixed complete dentures using flapless implant placement procedures: a cohort study of consecutive patients. *J Prosthet Dent.* 2007;97:331-9.
  31. Javed F, Ahmed HB, Crespi R, Romanos GE. Role of primary stability for successful osseointegration of dental implants: Factors of influence and evaluation. *Interv Med Appl Sci.* 2013;5:162-7.
  32. Rilo B, da Silva JL, Mora MJ, Santana U. Guidelines for occlusion strategy in implant-borne prostheses. *Int Dent J.* 2008;58:139-45.
  33. Drago C, Howell K. Concepts for designing and fabricating metal implant frameworks for hybrid implant prostheses. *J Prosthodont.* 2012;21:413-24.
  34. Raes F, Renckens L, Aps J, Cosyn J, De Bruyn H. Reliability of circumferential bone level assessment around single implants in healed ridges and extraction sockets using cone beam CT. *Clin Implant Dent Relat Res.* 2013;15:661-72.
  35. IBM Corp. IBM SPSS Statistics for Windows, Version 21.0. Armonk, NY: IBM Corp.; 2012.
  36. Field A. *Discovering Statistics Using IBM SPSS Statistics.* 4<sup>th</sup> ed. London, California, New Delhi: SAGE Publications Ltd; 2013.
  37. Hohlweg-Majert B, Metzger MC, Kummer T, Schulze D. Morphometric analysis - Cone beam

- computed tomography to predict bone quality and quantity. *J Craniomaxillofac Surg.* 2011;39:330-4.
38. Agnini A, Agnini AM, Romeo D, Chiesi M, Pariente L, Stappert CF. Clinical investigation on axial versus tilted implants for immediate fixed rehabilitation of edentulous arches: preliminary results of a single cohort study. *Clin Implant Dent Relat Res.* 2014;16:527-39.

AJD