

A new technique of palatal implantation using platelet rich plasma and septal cartilage for management of obstructive sleep apnea

Ahmed A. Alhamshary^a, Ahmed S. ElKady^a, Omneya Baioumy^a, Salwa A. Abdelhay^b, Mohamed Hassan^a

^aDepartment of otorhinolaryngology, Faculty of Medicine, Benha University, Egypt. ^b Department of Otorhinolaryngology, Phoniatics & Consultant of Phoniatics, Unit of Phoniatics, Faculty of Medicine, Benha University, Egypt.

Correspondence to: Omneya Baioumy, Department of otorhinolaryngology, Faculty of Medicine, Benha University, Egypt.

Email:

omneya_elsayed369@yahoo.com

Received: 4 December 2021

Accepted: 5 March 2022

Abstract

Background: Obstructive sleep apnea (OSA) is a common health problem affecting a large number of people all over the world with great psychological and physiological burdens. **The aim of this study** is to investigate the effect of implantation of septal cartilage and platelet rich plasma in the soft palate as a new technique in treatment of obstructive sleep apnea and snoring. **Patients and Methods:** This study included 30 Patients with mild to moderate OSA were divided into two groups (A and B) each was 15. Group A: n=15(Tonsillectomy and palatal implantation with septal cartilage). Group B: n=15(Tonsillectomy and platelet rich plasma (PRP) injection). **Results:** This study found that both techniques improved day time sleepiness with reduction of apnea-hypopnea index (AHI), also there was marked improvement in radiological parameters in the form of increase of the antro-posterior diameter and retro palatal cross-sectional area but also We found superiority of group A over group B in improvement of these parameters that in Group A: success rate was 86.6% while in Group B: it was 80%. No major postoperative complications were recorded. **Conclusion:** palatal implantation of septal cartilage and platelet rich plasma, both are effective as a treatment of obstructive sleep apnea due to retro-palatal collapse.

Keywords: palatal; implantation; platelet rich plasma; snoring; obstructive sleep apnea.

Introduction

Obstructive sleep apnea (OSA) is a common health problem affecting a large number of

people all over the world. The overall population prevalence ranged from 9% to

38% at apnea-hypopnea index (AHI) ≥ 5 , being higher in men. It increases with age and, in some elderly groups, was as high as 90% in men and 78% in women. The prevalence decreases as the severity increases to range from 6% to 17% at AHI ≥ 15 , being as high as 49% in the advanced ages. OSA prevalence is directly proportional to the body mass index (BMI), so the disease is more common among obese people (1).

Obstructive sleep apnea (OSA) is caused by pharyngeal collapse during sleep and is associated with adverse health outcomes. Pharyngeal collapse can occur at the retropalatal level (soft palate), retroglossal level (tongue base), oropharyngeal lateral walls, and/or hypopharynx. (1).

Palatal implantation was developed in 2003 as an office based procedure performed under local anesthesia with minimal morbidity. This procedure is aimed to reduce snoring by enhancing the stiffness of the soft palate to resist vibration. It can also help prevent soft palate collapse, which can obstruct the upper airway and cause sleep apnea. Several clinical studies have demonstrated the effectiveness of palatal implantation for patients with mild to moderate OSA (2).

Although a lot of publications describing the drawbacks of Uvulopalatopharyngoplasty (UPPP) can be found in scientific literature, there are still many articles highlighting the improvement of AHI after UPPP, not taking postoperative complications into consideration and not comparing its results with the outcomes of other palatal procedures (1).

Another study, found that both Barbed Reposition Pharyngoplasty and Expansion Sphincter Pharyngoplasty may allow to achieve better results than UPPP in terms of PSG parameters and ESS score (1).

The reported success of UPPP as an OSA treatment was between 16% and 83% depending on the definition of a positive outcome and selection of patients (8).

Some authors have defined surgical success after UPPP as a 50% reduction in the AHI, whereas others combine this criterion with an absolute AHI of 20 or less (9).

The success rate of UPPP in unselected patients was around 40%, and this is the main reason why it is not recommended as a standard treatment. Side effects include difficulty swallowing/nasal regurgitation, vpv stenosis, taste disturbances and voice changes (10).

In 2016, another study, concluded that their ESP is a safe and effective procedure in patients with lateral pharyngeal wall collapse, superior to UPPP, and with less short- and long-term complications and that that ESP provides better outcomes than other traditional methods of palatal surgeries (10).

In line with these results, another study, concluded that as a part of multilevel procedure, including conventional nasal surgery and robotic surgery, ESP seems to be superior to UPPP (7).

In 2017, a study showed similar results in patients treated with palatal surgery combined with transoral robotic surgery (TORS). The study showed no major difference between the BRP and the ESP groups, although both techniques proved to be more effective than UPPP in a multilevel setting. However, BRP was seen to be a quicker and easier technique and provided minimal blood loss and better preservation of the mucosal and muscular tissues in comparison with ESP and, of course UPPP (11).

Satisfactory outcomes have been achieved in the treatment of patients with severe obstructive sleep apnea using palatal implantation as part of multi-level or

stepwise surgery. However, there has been relatively little research on using palatal implants alone for the treatment of severe OSA (2).

Septal implantation in soft palate is a safe and feasible procedure. The advantages include providing implants of tailor-made length, biocompatible autologous cartilage and no need for extra-payment for the implant material (3).

Platelets are unique blood elements initiating hemostasis and healing processes. PRP (platelet rich plasma) is plasma contains a high concentration of platelets. Data from human and animal studies provide both direct and indirect evidence that platelet rich plasma plays a considerable role in tissue regenerative processes (4).

Platelet concentrates for surgical use are innovative tools of regenerative medicine, and were widely tested in oral and maxillofacial surgery (5).

The recent development of platelet concentrate for surgical use is an evolution of the fibrin glue technologies used since many years, these various technologies were tested in many different clinical fields, particularly oral and maxillofacial surgery, Ear-Nose-Throat surgery, plastic surgery, orthopedic surgery, sports medicine,

gynecologic and cardiovascular surgery and ophthalmology (6).

This study aimed to investigate the effect of implantation of septal cartilage and platelet rich plasma in the soft palate as a new technique in treatment of obstructive sleep apnea and snoring.

Patients and methods

This study is a prospective randomized case series clinical study. The study was conducted on Otorhinolaryngology clinics of Benha University Hospitals, during the period from May 2019 to May 2021. This study included 30 patients with mild to moderate OSA were divided into two groups

The study was approved by the local ethics committee of faculty of medicine, Benha University in accordance with the declaration of Helsinki. Oral and written consent were taken from all patients who participated in this study

Inclusion criteria:

1. Both sexes
2. Patients > 18 years old, and < 60 years.
3. BMI of patients less than 35 kg/m².

4. Patients diagnosed with OSAS with palatal flutter and collapse.
5. Documented failure/refusal of attempts of conservative treatment measures (not limited to continuous positive airway pressure CPAP).
6. Class 1 occlusion.
7. Pharyngeal tonsillar size grade I–II–III

Exclusion criteria:

1. Patient age < 18 or > 60 years old.
2. Marked deviated septum or marked hypertrophy of inferior turbinate
3. Modified Mallampati classification: class IV tongue position
4. Retrognathia, craniofacial abnormalities, chronic rhinosinusitis, trismus, anesthetic allergies.
5. Patient with central type apnea.
6. Body mass index (BMI) > 35 Kg/m².
7. Failure to attend postoperative follow-up polysomnography
8. Previous surgery to the palate or other surgical treatment of OSAHS.
9. A history of malignancy of the head and neck region, laryngeal trauma, or

other previous oropharyngeal/laryngeal surgery.

10. Class 2 occlusion.

11. Patients with severe medical illness.

Study population:

Thirty patients complaining of OSA (mild to moderate) degree, due to retropalatal collapse. After getting informed consent, patients were randomly allocated to two groups:

Group A: tonsillectomy with palatal implantation with septal cartilage.

Group B: tonsillectomy with palatal PRP injection.

Preoperative evaluation:

1. Full detailed history (personal, present and past history)
2. Complete clinical and physical examination:
3. Otorhinolaryngological examination.
4. Endoscopic examination by Awake Fiberoptic Nasopharyngoscopy with Müller's maneuver:
5. Epworth Sleepiness Scale
6. Polysomnography (PSG):
7. Radiological examination, by Volumetric CT for the upper airway to evaluate the retropalatal space:

8. Other preoperative investigation

- Bleeding profile
- Liver functions
- Kidney functions
- Blood sugar
- Viral markers
- ECG
- Chest X-Ray

Operative procedures:

- Patients were operated upon through the period from May 2019 to May 2021
- All the operative procedures were done by same E.N.T. surgeon.
- Patients were randomly allocated to two groups each included fifteen patients.
- ✓ Group A: n=15

Tonsillectomy and palatal implantation with septal cartilage.

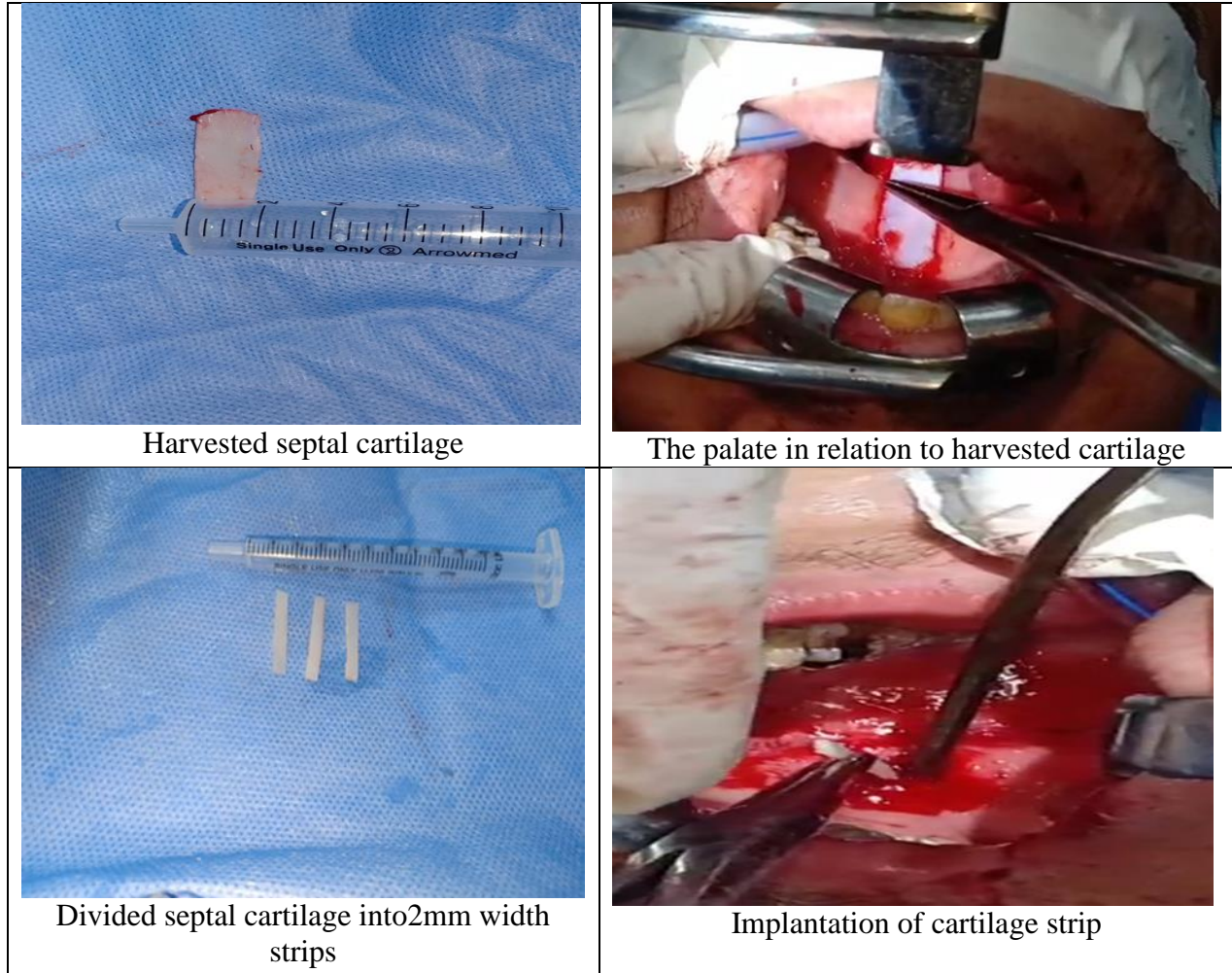
- ✓ Group B: n=15

Tonsillectomy and PRP injection

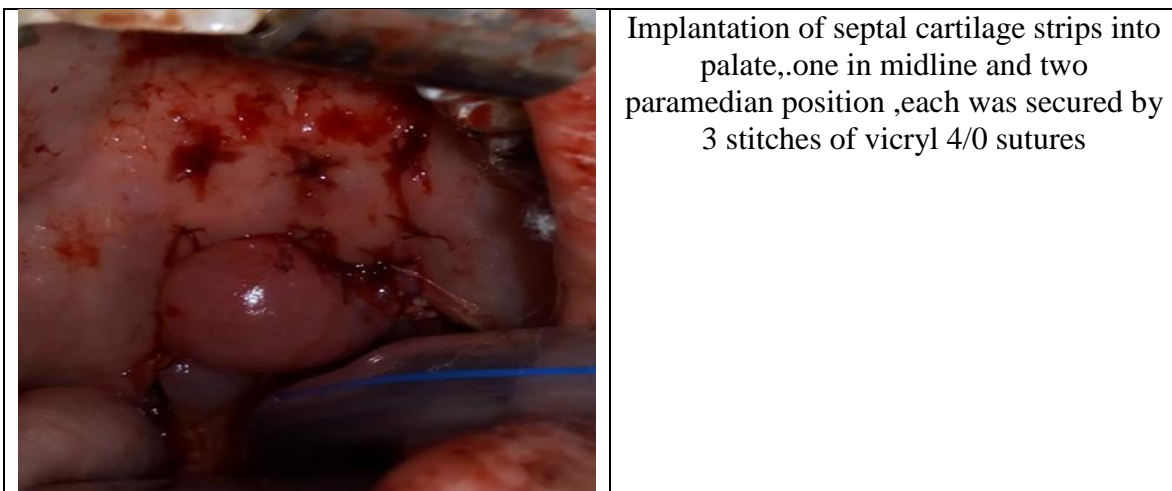
- All patients underwent transoral endotracheal intubation under general anesthesia.

Group A:as shown in figure1,2

- Submucous resection and harvesting septal cartilage about (4cm length, 2cm width)
- ✓ Preservation of the harvested septal cartilage in sterile saline with gentamicin (50 mg/500 ml) until implantation in the soft palate.
- ✓ Tonsillectomy
- ✓ Dividing septal cartilage into 3 strips each was about 0.2cm width and 4 cm length with the strip lengths adjusted according to the length of the soft palate in each patient. Shallow incisions were made on the cartilage strips to increase the contact surface area.
- ✓ Then mark the junction of the hard and soft palates, and local anesthesia was administered by injecting lidocaine HCl (1%) and epinephrine (1:100,000) into the soft palate.
- ✓ After 10 min, a 3-mm incision was made in the midline of the soft palate, approximately 5 mm below the junction of the soft and hard palates.
- ✓ Converse scissors were used to create a vertical tunnel between the muscular and glandular layers from the junction of the soft and hard palates to the base of the uvula.
- ✓ The first pre-prepared cartilaginous strip was then inserted into the midline submucosal tunnel, and the incision was closed with 4-0 Vicryl .
- ✓ This was repeated for the remaining two implants into bilateral paramidline tunnels at horizontal intervals of 2 mm.
- ✓ An additional simple suture was placed in the middle of the implanted cartilage to keep the implant in the inserted position



(Fig1: group A)






(fig 2: group A: septal cartilage implants in final position)

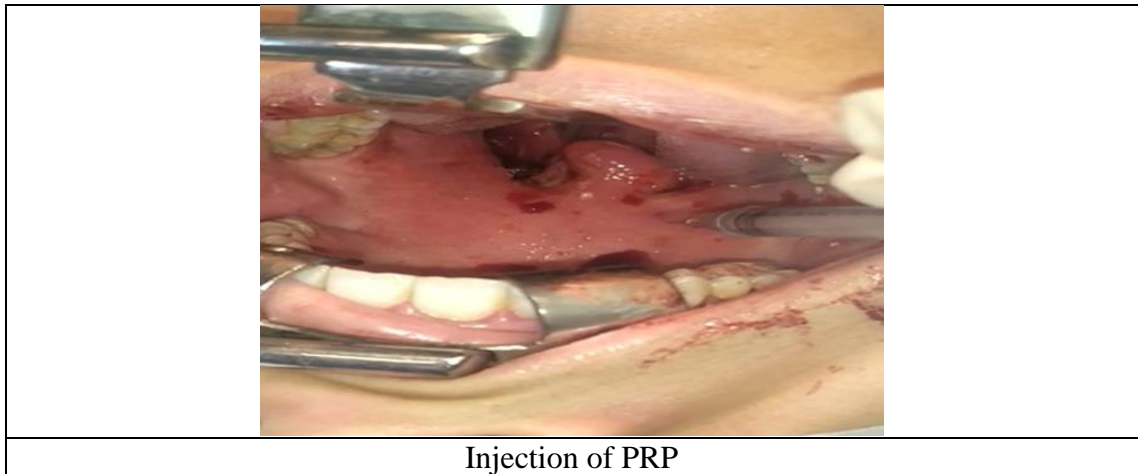
Group B: as shown in figure 3,4

- ✓ Tonsillectomy
- ✓ Prepared PRP 6cm is then divide into 3 insulin syringes each contain 1 cm of PRP.
- ✓ Injection of the PRP was done at three lines:
 1. 1st line is midline

2. 2nd line rt paramedian
 3. 3rd line Lt paramedian
- ✓ Each line starts 0.5 mm from the junction of soft and hard palate to the base of the uvula
 - ✓ Aspiration then slowly injection of PRP in three lines as described

	<p>Tube containing the PRP centrifugate</p>
	<p>Syringe containing about 4cm of PRP</p>
	<p>PRP is then divided into 3 parts each contain 1cm of PRP</p>

(Fig:3: group B)



(fig 4: groupB)

Postoperative Evaluation:

- A. Clinical examination:** Follow-up visits were scheduled at 1,2, 3 weeks, and 3 months postoperative.
- B. Epworth sleepiness scale (ESS):** Daytime sleepiness Assessment Snoring loudness and ESS score were assessed at baseline, 3 months after surgery. In addition, the AHI and BMI between baseline and 3 months postoperative were also compared.
- C. Polysomnography (PSG):** Polysomnography was done after 3 months, following the same protocol as preoperative one. Surgical success was considered when there was 50% reduction of preoperative AHI index.

D. Awake Fiberoptic Nasopharyngoscopy with Müller's maneuver:

Awake Endoscopic examination with Müller's maneuver to evaluate the site of collapse were done for all patients after 3 months

E. Radiologic investigations: volumetric CT were done 3 months postoperatively for all patients, following The same protocol as preoperative evaluation.

F. Complications:

We recorded, Postoperative soft palate implant extrusion, infection, bleeding, throat discomfort, foreign body sensation and velopharyngeal insufficiency were identified as an adverse event in this study.

Statistical analysis

The clinical data were recorded on a report form. These data were tabulated and analyzed using the computer program SPSS (Statistical package for social science) version 25 to obtain descriptive data. Descriptive statistics were calculated for the data in the form of mean and standard deviation ($SD\pm$) for quantitative data, Frequency and distribution for qualitative data. In the statistical comparison between the different groups, the significance of difference was tested using student's t-test, Chi square test, Fisher exact test and Correlation Study.

Results

This study was conducted on 30 patients attending the outpatient clinic of Otorhinolaryngology Department, Benha University Hospital, Benha University. Studied patients were divided into two groups: Group A: no=15, studied patients were treated by tonsillectomy and palatal implantation with septal cartilage. Group B: no=15, studied patients were treated by tonsillectomy and palatal PRP injection. sociodemographic data in (table 1).

Comparison between the two studied groups according to decrease in Body mass index

(BMI): The mean decrease in BMI of Group A was (0.47 ± 1.36 kg/m²). While The mean BMI of Group B was (0.67 ± 1.18 kg/m²) which is not a significant difference (P-Value 0.967) (table 2).

Comparison between the two studied groups according to decrease in Epworth sleepiness scale (ESS); The mean decrease in ESS of group A was (6.27 ± 2.19). While The mean decrease in ESS of group B was (4.87 ± 2.56) which is not a significant difference (P-Value 0.089) (table 3).

Comparison between the two studied groups according to decrease in Apnea-Hypopnea Index (AHI); The mean decrease in AHI of group A was (5.91 ± 2.50). While The mean decrease in ESS of group B was (5.47 ± 1.77) which is not a significant difference (P-Value 0.713) (table 4).

Comparison between the two studied groups according to Increase in Antro-Posterior diameter (A-P) (mm); The mean increase in A-P diameter (mm) of group A was (2.64 mm \pm 1.57 mm). While The mean increase in A-P diameter (mm) of group B was (1.67 mm \pm 1.0 mm) which is not a significant difference (P-Value 0.106) (table 5)

Comparison between the two studied groups according to degree and site of collapse in retropalatal area during Muller maneuver;

Regarding) improvement in degree of collapse in retropalatal area: In group A the 1st degree became 86.7% while became 80.0 % in group B which was not a significant difference between both groups (P-Value0.592) (figure 5)

Regarding site of collapse in retropalatal area during Muller maneuver: in group A; improvement with no detected site of collapse in 86.7% while it is 80.0% at group

B, which is not a significant difference between both groups (P-Value0.592) (figure 6)

Comparison between the two studied groups according to the Outcome: Success rate = cured cases + success cases, In Group A: success rate was 86.6% while in Group B: success rate 80%, which is not a significant difference between both groups; P-Value:1.000 (table 6)

Table (1): Comparison between the two studied groups according to demographic data

Gender	Group A (n = 15)		Group B (n = 15)		Test of Sig.	p
	No.	%	No.	%		
Male	9	60.0	8	53.3	$\chi^2=0.136$	0.713
Female	6	40.0	7	46.7		
Age (years)						
Min. – Max.	22.0 – 53.0		21.0 – 42.0		t=1.124	0.271
Mean ± SD.	35.93 ± 9.0		32.80 ± 5.97			
Median (IQR)	35.0 (31.0 – 40.50)		33.0 (29.50 – 37.0)			

p: p value for comparing between the studied groups, significant if >0.05.

Table (2): Comparison between the two studied groups according to change in BMI

BMI	A			B			U	P
	Preop	Postop	P	Preop	Postop	P		
Range	20.0 – 30.70	18.0 – 30.0		20.0 – 32.0	20.0 – 32.0			
Mean ± SD.	25.20 ± 3.60	24.73 ± 4.10	0.205	25.07 ± 4.03	24.40 ± 4.58	0.045*	111.0	0.967
Median (IQR)	25.0 (22.50 – 28.0)	24.0 (21.50 – 28.50)		24.0 (22.50 – 28.50)	23.0 (20.0 – 28.0)			

p: p value for comparing between Preop: pre-operative and Postop: post-operative *: Statistically significant at p ≤ 0.05 BMI: body mass index

Table (3): Comparison between the two studied groups according to change in ESS

ESS	A			B			U	P
	Preop	Postop	P	Preop	Postop	P		
Range	8.0 – 17.0	3.0 – 13.0		5.0 – 17.0	2.0 – 14.0			
Mean ± SD.	12.13 ± 2.77	5.87 ± 3.16	0.001*	10.53 ± 3.93	5.67 ± 3.74	0.001*	71.50	0.089
Median (IQR)	11.0 (10.0 – 14.0)	5.0 (3.50–7.0)		9.0 (7.50 – 14.50)	4.0 (3.0 –7.0)			

p: p value for comparing between pre and post*: Statistically significant at $p \leq 0.05$

ESS: Epworth Sleepiness Scale

Table (4): Comparison between the two studied groups according to change in AHI

AHI	A			B			U	P
	Preop	Postop	P	Preop	Postop	P		
Range	7.0 – 22.0	3.0 – 16.0		8.0 – 20.0	4.0 – 15.0			
Mean ± SD.	13.53 ± 5.32	7.62 ± 4.32	0.001*	12.93 ± 3.97	7.47 ± 3.60		103.0	0.713
Median (IQR)	11.0 (9.0 – 17.50)	6.0 (4.15 – 10.0)		12.0 (10.0 – 15.50)	6.0 (5.0 – 8.50)	0.001*		

p: p value for comparing between pre and post*: Statistically significant at $p \leq 0.05$

AHI: Apnea-Hypopnea Index

Table (5): Comparison between the two studied groups according to change in A-P diameter (mm)

A-P diameter (mm)	A			B			U	P
	Preop	Postop	P	Preop	Postop	P		
Range	3.10 – 10.0	3.20 – 11.40		2.50 – 10.0	2.70 – 11.20			
Mean ± SD.	6.59 ± 2.15	9.23 ± 2.54	0.001*	6.59 ± 2.25	8.26 ± 2.71	0.001*	73.50	0.106
Median (IQR)	6.20 (5.30 – 8.20)	9.80 (9.0 – 11.0)		6.30 (5.50 – 8.45)	8.50 (8.15 – 10.0)			

p: p value for comparing between pre and post*: Statistically significant at $p \leq 0.05$

A-P diameter: Antro-posterior diameter of retropalatal (RP) area

Table (6): Comparison between the two studied groups according to outcome

Outcome	Group A (n = 15)		Group B (n = 15)		χ^2	MC p
	No.	%	No.	%		
Success	8	53.3	8	53.3		
Cure	5	33.3	4	26.7	0.435	1.000
Fail	2	13.3	3	20.0		

χ^2 : Chi square test

MC: Monte Carlo

p: p value for comparing between the studied groups *: Statistically significant at $p \leq 0.05$

Cure: AHI post < 5 and ESS post < 10 and reduction of both of them > 50%

Success: AHI post < 15 and ESS post < 10 and reduction of both of them > 50%

Failure: AHI post ≥ 30 or ESS post ≥ 10 or reduction of both of them $\leq 50\%$

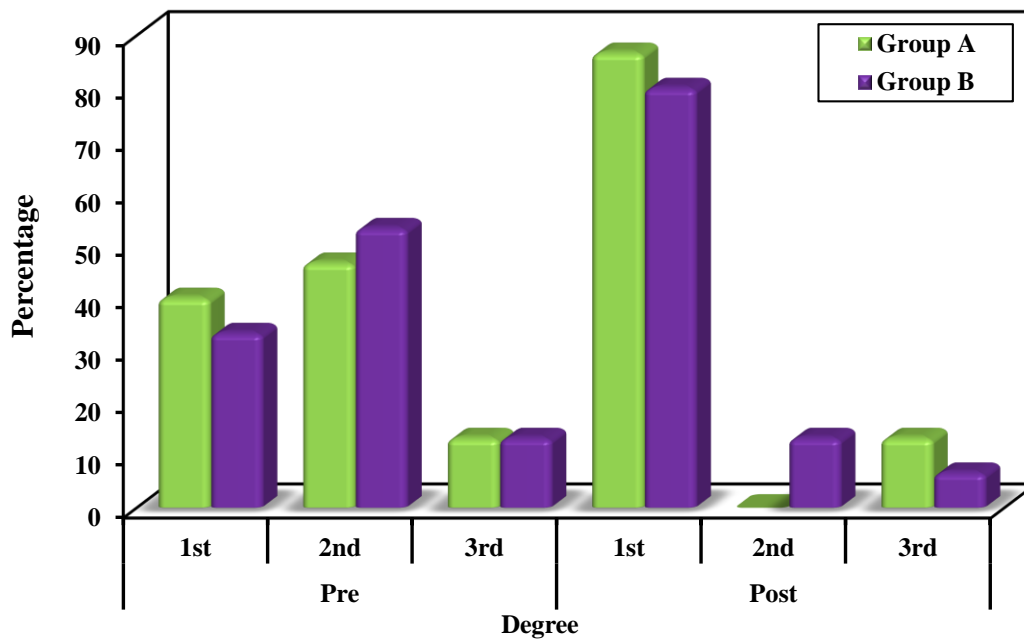


Figure (5): Comparison between the two studied groups according to Degree of collapse in retropalatal area during muller maneuver

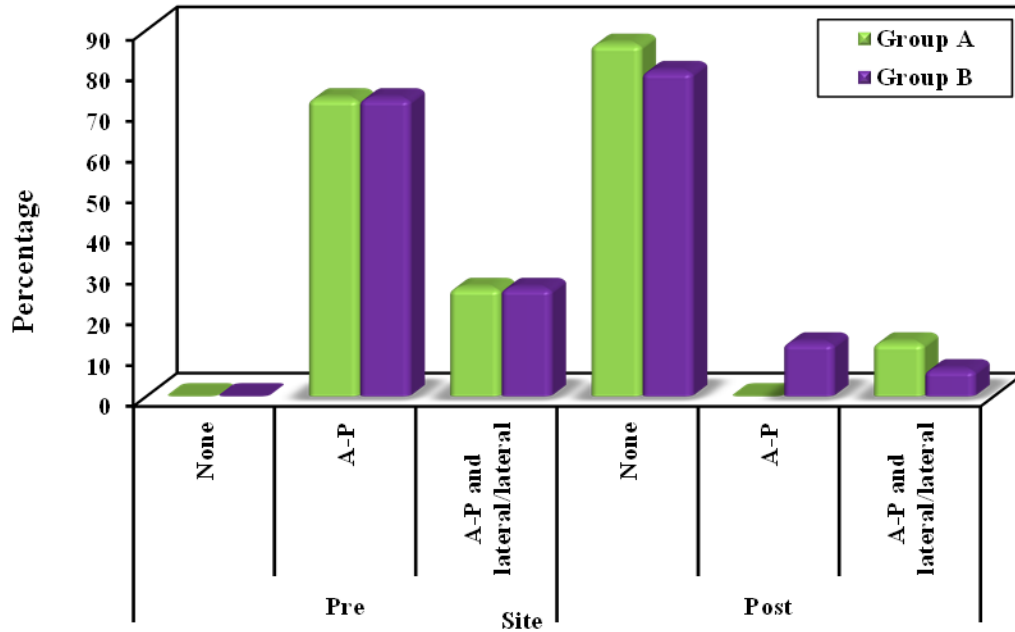


Figure (6):Comparison between the two studied groups according to Site of collapse in retropalatal area d

Discussion

Different palatal techniques have been introduced along the last two decades, especially after the evolution of palatal surgeries focused on the lateral pharyngeal wall collapse, from the first lateral pharyngoplasty to the newest Barbed Reposition Pharyngoplasty (7).

As the field of sleep surgery expands and new procedures are being created to address the dynamic upper airway, a thorough understanding of the fundamental principles of this surgery is critical to success (12). our study was undertaken to address the effect of palatal stiffening using our novel two

techniques to determine the short-term success rate of the two procedures in the elimination of snoring and OSA, our work may address a clinical application of this biological product (PRP) and auto graft (septal cartilage) in management of obstructive apnea due to retropalatal collapse.

The presence of palatal implants does not in any way affect or complicate subsequent palatal revision procedures(13) hence we adopt the non-respective manner for correction of the AHI with preservation of

soft palate horizontal part and vertical part (uvula) and pillars .

The challenge of this procedure is preservation of soft tissue. Based on the above facts, the rationale of this study stands upon Evaluating a non-resective techniques of soft palate surgeries to prove which technique allows the best functional outcomes in OSA patients with single-level collapse (retropalatal collapse).

So the intrapharyngeal surgery (soft palate surgery) is a target-oriented procedure that needs to be performed precisely and combines with integrated treatment for OSA patients (14).

This study found that both techniques of palatal implantation using septal cartilage and platelet rich plasma improved day time sleepiness, with reduction of AHI, also there was marked improvement in radiological parameters in the form of increase in the antro-posterior diameter but also We found superiority of group A over group B in improvement of these parameters that In Group A: success rate was 86.6% while in Group B: it was 80%. No major postoperative complications were recorded; as: severe bleeding which requires surgical intervention, severe edema which requires tracheotomy, or secondary infection. Some

minor complications were recorded, mainly pain and dysphagia that improved in a few days

Conclusion

palatal implantation of septal cartilage and platelet rich plasma, both are effective as a treatment of obstructive sleep apnea due to retropalatal collapse.

References

1. Rashwan MS, Montevecchi F, Cammaroto G, Badr el Deen M, Iskander N, El Hennawi D, et al. Evolution of soft palate surgery techniques for obstructive sleep apnea patients: A comparative study for single-level palatal surgeries. *Clin Otolaryngol.* 2018;43(2):584–90.
2. Hu H-C, Kuo C-L, Tung T-H, Chen S-C, Li LP-H. Long-term results of palatal implantation for severe obstructive sleep apnea patients with prominent retropalatal collapse. *J Chinese Med Assoc.* 2018;81(9):837–41.
3. Lee Y-C, Lee L-A, Li H-Y. The palatal septal cartilage implantation for snoring and obstructive sleep apnea. *Auris Nasus Larynx.* 2018;45(6):1199–205.
4. Everts PAM, Knape JTA, Weibrich G, Schönberger JPAM, Hoffmann J, Overdevest EP, et al. Platelet-rich plasma and platelet gel: a review. *J Extra Corpor Technol.* 2006;38(2):174–87.
5. Simonpieri A, Del Corso M, Vervelle A, Jimbo R, Inchingolo F, Sammartino G, et al. Current knowledge and perspectives for the use of platelet-rich plasma (PRP) and platelet-rich fibrin (PRF) in oral and maxillofacial surgery part 2: Bone graft, implant and reconstructive surgery. *Curr Pharm Biotechnol.* 2012;13(7):1231–56.

6. Bielecki T, M Dohan Ehrenfest D. Platelet-rich plasma (PRP) and Platelet-Rich Fibrin (PRF): surgical adjuvants, preparations for in situ regenerative medicine and tools for tissue engineering. *Curr Pharm Biotechnol.* 2012;13(7):1121–30.
7. Vicini C, Hendawy E, Campanini A, Eesa M, Bahgat A, AlGhamdi S, et al. Barbed reposition pharyngoplasty (BRP) for OSAHS: a feasibility, safety, efficacy and teachability pilot study. “We are on the giant’s shoulders.” *Eur Arch Oto-Rhino-Laryngology.* 2015;272(10):3065–70.
8. Yousuf A, Beigh Z, Khursheed RS, Jallu AS, Pampoori RA. Clinical predictors for successful uvulopalatopharyngoplasty in the management of obstructive sleep apnea. *Int J Otolaryngol.* 2013;2013.
9. Megwalu UC, Piccirillo JF. Methodological and statistical problems in uvulopalatopharyngoplasty research: a follow-up study. *Arch Otolaryngol Neck Surg.* 2008;134(8):805–9.
10. Pang KP, Pang EB, Win MTM, Pang KA, Woodson BT. Expansion sphincter pharyngoplasty for the treatment of OSA: a systemic review and meta-analysis. *Eur Arch Oto-Rhino-Laryngology.* 2016;273(9):2329–33.
11. Cammaroto G, Montevecchi F, D’Agostino G, Zeccardo E, Bellini C, Meccariello G, et al. Palatal surgery in a transoral robotic setting (TORS): preliminary results of a retrospective comparison between uvulopalatopharyngoplasty (UPPP), expansion sphincter pharyngoplasty (ESP) and barbed repositioning pharyngoplasty (BRP). *Acta Otorhinolaryngol Ital.* 2017;37(5):406.
12. Yang LC, Hu SW, Yan M, Yang JJ, Tsou SH, et al. Antimicrobial activity of platelet-rich plasma and other plasma preparations against periodontal pathogens. *J Periodontol* 2015;86:310–318.
13. Randerath WJ, Verbraecken J, Andreas S, Bettge G, Boudewyns A, et al. European Respiratory Society task force on non-CPAP therapies in sleep apnoea (2011) Non-CPAP therapies in obstructive sleep apnoea. *Eur Respir J* 37:1000–1028
14. Cho JH, Kim JK, Lee HY and Yoon JH. Surgical anatomy of human soft palate. *Laryngoscope.* 2013 Nov;123(11):2900-4. doi: 10.1002/lary.24067. Epub 2013 May 17. PMID: 23686451.

To cite this article: Ahmed A. Alhamshary, Ahmed S. ElKady, Omneya Baioumy, Salwa A. Abdelhay, Mohamed Hassan. A new technique of palatal implantation using platelet rich plasma and septal cartilage for management of obstructive sleep apnea. *BMFJ* 2022;39(1):279-294. DOI: 10.21608/bmfj.2022.109428.1519