

## Role of Acitretin in Management of Multiple Warts: Review Article

Mohanad Abdelslam Omar, Ahmad Nofal, Waleed Mohamed Al Balat

Department of Dermatology, Venereology & Andrology, Faculty of Medicine, Zagazig University, Egypt

\*Corresponding author: Mohanad Abdelslam Omar, E-Mail: mohannadh1989@gmail.com

### ABSTRACT

**Background:** Human papillomavirus infection (HPV) is the primary cause of cutaneous viral warts. Plantar warts, flat warts, filiform warts, periungual warts, anogenital warts, oral warts, and pulmonary papillomas are just a few of the many types of warts that can be found on different parts of the body. Warts can be treated using cryotherapy, electrocautery, and lasers, which are all local destructive techniques. It is not realistic to use these therapies for several lesions since they may be unpleasant or cause scarring or dyspigmentation or recurrence. Psoriasis and other keratinization disorders have been widely treated using acitretin is aromatic systemic 2<sup>nd</sup> generation retinoid with immunomodulatory, antiproliferative, and anti-differentiative characteristics. With acitretin, patients with many recalcitrant warts have reported good results with doses of 0.5 mg/kg each day.

**Objective:** To evaluate the potential role of acitretin in management of multiple warts.

**Methods:** The databases were searched for articles published in English in 3 data bases [PubMed – Google scholar-Science direct] and Boolean operators (AND, OR, NOT) had been used such as acitretin and multiple warts OR HPV and in peer-reviewed articles between January 2006 and November 2021.

**Conclusion:** Several recent studies showed that acitretin shows great clinical success in treating of widespread as well as persistent warts, whether it is used alone or in conjunction with other therapies.

**Keywords:** Acitretin, Multiple warts.

### INTRODUCTION

HPVs infect stratified epithelium and cause long-term infections. These infections can persist because papillomaviruses have evolved ways to resist both the innate and adaptive immune systems' impacts during the earliest phases of infection <sup>(1)</sup>.

HPV causes warts, which are visible signs of infection on the skin. Depending on the epithelium surface and the HPV type that caused the infection, warts can take on a variety of shapes and sizes. HPV infection can cause a variety of symptoms, including plantar warts (*Verruca plantaris*), genital tract warts (*Condyloma acuminata*), common warts (*Verruca vulgaris*) and flat or plane warts (*Verruca plana*) <sup>(2)</sup>.

By direct or indirect touch, warts can be transmitted from one person to another. Skin that has been macerated and has come into touch with rough surfaces, such as those found in swimming pools and laundry rooms, increases the risk of infection through the environment <sup>(2)</sup>.

### Role of acitretin in management of multiple warts:

Retinoids are a class of medications that include acitretin. Vitamin A-like retinoids include both natural and synthetic substances. During embryonic development, vitamin A aids in immune system regulation and has an impact on cellular growth, differentiation, and proliferation. Additionally, retinoids have immunologic anti-inflammatory effects, apoptosis-inducing properties, and anti-tumor benefits <sup>(3)</sup>.

Vitamin A raffinates include retinol (an alcohol), retinal (an aldehyde), and retinoic acid (a retinoic acid derivative). Vitamin A cannot be synthesized by the body, thus it must be obtained from food sources like milk as well as eggs. Plants produce carotenoids,

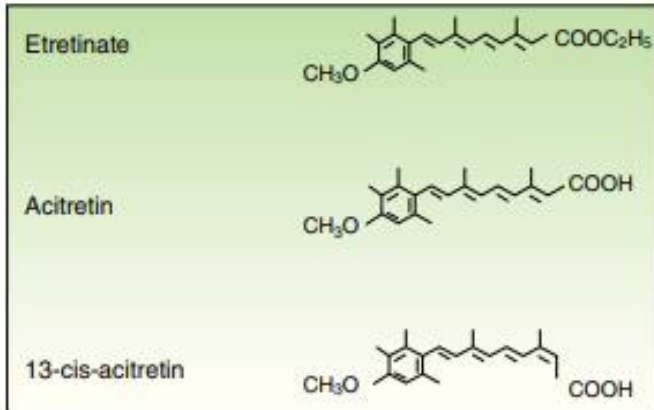
which are precursors to vitamin A. It's here that beta-carotene is converted into retinal and absorbed. In the presence of light, the oxidation of one beta-carotene molecule creates two retinal molecules. Vitamin A deficiency has been linked to skin hyperkeratosis, mucous membrane squamous metaplasia, and precancerous lesions in animals, according to research <sup>(3)</sup>.

Three synthetic generations of retinoids are currently available. 1<sup>st</sup> generation retinoids involve alitretinoin (9-cis RA), tretinoin (all-trans RA) as well as isotretinoin (13-cis-retinoic acid). 2<sup>nd</sup> generation involve acitretin as well as etretinate. 3<sup>rd</sup> generation involve bexarotene, tazarotene as well as adapalene. Etretinate and acitretin, two aromatic retinoids discovered by Bolag in 1972, were the first of their kind. Etretinate's retinoic acid metabolite, acitretin, is known as retinoic acid. Acitretin, on the other hand, is relatively water-soluble and accumulates in adipose tissue in low concentrations <sup>(4)</sup>. To treat psoriasis, acitretin has been approved by the FDA for use in combination dermatologists frequently prescribe UVB or UVA radiation to treat severe plaque-type psoriasis. Cyclosporine and biologics are sometimes used in tandem with this treatment. It works well when administered alone, and it's the only systemic retinoid approved by the FDA to treat the disease <sup>(4)</sup>.

Off-label use of acitretin in dermatology has been documented. Acitretin has been used as a chemo-preventative strategy for non-melanoma skin malignancies in patients with solid organ transplantation. Pityriasis rubra pilaris (PRP), Darier disease, and ichthyoses such as lamellar ichthyosis have all been treated with acitretin. Lichen planus, Grover disease, and lupus erythematosus are other conditions for which acitretin is used <sup>(5)</sup>.

**Pharmacology:**

Acitretin (C<sub>21</sub>H<sub>26</sub>O<sub>3</sub>, PM 326.42934 [g/mol]) (figure 1) in its free acid state and as an active metabolism of its precursor etretinate, is 2<sup>nd</sup> generation monoaromatic retinoid. It has a substantially shorter half-life than its predecessor. Both medications are chemically and physically distinct despite their structural resemblance. Acitretin has replaced etretinat because of its superior pharmacokinetic profile, effectiveness, and safety <sup>(6)</sup>.

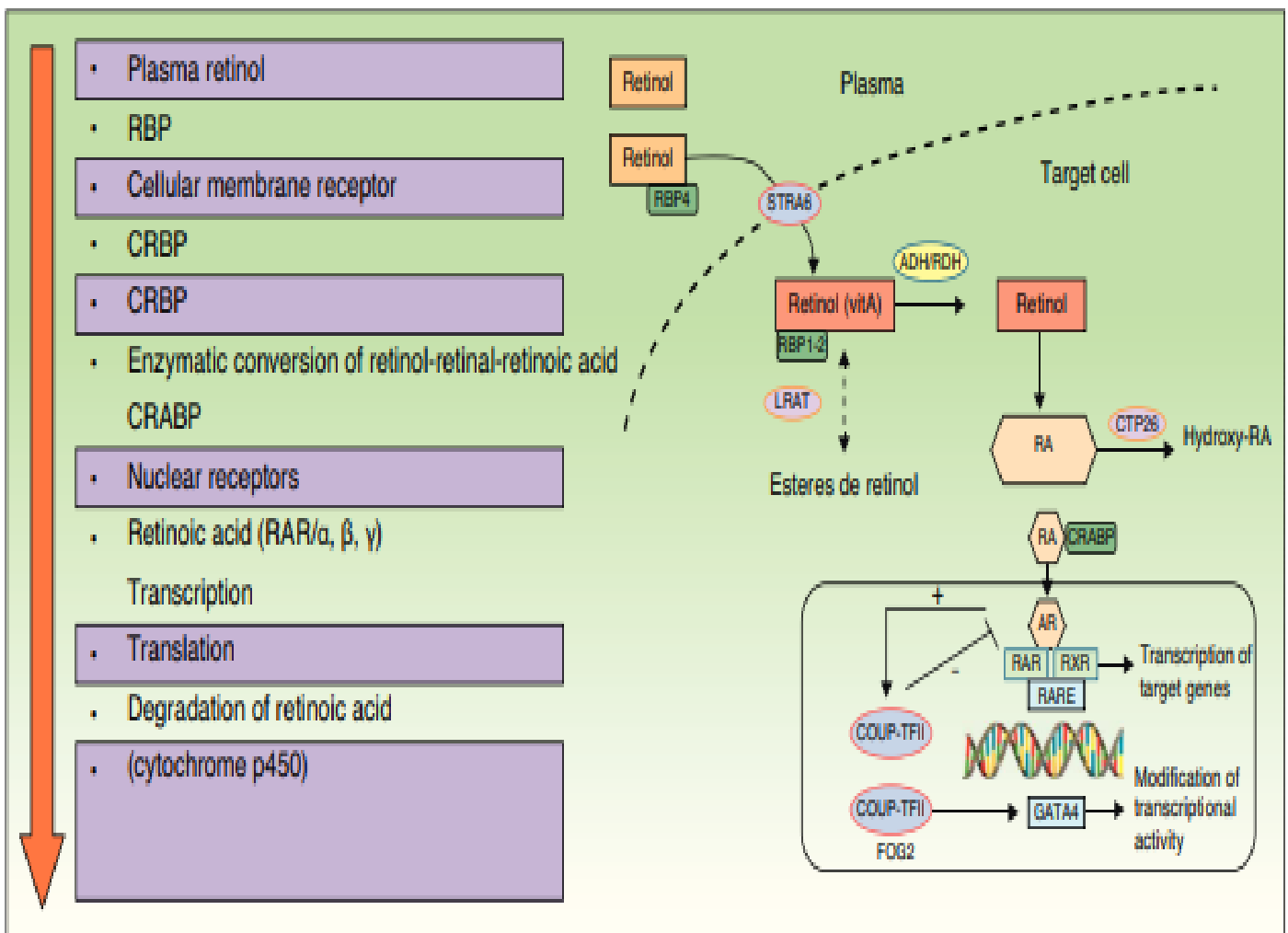


**Figure (1):** The acitretin chemical structure <sup>(6)</sup>.

**Mechanism of action:**

Intracellular transport is carried out by binding retinoic acid binding protein to the cytosolic retinoic acid-binding protein, which serves as the intracellular carrier. Retinoids influence transcription in the nucleus by binding to two groups of nuclear receptors in the nucleus: retinoid X receptors as well as retinoic acid receptors. Retinoid X receptors as well as retinoic acid receptors families alpha, beta, and gamma receptor subtypes are all represented in the genome in distinct ways. Retinoid X receptors binds to retinoic acid receptors generating a heterodimer.

Nuclear receptors including peripheral peroxidase-activated receptors, vitamin D3, as well as thyroid hormone can all bind to retinoid X receptors and create homodimers. A conformational shift occurs when the ligand binds, releasing co-repressors and recruiting co-activators. Working indirectly, retinoid-receptor complexes inhibit other transcription factors. Competition for retinoic acid-binding proteins between acitretin and retinoic acid occurs. Multiple retinoid acid receptors can be activated by acitretin, although acitretin does not bind to them <sup>(7)</sup>.



**Figure (2):** Retinoids' mechanism of action <sup>(8)</sup>.

The anti-inflammatory and anti-proliferative properties of acitretin make it an excellent anti-aging drug. The epithelium's keratinocyte differentiation is restored as a result of this treatment. Interferon-gamma, migration inhibitory factor-related protein-8, as well as Interleukin-6 expression are all inhibited as a result. To achieve its desired effects, the agent is thought to interact and activate all of the nuclear subtypes of retinoic acid and retinoid X-receptors <sup>(4)</sup>.

#### Pharmacogenetics:

Nuclear receptors that are implicated in signal transduction, as well as numerous additional pathway regulators, are all encoded by more than 20 genes discovered to yet <sup>(6)</sup>.

#### Indications:

Specific indications are listed in the summary of product characteristics for Neotigason (SPC): Severe congenital ichthyosis, Darier disease as well as palmoplantar pustular psoriasis, are all severe forms of psoriasis that are resistant to other treatments. Acitretin is still an important part of psoriasis treatment. Psoriasis with a desquamative component should be investigated for acitretin treatment because of its potential to modulate skin cell keratinization. Psoriasis patients with pustular psoriasis, especially those with palmoplantar psoriasis, should consider acitretin as a first-line therapeutic option <sup>(9)</sup>.

Psoriatic erythroderma patients have historically turned to acitretin as the first-line treatment. Because etretinate has been shown to be equally effective as acitretin in the treatment of psoriasis vulgaris, it was assumed that the equivalence between the two would also hold true for erythroderma <sup>(10)</sup>.

Acitretin has not been tested in erythroderma directly, and there is little data that support its use in this context. First-line therapy options for psoriatic erythema should no longer include acitretin because of the availability of faster-acting and more effective medications (such as cyclosporine). Melanoma patients, those with solid tumours or lymphoproliferative malignancies and those with HIV should be treated with acitretin as the first-line systemic therapy, as it does not contain immunosuppression in its mechanism of action. Patients with psoriatic arthritis should not use acitretin <sup>(11)</sup>.

#### Contraindications:

The use of acitretin should be avoided at: (1) An expectant mother or a lady who is planning on getting pregnant. (2) Absence of contraceptive use. (3) Mothers who are breast-feeding.

Concurrent usage with methotrexate or tetracycline methotrexate, severe hepatic or renal impairment, persistent excessively increased blood lipid levels, or pregnancy within three years of

medication termination are all contraindications. Doctors who prescribe acitretin should ensure that women of reproductive age do not become pregnant for at least 3 years after stopping the medicine <sup>(4)</sup>.

#### Administration:

- **Initial:** Take a single dose of 25 to 50 mg with the main meal each day.
- **Maintenance:** After an initial response to therapy, administer 25 to 50 mg orally daily. There should be a justification for the maintenance dose in clinical efficacy and permissibility.

Before beginning phototherapy, patients should take 25 mg orally once daily for two weeks at a time, with the UV light dosage gradually decreasing. After seven days of taking acitretin, if a patient is already on a steady dose of UV radiation, cut the dose by 30 to 50 percent <sup>(4)</sup>.

#### Negative effects:

Epistaxis, tinnitus, paronychia, high liver enzymes, high creatinine phosphokinase, hypercholesterolemia, paresthesia, hyperesthesia, alopecia, cheilitis, exfoliation of the skin, Capillary leak syndrome xeroderma, nail disease, pruritus, hepatotoxicity, exfoliative dermatitis erythematous rash, rigors, hypertriglyceridemia, hypoglycemia, hyperglycemia, xerophthalmia, pseudotumor cerebri and rhinitis <sup>(12)</sup>.

#### Uses:

Acitretin is a successful treatment for hyperkeratotic diseases when used alone or in conjunction with other medications. Because of its anti-keratinizing, anti-inflammatory, and anti-proliferative properties. It is regarded as an established second-line treatment for psoriasis. As a cancer-preventative agent and it has antineoplastic characteristics <sup>(13)</sup>.

Viral replication and assembly may be inhibited by the use of acitretin. With amazing success, oral retinoids have been utilised to treat widespread and persistent warts without any recurrences. Oral acitretin, administered alone or in combination, has demonstrated remarkable improvement in Epidermodysplasia verruciformis, a hereditary illness marked by widespread and persistent HPV infection, pityriasis versicolor-like lesions, and reddish plaques <sup>(14)</sup>. As a result, oral acitretin is a viable therapeutic choice for warts that are both persistent and difficult to treat <sup>(15)</sup>.

**Nofal et al.** <sup>(16)</sup> reported that acitretin as monotherapy or in combination with other treatments has been proven to be effective in the treatment of extensive and resistant warts in clinical trials. **Zhang et al.** <sup>(17)</sup> illustrated that systemic acitretin monotherapy was studied for clinical efficacy and safety in patients

with extensive/recalcitrant cutaneous warts. For two months, the clinical effectiveness and safety of acitretin was monitored every two weeks in the patients receiving a dose of 0.8 mg kg<sup>-1</sup> day<sup>-1</sup>. Some (42.9%, 6/14) of acitretin patients had a complete reaction, 28.6% (4/14) had an excellent response, and 28.6% (4/14) had a good response after two months of treatment. The medicine was well-tolerated, and no one was forced to stop taking it because of negative side effects. Side effects including dry skin and cheilitis are not uncommon. During the six-month follow-up period, there were no recurrences. Warts patients who are unfit or unable to accept traditional methods of treatment can benefit from acitretin monotherapy, which is an effective, safe, and well-tolerated treatment option.

## CONCLUSION

Several recent studies showed that acitretin shows great clinical success in treating of widespread as well as persistent warts, whether it is used alone or in conjunction with other therapies.

**Financial support and sponsorship:** Nil.

**Conflict of interest:** Nil.

## REFERENCES

1. **Ferreira A, Ramalho A, Marques M *et al.* (2020):** The interplay between antiviral signalling and carcinogenesis in human papillomavirus infections. *Cancers (Basel)*, 12: 646-51.
2. **Tong Y, Stephen K, Zsuzsanna Z (2019):** Human Papillomavirus Infection. *Harper's Textbook of Pediatric Dermatology*, Pp: 588-597. <https://onlinelibrary.wiley.com/doi/book/10.1002/9781119142812>
3. **Ighani A, Partridge A, Shear N *et al.* (2019):** Comparison of management guidelines for moderate-to-severe plaque psoriasis: a review of phototherapy, systemic therapies, and biologic agents. *Journal of Cutaneous Medicine and Surgery*, 23 (2): 204-221.
4. **Zito P, Mazzoni T (2021):** Acitretin. *StatPearls* . <https://www.ncbi.nlm.nih.gov/books/NBK519571/>
5. **Kaushik S, Lebwohl M (2019):** Review of safety and efficacy of approved systemic psoriasis therapies. *International Journal of Dermatology*, 58 (6): 649-658.
6. **Carretero G, Ribera M, Belinchón I *et al.* (2013):** Guidelines for the use of acitretin in psoriasis. *Actas Dermo-Sifiliográficas (English Edition)*, 104 (7): 598-616.
7. **Chen L, Zhu Y, Papandreou G *et al.* (2018):** Encoder-decoder with atrous separable convolution for semantic image segmentation. *ECCV.*, 18: 801-818.
8. **Dogra S, Stathokostas L (2012):** Sedentary behavior and physical activity are independent predictors of successful aging in middle-aged and older adults. *Journal of Aging Research*, 2012:190654.
9. **Sbidian E, Maza A, Montaudié H *et al.* (2011):** Efficacy and safety of oral retinoids in different psoriasis subtypes: a systematic literature review. *Journal of the European Academy of Dermatology and Venereology*, 25: 28-33.
10. **Paul C, Gallini A, Maza A *et al.* (2011):** Evidence-based recommendations on conventional systemic treatments in psoriasis: systematic review and expert opinion of a panel of dermatologists. *Journal of the European Academy of Dermatology and Venereology*, 25: 2-11.
11. **Strober B, Berger E, Cather J *et al.* (2009):** A series of critically challenging case scenarios in moderate to severe psoriasis: a Delphi consensus approach. *Journal of the American Academy of Dermatology*, 61 (1): S1-S46.
12. **Chiricozzi A, Panduri S, Dini V *et al.* (2017):** Optimizing acitretin use in patients with plaque psoriasis. *Dermatologic Therapy*, 30 (2): e12453.
13. **Sarkar R, Chugh S, Garg V (2013):** Acitretin in dermatology. *Indian Journal of Dermatology, Venereology & Leprology*, 79 (6): 759-771.
14. **Choi Y, Lee K, Kim W *et al.* (2006):** Treatment of extensive and recalcitrant viral warts with acitretin. *International Journal of Dermatology*, 45 (4): 480-482.
15. **Krupa Shankar D, Shilpakar R (2008):** Acitretin in the management of recalcitrant warts. *Indian J Dermatol Venereol Leprol.*, 74: 393-395.
16. **Nofal A, Khattab F, Nofal E *et al.* (2018):** Combined acitretin and Candida antigen versus either agent alone in the treatment of recalcitrant warts. *Journal of the American Academy of Dermatology*, 79 (2): 377-378.
17. **Zhang S, Xu X, Liu Y *et al.* (2020):** Successful clearance of extensive/recalcitrant cutaneous warts by acitretin monotherapy: A case series study. *Dermatologic Therapy*, 33(3): 13390.